



## Crescentic flap for the reconstruction of the nose after skin cancer resection



Federica Arginelli <sup>a, \*</sup>, Attilio Carlo Salgarelli <sup>b</sup>, Barbara Ferrari <sup>a</sup>, Amanda Losi <sup>a</sup>, Pierantonio Bellini <sup>b</sup>, Cristina Magnoni <sup>a</sup>

<sup>a</sup> Department of Dermatology, University of Modena and Reggio Emilia, Via del Pozzo 71, 41124 Modena, Italy

<sup>b</sup> Maxillofacial Surgery Unit, Department of Head and Neck Surgery, University of Modena and Reggio Emilia, Via del Pozzo 71, 41124 Modena, Italy

### ARTICLE INFO

#### Article history:

Paper received 22 October 2015

Accepted 9 February 2016

Available online 16 February 2016

#### Keywords:

Non-melanoma skin cancer

Oncologic surgery

Crescentic flap

Reconstructive surgery

### ABSTRACT

**Purpose:** Non-melanoma skin cancers are the most frequent skin tumours; in 25.5% of cases, they are reported to affect the nasal area. For an excellent surgical outcome, first of all the radical excision of the lesion is important, with appropriate margins of healthy skin in order to avoid recurrences. Moreover is important to achieve a good aesthetical result, avoiding distortion of the aesthetic units and preserving their functions.

**Material and methods:** We have applied the modified crescentic flap, described by Smadja in 2007, to 24 nasal skin defects left by oncologic surgery. It consists of the crescent-shaped resection of Burow's triangle all around the alar groove that allows the advancement of the flap to the tip of the nose, hiding the scar in the alar groove.

**Results:** The outcome and the long-term follow-up were completely satisfactory both for patients and for surgeons.

**Conclusion:** For skin defects localized in the midline or paramedian line of the dorsum of the nose, the crescentic flap seems to be a good solution to obtain the better aesthetic result with respect to both anatomy and function of the nasal area, sparing the patient a second intervention or an overly invasive procedure.

© 2016 European Association for Cranio-Maxillo-Facial Surgery. Published by Elsevier Ltd. All rights reserved.

## 1. Introduction

Skin cancers are traditionally divided into two groups: melanoma and non-melanoma skin cancers (NMSCs). The latter are the most frequent skin tumours among the adult and elderly population; their incidence grows proportionally with age, and prolonged sun exposure is one of the highly proved risk factors for their onset. Basal cell carcinoma (BCC) is the most common tumour within the NMSC group, accounting for 77% of cases, followed by squamous cell carcinoma (SCC) at 20%. Tumours such as melanoma, Merkel cell carcinoma, cutaneous lymphoma, Kaposi's sarcoma, and other sarcomas are less frequent (3%). Major risk factors related to the onset of BCCs are UV cumulative exposure (in particular sun burns, but also tanning treatments), advanced age, white skin, and, above

all, Fitzpatrick's skin types I and II. Likewise, SCCs are more frequent in individuals of white ethnicity with a history of exposure to UV rays and the human papillomavirus (HPV) infection (in particular types 16, 18, and 31) (Fleming et al., 1995; Salgarelli et al., 2010; Kallini et al., 2015).

NMSCs typically grow on areas exposed to the sun, in particular on photodamaged skin chronically subjected to ultraviolet radiation damage. Therefore, the most common site of onset is the face skin (86.6%) and, more specifically, the nasal area in 25.5% of cases (Silverstone and Gordon, 1996; Salgarelli et al., 2010).

When treating a tumour, first of all we have to achieve its complete and radical excision, with appropriate margins of healthy skin in order to avoid recurrences and to obtain a tumour-free patient status. The scientific literature highlights several studies showing the surgical parameters necessary for the excision of primary NMSCs. Tumours less than 2 cm in diameter require 4 mm of healthy skin margins to obtain a 95% cure rate. If we are facing a high-risk tumour, SCC in particular, showing evidence of

\* Corresponding author. Present/permanent address: Department of Dermatology, Via del Pozzo 71, 41124 Modena, Italy.

E-mail address: [dottorressa.federica.arginelli@gmail.com](mailto:dottorressa.federica.arginelli@gmail.com) (F. Arginelli).

subcutaneous invasion or recurrence or measuring more than 2 cm in diameter, it is better to keep 6-mm margins in order to obtain a 95% cure rate (Wolf and Zitelli, 1987; Brodland and Zitelli, 1992; Huang and Boyce, 2004).

After the excision of the tumour, oncologic surgery is accompanied by the reconstructive phase, which is extremely important to preserving the physiologic functions of each anatomic unit; moreover, the integrity of complex facial functions and expressivity should not be separated from the search for a good cosmetic result. In particular, the nasal area has some fundamental features that the surgeon has to know: first of all, the presence of adjacent convex and concave surfaces; second, the limited laxity of the nasal skin; and finally, the sebaceous composition of distal nasal skin. Last but not least, the function of the nose must always be preserved (Brodland and Zitelli, 1992). Zitelli's bilobed flap, adapted from Esser's design of the first bilobed flap, is one of the most useful flaps for nasal reconstruction (Salgarelli et al., 2010).

The surgical technique described in this paper, applied to the reconstruction of nasal skin defects left by oncologic surgery, was reported by Smadja in 2007, who presented a refinement of the works of Snow et al., Yoo and Miller, and Wheatley et al. Refinement by Smadja consists of the crescent shape resection of Burow's triangle all around the alar groove, which allows the advancement of the flap to the tip of the nose, hiding the scar in the alar groove. We have applied that technique to defects of the midline and paramedian line of the dorsum of the nose near the tip (Snow et al., 1990; Wheatley et al., 1997; Smadja, 2002; Yoo and Miller, 2003; Smadja, 2007).

## 2. Material and methods

The above-mentioned technique of crescentic flap has been applied to 24 cases of nose reconstruction after surgical excision of nodular basal cell carcinomas more than 1 cm in diameter arising

on the dorsum of the nose, on the midline and paramedian line, near the tip (Figs. 1A and 2A). The patients came to the attention of our Departments from January 2012 to December 2014; they were 15 men and 9 women, with a mean age of 75 years (standard deviation  $\pm$  4.7 years).

The diagnosis was made by clinical visit along with dermoscopic and reflectance confocal microscopy (RCM) examinations. RCM confirmed the diagnostic criteria already described in the literature (Longo et al., 2014).

After obtaining the patient consent and performing preliminary examinations before the surgery, the surgeon drew the surgical lines on the skin surface. The drawing began at the inferior part of the defect situated near the ala, continued in an arc shape to meet the alar groove, and then extended inferiorly in the alar–labial groove at its junction with the upper lip. The surgical intervention was performed with local anaesthesia with sedation, and the excision for the histopathological examination was made keeping 5 mm of macroscopically healthy skin surrounding the lesion. In all cases, the histological examination confirmed the radical excision of nodular basal cell carcinoma, with deep and lateral margins free of neoplasia.

After having completely excised the tumour, a round-shaped defect was present. Then the incision followed the drawing, starting from the bottom of the middle part of the defect along the alar groove onto the cheek and then turning around the alar lobule and finally ending at the alar labial groove. The flap was then positioned, creating a superior dog-ear that required excision. A second dog-ear around the nasal lobule, as a skin Burow's triangle, was excised in the shape of a crescent to optimise the mobility of the cheek towards the skin defect (Fig. 1B,C). The size of the tissue loss and the laxity of the skin determined the width of the excised crescent. The stitches were made with 5-0 Ethilon to close the cheek and the alar crease. If the tumour was 1.5 cm or less in the larger diameter, the unilateral technique was preferred (right or left) (Fig. 1); if the lesion was 1.5 cm or more in the larger diameter,

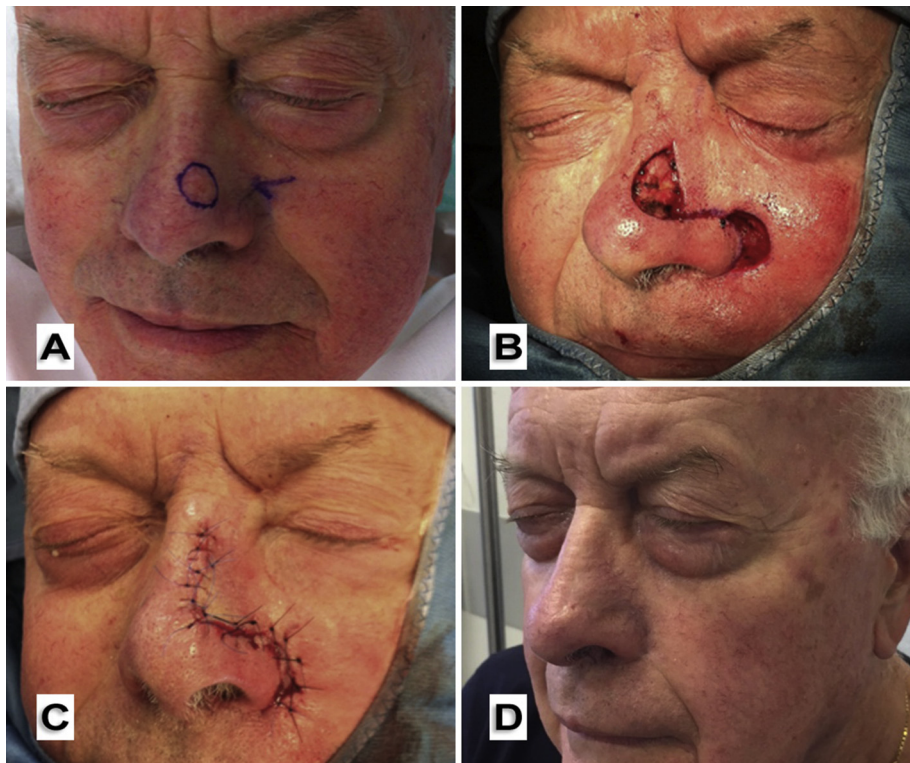
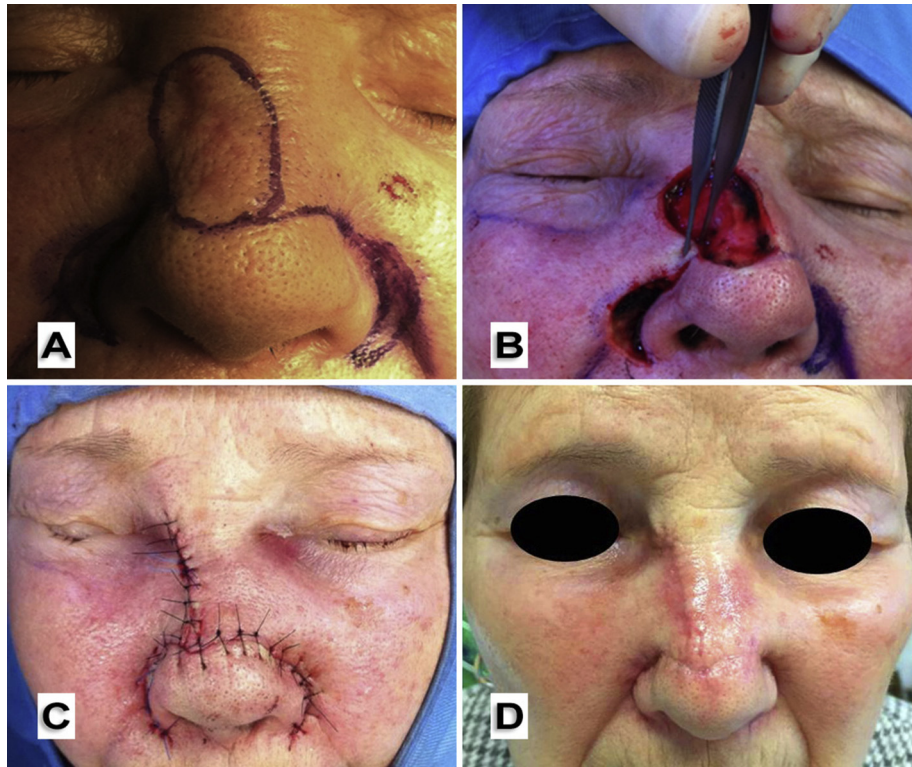


Fig. 1. Unilateral left crescentic flap. (A) Before surgery. (B, C) During surgical reconstruction. (D) After 6 months' follow-up.



**Fig. 2.** Bilateral crescentic flap. (A) Before surgery. (B, C) During surgical reconstruction. (D) After only 3 weeks' follow up.

the bilateral technique was used, which consists of the same steps repeated on both sides of the nose (Fig. 2). In particular, the classic unilateral technique was applied in 18 cases and the bilateral technique in the remaining 6 cases. The right or left side of the crescentic unilateral flap depended on the position of the primitive tumour, if it was located on the paramedian right or left side of the dorsum of the nose.

The day after surgery, the first medication was administered at the hospital. Oral antibiotics were prescribed for nearly 1 week of therapy (2 g of penicillin daily for 6 days). Patients were recommended not to wet the medication and not to remove it for 1 week. After that, another medication was performed at the hospital. Then, after 12–14 days since the surgery, the stitches were removed.

Preoperative, intraoperative, and postoperative photographs were performed. Patients were recommended to use sunscreen on the scar, and follow-up visits were scheduled monthly.

### 3. Results

No signs of infections or haematomas appeared during the post-surgery follow-up. In 3 cases (2 bilateral and 1 unilateral), a small area of necrosis appeared, probably due to the dehiscence of the surgical margins. In particular, the unilateral flap showed a small area of dehiscence in correspondence of the distal margin (tip of the flap), and in the bilateral cases it appeared at the joint of the two flaps. The necrosis quickly resolved through daily application of fusidic acid ointment, for 1 week after the removal of the stitches. Patients were completely satisfied with the results, and no alteration of the physiologic functions of the nose was observed.

### 4. Discussion

NMSCs of the nose are extremely frequent, and the defect left by the surgical excision of the primary tumour is one of the most

challenging subunits to reconstruct. The aesthetic and functional reconstruction of full-thickness soft tissue nasal defects after oncologic surgery involves many options. The main objective of oncologic surgery is to achieve a tumour-free patient status. Therefore, in the planning of the reconstruction, it is important for the surgeon to evaluate three factors: the precise determination of the features of the tissue loss (topography, extent, depth, skin texture, colour, and contours); the replacement of the missing tissue with its best equivalent (nearby nasal skin); and the respect of the aesthetic units of the nose, distinguished into aesthetic subunits by Burget and Menick and the location of scars in the natural folds and grooves of the nose. These principles are better respected by choosing skin flaps for the reconstruction of the dorsum of the nose, instead of skin grafting and secondary intention healing (Burget and Menick, 1985; Smadja, 2007).

A previous accurate analysis of the patient's history, comorbidities, therapies, and expectations is mandatory. The choice of the best nasal reconstruction depends on the location, size, and depth of the surgical defect and, of course, on the surgeon's skills. In our experience with elderly patients or with patients with severe comorbidities, a simple and quick technique is often preferred over a complex reconstruction, obtaining a similar aesthetic outcome, even if the aesthetic units are not completely respected.

In the literature, we can find few guidelines with little supporting evidence. Direct elliptical closure can be used only for small defects (<1 cm in diameter), which must be located in a non-sebaceous area with a more marked laxity of the skin. Several flaps have been described, with the aim of achieving good aesthetic quality, avoiding skin grafts (Salgarelli et al., 2011), but that are aesthetically less accepted by the patient and with a high risk of failed engraftment due to the sebaceous composition of the nose, and with the subsequent high risk of necrosis.

Zitelli's bilobed flap is a simple double transposition flap that can be used to repair defects located on the distal and lateral area of

the nose, where the skin is least mobile (lateral tip, supratip, or tissue near the tip), with a diameter between 0.5 and 1.5 cm (Zitelli, 1989, 1990; Salgarelli et al., 2010; Salgarelli et al., 2011; Kim et al., 2015).

The modified nasalis flap is a transposition flap based on the angular artery that rotates toward the midline and nasal tip, and leaves donor scars located in the naso-jugal and alar creases. It can be used to reconstruct defects located on the central and lateral nasal tip or supratip smaller than 2.0 cm in diameter (Wheatley et al., 1997; Salgarelli et al., 2000, 2011). Both Zitelli's and modified nasalis flap are better applied to defects smaller than 1.5–2 cm in diameter and preferentially located on the tip or supratip area or near the wing.

For tumours located on the alar lobules leaving defects with diameters between 1.5 and 2.0 cm, the nasolabial flap could be a good option. This transposition flap, which exploits the laxity of the cheek skin, requires a second surgical action, lengthening the time of postoperative recovery: after 3 weeks from the excision infact, the pedicle has to be divided (Zitelli, 1990; Salgarelli et al., 2011).

The forehead flap is a two-stage, more invasive procedure used for reconstruction of wide defects (2.5–3.0 cm and more in diameter) of the distal nose (tip in particular), particularly where the cartilage is involved and large ulcerations are present (Zitelli and Fazio, 1991; Hoasjoe et al., 1994; Salgarelli et al., 2011). Another flap used for the tip, especially for large defects, is the axial fronto-nasal flap, an alternative, less invasive, to the forehead flap (Xue et al., 2009).

Recently, Kim et al. proposed an algorithm to select the optimal technique for repairing nasal BCC surgical defects according to their size and location, concluding that the island pedicle flap is a versatile option that can be widely applied to the reconstructions of defects. Moreover, they observed that the nasolabial interpolation flap is excellent for the reconstruction of the lower nose, including the nasal tip and orifices, with an interval of only 1 week required before the second operation (Yoo and Miller, 2003; Kim et al., 2015).

Finally, the crescentic naso-jugal flap (Snow et al., 1990) is used in particular for defects involving the dorsum and the supratip area of the nose, as we showed in our cases, exploiting the laxity of the skin of the lateral surface of the nose and the cheek to replace the tissue lost.

Our cases presented herein have illustrated a refinement of a naso-jugal flap, characterized by the use of a crescentic perialar skin excision, instead of a Burow's triangle, to enable the advancement of the cheek, as experienced by Smadja; the modified Burow's triangle is used to correct the dog-ear created by the movement of the flap; the replacement for the initial tissue loss is provided by the adjacent skin, exploiting the laxity of the tissue of the lateral surface of the nose and cheek and finally placing the scars in the natural alar and alar-labial groove, without anatomic distortion. A crescentic flap, in our experience, seems to be preferable to a Rieger-Marchac flap for the reconstruction of the dorsum of the nose. A Rieger-Marchac flap, in fact, requires a large detachment of tissue with an increased risk of bleeding and consequently low vitality of the flap; moreover, it is not easily applicable to supratip defects. Crescentic flap technique, in our experience, is a suitable choice because the surgical technique is quick and minimally invasive for the patient. Moreover, minimizing anatomic distortion, is possible to obtain symmetrical scars by using adjacent skin, thereby avoiding skin grafts, with consequent good aesthetic results.

In contrast to the forehead flap, the crescentic flap can be raised in a single stage under local anaesthesia, and late revisions have not been required.

Possible complications could be ecchymosis, inflammatory reactions to the sutures, haematomas, infections, necrosis of the tip of

the flap, and dehiscence of the surgical wound. Only 12.5% of the patients developed a small area of necrosis of the tip of the flap, which subsequently healed within a few days, thanks to the application of fusidic acid ointment. No adverse events or persistent necrotic areas have been registered, and patients were completely satisfied with the results.

## 5. Conclusion

Oncological surgery involving the skin of the head and neck must satisfy a few important principles, including radical surgery and aesthetic outcome. The dorsum and the supratip areas of the nose are the aesthetic focal point of the face, so the irregularities in colour, texture, and thickness are easily noted.

The nose has tridimensional contours and complicated structures; thus its defects are a real challenge to reconstruct. In fact, a great variety of techniques and flaps have been described in this localization, with particular attention to the aesthetic units so that they are not to be broken by incision lines crossing their borders (Yoo and Miller, 2003). However, transposition or rotation flaps may result in 'dog-ear' deformities or in distortion, and are often difficult to cover large defects using these techniques (Xue et al., 2009).

We think that unilateral and bilateral crescentic flaps could be indicated in post-oncologic surgery reconstruction of the skin defects located on the supratip or on the midline and paramedian lines of the dorsal region of the nose, exploiting crescentic perialar skin excision, instead of a Burow's triangle, to enable the advancement of the cheek and to leave the scar hidden in the anatomic creases. In particular, when the lesion is situated in the center of the nose and the defect left by surgery is more than 1.5 cm, our experience suggests that it is better to use the bilateral technique (modified crescentic flap) to minimize nasal distortion. Even if the defect is not so large, we think that the bilateral technique is preferable in order to create symmetrical scars providing better aesthetic results. Finally, even if the surgical scars were sometimes located in the midline of the dorsum of the nose or just adjacent to it, according to the localizations of the tumours, the aesthetic outcome was completely satisfactory both for patients and for surgeons.

## Conflict of interest

None to declare.

## References

- Brodland DG, Zitelli JA: Surgical margins for excision of primary cutaneous squamous cell carcinoma. *J Am Acad Dermatol* 27(21): 241–248, 1992
- Burget GC, Menick FJ: The subunit principle in nasal reconstruction. *Plast Reconstr Surg* 76: 239–247, 1985
- Fleming ID, Amonette R, Monaghan T: Principles of management of basal and squamous cell carcinoma of the skin. *Cancer* 75(Suppl. 2): 699–704, 1995
- Hoasjoe DK, Stucker FJ, Aarstad RE: Aesthetic and anatomic considerations for nasal reconstruction. *Facial Plast Surg* 10(4): 317–321, 1994
- Huang CC, Boyce SM: Surgical margins of excision for basal cell carcinoma and squamous cell carcinoma. *Semin Cutan Med Surg* 23(3): 167–173, 2004
- Kallini JR, Hamed N, Khachemoune A: Squamous cell carcinoma of the skin: epidemiology, classification, management, and novel trends. *Int J Dermatol* 54(2): 130–140, 2015
- Kim YJ, Cho HH, Kim SO, Lee JB, Lee SC: Reconstruction algorithm for nasal basal cell carcinoma with skin involvement only: analysis of 221 cases repaired by minor surgery. *Clin Exp Dermatol*. <http://dx.doi.org/10.1111/ced.12676>, 2015 [Epub ahead of print]
- Longo C, Lallas A, Kyrgidis A, Rabinovitz H, Moscarella E, Ciardo S, et al: Classifying distinct basal cell carcinoma subtype by means of dermatoscopy and reflectance confocal microscopy. *J Am Acad Dermatol* 71(4): 716–724, 2014
- Salgarelli AC, Bellini P, Multinu A, Magnoni C, Francomano M, Fantini F, et al: Reconstruction of nasal skin cancer defects with local flaps. *J Skin Cancer*: 181093, 2011
- Salgarelli AC, Cangiano A, Sartorelli F, Bellini P, Collini M: The bilobed flap in skin cancer of the face: our experience on 285 cases. *J Craniomaxillofac Surg* 38(6): 460–464, 2010

- Salgarelli AC, Cella L, Ladisa R, Carminati R: Modify lateral flap for nasal tip reconstruction. *Rivista italiana di chirurgia maxilla-facciale* 6: 53–57, 2000
- Silverstone H, Gordon D: Regional studies in skin cancer 2. Wet tropical and subtropical coasts of Queensland. *Med J Aust* 2: 733–740, 1996
- Smadja J: Nasojugal advancement rotation flap for reconstruction of median and paramedian defects of the nasal tip. *Int Soc Dermatol Surg*, 2002
- Smadja J: Crescentic nasojugal flap for nasal tip reconstruction. *Dermatol Surg* 33: 76–81, 2007
- Snow S, Mohs FE, Olansky DC: Nasal tip reconstruction. The horizontal 'J' rotation flap using skin from the lower lateral bridge and cheek. *J Dermatol Surg Oncol* 16(8): 727–732, 1990
- Wheatley MJ, Smith JK, Cohen IA: A new flap for nasal tip reconstruction. *Plast Reconstr Surg* 99: 220–224, 1997
- Wolf DJ, Zitelli JA: Surgical margins for basal cell carcinoma. *Arch Dermatol* 123(3): 340–344, 1987
- Xue CY, Li L, Guo LL, Li JH, Zhang ML, Xing X: The axial frontonasal flap for reconstruction of large nasal-tip defects based on modified nasal subunits in East Asians. *Clin Exp Dermatol* 34: 426–428, 2009
- Yoo SS, Miller SJ: The crescentic advancement flap revisited. *Dermatol Surg* 29(8): 856–858, 2003
- Zitelli JA: The bilobed flap for nasal reconstruction. *Arch Dermatol* 125(7): 957–959, 1989
- Zitelli JA: The nasolabial flap as a single-stage procedure. *Arch Dermatol* 126(11): 1445–1448, 1990
- Zitelli JA, Fazio MJ: Reconstruction of the nose with local flaps. *J Dermatol Surg Oncol* 17(2): 184–189, 1991