



Open Access

ORIGINAL ARTICLE

Male Fertility

Testicular ultrasound inhomogeneity is an informative parameter for fertility evaluation

Giorgia Spaggiari^{1,2}, Antonio R M Granata², Daniele Santi^{1,2}

Testicular volume (TV) is proposed to be a positive predictor of male fertility status, because of the relation known between the TV and the seminiferous tubule content. Independently of the measurement methodology, the role of TV and testicular ultrasound (US) assessments is still debated in andrological clinical practice. In this retrospective cohort study, we evaluated TV and testis US role in the diagnostic workup of andrological patients. All consecutive outpatients undergoing single-operator testis US (Modena, Italy) from March 2012 to March 2018 were enrolled, matching sonographic, hormonal, and seminal data. A total of 302 men were referred and evaluated for gynecomastia, suspected hypogonadism, couple infertility (CI), or sexual dysfunction. In the hypogonadal group, TV was lower compared to that in other groups ($P < 0.001$), and a significant, direct correlation between TV and testosterone level was observed in nonandrogen-treated patients ($R = 0.911$, $P < 0.001$), suggesting that testicular size could be related to the testosterone-secreting compartment. In the CI group, normozoospermic patients showed higher TV compared to men with impaired semen quality ($P = 0.003$) and azoospermia ($P = 0.003$). However, TV was not able to discriminate between patients presenting normal and altered semen quality. On the contrary, testis US inhomogeneity was more frequent in patients with impaired sperm quality (55.0%; $P = 0.007$) and azoospermia (40.0%; $P = 0.012$), compared to patients with normozoospermia (5%), identifying thereby the sonographic pattern as an informative parameter of the fertility status. Therefore, in the CI workup, US evaluation seems to be more informative than the TV assessment alone.

Asian Journal of Andrology (2019) 21, 1–7; doi: 10.4103/aja.aja_67_19; published online: 2 July 2019

Keywords: male hypogonadism; male infertility; testicular diseases; testis

INTRODUCTION

Physical examination of external genitalia is one of the most important steps in the workup of patients undergoing andrological evaluation for any reason. In particular, the assessment of testicular volume (TV), tone, and consistency provides indirect information about both spermatogenic and hormonal compartment, guiding the subsequent diagnostic and therapeutic choices.¹ In clinical practice, TV is measured using Prader's orchidometer, which provides overestimation of testicular size compared to ultrasound (US) assessment.^{2–5} Although testis US represents the most reliable and accurate tool to evaluate TV, a strict and direct correlation between US and Prader's orchidometer in volume measurements was demonstrated,^{4,5} justifying the use of orchidometer-derived TV in the clinical setting.⁵

Independently of the method used, an accepted consensus about TV reference ranges has not been reached so far and different values have been proposed, depending on ethnic, environmental, and geographical factors.^{5,6} Considering the cumulative volume of the right and the left testes, the suggested cutoff of normality is ≥ 30 ml by orchidometer evaluation or ≥ 20 ml by US.⁷ Considering individual testis, the TV should be >14 – 15 ml by orchidometer or ≥ 11 – 12 ml by US.⁸

The TV relevance is due to its relationship with testicular spermatogenic and steroidogenic capabilities.⁷ Since the intratesticular

number of seminiferous tubules contributes to about 80% of TV, this parameter is considered to be particularly informative of the fertility status.^{9,10} Indeed, TV reduction seems to be a clinical sign of both impaired semen quality (oligo- and/or astheno- and/or teratozoospermia, detected by conventional semen analysis) and hypogonadism.^{11–13} Recently, a logistic regression-based nomogram was proposed to predict hypogonadism in infertile men, based on data derived from physical examination, such as TV and body mass index, and on the seminal finding of azoospermia.¹⁴ This mathematical approach is able to predict andrological diseases with 68% of accuracy, limiting its application in clinical practice.^{14,15} In general, the real predictive significance of TV for the andrological workup remains unclear, considering the absence of validated cutoffs being able to predict testicular function in relation to TV.

Testis US assessment is recommended in the flowchart of the infertile male, according to the most recent guidelines.^{16,17} Alongside TV measurement, the added value of the sonographic evaluation is given by the possibility to accurately examine the testicular structure. Testicular US echogenicity increases during testis maturation and the US appearance of the normal testis mimics the homogenous structure of the normal thyroid gland.¹⁸ However, the testis US structure evaluation is an operator-dependent variable⁵ and inhomogeneity is defined as the absence of the uniform structure otherwise

¹Unit of Endocrinology, Department of Biomedical, Metabolic and Neural Sciences, University of Modena and Reggio Emilia, Modena 41126, Italy; ²Unit of Endocrinology, Department of Medical Specialties, Azienda Ospedaliero-Universitaria of Modena, Ospedale Civile di Baggiovara, Modena 41126, Italy.

Correspondence: Dr. D Santi (daniele.santi@unimore.it)

Received: 10 September 2018; Accepted: 26 March 2019

characterizing normal testicular parenchyma. A 5-point grade scale was proposed to quantify testis US inhomogeneity.^{11,19} However, an accepted validation of this method does not exist so far. Similarly, the predictive value of the US detection of microlithiasis is still debated, since data about its relationship with male infertility and testicular malignancy are contradictory.^{20–24} In such cases, a tailored follow-up of the patients is recommended, considering the presence of further risk factors.²⁵ The current clinical guidelines shifted the predictive accuracy of microlithiasis from cancer detection to nonspecific structure alterations, which should be monitored over years.

With this in mind, TV and testicular US assessment could play a fundamental role in the diagnostic flowchart of male infertility. The aim of the present study was to retrospectively evaluate the role of testis US in the diagnostic workup of andrological patients, with a special focus on male infertility.

PATIENTS AND METHODS

A retrospective observational cohort study was carried out, including 302 patients consequently undergoing US andrological examination by a single operator from March 2012 to March 2018 at the Andrology Unit of the Department of Biomedical, Metabolic and Neural Sciences of the University of Modena and Reggio Emilia (Modena, Italy). All clinical conditions leading to andrological consultation were considered eligible. Patients were clinically evaluated considering the reason for referral, and proper diagnostic flowcharts were applied, according to clinical guidelines, recommendations, and suggestions approved by scientific societies.^{15,16,26–28} Patients referred for testicular pain or infections were excluded from the analysis. The following reasons for referral were considered separately: gynecomastia (Group 1), suspected hypogonadism (Group 2), couple infertility (Group 3), and sexual dysfunctions (Group 4). The patients' subgrouping was not performed according to the final diagnosis, but the initial clinical request. Thus, the clinical approach was slightly different for each patient, based on the hypothesized andrological problem. However, in all four groups, the following initial workup was performed: (1) personal and familial history collection, with particular attention to possible risk factors for andrological diseases and to ongoing therapies, (2) physical and andrological examination, (3) blood examination, (4) testicular US, and (5) conventional semen analysis in those patients searching fatherhood. All patients undergoing testicular US were included in the study. No further inclusion or exclusion criteria were provided. A dataset was created and US data were connected to the parameters collected during the diagnostic workup. Hormonal evaluations were performed in all patients, whereas only men presenting for untreated hypogonadism looking for fatherhood and men presenting for infertility (part of Group 2 and all the Group 3) underwent conventional semen analysis.

All examinations were approved by the Azienda Ospedaliero-Universitaria of Modena, Ospedale Civile of Baggiovara, Hospital management (Modena, Italy), which is the Ethic Committee internal to the Hospital, and all patients provided informed consent to participate.

Testicular ultrasound

Testicular US scan was performed by a single operator using a single machine (Esaote® My Lab25 Gold, Malmesbury, Wiltshire, UK). The US operator was blind to the seminal and hormonal status of each patient, since the US examination was performed during the first visit, before biochemical and semen analyses. The following testicular characteristics were evaluated by US and collected in the dataset: TV, parenchyma homogeneity/inhomogeneity, pampiniform plexus, epididymis, and proximal vas deferens.⁵

Axial and longitudinal scans allowed to obtain depth, transverse, and longitudinal diameter of each testis. TV was calculated using the ellipsoid formula: length (cm) × width (cm) × depth (cm) × 0.71. Although not definitely validated, we used this mathematical formula since its superiority in the prediction of real TV was described.¹³

Parenchyma homogeneity/inhomogeneity is an operator-dependent nonobjective parameter. In 1993, Lenz *et al.*¹¹ proposed a 5-grade scale classification of testis inhomogeneity, but in clinical practice, the parenchymal echostructure is heterogeneously reported. Thus, we chose to classify testis US echostructure into only three different categories: Type 1, testicular homogeneity; Type 2, testicular inhomogeneity; Type 3, suspected tumor (Figure 1).

The pampiniform plexus was evaluated during US, and the presence of varicocele was detected both in resting conditions and after Valsalva maneuver. When present, varicocele was graded according to the “Sarteschi” 5-item scale (Supplementary Table 1).²⁹

Considering epididymis, the head was detected at the upper pole of the testis and measured in a longitudinal scan from the top to the base of the triangle.⁵ Epididymis body and tail were detected posteriorly to the testis and measured considering the anterior–posterior diameters.⁵

The vas deferens was searched as a straight duct, slightly hypoechoic compared with the epididymis, originating from the epididymal tail.⁵

Blood examination

After a fasting blood sample in the morning (8:00 a.m.), the following hormonal measurements were performed in all patients: total testosterone, luteinizing hormone (LH), follicle-stimulating hormone (FSH), and prolactin serum levels. Serum total testosterone levels were measured by Chemiluminescent Microparticle Immunoassay (Architect, Abbott, Dundee, UK), with inter- and intra-assay coefficients of variation (CV) of 5.2% and 5.1%, respectively. The blood samples were collected approximately 3 h after the gel application in case of hypogonadal patients under transdermal replacement therapy and 1 week before the subsequent injection in case of hypogonadal patients treated with testosterone undecanoate. FSH and LH were measured by Chemiluminescent Microparticle Immunoassay (Architect, Abbott,

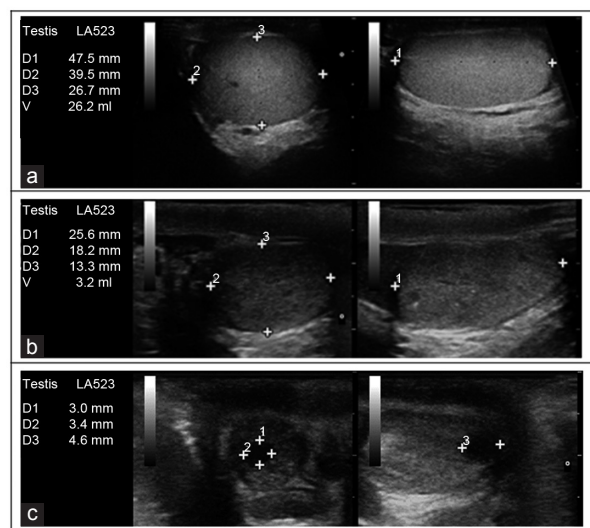


Figure 1: Testicular ultrasound parenchymal classification. (a) Testis with homogeneous isoechoic echo pattern (Type 1 homogeneity). (b) Testis with Type 2 inhomogeneous hypoechoic echo pattern and diffuse hyperechoic spots. (c) Testis with Type 3 inhomogeneity (lesion suspected for malignancy). Numbers (1, 2 and 3) represent the three diameters taken during US evaluation. US: ultrasound; D: diameter; V: volume.

Longford, Ireland) with inter- and intra-assay CV of 4.1% and 3.1% for LH, and 4.6% and 4.2% for FSH, respectively. Prolactin was evaluated by Chemiluminescent Immunoassay (Beckman Coulter, Brea, CA, USA) with inter- and intra-assay CV of 4.2% and 1.6%, respectively.

Semen analysis

Conventional semen analyses were requested and reported for all men seeking andrological consultation for both untreated hypogonadism and couple infertility. Semen samples were collected after an abstinence period of 3–7 days, and analysis was performed according to the WHO criteria.³⁰

Statistical analyses

Patients were first divided into four groups, according to the reason for referral. TV was considered both as single and combined TV. Moreover, patients seeking andrological consultation for hypogonadism were further divided into two subgroups, treated and untreated, depending on whether the patients were or were not on androgen replacement therapy when enrolled in the study. Men seeking andrological consultation for couple infertility were further subdivided according to the seminal status in normozoospermic (when all semen parameters were above the normal range), with reduced sperm quality (when oligo- and/or astheno- and/or teratozoospermia were detected), and azoospermic patients.

Data distribution was evaluated using Kolmogorov–Smirnov test. Differences among groups and subgroups were evaluated using ANOVA univariate analysis when the data were normally distributed and using Kruskal–Wallis/Mann–Whitney U test when nonnormally distributed. Dunnett's test was used for *post hoc* analyses, choosing unequal variances. Differences among categorical variables were evaluated by Fisher's exact test or Kendall's test, considering the number of categories to be compared. These analyses were first performed considering the entire cohort of patients and then considering each group of patients separately. Moreover, after subgrouping, correlations among continuous variables were evaluated using Pearson and Spearman Rho coefficients, for normal and abnormal distributed parameters, respectively.

Finally, multivariate analyses were performed in order to identify those parameters which could predict TV variations. Thus, multiple linear pairwise regression analyses were performed in each group and in further subgroups, using TV as a dependent variable and hormonal and semen parameters as independent variables.

Statistical analysis was performed using the “Statistical Package for the Social Sciences” software for Macintosh (version 20.0; SPSS Inc., Chicago, IL, USA). For all comparisons, $P < 0.05$ was considered statistically significant.

RESULTS

Three hundred and two men were enrolled, with a mean age of 39.8 (standard deviation [s.d]: 15.2) years. Considering the reason for andrological consultation, patients were divided into Group 1 (37 patients, 12.3%), Group 2 (101 patients, 33.4%), Group 3 (118 patients, 39.1%), and Group 4 (46 patients, 15.2%) (Table 1). The

mean age was different among groups ($P < 0.001$), and *post hoc* analysis showed that Group 4 was older than the other groups ($P < 0.001$).

Right and left TVs were directly related together ($R = 0.868$, $P < 0.001$), justifying the evaluation of a single testis TV for the overall volume consideration. TV was significantly different among groups (Table 1 and Figure 2). *Post hoc* analyses showed that TV was lower in Group 2 compared to that of the other groups ($P < 0.001$, Figure 2). On the contrary, TV was not significantly different among Groups 1, 3, and 4 (Figure 2), confirming that men referring for hypogonadism generally present smaller testes.

Testicular US inhomogeneity (Type 2) was more frequent in Group 2 (53.9%) compared to that in the other groups ($P < 0.001$), and in Group 3 (37.8%) compared to that in both Groups 1 (9.8%) and 4 (10.8%) ($P < 0.001$) (Figure 3). Moreover, Type 2 inhomogeneity was more frequent in Group 2 than in Group 3 ($P < 0.001$, Figure 3). No tumor (Type 3 inhomogeneity) was suspected in our cohort. The detection of microlithiasis was not different among groups ($P = 0.115$). In particular, the frequency of microlithiasis was 14.9% in Group 2 (15 patients), 5.1% in Group 3 (6 patients), and 10.9% in Group 4 (5 patients). On the contrary, no microlithiasis was detected in Group 1. Similarly, macrocalcifications were detected in 2.7% of Group 1 (1 patient), 4.0% of Group 2 (4 patients), and 2.2% of Group 4 (1 patient), without significant differences ($P = 0.211$). TV was lower comparing patients with and without microlithiasis (right: 7.46 ± 6.93 ml vs 12.15 ± 8.22 ml, $P = 0.003$; left: 7.02 ± 6.59 ml vs 12.12 ± 7.89 ml, $P = 0.001$). However, this difference was lost within each group (Group 2: $P = 0.081$; Group 3: $P = 0.262$; and Group 4: $P = 0.979$). Patients with US Type 2 inhomogeneity showed a reduced TV compared to those with US homogeneity (right: 7.83 ± 7.66 ml vs 14.41 ± 7.53 ml, $P < 0.001$; left: 7.61 ± 7.81 ml vs 13.87 ± 7.06 ml, $P < 0.001$). This difference was also present in Group 1 ($P = 0.001$ and $P < 0.001$, respectively) and 2 ($P < 0.001$ for both testes). Epididymis head, corpus, and cauda diameters ($P = 0.076$, $P = 0.078$, and $P = 0.182$, respectively), as well as the incidence of varicocele ($P = 0.410$), did not differ among groups.

Although serum total testosterone levels were not different ($P = 0.535$) among groups, LH ($P = 0.003$) and FSH ($P = 0.006$) showed

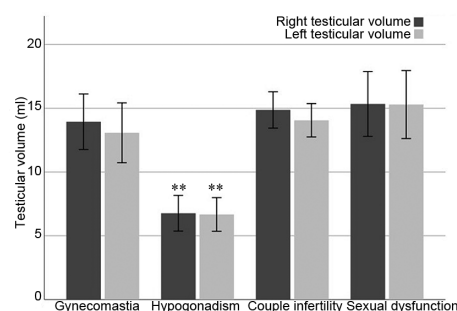


Figure 2: Right and left TV among groups. ** $P < 0.001$, the hypogonadism group compared with other three groups. TV: testicular volume.

Table 1: Patients' characteristics

Parameters	Entire cohort	Group 1 (gynecomastia)	Group 2 (suspected hypogonadism)	Group 3 (couple infertility)	Group 4 (sexual dysfunction)	P (Kruskal–Wallis)
Patients (n)	302	37	101	118	46	
Age (year), mean±s.d.	39.75±15.24	38.41±25.09	38.91±16.43	37.11±7.05	49.71±14.03	<0.001
Right testicular volume (ml), mean±s.d.	11.62±7.88	13.07±7.03	6.70±6.35	13.83±6.80	15.29±9.03	<0.001
Left testicular volume (ml), mean±s.d.	12.15±8.22	13.94±6.53	6.74±6.70	14.96±7.45	15.33±8.62	<0.001

s.d.: standard deviation

a different distribution, with higher serum gonadotropin levels in men seeking consultation for couple infertility (10.16 ± 11.15 IU⁻¹ and 16.41 ± 19.57 IU⁻¹, respectively). Prolactin did not differ among groups ($P = 0.478$).

Considering conventional semen analysis, no differences were observed between Groups 2 and 3 in terms of total sperm number ($P = 0.344$). On the contrary, sperm motility was lower in Group 2 ($5.94\% \pm 13.85\%$) compared to Group 3 ($25.09\% \pm 24.75\%$) ($P = 0.016$).

Men seeking andrological consultation for hypogonadism

At the time of the first visit, 30 men (29.7% of Group 2) were on androgen replacement therapy, whereas none of the patients were on gonadotropin treatment. The mean age was higher in the treated subgroup compared to that in the untreated one ($P = 0.009$) (Table 2).

TV was lower in men treated with androgen replacement therapy, compared to untreated patients ($P = 0.006$, Table 2). The prevalence of testicular US inhomogeneity did not differ between treated and untreated patients ($P = 0.199$), as well as the occurrence of testicular microcalcifications ($P = 0.221$). Neither epididymis head, corpus, and cauda diameter ($P = 0.913$, $P = 0.219$, and $P = 0.702$, respectively) nor the incidence of varicocele differed between groups ($P = 0.707$).

Serum total testosterone levels were higher in men undergoing androgen replacement therapy compared to those untreated ($P = 0.025$, Table 2). On the contrary, no differences were observed between treated and untreated men in terms of LH ($P = 0.465$), FSH ($P = 0.517$), and prolactin ($P = 0.644$) (Table 2).

Considering the whole group of hypogonadal men, TV was not correlated to hormonal variables (testosterone: $R = 0.155$, $P = 0.147$; LH: $R = -0.196$, $P = 0.202$; FSH: $R = -0.255$, $P = 0.083$; and prolactin: $R = -0.099$, $P = 0.622$). Similarly, no correlation with TV was found

in men treated with androgen replacement therapy (testosterone: $R = -0.122$, $P = 0.536$; LH: $R = -0.056$, $P = 0.849$; FSH: $R = -0.078$, $P = 0.769$; and prolactin: $R = -0.355$, $P = 0.557$). On the contrary, in untreated patients, a significant, direct correlation between serum total testosterone levels and TV was detected ($R = 0.370$, $P = 0.003$). Moreover, in this subgroup, FSH was directly related to TV ($R = 0.361$, $P = 0.014$), differently from LH ($R = 0.274$, $P = 0.075$).

TV was directly correlated to both total sperm number ($R = 0.806$, $P < 0.001$) and sperm motility ($R = 0.477$, $P = 0.046$). However, this information was only available for hypogonadal, untreated men, since conventional semen analyses were not available for men undergoing androgen replacement therapy.

Men seeking andrological consultation for couple infertility

Men seeking andrological consultation for couple infertility were divided into normozoospermic (30 patients, 25.4%), impaired semen quality (58 patients, 49.2%), and azoospermic (30 patients, 25.4%). The mean age among subgroups was not different ($P = 0.625$), whereas TV resulted in higher values in normozoospermic patients compared to the other groups ($P = 0.014$) (Table 3). Conversely, there were no TV differences between men with reduced sperm quality and azoospermic patients ($P = 0.714$). Testis US inhomogeneity (Type 2) was more frequent in patients with reduced sperm quality (54.9%) ($P = 0.007$), compared to azoospermic (44.1%) and normozoospermic (5.0%) men. Moreover, Type 2 inhomogeneity was more frequent in azoospermic than that in normozoospermic patients ($P = 0.012$). The US finding of microcalcifications did not differ ($P = 0.090$). Neither epididymis head, corpus, and cauda diameters ($P = 0.991$, $P = 0.108$, and $P = 0.312$, respectively) nor the incidence of varicocele differed among groups ($P = 0.103$).

Serum total testosterone levels, LH, and prolactin did not differ among subgroups (Table 3), whereas FSH levels were different ($P = 0.004$). *Post hoc* test showed higher serum FSH levels in azoospermic patients compared to those in the other two groups ($P = 0.006$), whereas no differences were detected between normozoospermic patients and those with reduced sperm quality.

Considering the entire group of men seeking andrological consultation for infertility, an indirect correlation was detected between TV and LH ($R = -0.449$, $P < 0.001$), FSH ($R = -0.435$, $P < 0.001$), and prolactin ($R = -0.389$, $P < 0.001$). On the contrary, a significant, direct correlation was detected between TV and both total sperm count ($R = 0.480$, $P < 0.001$) and sperm motility ($R = 0.443$, $P < 0.001$). Subdividing patients according to the seminal status, significant correlations were confirmed in normozoospermic patients. In particular, significant inverse correlations between TV and LH ($R = -0.400$,

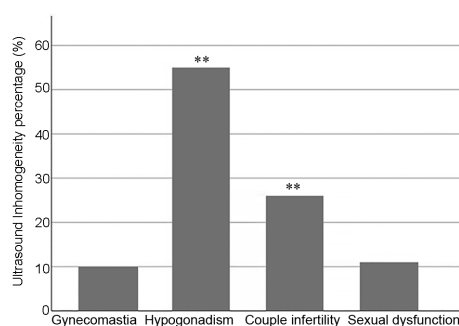


Figure 3: Percentage of ultrasound Type 2 inhomogeneity detection among different groups. ** $P < 0.001$, the hypogonadism group compared with group of patients with gynecomastia and sexual dysfunction.

Table 2: Men seeking andrological consultation for suspected hypogonadism (Group 2)

Parameters	Entire group	Treated men	Untreated men	P (Mann-Whitney U test)
Patients (n)	101	30	71	NA
Age (year), mean \pm s.d.	38.91 \pm 16.43	45.42 \pm 16.51	36.16 \pm 15.71	0.009
Right testicular volume (ml), mean \pm s.d.	6.70 \pm 6.35	3.83 \pm 4.00	7.94 \pm 3.84	0.006
Left testicular volume (ml), mean \pm s.d.	6.74 \pm 6.70	3.90 \pm 3.22	7.81 \pm 3.90	0.006
Total testosterone (ng dl ⁻¹), mean \pm s.d.	482.83 \pm 309.40	586.60 \pm 335.19	434.19 \pm 286.47	0.025
LH (IU l ⁻¹), mean \pm s.d.	10.17 \pm 11.15	9.36 \pm 13.21	10.34 \pm 11.20	0.465
FSH (IU l ⁻¹), mean \pm s.d.	16.41 \pm 19.57	13.14 \pm 20.72	16.67 \pm 19.69	0.517
Prolactin (ng dl ⁻¹), mean \pm s.d.	26.68 \pm 55.87	11.30 \pm 8.10	24.10 \pm 17.87	0.644
Total sperm count (10 ⁶ per ejaculate), mean \pm s.d.	18.14 \pm 50.28	NA	18.14 \pm 50.28	NA
Sperm motility (%), mean \pm s.d.	5.94 \pm 13.85	NA	5.94 \pm 13.85	NA

NA: not available; s.d.: standard deviation

Table 3: Men seeking andrological consultation for couple infertility (Group 3)

Parameters	Entire group	Normozoospermia	Reduced sperm quality	Azoospermia	P (Kruskal-Wallis)
Patients (n)	118	30	58	30	NA
Age (year), mean±s.d.	37.11±7.05	35.36±7.52	37.76±8.94	34.39±10.22	0.625
Right testicular volume (ml), mean±s.d.	13.83±6.80	17.07±8.41	12.81±5.92	7.85±7.73	0.001
Left testicular volume (ml), mean±s.d.	14.96±7.45	17.04±6.43	12.04±5.71	6.27±5.71	0.001
Total testosterone (ng dl ⁻¹), mean±s.d.	535.38±231.14	523.37±247.33	498.12±178.68	469.56±230.47	0.348
LH (IU l ⁻¹), mean±s.d.	5.13±5.01	3.95±5.34	5.29±4.33	10.13±8.28	0.098
FSH (IU l ⁻¹), mean±s.d.	8.13±9.42	4.91±7.39	7.61±7.90	19.17±15.78	0.004
Prolactin (ng dl ⁻¹), mean±s.d.	10.53±13.98	8.91±3.00	11.39±4.35	11.25±4.84	0.136
Total sperm count (10 ⁶ per ejaculate), mean±s.d.	33.24±25.70	200.98±182.18	28.17±35.06	0	<0.001
Sperm motility (%), mean±s.d.	25.09±24.75	51.09±35.22	23.26±19.08	0	<0.001

s.d.: standard deviation; FSH: follicle-stimulating hormone; LH: luteinizing hormone; NA: not available

$P = 0.031$), FSH ($R = -0.350$, $P = 0.018$), and prolactin ($R = -0.456$, $P = 0.022$) were detected, whereas a significant, direct correlation between TV and sperm count ($R = 0.577$, $P = 0.010$) was found. In men with reduced sperm quality and azoospermia, no correlation was found.

Multivariate analyses

Multivariate linear analyses were performed considering TV as a dependent variable and hormonal and semen analyses as independent, pairwise parameters in each group of patients. No significant models were generated for men seeking andrological consultations for gynecomastia, hypogonadism, and sexual dysfunction (Groups 1, 2, and 4). In Group 3, a significant model was generated in which total sperm count and serum FSH levels entered ($R 10.735$, $P < 0.001$). This result suggests that TV in this category of patients could be better predicted by the two variables, total sperm count and serum FSH levels. This result was lost repeating the analyses for subgroups of patients according to semen quality, probably due to the reduced number of patients after further grouping.

DISCUSSION

In this study, testicular sonographic data collected during andrological consultation show that US-derived TV is lower in hypogonadal patients compared to other conditions. Indeed, hypogonadal men generally show impairment of both testosterone-secreting and spermatogenic compartments. Accordingly, TV is directly related to serum testosterone and FSH levels, as well as to sperm number and motility in such patients. However, the impact of the testosterone-secreting compartment on TV seems to be particularly relevant, considering the difference detected between hypogonadal patients and patients evaluated for infertility. In particular, in hypogonadal patients, TV seems to be informative of both spermatogenic function and the androgen-secreting compartment.

As expected, within the group of hypogonadal men, testicular sizes result lower in androgen-treated patients compared to untreated men, confirming that the exogenous administration of testosterone could impact TV. As demonstrated both in humans and in animal models, this effect is due to the testosterone-mediated suppression of the gonadotropin pulsatile secretion, which acts as a trophic factor on the testicular tissue.^{31,32} No further significant differences were found between androgen-treated and untreated patients concerning both the hormonal pattern and the testicular ultrasound features, with the exception of testosterone levels resulting in higher levels in testosterone-treated patients. Although several authors suggested a relationship between TV and the presence of microlithiasis,³³ we do not find a correlation between these two parameters.

In patients evaluated for infertility, TV does not appear informative of the fertility status, since it cannot discriminate the degree of

alteration in semen quality, from a mild decline (oligo- and/or astheno- and/or teratozoospermia) to azoospermia. On the contrary, gonadotropin levels are higher in men presenting for infertility compared to those in other andrological patients, identifying LH and FSH as informative markers of male fertility status. In particular, FSH levels are increased in azoospermic patients, whereas no LH and FSH differences between normozoospermic men and patients with impaired semen quality are detected. This finding could be due to our choice to evaluate the alterations in semen quality irrespective of the parameter involved (sperm count and/or motility and/or morphology), the alterations degree, and the presence of combined sperm abnormalities. In men seeking andrological consultation for couple infertility, multivariate analyses develop a model in which FSH levels and sperm number are identified as the most relevant variables to predict TV. Hence, TV could be interpreted both as a consequence of a FSH-mediated effect and a parameter of spermatogenic function.³⁴⁻³⁶ The model developed, interconnecting TV, FSH, and sperm number, could add rationale to the therapeutic use of FSH, which is currently proposed on an empirical base for improving sperm quality in men affected by idiopathic infertility.³⁷ Nevertheless, subdividing patients according to their seminal status, correlations are only confirmed when normozoospermia occurs. This result could be simply due to the low patient number impacting the statistical power. However, other pathophysiological phenomena, not evaluable by simple hormonal and sonographic assessments, could be involved, e.g., at testicular histology level. Indeed, TV and FSH levels were proposed in direct and indirect correlation with histological structure detected by testis biopsy,³⁸ respectively; TV and FSH levels were also proposed in direct and indirect correlation with the prediction of successful testicular sperm extraction.^{39,40}

Testicular echostructure evaluation highlights an increased frequency in US inhomogeneity in Group 2 and Group 3 compared to the other groups. Thus, US inhomogeneity seems to better characterize hypogonadism and infertility,^{41,42} rather than other andrological conditions. The testicular parenchyma alteration seems to be an informative marker of testicular function, including both testosterone production and the spermatogenic compartment. Due to the difficulty to categorize the testis US echostructure and to objectify an operator-dependent parameter, we chose to evaluate a dichotomous variable (presence/absence of a characteristic). This classification is easily applicable in the clinical practice and able to provide useful information about the testicular functionality, at least in our population. An inhomogeneous echo pattern does not add relevant information in the setting of male hypogonadism; on the contrary, it seems extremely useful in infertility workup, in which the frequency of testis US

inhomogeneity is higher in patients with semen alterations compared to normozoospermia, allowing the identification of pathological conditions, although the severity of the impaired semen quality cannot be discriminated. Thus, a correlation between sonographic alterations and “impaired” function could be suggested. Indeed, US inhomogeneity (Type 2) is related to a reduced TV in the entire cohort, confirming the role of both parameters in testicular function evaluation.

Given its retrospective design, the major limitation of this study consists in the heterogeneity of the patients’ management, which was chosen according to the reason for referral. According to clinical practice, the investigations performed in each patient are consistent with andrological guidelines/recommendations, and, consequently, hormonal and seminal parameters are not available for all patients. Although the entire cohort of US-evaluated patients is representative of a single-operator practice, the relative low sample size due to further subgrouping represents another limitation of the study, together with the absence of a structured control group. The limited number of patients prevents calculation of reliable accuracy measures, such as sensitivity and specificity. However, since all US exams were performed by a single andrologist, skilled in testicular US diagnostics, sonographic data do not suffer from interoperator variability. Moreover, the analysis of data deriving from the common clinical practice documents the feasible application of these evaluations in the real medical life.

CONCLUSION

Our cohort study evaluates the testis US application in the andrological setting and the results suggest that testis US inhomogeneity is informative of a comprehensive testicular dysfunction. Indeed, testicular inhomogeneity is highly frequent in both hypogonadal and fertility-evaluated patients. Moreover, in infertile patients, testis US inhomogeneity discriminates between normozoospermia and impaired semen quality. Finally, gonadotropin levels are confirmed as highly informative in male infertility management, showing higher serum levels in men seeking medical consultation for couple infertility compared to other groups. Despite this potential US application, the systematic use of testis US in andrology is still debated. Our data suggest a novel, relevant aspect of testis US in the andrological practice, in particular in the male infertility workup. In this setting, a simple, dichotomous, reproducible, approachable, and minimally operator-dependent parameter such as echostructure inhomogeneity could be an effective marker of male fertility status. Although our results need further confirmation in larger, prospective populations, the testicular sonographic assessment seems to provide more information about the spermatogenic function compared to the measure of testicular sizes.

AUTHOR CONTRIBUTIONS

GS collected and analyzed the data and wrote the manuscript. ARMG collected the data and revised the manuscript. DS conceived of the study, collected and analyzed the data, and wrote the manuscript. All authors edited the manuscript or revised it critically for important intellectual content. All authors read and approved the final manuscript.

COMPETING INTERESTS

All authors declared no competing interests.

ACKNOWLEDGMENTS

All authors are grateful to Prof. Manuela Simoni for her support and advice for the conduction of this study.

Supplementary Information is linked to the online version of the paper on the *Asian Journal of Andrology* website.

REFERENCES

- Jarow JP. Diagnostic approach to the infertile male patient. *Endocrinol Metab Clin North Am* 2007; 36: 297–311.
- Behre HM, Nishan D, Nieschlag E. Objective measurement of testicular volume by ultrasonography: evaluation of the technique and comparison with orchidometer estimates. *Int J Androl* 1989; 12: 395–403.
- Diamond DA, Paltiel HJ, DiCanzio J, Zurakowski D, Bauer SB, *et al*. Comparative assessment of pediatric testicular volume: orchidometer versus ultrasound. *J Urol* 2000; 164: 1111–4.
- Goede J, Hack WW, Sijstermans K, van der Voort-Doedens LM, Van der Ploeg T, *et al*. Normative values for testicular volume measured by ultrasonography in a normal population from infancy to adolescence. *Horm Res Paediatr* 2011; 76: 56–64.
- Lotti F, Maggi M. Ultrasound of the male genital tract in relation to male reproductive health. *Hum Reprod Update* 2015; 21: 56–83.
- Nieschlag E, Behre HM, Nieschlag S. *Andrology: Male Reproductive Health and Dysfunction*. Heidelberg: Springer; 2009. p629.
- Ruiz-Olvera SF, Rajmil O, Sanchez-Curbelo JR, Vinay J, Rodriguez-Espinosa J, *et al*. Association of serum testosterone levels and testicular volume in adult patients. *Andrologia* 2018; 50: e12933.
- Condorelli R, Calogero AE, La Vignera S. Relationship between testicular volume and conventional or nonconventional sperm parameters. *Int J Endocrinol* 2013; 2013: 145792.
- Forti G, Krausz C. Clinical review 100: evaluation and treatment of the infertile couple. *J Clin Endocrinol Metab* 1998; 83: 4177–88.
- Sakamoto H, Ogawa Y. Does a clinical varicocele influence the relationship between testicular volume by ultrasound and testicular function in patients with infertility? *Fertil Steril* 2009; 92: 1632–7.
- Lenz S, Giwercman A, Elsborg A, Cohr KH, Jelnes JE, *et al*. Ultrasonic testicular texture and size in 444 men from the general population: correlation to semen quality. *Eur Urol* 1993; 24: 231–8.
- Lenz S, Thomsen JK, Giwercman A, Hertel NT, Hertz J, *et al*. Ultrasonic texture and volume of testicles in infertile men. *Hum Reprod* 1994; 9: 878–81.
- Sakamoto H, Yajima T, Nagata M, Okumura T, Suzuki K, *et al*. Relationship between testicular size by ultrasonography and testicular function: measurement of testicular length, width, and depth in patients with infertility. *Int J Urol* 2008; 15: 529–33.
- Ventimiglia E, Capogrosso P, Boeri L, Ippolito S, Scano R, *et al*. Validation of the American society for reproductive medicine guidelines/recommendations in white European men presenting for couple's infertility. *Fertil Steril* 2016; 106: 1076–82.e1.
- Barratt CL, Bjorndahl L, De Jonge CJ, Lamb DJ, Osorio Martini F, *et al*. The diagnosis of male infertility: an analysis of the evidence to support the development of global WHO guidance-challenges and future research opportunities. *Hum Reprod Update* 2017; 23: 660–80.
- Jungwirth A, Giwercman A, Tournaye H, Diemer T, Kopa Z, *et al*. European Association of Urology guidelines on male infertility: the 2012 update. *Eur Urol* 2012; 62: 324–32.
- Dimitriadis F, Adonakis G, Kaponis A, Mamoulakis C, Takenaka A, *et al*. Pre-testicular, testicular, and post-testicular causes of male infertility. In: Simoni M, Huhtaniemi I, editors. *Endocrinology of the Testis and Male Reproduction*. Cham: Springer; 2017. p1364.
- Hamm B, Fobbe F. Maturation of the testis: ultrasound evaluation. *Ultrasound Med Biol* 1995; 21: 143–7.
- Westergaard LG, Erb K, Laursen SB, Rex S, Rasmussen PE. Human menopausal gonadotropin versus recombinant follicle-stimulating hormone in normogonadotropic women down-regulated with a gonadotropin-releasing hormone agonist who were undergoing *in vitro* fertilization and intracytoplasmic sperm injection: a prospective randomized study. *Fertil Steril* 2001; 76: 543–9.
- Miller FN, Sidhu PS. Does testicular microlithiasis matter? A review. *Clin Radiol* 2002; 57: 883–90.
- Yee WS, Kim YS, Kim SJ, Choi JB, Kim SI, *et al*. Testicular microlithiasis: prevalence and clinical significance in a population referred for scrotal ultrasonography. *Korean J Urol* 2011; 52: 172–7.
- Appelbaum L, Gaitini D, Dogra VS. Scrotal ultrasound in adults. *Semin Ultrasound CT MR* 2013; 34: 257–73.
- Elzinga-Tinke JE, Sirre ME, Looijenga LH, van Casteren N, Wildhagen MF, *et al*. The predictive value of testicular ultrasound abnormalities for carcinoma *in situ* of the testis in men at risk for testicular cancer. *Int J Androl* 2010; 33: 597–603.
- Richenberg J, Brejt N. Testicular microlithiasis: is there a need for surveillance in the absence of other risk factors? *Eur Radiol* 2012; 22: 2540–6.
- Albers P, Albrecht W, Algaba F, Bokemeyer C, Cohn-Cedermark G, *et al*. Guidelines on testicular cancer: 2015 update. *Eur Urol* 2015; 68: 1054–68.
- Hatzimouratidis K, Amar E, Eardley I, Giuliano F, Hatzichristou D, *et al*. Guidelines on male sexual dysfunction: erectile dysfunction and premature ejaculation. *Eur Urol* 2010; 57: 804–14.
- Shamsian N, Jones L, Ghosh S. Gynaecomastia: are surgical guidelines realistic? *BMJ* 2008; 336: 790.
- Seftel AD, Kathrins M, Niederberger C. Critical update of the 2010 Endocrine

- Society Clinical Practice Guidelines for male hypogonadism: a systematic analysis. *Mayo Clin Proc* 2015; 90: 1104–15.
- 29 Pauroso S, Di Leo N, Fulle I, Di Segni M, Alessi S, *et al*. Varicocele: ultrasonographic assessment in daily clinical practice. *J Ultrasound* 2011; 14: 199–204.
- 30 World Health Organization. WHO Laboratory Manual for the Examination and Processing of Human Semen. 5th ed. Geneva: World Health Organization; 2010.
- 31 Mann DR, Smith MM, Gould KG, Collins DC. Effect of a gonadotropin-releasing hormone agonist on luteinizing hormone and testosterone secretion and testicular histology in male rhesus monkeys. *Fertil Steril* 1985; 43: 115–21.
- 32 Nieschlag E, Vorona E. Mechanisms in endocrinology: medical consequences of doping with anabolic androgenic steroids: effects on reproductive functions. *Eur J Endocrinol* 2015; 173: R47–58.
- 33 Pedersen MR, Osther PJ, Rafaelsen SR. Ultrasound evaluation of testicular volume in patients with testicular microlithiasis. *Ultrasound Int Open* 2018; 4: e99–103.
- 34 Acosta AA, Oehninger S, Ertunc H, Philput C. Possible role of pure human follicle-stimulating hormone in the treatment of severe male-factor infertility by assisted reproduction: preliminary report. *Fertil Steril* 1991; 55: 1150–6.
- 35 Koskenniemi JJ, Virtanen HE, Toppari J. Testicular growth and development in puberty. *Curr Opin Endocrinol Diabetes Obes* 2017; 24: 215–24.
- 36 Tapanainen JS, Aittomaki K, Min J, Vaskivuo T, Huhtaniemi IT. Men homozygous for an inactivating mutation of the follicle-stimulating hormone (FSH) receptor gene present variable suppression of spermatogenesis and fertility. *Nat Genet* 1997; 15: 205–6.
- 37 Santi D, Granata AR, Simoni M. FSH treatment of male idiopathic infertility improves pregnancy rate: a meta-analysis. *Endocr Connect* 2015; 4: R46–58.
- 38 Gnessi L, Scarselli F, Minasi MG, Mariani S, Lubrano C, *et al*. Testicular histopathology, semen analysis and FSH, predictive value of sperm retrieval: supportive counseling in case of reoperation after testicular sperm extraction (TESE). *BMC Urol* 2018; 18: 63.
- 39 Karamazak S, Kizilay F, Bahceci T, Semerci B. Do body mass index, hormone profile and testicular volume effect sperm retrieval rates of microsurgical sperm extraction in the patients with nonobstructive azoospermia? *Turk J Urol* 2018; 44: 202–7.
- 40 Ramasamy R, Ricci JA, Leung RA, Schlegel PN. Successful repeat microdissection testicular sperm extraction in men with nonobstructive azoospermia. *J Urol* 2011; 185: 1027–31.
- 41 Fedder J. Prevalence of small testicular hyperechogenic foci in subgroups of 382 non-vasectomized, azoospermic men: a retrospective cohort study. *Andrology* 2017; 5: 248–55.
- 42 Ventimiglia E, Ippolito S, Capogrosso P, Pederzoli F, Cazzaniga W, *et al*. Primary, secondary and compensated hypogonadism: a novel risk stratification for infertile men. *Andrology* 2017; 5: 505–10.

This is an open access journal, and articles are distributed under the terms of the Creative Commons Attribution-NonCommercial-ShareAlike 4.0 License, which allows others to remix, tweak, and build upon the work non-commercially, as long as appropriate credit is given and the new creations are licensed under the identical terms.

©The Author(s)(2019)



Supplementary Table 1: "Sarteschi" 5-item scale for ultrasound grading of the varicocele

<i>Grade</i>	<i>Grade 1</i>	<i>Grade 2</i>	<i>Grade 3</i>	<i>Grade 4</i>	<i>Grade 5</i>
Presence of varicosities	No	Presence of small varicosities	Presence of overt varicosities	Evident varicosities in all positions	Evident venous dilatation in all positions
Testis hypotrophy	No	No	No	Usual	Yes
Venous reflux	During Valsalva maneuver	During Valsalva maneuver	Evident during Valsalva maneuver	Spontaneous, increased with Valsalva maneuver or standing station	Spontaneous at rest, not changed by Valsalva maneuver