





Proximal Splenic Artery Embolization to Treat Refractory Ascites in a Patient With Cirrhosis

Cristian Caporali,^{1*} Laura Turco,^{2*} Francesco Prampolini,¹ Pietro Quaretti,³ Marcello Bianchini,² Dario Saltini,² Francesca Miceli,² Federico Casari,¹ Davide Felaco,¹ Juan Carlos Garcia-Pagan ,⁴ Jonel Trebicka ,⁵ Marco Senzolo,⁶ Gian Piero Guerrini,⁷ Fabrizio Di Benedetto,⁷ Pietro Torricelli,¹ Erica Villa ,² and Filippo Schepis ²

Since the early 1970s several studies have reported distal splenic artery embolization, better known as partial spleen embolization (PSE), as an efficacious treatment of portal hypertensive variceal bleeding and hypersplenism in cirrhosis.^(1,2) However, the effect of PSE on portal pressure is secondary to the induction of splenic infarction. Depending on both the infarct volume and possible infection, PSE can induce serious complications including death.^(2,3) On the other hand, proximal splenic artery embolization (PSAE), which mimics surgical splenic artery ligation, prevents large infarction of the spleen, favoring collateral perfusion of its intact distal vasculature.⁽³⁾ For this, PSAE has been extensively preferred over PSE for reducing portal hyperflow and treating refractory ascites (RA) after whole or partial liver transplantation (LT).^(3,4)

We report here a case of PSAE used to treat RA in a patient with cirrhosis not eligible for transjugular intrahepatic portosystemic shunt (TIPS) and LT.

Case Report

A 72-year-old man under regular follow-up at our unit since 2009 (obesity as the main comorbidity, teetotaler, under 80 mg propranolol since 2013 for secondary prophylaxis of variceal bleeding, HCV eradicated in 2016) in October 2018 was admitted for his second acute decompensation (grade 3 ascites, grade 3 hepatic encephalopathy (HE), stage 2 acute kidney injury, no infections). After discharge, despite halving the dose of propranolol, administering 40 g/week of albumin, and tuning the diuretic dosage, grade 3 ascites kept recurring (20 L per month). In February 2019, diuretics were definitively withdrawn for induced complications (renal failure, severe hyponatremia, HE). The patient was judged not eligible for LT, mainly for exceeding the age limit. TIPS was considered not feasible because of the risk of complications related to the patient's age, history of recurrent episodes of HE, and creatinine levels often exceeding 3 mg/dL. At volumetric MRI, the spleen/liver volume ratio (SLVR) was 1.4.^(4,5)

Abbreviations: HE, hepatic encephalopathy; LT, liver transplantation; PSAE, proximal splenic artery embolization; PSE, partial splenic embolization; RA, refractory ascites; SLVR, spleen/liver volume ratio; TIPS, transjugular intrahepatic portosystemic shunt.

Received December 5, 2020; accepted June 28, 2021.

**These authors equally contributed to this work.*

© 2021 The Authors. HEPATOLOGY published by Wiley Periodicals LLC on behalf of American Association for the Study of Liver Diseases. This is an open access article under the terms of the [Creative Commons Attribution-NonCommercial-NoDerivs License](https://creativecommons.org/licenses/by-nc-nd/4.0/), which permits use and distribution in any medium, provided the original work is properly cited, the use is non-commercial and no modifications or adaptations are made.

View this article online at [wileyonlinelibrary.com](https://www.wileyonlinelibrary.com).

DOI 10.1002/hep.32037

Potential conflict of interest: Dr. Garcia-Pagan consults for Cook, Gore, Shionogi and Vifor. He received grants from Conatus, Theravance and Exalenz. Dr. Trebicka consults and is on the speakers' bureau for Gore, Grifols and CSL Bebring. He consults for Boehringer Ingelheim and Genfit.

After obtaining the patient's consent, we decided to perform PSAE to treat RA following the hypothesis that it would primarily decrease portal pressure and ascites filtration and secondarily lessen the prerenal component of kidney failure.

PSAE was performed as described.^(3,4) Pre-PSAE and post-PSAE imaging is shown in Fig. 1. Main clinical, laboratory, hemodynamic, and volumetric features recorded during the main follow-up time points are summarized in Fig. 2.

No immediate or late complications related to PSAE were observed. Portal pressure significantly decreased, response/tolerance to diuretic was restored, and 3 weeks post-PSAE ascites disappeared. At the end of follow-up (15 months), estimated glomerular filtration rate improved by 104% and cardiac index and left ventricle stroke work index returned to predecompensation levels. MRI showed an expected reduction in the spleen volume and an unexpected increase in the total liver volume compared to pre-PSAE. Liver function tests, body mass index, and hemoglobin level returned to their predecompensation values.

Discussion

PSAE caused a decrease in portal pressure and ascites filtration. After this, renal response/tolerance to diuretics improved. Decrease in systemic inflammation, normalization of hemoglobin level, and nutritional status recovery may have contributed to renal and cardiac function improvement.

The mechanism underlying liver enlargement remains unexplained. Future studies should clarify if

it is due to liver regeneration triggered by changes in liver perfusion.

Vascular plugs may present technical advantages compared with coils, allowing reliable deployment in a short proximal segment of the splenic artery.⁽⁴⁾

The ideal SLVR as a predictor of significant portal pressure reduction after PSAE remains to be determined.^(4,5)

In conclusion, the safety and long-term efficacy of PSAE as a therapeutic option in patients with cirrhosis and RA not eligible for TIPS or LT should be tested in larger case series.

Acknowledgment: We thank the patient and his family for trusting us. We also thank the nurses who gracefully supported our work. Open Access Funding provided by Università degli Studi di Modena e Reggio Emilia within the CRUI-CARE Agreement. [Correction added on 17 May, after first online publication: CRUI-CARE funding statement has been added.]

Author Contributions: All authors read and approved the final manuscript. C.C. was responsible for study concept and execution of the procedure. L.T. was responsible for acquisition of hemodynamic data, manuscript drafting, and technical and material support. F.P. was responsible for acquisition of volumetric data and technical and material support. P.Q. was responsible for study concept and critical revision of the manuscript for important intellectual content. M.B. was responsible for acquisition of hemodynamic data and technical and material support. D.S. was responsible for acquisition of clinical data and technical and material support. F.M. was responsible for technical and material support. F.C. and D.F. were responsible for execution of the procedure

ARTICLE INFORMATION:

From the ¹Division of Radiology, Azienda Ospedaliero-Universitaria di Modena and University of Modena and Reggio Emilia, Modena, Italy; ²Division of Gastroenterology, Azienda Ospedaliero-Universitaria di Modena and University of Modena and Reggio Emilia, Modena, Italy; ³Unit of Interventional Radiology - Radiology Department, IRCCS Policlinico San Matteo Foundation, Pavia, Italy; ⁴Hepatic Hemodynamic Laboratory, Liver Unit, Hospital Clinic, IDIBAPS and CIBERehd, Health Care Provider of the European Reference Network on Rare Liver Disorders (ERN-Liver), Barcelona, Spain; ⁵Department of Internal Medicine I, University of Frankfurt, Frankfurt, Germany; ⁶Multivisceral Transplant Unit, Gastroenterology, Department of Surgery, Oncology and Gastroenterology, Padova University Hospital, Padova, Italy; ⁷Hepato-Pancreato-Biliary Surgery and Liver Transplantation Unit, University of Modena and Reggio Emilia, Modena, Italy.

ADDRESS CORRESPONDENCE AND REPRINT REQUESTS TO:

Filippo Schepis, M.D.
Division of Gastroenterology
University of Modena & Reggio Emilia

Via del Pozzo 71, Modena, 41100, Italy.
E-mail: fschepis@unimore.it
Tel: +39 059 4225664

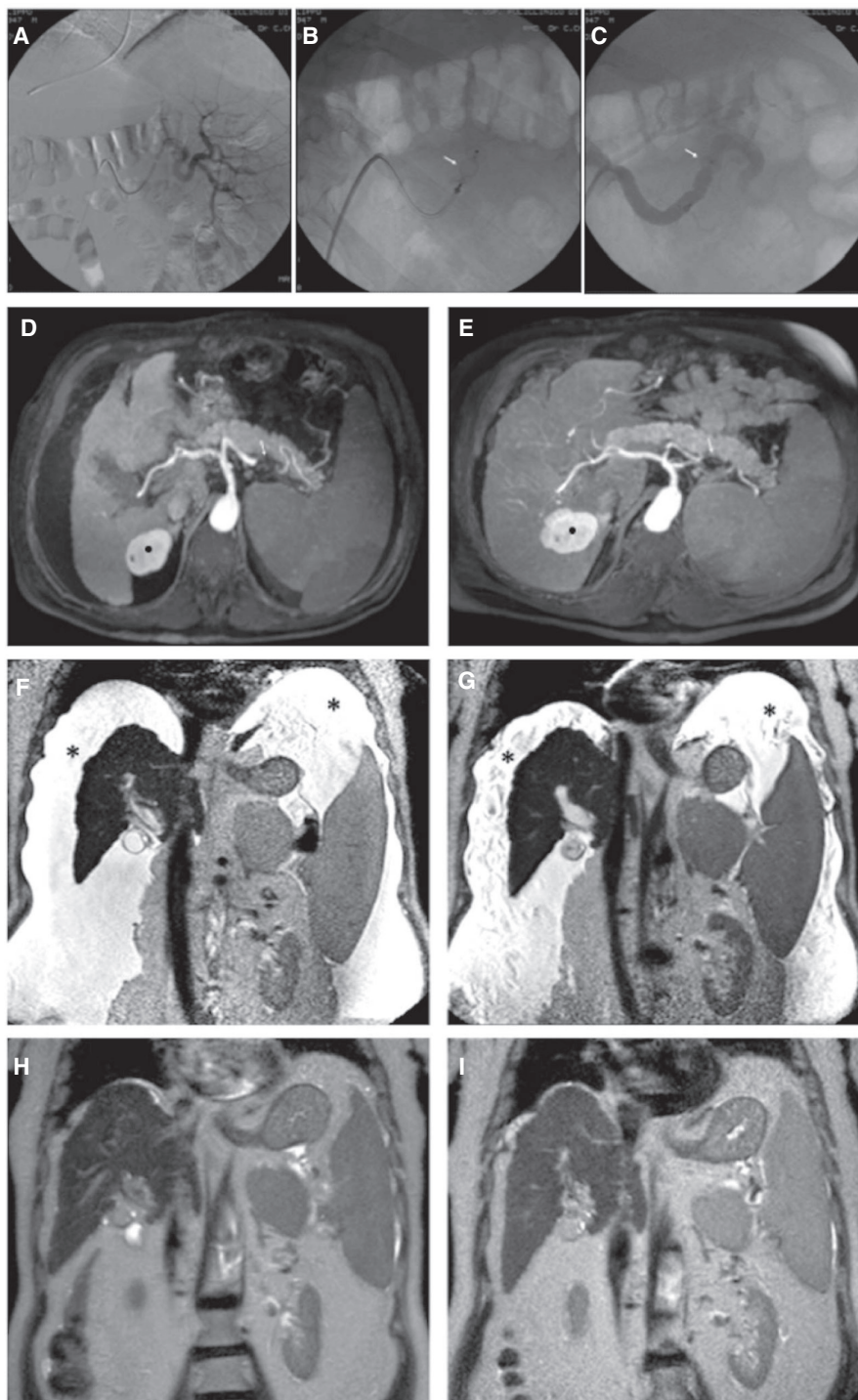


FIG. 1. Arteriographic and MRI findings before and after PSAE. (A) Panoramic angiography of the splenic artery; (B) selective catheterization of the splenic artery and its embolization by deployment of a 10-mm obliterative plug (white arrow); (C) immediate postembolization contrast agent injection showing a reflux in other branches of the celiac trunk and a significant reduction of the blood flow beyond the plug. (D,E) Maximum intensity projection reconstructions on the axial plane of arterial phase T1-weighted three-dimensional gradient-echo MRI sequences taken 2 (D) and 15 months (E) after PSAE, respectively. Contrast agent in the portion of the splenic artery distal to the obliterative plug indicates perfusion of the spleen through collateral arteries. White arrows indicate the plug inside the splenic artery. An increase of liver volume is evident in (E). The black dot indicates the upper pole of the right kidney. (F-I) Coronal single-shot T2-weighted MRI sequences taken the day after PSAE and 1 week, 2 months, and 15 months later. White asterisk indicates ascites.

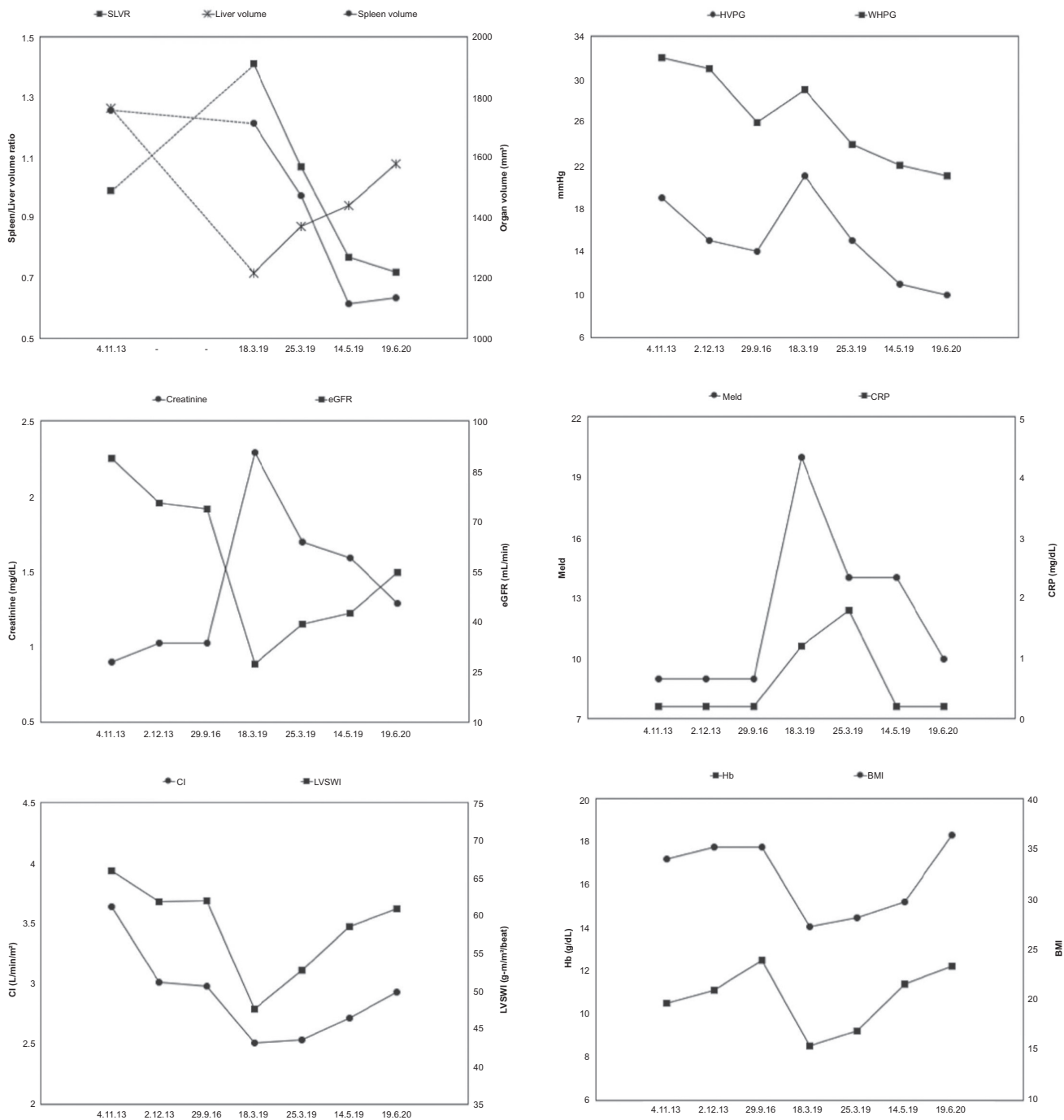


FIG. 2. Main clinical, laboratory, hemodynamic, and volumetric features of the patient during pre-PSAE and post-PSAE follow-up at our unit. Abbreviations: BMI, body mass index; CI, cardiac index (range 2.5-4.2 L/min/m²); CRP, C-reactive protein; eGFR, estimated glomerular filtration rate; Hb, hemoglobin; HVP, hepatic venous pressure gradient; LVSWI, left ventricular stroke work index (range 50-62 g-m²/beat); MELD, Model for End-Stage Liver Disease; SLVR, spleen liver volume ratio; WHVP, wedge hepatic vein pressure.

and technical and material support. J.C.G.-P., J.T., M.S., G.P.G., and F.D.B. were responsible for interpretation of data and critical revision of the manuscript for important intellectual content. P.T. and E.V. were

responsible for critical revision of the manuscript for important intellectual content. F.S. was responsible for study concept and design, execution of the procedure, acquisition of hemodynamic data, study supervision,

analysis and interpretation of data, and critical revision of the manuscript for important intellectual content.

REFERENCES

- 1) Buechter M, Kahraman A, Manka P, Gerken G, Dechène A, Canbay A, et al. Partial spleen embolization reduces the risk of portal hypertension-induced upper gastrointestinal bleeding in patients not eligible for TIPS implantation. *PLoS One* 2017;12:e0177401.
- 2) Zhang L, Zhang ZG, Long X, Liu FL, Zhang WG. Severe complications after splenic artery embolization for portal hypertension due to hepatic cirrhosis. *Risk Manag Healthc Policy* 2020;13:135-140.
- 3) Madoff DC, Denys A, Wallace MJ, Murthy R, Gupta S, Pillsbury EP, et al. Splenic arterial interventions: anatomy, indications, technical considerations, and potential complications. *Radiographics* 2005;25(Suppl. 1):S191-S211.
- 4) Quintini C, D'Amico G, Brown C, Aucejo F, Hashimoto K, Kelly DM, et al. Splenic artery embolization for the treatment of refractory ascites after liver transplantation. *Liver Transpl* 2011;17:668-673.
- 5) Luca A, Miraglia R, Caruso S, Milazzo M, Gidelli B, Bosch J. Effects of splenic artery occlusion on portal pressure in patients with cirrhosis and portal hypertension. *Liver Transpl* 2006;12:1237-1243.