

Exclusive surgical treatment for vestibular schwannoma regrowth or recurrence: A meta-analysis of the literature[☆]

Cristoforo Fabbris^{a,*}, Luca Gazzini^a, Daniele Paltrinieri^b, Daniele Marchioni^a

^a Otolaryngology Department, University Hospital of Verona, Verona, Italy

^b IT Department, University Hospital of Verona, Verona, Italy



ARTICLE INFO

Keywords:

Vestibular schwannoma
Residual
Recurrence
Facial nerve
Incomplete resection

ABSTRACT

Vestibular schwannomas can be treated in different ways, but for symptomatic or growing tumors, the gold standard is surgical removal of the lesion. In order to preserve neurovascular structures, partial removal is often performed, leaving a residual that may grow in subsequent years. To date, there is no consensus with regard to surgical treatment of vestibular schwannoma residuals, and so this review focuses on this topic.

A structured search was performed on PubMed searching for all articles discussing vestibular schwannoma residuals and recurrences. Only articles discussing surgical treatment were included, focusing on studies which also examined facial nerve outcomes.

A total of 51 articles were eligible for review and these included 375 patients. Statistical analysis was performed by correlating the following parameters: patients' gender and age at first surgery, surgical approach adopted at first and subsequent surgeries, tumor and residual size, and extent of resection (gross total, near total, subtotal or others) at first and subsequent surgical procedures. Facial nerve function was also analyzed focusing on its performance when correlated with the different surgical approaches. The data were analyzed by linear regression but there were no correlations between any of the parameters chosen. There was a statistically significant difference between the first approach used (mainly the retrosigmoid route) compared with subsequent approaches (mainly the translabyrinthine route). In total, 8.5 % of patients needed further treatment due to residual regrowth. Facial nerve outcome was independent of the parameters chosen.

Exclusive surgical treatment for vestibular schwannoma residuals had a very low failure rate in terms of requiring further treatment. The approach usually chosen for second surgery was the translabyrinthine technique, and this may be explained by the location of the residual, rather than its size. The choice of a particular surgical approach rather than another had no influence on facial nerve function. Complications rates are comparable to Gamma Knife Radiosurgery's as reported in the literature.

1. Introduction

Vestibular schwannomas (VS) are benign tumors arising from the Schwann cells of the vestibular part of the VIII cranial nerve, and are the most common cerebellopontine angle (CPA) tumor. Management of this pathology is challenging and different therapeutic strategies are possible on the basis of the patients' age, performance status or symptoms, or on the basis of the characteristics of the tumor such as its dimensions, mass effect on CPA structures and growth rate [1,2]. The first choice is a wait-and-scan approach evaluating the tumor growth rate with MRI follow-up [1]. For symptomatic or growing tumors, the gold standard is surgical removal of the lesion. Alternatively, a radiotherapeutic or radiosurgical treatment can be chosen. Different

microsurgical approaches have been developed: the retrosigmoid approach, the middle cranial fossa approach, the translabyrinthine approach and, more recently, the transcanal transpromontorial approach [1]. The goal of surgery is the gross total resection of the tumor avoiding damage to the adjacent structures of the CPA, bearing in mind that preservation of the facial nerve (FN) is challenging and a good outcome for the FN contributes to maintaining quality of life [1–5]. In particular, in cases of large VS, total removal can be associated with the risk of FN damage with subsequent paralysis [6,7]. This is why some surgeons may choose to leave small fragments of tumor in the surgical cavity, to reduce the risk of disruption of vascularization and, consequently, to preserve FN function [3].

Tumor recurrence is reported in about 0–11 % of follow-up after

[☆] This paper has not been previously published partly or in full.

* Corresponding author at: Otolaryngology Department, University Hospital of Verona, Piazzale Aristide Stefani 1, Verona, Italy.

E-mail address: cristoforo.fabbris@gmail.com (C. Fabbris).

complete surgical removal [5], but good FN outcomes (House-Brackmann grade I–II) [8] have been reported following NTR and STR [9].

Recurrences or residuals of VS are challenging: the growth rate is unpredictable, and treatment is not always required. As with primary tumors, there are different feasible approaches in the management of residuals or recurrences: wait-and-scan, surgery, or radiosurgery [2]. Focusing on surgical treatment, there is no agreement on the gold standard technique to approach this pathology, and the results in the literature are equivocal. Moreover, repeat surgery for VS residuals or recurrences seems to result in deterioration of FN function [10], but FN outcomes are unpredictable.

Revision surgery for removal of residuals or recurrences of a Vestibular Schwannomas is often debated and presents controversies, because it may determine higher rates of facial nerve paralysis and of major complications. Lots of authors, indeed, prefer the radiotherapeutic approach in case of recurrence, thus avoiding other surgical operations [11]. This meta-analysis aims to evaluate the characteristics of re-interventions (e.g., chosen approach and extent of resection) for Vestibular Schwannoma residuals or recurrences, and aims to evaluate the real intra-operative risk rate, focusing on intra-operative and post-operative complications rate.

2. Materials and methods

The present study was performed following the Preferred Reporting Items for Systematic Reviews and Meta-Analyses [12].

In August 2017, a structured search was performed on PubMed searching the terms “acoustic AND neuroma AND residual”, “vestibular AND schwannoma AND residual”, “acoustic AND neuroma AND recurrence”, “vestibular AND schwannoma AND recurrence”, “acoustic AND neuroma AND regrowth”, and “vestibular AND schwannoma AND regrowth”.

“Residual” was defined as a part of the tumor intentionally left by the surgeon, “recurrence” was defined as new growth of the tumor after its total resection, whereas “regrowth” was defined as an enlargement of a fragment of tumor intentionally left in the surgical field [2,13].

By following inclusion and exclusion criteria, titles and abstracts eligible for further review were identified. Inclusion criteria were: English language; abstract available; original papers; articles describing human patients; articles describing patients who underwent revision surgery for VS. Exclusion criteria were: non-English language; full text unavailability; laboratory studies (e.g. cadaveric and radioanatomical studies); animal studies; reviews of the literature; studies clearly unrelated to the object of the primary research.

After an initial screening, a second analysis was performed on the full texts of the articles identified. Papers describing surgical treatment of VS residuals or regrowth after a previous surgical operation were included. The following were excluded: articles not reporting clinical cases; articles describing patients treated with radiation therapy only or as revision treatment after one surgery; patients treated with a wait-and-scan policy; articles reporting a neurofibromatosis 2 case series; articles lacking clinical information.

The main information was extracted from the final set of articles included in this review, and then summarized. In the case of different papers published by the same authors, in which they specified that some patients were reported in more than one paper, only articles showing the largest case series were considered, to avoid duplication of patient data. Data missing in one paper or in the other, were collected by comparing those different cited articles.

Whenever available, patients’ data regarding gender, age at first intervention, tumor size (original value, size at moment of first intervention and at revision surgery), type of approach used at first intervention and revision surgery, extent of resection at first intervention and revision surgery, eventual presence of regrowth and further treatments after last revision surgery, have been collected.

Tumor removal was classified in terms of the percentage of tumor

removed by resection as follows:

- gross total (GTR, no macroscopic residual of tumor);
- near-total resection (NTR removal of more than 95 % of tumor volume);
- subtotal resection (STR, removal of less than 95 % of tumor volume) [14].

Further categories were considered if the articles mentioned other resection extents without defining these in detail, and the same terminologies were used (e.g. “partial removal”).

According to the descriptions provided by the authors, surgical approaches were categorized (e.g. “retrosigmoid approach”). The same kind of surgery was considered for approaches with different names but describing the same procedure.

Data on FN function were collected, whenever available, with regard to assessment before first surgery, before and after second surgery, and at last follow-up. Function assessment was noted as described within the articles, noting House-Brackmann’s grading system [8] when available, or noting the description of FN function (e.g. “palsy”). In a further categorization for statistical analysis, House-Brackmann grade I and II, and “mild”, “numbness” and “normal” terms were considered to be “Normal FN function”. House-Brackmann grade III and IV and “moderate” term were considered to be “Moderate FN function”. House-Brackmann grade V and VI and “severe” term were considered to be “Severe FN function”. In this categorization, terms used to assess FN function but without a clear explanation or reference to a grading system, were considered to be unavailable data.

Intra-operative and post-operative complications were considered and distinguished according to the moment of occurrence (during or after first surgery, revision surgery or subsequent operations). FN dysfunction, as mentioned above, was considered separately.

Whenever reported by the authors, site of residual was noted in order to evaluate its influence on subsequent surgical choices.

Diverse correlations between the different types of data collected have been analyzed, as described in the “Results” section. Linear regression was performed for statistical analysis to establish correlations in the data.

3. Results

3.1. Article selection

The search on the PubMed database found 626 citations, and when adjusted for duplicates, this decreased to 617 studies. The articles were then screened on the basis of their Abstracts. Of these, 62 were discarded because they were reviews and not original articles; another 274 citations were not relevant because no surgery was performed, radiotherapy was the only treatment administered, or the study was conducted on malignant tumors. A further 18 citations were not eligible because they were conducted on animal models, cadaveric specimens, or they only included radioanatomic or histopathologic studies. Moreover, 115 studies were not eligible because the full text was not available in English. The remaining 148 citations were carefully evaluated and the full text was examined. Out of these, 58 were excluded because there was insufficient data about the patients, the surgical technique, the postoperative follow-up or the surgical outcomes. In a further 15 studies, it was not possible to characterize the different patients included in the study. A total of 21 citations were discarded because those studies included patients in which radiotherapy or gamma knife treatments were administered before or after the surgical procedure. A staged resection was planned in three studies and they were considered to be unique procedures rather than residual tumor surgery. Finally, a total of 51 citations were eligible as shown in a flow diagram (Fig. 1) and were analyzed in this study.

All of the studies included were retrospective case series or case

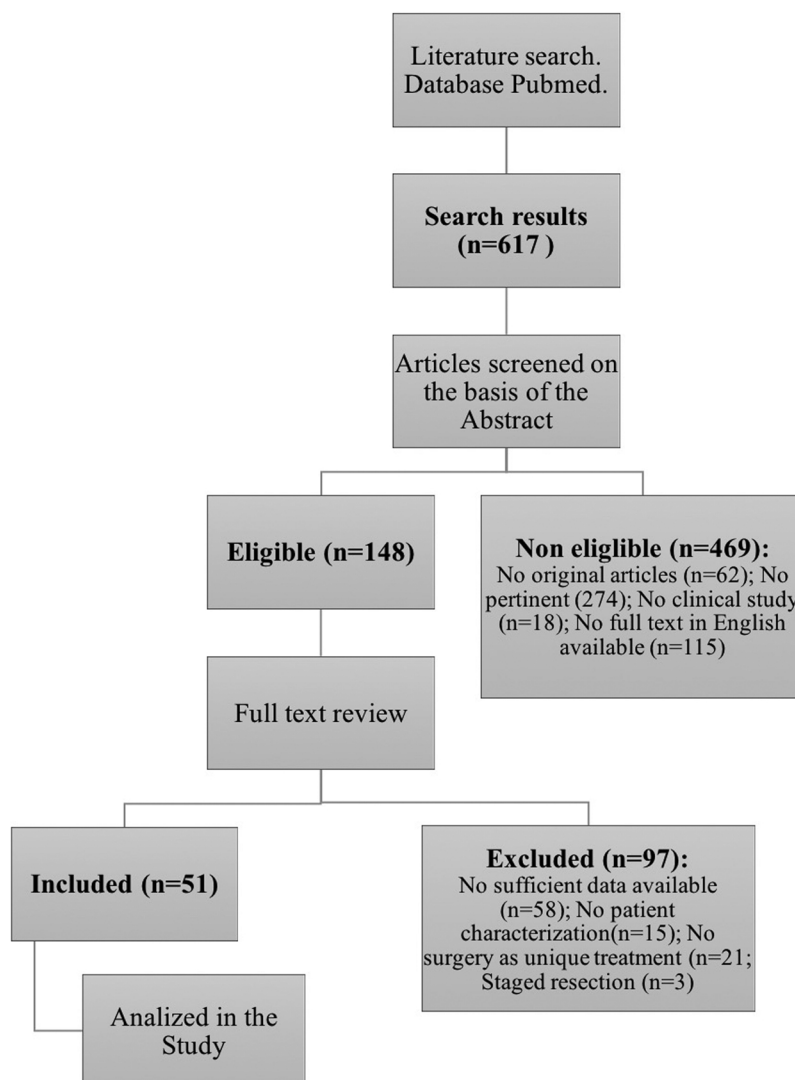


Fig. 1. Study selection.

reports.

3.2. Demographic data

Based on the inclusion criteria, a total of 375 patients underwent revision surgery for residual or recurrent vestibular schwannoma. Of these, 148 (39.5 %) were female and 103 (27.5 %) were male; gender was not characterized in the remaining 124 (33.0 %) patients. Age data was available in 329 (87.7 %) cases, and the average age at revision surgery was 45.34 (15–80) years.

3.3. Tumor characteristics

The original tumor size was mentioned for 216 (57.6 %) patients. Although the measurement units were not uniform, it was possible to estimate tumor size with an acceptable level of bias as described: in 158 (42.1 %) patients, the maximum diameter measurement was available (expressed in centimeters or millimeters); in 42 (11.2 %) patients, the lesion size was characterized by a measurement interval; the median value of the interval was considered for the analysis (i.e. for a tumor diameter between 1 cm and 2 cm, we considered 1.5 cm as the approximate measurement for the analysis). Moreover, in another study where the tumor size was given as a volume measurement (cm³) in 16 (4.3 %) patients, in this case, an approximation of the diameter was

obtained using $\sqrt[3]{x}$ of the volume. According to these methods, the median tumor size was 3.22 cm (1–6 cm) as the maximum diameter of the lesion. For other patients, it was not possible to extrapolate these data.

The residual or recurrence tumor size after the first operation was available for 124 (33.0 %) patients: in 105 (28.0 %), an accurate diameter was available; in 18 (4.8 %) patients, it was described as a measurement interval, and in 1 (0.3 %) patient, it was expressed as a volume. The median lesion diameter, approximated as previously described, was 2.48 cm (0.3–5 cm).

Location of the residual tumor was reported in 114/375 cases. The internal auditory canal was involved in 70/114 cases, with extension to the posterior cranial fossa (3/70), the petrous apex (1/70), the cerebellum (1/70), or it was located within the fundus (3/70); no details of nearby structures involvement were available among 62/70 cases. Adherence to the FN was reported in 2/114 cases and basal turn of the cochlea remnant was noted in 1/114 case. CPA was involved in 36/114 cases: in particular, 1/36 case was reported as “lateral brainstem” residual, 1/36 case involved cranial nerves, and 5/36 extended to the porus acusticus internus. Residual was adherent to cerebellum in 1/114 case. One case (1/114) was defined as a residual on the VIII cranial nerve stump. Finally, 3/114 cases of multifocal residuals were reported.

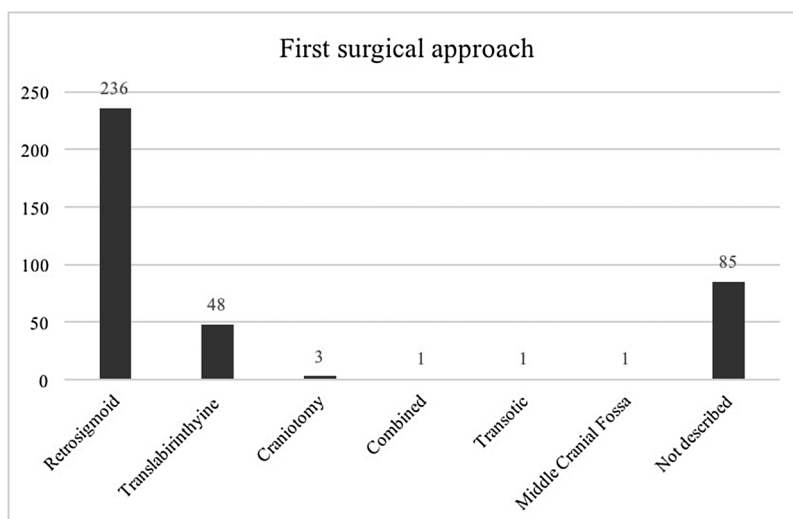


Fig. 2. First surgical approach.

3.4. First surgery

The first approach technique was a retrosigmoid approach in 236 (62.9 %) patients, a translabyrinthine approach in 48 (12.8 %) patients (in one case, an enlarged translabyrinthine approach was performed), a retrosigmoid combined with a translabyrinthine approach in 1 (0.3 %) patient, a craniotomic approach not otherwise described in 3 (1%) patients, a transotic approach in 1 (0.3 %) case, and a middle cranial fossa approach in 1 (0.3 %) patient. In 85 (22.7 %) patients, the first surgical technique was not described (Fig. 2).

The radicality of resection was classified as gross total in 109 (29.0 %), near-total in 16 (4.3 %), subtotal in 114 (30.4 %), intracapsular in 26 (6.9 %) and partial removal in 7 (1.9 %) patients. In 103 (27.5 %) cases, the extent of resection was not described in the study (Fig. 3).

There was no statistical correlation between tumor size and the surgical technique chosen in the first surgical approach (p-value = 0.1492), or between tumor size and the radicality of the first resection (p-value = 2.326).

3.5. Revision surgery

In revision surgery, the approach chosen for residual and recurrent

tumor treatment was a retrosigmoid approach in 84 (22.4 %) patients (in seven patients, a first revision surgery via a retrosigmoid approach was followed by a second revision surgery performed via a translabyrinthine approach; in one patient, two revision surgical procedures via a retrosigmoid approach were followed by surgery by a translabyrinthine approach); a translabyrinthine approach in 140 (37.3 %) patients (in 16 patients, an enlarged translabyrinthine approach was performed; in two patients, a first revision surgery via a translabyrinthine approach was followed by a second surgical procedure by a retrosigmoid approach; in three patients, two revision surgical procedures were performed by a translabyrinthine approach; in six patients, a first revision surgery by a translabyrinthine approach was followed by a second translabyrinthine approach and a third procedure by a retrosigmoid approach); a modified extended middle cranial fossa approach in 18 (4.8 %) patients (in one case, a classic middle cranial fossa approach was performed); an exploratory craniotomy in 2 (0.6 %) patients (in one of these, the craniotomy was combined with an infratemporal approach type A); a transotic approach in 3 (0.8 %) patients and a transcochlear approach in 6 (1.6 %) patients. Data for 122 (32.5 %) patients were not available (Fig. 4).

By considering retrosigmoid and translabyrinthine approaches, a statistically significant difference emerged between the technique used

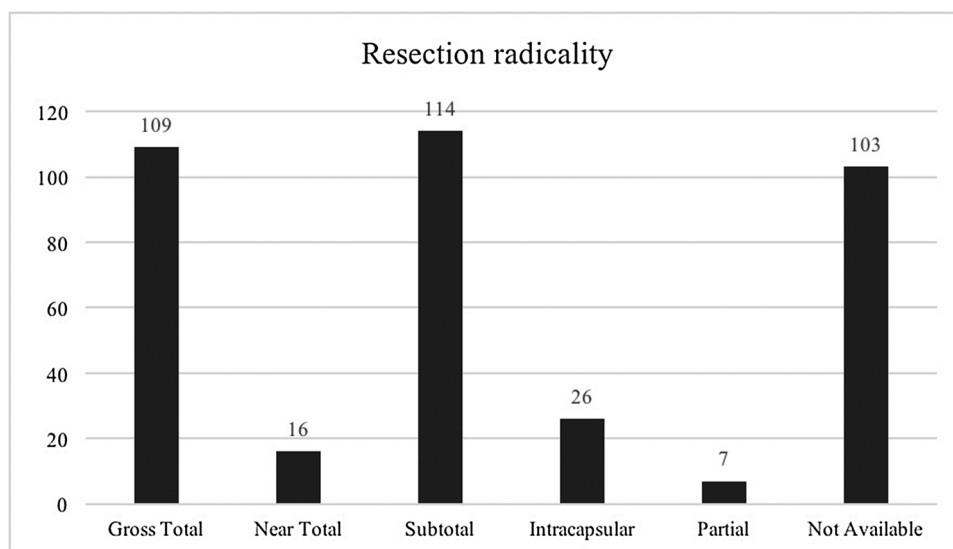


Fig. 3. Radicality of resection after the first surgery.

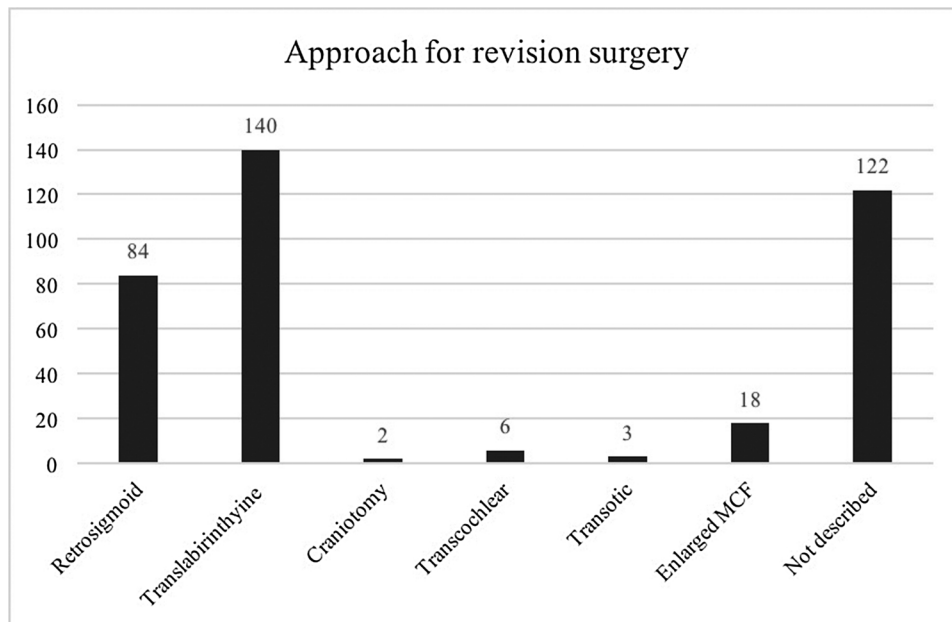


Fig. 4. Surgical approach in the revision surgery.

in the first surgery and the technique used in the revision surgery (p-value < 0.00001).

The radicality of resection after revision surgery was classified as: gross total in 141 (37.6 %); near-total in 14 (3.7 %) (three of these had a second revision surgery obtaining a near-total, gross total, and partial resection); subtotal in 37 (9.9 %) patients (four patients had a second revision surgery obtaining a gross total, a subtotal and in two cases, a near-total resection; of this last group, one patient underwent a third revision surgery obtaining a gross total removal of the tumor); partial in 3 (0.8 %) patients (one patient had three revision surgical procedures, all with subtotal removal of the lesion). In 180 (48.0 %) cases, the extent of resection was not described in the study. The radicality of revision surgery was independent of the residual/recurrent tumor size (p-value: 0.3888) (Fig. 5).

In the articles included in the present study, the site of residual tumor was not indicated by the authors in 261/375 patients, in 71/375 it was located in the IAC or extended to petrous apex, in 36/375 in the CPA or adherent to the cerebellum, in 4/375 it was adherent to the VII cranial nerve (not specified site), and in 3/375 a multifocal residual was

found.

The retrosigmoid approach tended to be used more often for the first surgery whereas the translabyrinthine approach was used more often to treat residuals and the difference was statistically significant (p-value < 0.00001).

3.6. Facial nerve function

In 21 out of 51 studies, facial nerve function was described and characterized for each patient with a total of 205 cases. Facial nerve function was evaluated in the different studies using different classifications. In order to summarize and to standardize the results, we divided facial nerve function into three groups: normal or near-normal (corresponding to grade I or II of the House-Brackmann classification), moderate facial palsy (corresponding to grade III or IV of the House-Brackmann classification), and severe or complete facial palsy (corresponding to grade V or VI of the House-Brackmann classification).

After the first surgical procedure, 107 (52.2 %) patients presented a normal or near-normal facial function, 43 (21.0 %) patients presented a

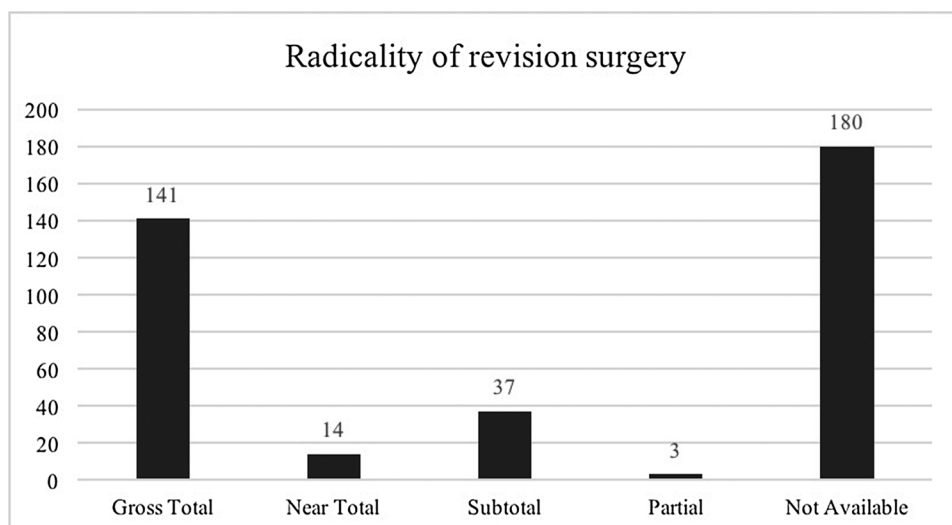


Fig. 5. Radicality of resection after the revision surgery.

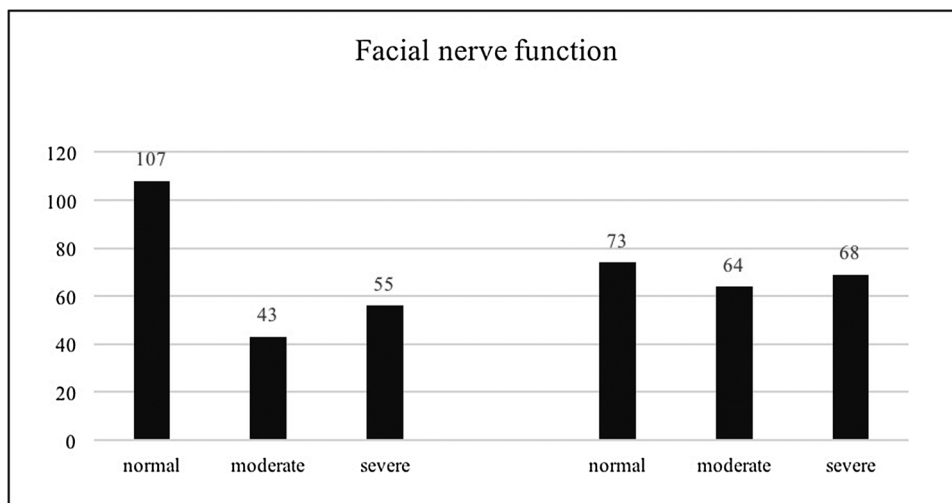


Fig. 6. Facial nerve function after the first operation and after revision surgery.

moderate facial nerve palsy, and 55 (26.8 %) had a severe or complete facial palsy. After the revision surgery, facial nerve function was normal or near-normal in 73 (35.6 %) patients, moderate in 64 (31.2 %) patients, and a severe or complete facial palsy was found in 68 (33.2 %) patients (Fig. 6).

Evaluating the difference in facial nerve function before and after revision surgery, in 18 (8.8 %) patients, there was an improvement in facial nerve function (from moderate to normal in four patients and from severe to moderate in 14) in 123 (60.0 %) patients, facial nerve function remained the same as before surgery, and in 68 (33.2 %) patients, it worsened (from normal facial function to moderate facial palsy in 35, from moderate to severe in 20 patients, and from normal to severe or complete facial palsy in 13 patients) (Table 1).

Facial nerve function after revision surgery was significantly poorer than after the first operation (Chi-squared test: p-value = 0.002705).

Regarding the correlation between modification of facial nerve function before and after revision surgery and (1) the approach chosen for revision surgery, (2) residual or recurrent tumor size, (3) radicality of revision resection, and (4) approach for revision surgery corrected for residual/recurrence tumor size and radicality of revision surgery, none of these correlations were statistically significant, as summarized in Table 2.

Regarding revision surgery, by considering only translabyrinthine resections, 102 cases were performed by ENT surgeons alone, 4 by neurosurgeons alone, while 34 cases were treated by a multidisciplinary team (neurosurgeon and ENT). In the first subgroup, removals were classified as 39 GTR, 4 NTR, 7 STR and 1 partial (data were not available in 51 cases). FN function resulted to be normal in 18/102 cases, moderate in 25/102, and severe in 31/102, while data were unavailable in 28/102 cases. The second subgroup was composed by 4 GTR and FN function resulted HB grade II in 1 case and grade III in 3 cases. In the latter subgroup there were 17 GTR, 4 NTR and 11 STR (data were unavailable in 2 cases); FN outcome after revision surgery resulted to be normal in 8/34 patients, moderate in 9/34, and severe in 2/34 (data were unavailable in 15/34 cases). Final regrowth occurred in 1 case belonging to the first and 1 belonging to the third subgroup, respectively, and both tumors had been previously subtotally removed.

Table 1
Modification of facial nerve function before and after the revision surgery.

	Facial nerve function					
	Severe to normal	Severe to moderate	No variation	Moderate to severe	Normal to moderate	Normal to severe
No. of patients (%)	4 (1.9 %)	14 (6.8 %)	123 (60.0 %)	20 (9.7 %)	35 (17.1 %)	13 (6.3 %)

Table 2
Statistical significance of correlations between facial nerve function before and after revision surgery and the parameters of revision surgery.

Parameter of revision surgery	p-value
Approach for revision surgery	0.05399
Residual/recurrence tumor size	0.2139
Radicality of revision surgery	0.2999
Approach for revision surgery corrected for residual/recurrence tumor size and radicality of revision surgery	0.2818

3.7. Long-term results

Twelve patients who developed a recurrence or had a residual tumor after revision surgery underwent radiotherapy (in 3 cases gamma knife radiosurgery and in 9 cases traditional radiotherapy). Moreover, 4 patients received radiotherapy after 2 revision surgical procedures with tumor relapse.

3.8. Complications

Regarding first surgery, post-operative course was described in 39/375 cases. Complications did not occur during first surgery or in the first postoperative period in 26/39 (66.6 %) patients. Complications were described among 13 (33.3 %) patients. In 4/39 patients CSF leakage and in 2/39 hydrocephalus were observed, 3/39 patients experienced cranial nerves lesions (IV, V, IX, X or XII cranial nerve), 1/39 patient experienced vocal chord paralysis, and 1/39 temporary dysphagia. At last, 1/39 suffered from multiple air embolism and 1/39 from change of vital signs. Data were not indicated by the authors in 336/375 (89.6 %) patients.

During revision surgery or in the second postoperative period, complications were absent among 78/375 (20.8 %) patients, while they were present in 36/375 (9.6 %). CSF alone or associated with other symptoms occurred among 12/114 patients, while hydrocephalus was reported among 2/114 patients. Seven patients suffered from cranial nerve dysfunction (III-XI cranial nerves, in different associations) and in

one of them a post-operative tracheostomy for dyspnea was needed. Moreover, one patient suffered from corneal clouding. Ataxia occurred in 4/114 cases, a temporary hemiparesis was present in 1/114 case, intracranial hematoma alone was observed in 1/114 case, and meningitis was present in 1/114 case. One patient experienced cardiovascular accident, 4 suffered from vertigo, and in 1 case hematoma of the leg in the site of muscle grafting occurred. At last, 1 patient died during follow-up. Data were not available in 261/375 (69.6 %) cases.

Further complications were evaluated in patients who underwent more than 2 surgeries. Among them, no complications occurred in 18 (29 %) cases, whereas they were present in 5 (8.1 %). Cranial nerve dysfunction was present in 2 cases and 1 of them subsequently died due to dysphagia, ab ingestis and septic shock. CSF leakage was present in 1 case, temporary apraxia in 1, and cardiovascular accident occurred in 1 patient. Data were not present among 39/62 (62.9 %) cases.

4. Discussion

4.1. Surgical outcomes

According to some authors, after subtotal resection, VS residuals do not show any growth for years [15–19] even though recurrence rates after subtotal resection have been reported to be about 20 % [7,18,19].

Treatment for residual VS can be by different modalities (a wait-and-scan policy, radiation therapy, or revision surgery) and depends on the status of the lesion, general clinical condition and the preference expressed by the patient [20]. In the case of a large VS encountered at first operation, some authors have also emphasized the importance of surgical treatment followed by adjuvant radiosurgery, to preserve neural structures [18]. To date, to the best of our knowledge, there is no protocol or consensus regarding the treatment of choice for VS residuals, for several reasons, e.g. tumor size, patients' age, surgeon's expertise, etc.

Even when gross total resection (GTR) is performed, an eventual recurrence should not be excluded. Indeed, < 10 % recurrence rates occurring after complete resection are reported, even though many studies are limited by a short follow-up or low definition imaging [21]. In the present study, among the 375 cases analyzed, only 109 (29.1 %) originally underwent GTR. This may be explained by the progressive improvement in imaging, in particular MRI, so that earlier diagnosis can now be made before the tumor has reached a large size; however, it must also be considered that a significant amount of data were lacking in this study, since there were no data regarding resection extent in 103 (27.5 %) patients.

Moreover, considering the slow growth of VS, an adequate follow-up period is required. Nakatomi et al. [21] hypothesized a gross underestimation of recurrence frequency among studies with a short follow-up (< 5–10 years). Also, in their case series, they found a shorter interval between treatment and recurrence among patients with subtotal resection (STR) compared with GTR, probably due to the more difficult detectability of a smaller VS remnant on imaging. In our meta-analysis, the follow-up period was rarely mentioned in the selected articles and it was not always clear whether the period started from the first operation or the last one. Overall, on average, the follow-up period lasted for 64.8 months, and data were not mentioned in 56 cases. Nevertheless, since there was a wide heterogeneity and missing data, a valid statistical analysis could not be performed.

Nakatomi et al. [21] also mentioned the importance of an adequate follow-up period according to the type of resection of the original tumor. They suggested an MRI scan after 2, 7 and 10 years in GTR if no suspicious enhancement was revealed after removal, otherwise, if a resection less than GTR was performed, more frequent MRIs are recommended. This prompted us to consider the higher recurrence rate after near-total resection (NTR), STR or other partial removal. To confirm this, among our cases analyzed, 163/375 underwent incomplete removal. If we exclude cases with data not reported (103/

375, 27.5 %), the results show that recurrence was higher in the non-GTR group (59.6 %) compared with the GTR group (40.4 %).

Regarding the surgical approach, the one mainly chosen at the time of first operation was the retrosigmoid approach (236/375), and the second was the translabyrinthine approach (48/375) with some variants (1 enlarged translabyrinthine and 1 combined translabyrinthine-retrosigmoid approach). Treatment of residuals was mainly accomplished with the translabyrinthine (140/375 cases) and retrosigmoid techniques (84/375). The choice of one approach rather than the other is dictated by different reasons, such as location of the residual, surgeon's expertise and patient's hearing status. In particular, according to our results, the latter seemed not to be the main reason. Indeed, by comparing hearing status between patients who underwent revision surgery via translabyrinthine and retrosigmoid approach, data were available among 93 patients. Among them, 69/93 had undergone a translabyrinthine approach as first surgery, so at revision they had no residual hearing on the affected side. The remaining 24 cases underwent revision surgery with retrosigmoid approach (3/24) and with translabyrinthine approach (21/24). There were no substantial differences regarding hearing status, since all of them suffered from highly compromised hearing (as defined as "profound hearing loss", "class C/D", "< 50 dB PTA", "deafness", or "hearing loss" without further details).

In the articles included in the present study, the site of residual tumor was not indicated by the authors in 261 patients. Therefore, since this fundamental data was lacking for the large majority of patients, it was not possible to correlate the residual tumor site with the chosen approach for revision or subsequent surgeries. On the other hand, a statistically significant difference emerged regarding the use of the retrosigmoid and translabyrinthine techniques: the retrosigmoid approach tended to be more often used for first surgery whereas the translabyrinthine approach was adopted to treat residuals, and this difference was statistically significant (p-value < 0.00001).

No evidence was sufficiently robust to explain the choice of a particular approach according to age, size of residual or other factors, possibly because this case series is very heterogeneous, and perhaps it depends on the surgeon's choice and, in particular, on the location of the residual, as reported in the "results" paragraph. As mentioned above, the approach mainly chosen to treat recurrences was the translabyrinthine approach, and this may be explained by the fact that the residuals are generally found in the internal auditory canal. The retrosigmoid approach allows a wide view of the cerebellopontine angle, the possibility to resect large tumors and eventually to preserve hearing function, but on the other hand, this approach does not provide adequate control over tumors occurring in the internal auditory canal, leading to the possibility of leaving tumor fragments in the surgical cavity (even though a final check with endoscopes has been suggested to remove any residual [22]). The disadvantages of the retrosigmoid approach, in contrast to the ability of the translabyrinthine and the other above-mentioned techniques to provide better control over tumors in the internal auditory canal, may explain the statistically significant choice of the latter options for revision surgery. Even if among the selected papers there were no cases of endoscopic-assisted procedures, access to the IAC during retrosigmoid approaches has been described. Regarding first surgery drilling of the internal acoustic canal was mentioned in 22 cases, while it was not performed or not mentioned in 214. Post-operative FN outcome resulted as follows: among the IAC-drilled cases, 3/22 had severe FN function and 19/22 had no available data; among the non-IAC-drilled patients, 84/214 had normal FN function, 30/214 moderate, and 48/214 severe (52/214 had no available data). Regarding revision surgery, IAC-drilled patients were 19, while non-IAC-drilled ones were 65. Post-operative FN function was as follows: in the first subgroup, it was normal in 1/19 patient, moderate in 5/19, and severe in 8/19 (no available data regarded 5/19 cases); in the second subgroup, it was normal in 18/65 cases, moderate in 17/65, and severe in 21/65 (unavailable data regarded 11/65 cases).

Among all patients who underwent revision surgery via retrosigmoid approach, 15 experienced further recurrence and none of them had been previously treated with IAC drilling.

Overall, by considering only cases with available data, after removal of residuals, only 32/375 patients needed further treatment, representing 8.5 % of all cases. One patient (0.3 %) died during follow-up, whereas there was no mention of further surgery or radiation therapy among 342/375 (91.2 %) patients. Since there is no statistical correlation of this result with other factors, the exclusive surgical treatment of VS residuals has a low failure rate, independent of patients' age, size of the tumor and previously adopted approach, and this must be bore in mind by the neurosurgeon or the otolaryngologist who formulates any treatment plan.

4.2. Facial nerve outcomes

In the last few decades, management of VS has evolved significantly, and, in particular, more attention is now paid to patients' quality of life, thus treatment strategies have changed [23].

Surgical treatment for VS has been proved to have good clinical outcomes, especially in the case of small tumors [24], but quality of life depends on multiple factors. The importance of this aspect can be indicated by the presence of tinnitus, vestibular impairment or hearing impairment [25]. In addition, FN function is considered to be the most relevant indicator for quality of life [26]. According to Tokimura et al. [27], continuous facial motor evoked potential monitoring may be useful during surgical removal of VS, since this technique alerts the surgeon to FN invasion. This aspect seems to have a predictive value on postoperative FN outcome, so those authors underline the importance of avoiding even transient postoperative FN dysfunction.

Each surgical approach (e.g. translabyrinthine, retrosigmoid, etc.) has its own advantages and disadvantages, even though there is no firm evidence to support the superiority of one over another. The same assumption can also be made with regard to FN preservation: even considering subtotal resection followed by radiation treatment, there is no definite evidence of a better outcome given by any one type of treatment [28].

In a case series of 168 patients, Obaid et al. [29] compared the translabyrinthine approach with the retrosigmoid route. According to their analysis, resection efficacy did not show any relevant differences; however, in terms of postoperative complications and FN preservation, the translabyrinthine approach resulted in lower morbidity.

Good results on FN outcome were also obtained by Marchioni et al. [30], who suggested a transcanal approach to treat small- and medium-sized VS. In their case series, there was 95.9 % FN preservation (House-Brackmann stage I and II), thus those results were comparable to others, obtained with the translabyrinthine approach in two different case series [14,31].

Small lesions can also be resected with radiation therapy: gamma-knife radiosurgery can be used to treat VS residuals or recurrences after microsurgical resection. In this case, there was a high rate of serviceable FN function postoperatively, thus confirming that radiation treatment can be a valid option [32].

To date, there are no established criteria to choose a particular approach for VS treatment, since stereotactic radiotherapy, surgical removal or combined approaches, and clinical observation are all well accepted options [29]. Incomplete removals are often performed in the case of large tumors, but in general, they are performed if there is a risk of damage to the FN and other neurovascular structures, so a fragment of the lesion is intentionally left in place. If this kind of resection is performed, a near-total (> 95 %) or subtotal (< 95 %) excision is defined [33] according to the percentage of tumor removed, even though these rates vary across different studies [34]. These residuals have different behaviors, including eventual regrowth with subsequent compression of the surrounding structures and FN. In these cases, surgical removal may be an appropriate solution, but on the other hand,

scar tissue may be a significant obstacle for the surgeon [35].

In the present study, the lack of uniformity with regard to the use of a surgical approach may explain the high heterogeneity of our results, not only regarding the surgical technique used, but in particular, regarding FN outcome. By considering FN function at the last follow-up compared to the assessment before revision surgery, there were data for 205 patients. Among these, 18/205 cases (8.8 %) showed functional improvement (even if this seems to be an anomalous event, since with revision surgery a stability or a deterioration of FN function should be expected), 62/205 (30.2 %) showed functional deterioration, and for 125/205 patients (61 %), no variation of FN function was noted. The impact of tumor size on FN outcome has been advocated by many authors, even though a wide variation in function has also been shown, possibly due to the different methods used to assess VS size. In some case series, there was a significant association between preoperative tumor size and FN outcome, and in particular, FN function deterioration related to VS greater than 4 cm [36]. In our study, by comparing all results regarding VS residuals and original tumor size, we did not find a statistically significant correlation for FN outcome after the first operation, and no differences in outcome according to the extent of resection.

In some cases, good results for FN function were reported, function being improved or remaining the same after revision surgery, thanks to intraoperative monitoring of the FN nerve itself and other possible factors. On the other hand, in the majority of cases, FN outcome had deteriorated. Beatty et al. [37] claimed that, for revision surgery, the translabyrinthine approach was a safer approach than the retrosigmoid approach, because of the possibility to approach the cerebellopontine angle through a corridor of previously untouched tissue, thus no scars or adhesions were present. As a result, preservation of FN function seemed to be higher. On the other hand, according to our analysis, there was no statistically significant correlation between FN outcome at the last follow-up and the surgical approach chosen. Moreover, no correlation was found when considering the change in FN function before and after revision surgery.

Another matter the surgeon may have to deal with is the size of the VS residual. Ramina et al. [35] reported a case series of patients with large or giant VS residuals. The authors treated these large-sized lesions with a retrosigmoid approach. FN outcomes were variable and in accordance with the overall results that we found in the literature. In our analysis, indeed, there was no statistically significant correlation between tumor size and FN function.

The results of this study seem to show that FN functional outcome was independent of the different factors that may have an influence on the choice of approach by the surgeon. The choice of surgical route to treat these residuals may be dictated by the same parameters as considered for previously untreated VS (e.g., tumor location and size, and clinical condition of the patient). FN outcome might be influenced by the presence of scars, by preoperative FN function and by the fact that this is a complex operation. Further reviews might be performed to analyze the influence of radiation therapy on FN outcome.

4.3. Complications

In the different examined articles, various kinds of complications were noted. As reported in the "Results" paragraph, they were very heterogeneous, thus no statistical analysis could be made. The most frequently observed complications were CSF leakage and cranial nerve dysfunction. There was no correspondence with a particular surgical approach or a specific characteristic of the VS. Moreover, lots of patients were not characterized, so, for instance, it was not deducible whether a particular complication occurred in a patient operated on with a retrosigmoid or a translabyrinthine approach. The choice of the surgical technique probably varied depending on surgeon's expertise, and this factor, together with patient and tumor characteristic, determined the occurrence or not of particular complications.

By considering only patients with available data, both with first and second surgery, complications rate was approximately one third of cases (33.4 % and 31.6 %, respectively), while in case of subsequent surgeries this ratio improves to 21.9 %, maybe due to the reduced size of VS residual to be removed. By the way, it must be bore in mind that for the majority of patients, data on complications were not available, so if the overall rates of complications are considered, these ones result to be comparable to others reported in the literature regarding treatment of VS residuals with Gamma Knife Radiosurgery [37,38].

4.4. Limitations of the present study

The present meta-analysis combines data from different studies to evaluate the surgical treatment of VS residuals and to identify any uniformity in its choice. The main limitations of this study are that the patient population and tumor characteristics are very heterogeneous across studies. As a result, the use of a funnel plot and test for small-study effects, as suggested for meta-analyses, are not appropriate [39–42], so risk assessment for bias was not performed in this study.

5. Conclusion

This study focuses on exclusive surgical treatment for vestibular schwannoma residuals. Surgery alone, without radiosurgery or other kinds of radiation therapy, had a very low failure rate in terms of patients requiring further treatment (8.5 %). The approach mainly chosen for second surgery was the translabyrinthine technique, and this may be explained by the location of the residual, rather than its size. Facial nerve outcomes were independent of the approach chosen, tumor characteristics, extent of resection or patient characteristics. Other complications represent a low overall rate, which is comparable to reported rates for Gamma Knife Radiosurgery. Further studies with a different design would be necessary to show whether radiosurgery alone had a similar or different rate of effectiveness compared with surgery alone, as this topic goes beyond the scope of this paper.

Disclosures

The authors have no funding to disclose.

Ethical approval

All procedures performed in studies involving human participants were in accordance with the ethical standards of the institutional and/or national research committee and with the 1964 Helsinki declaration and its later amendments or comparable ethical standards. As this manuscript is a meta-analysis of the literature, ethical approval and informed consent have been checked within the articles reviewed.

Declaration of Competing Interest

All of the authors declare that they have no conflict of interest and no funding to disclose.

References

- [1] F. Arlt, C. Trantakis, V. Seifert, F. Bootz, G. Strauss, J. Meixensberger, Recurrence rate, time to progression and facial nerve function in microsurgery of vestibular schwannoma, *Neurol. Res.* 33 (Dec. (10)) (2011) 1032–1037.
- [2] M. Sanna, M. Falcioni, A. Taibah, G. De Donato, A. Russo, E. Piccirillo, Treatment of residual vestibular schwannoma, *Otol. Neurotol.* 23 (Nov. (6)) (2002) 980–987.
- [3] Z. Chen, S.C. Prasad, F. Di Lella, M. Medina, E. Piccirillo, A. Taibah, et al., The behavior of residual tumors and facial nerve outcomes after incomplete excision of vestibular schwannomas, *J. Neurosurg.* 120 (Jun. (6)) (2014) 1278–1287.
- [4] D. Marchioni, M. Carner, A. Rubini, J.F. Nogueira, B. Masotto, M. Alicandri-Ciuffelli, et al., The fully endoscopic acoustic neuroma surgery, *Otolaryngol. Clin. North Am.* 49 (Oct. (5)) (2016) 1227–1236.
- [5] B.E. Pollock, L.D. Lunsford, J.C. Flickinger, B.L. Clyde, D. Kondziolka, Vestibular schwannoma management. Part I. Failed microsurgery and the role of delayed stereotactic radiosurgery, *J. Neurosurg.* 89 (Dec. (6)) (1998) 944–948.
- [6] M.A. Arriaga, W.M. Luxford, J.S. Atkins Jr., J.A. Kwartler, Predicting long-term facial nerve outcome after acoustic neuroma surgery, *Otolaryngol. Head. Neck Surg.* 108 (1998) 220–224.
- [7] S.P. Lownie, C.G. Drake, Radical intracapsular removal of acoustic neurinomas. Long-term follow-up review of 11 patients, *J. Neurosurg.* 74 (1991) 422–425.
- [8] J.W. House, Facial nerve grading systems, *Laryngoscope* 93 (1993) 1056–1069.
- [9] D.C. Bloch, J.S. Oghalai, R.K. Jackler, M. Osofsky, L.H. Pitts, The fate of the tumor remnant after less-than-complete acoustic neuroma resection, *Otolaryngol. Head. Neck Surg.* 130 (2004) 104–112.
- [10] M.J. Huang, H. Kano, S.H. Mousavi, A. Niranjani, E.A. Monaco 3rd, Y. Arai, et al., Stereotactic radiosurgery for recurrent vestibular schwannoma after previous resection, *J. Neurosurg.* 126 (May (5)) (2016) 1506–1513.
- [11] R.T. Daniel, C. Tuleasca, M. George, E. Pralong, L. Schiappacasse, M. Zeverino, et al., Preserving normal facial nerve function and improving hearing outcome in large vestibular schwannomas with a combined approach: planned subtotal resection followed by gamma knife radiosurgery, *Acta Neurochir. (Wien)* 159 (Jul. (7)) (2017) 1197–1211.
- [12] D. Moher, A. Liberati, J. Tetzlaff, D.G. Altman, P. Group, Preferred reporting items for systematic reviews and meta-analyses: the PRISMA statement, *Ann. Intern. Med.* 151 (2009) 264–269 W264.
- [13] C. Shelton, Unilateral acoustic tumors: how often do they recur after translabyrinthine removal? *Laryngoscope* 105 (Sep. (9 Pt. 1)) (1995) 958–966.
- [14] S.F. Ansari, C. Terry, A. Cohen-Gadol, Surgery for vestibular schwannomas: a systematic review of complications by approach, *Neurosurg. Focus* 33 (2012) E14.
- [15] J.P. Cross, Unilateral neurilemmomas of the eighth cranial nerve: then and now, *Am. J. Otol.* 3 (1981) 28–34.
- [16] S.G. Hamer, C.W. Beatty, M.J. Ebersold, Retrosigmoid removal of acoustic neuromas: experience 1978–1988, *Otolaryngol. Head. Neck Surg.* 103 (1990) 40–45.
- [17] W. House, Partial tumor removal and recurrence in acoustic tumor surgery, *Arch. Otolaryngol.* 88 (1968) 96–106.
- [18] H. Olivecrona, Acoustic tumors, *J. Neurosurg.* 86 (1987) 6–13.
- [19] J. Wazen, H. Silverstein, H. Norrell, B. Besse, Preoperative and postoperative growth rates in acoustic neuromas documented with CT scanning, *Otolaryngol. Head. Neck Surg.* 93 (1985) 151–155.
- [20] R.J. Wiet, R.P. Kazan, I. Giric, P.D. Littlefield, Acoustic neuroma (vestibular schwannoma) revision, *Otolaryngol. Clin. N. Am.* 39 (2006) 751–762.
- [21] H. Nakatomi, J.T. Jacob, M.L. Carlson, S. Tanaka, M. Tanaka, N. Saito, et al., Long-term risk of recurrence and regrowth after gross-total and subtotal resection of sporadic vestibular schwannoma, *J. Neurosurg.* 19 (May) (2017) 1–7.
- [22] N. Goksu, Y. Bayazit, Y. Kemaloglu, Endoscopy of the posterior fossa and endoscopic dissection of acoustic neuroma, *Neurosurg. Focus* 6 (Apr. (4)) (1999) e15.
- [23] M.I. Syed, A. Wolf, O. Ilan, C.O. Hughes, J. Chung, M. Tymianski, et al., The behaviour of residual tumour after the intentional incomplete excision of a vestibular schwannoma: is it such a bad thing to leave some behind? *Clin. Otolaryngol.* 42 (Feb. (1)) (2017) 92–97.
- [24] A.K. Chiluwal, A. Rothman, M. Svrakic, A.R. Dehdashti, Surgical outcome in smaller symptomatic vestibular schwannomas. Is there a role for surgery? *Acta Neurochir. (Wien)* 160 (Nov. (11)) (2018) 2263–2275.
- [25] S. Cheng, Y. Nidoo, M. da Cruz, M. Dexter, Quality of life in postoperative vestibular schwannoma patients, *Laryngoscope* 119 (Nov. (11)) (2009) 2252–2257.
- [26] A.K. Lalwani, F.Y. Butt, R.K. Jackler, L.H. Pitts, C.D. Yingling, Facial nerve outcome after acoustic neuroma surgery: a study from the era of cranial nerve monitoring, *Otolaryngol. Head. Neck Surg.* 111 (1999) 561–570.
- [27] H. Tokimura, S. Sugata, H. Yamahata, S. Yunoue, R. Hanaya, K. Arita, Intraoperative continuous monitoring of facial motor evoked potentials in acoustic neuroma surgery, *Neurosurg. Rev.* 37 (Oct. (4)) (2014) 669–676.
- [28] C.G. Hadjipanayis, M.L. Carlson, M.J. Link, T.A. Rayan, J. Parish, T. Atkins, et al., Congress of neurological surgeons systematic review and evidence-based guidelines on surgical resection for the treatment of patients with vestibular schwannomas, *Neurosurgery* 82 (Feb. (2)) (2018) E40–E43.
- [29] S. Obaid, I. Nikolaidis, M. Alzahrani, R. Moumdjian, I. Saliba, Morbidity rate of the retrosigmoid versus translabyrinthine approach for vestibular schwannoma resection, *J. Audiol. Otol.* 22 (Oct. (4)) (2018) 236–243.
- [30] D. Marchioni, D. Soloperto, B. Masotto, C. Fabbris, S. De Rossi, D. Villari, et al., Transcranial transpromontorial acoustic neuroma surgery: results and facial nerve outcomes, *Otol. Neurotol.* 39 (Feb. (2)) (2018) 242–249.
- [31] D.E. Brackmann, R.D. Cullen, L.M. Fisher, Facial nerve function after translabyrinthine vestibular schwannoma surgery, *Otolaryngol. Head. Neck Surg.* 136 (2007) 773–777.
- [32] E. Suero Molina, A.T.C.J. van Eck, C. Sauerland, S. Schipmann, G. Horstmann, W. Stummer, et al., Local tumor control and clinical symptoms after gamma knife radiosurgery for residual and recurrent vestibular schwannomas, *World Neurosurg.* 122 (Feb) (2019) e1240–e1246.
- [33] C.H. Hahn, S.E. Stangerup, P. Caye-Thomasen, Residual tumour after vestibular schwannoma surgery, *J. Laryngol. Otol.* 127 (Jun. (6)) (2013) 568–573.
- [34] C.K. Park, H.W. Jung, J.E. Kim, Y.J. Son, S.H. Paek, D.G. Kim, Therapeutic strategy for large vestibular schwannomas, *J. Neurooncol.* 77 (2006) 167–171.
- [35] R. Ramina, M. Coelho Neto, K.C. Bordignon, T. Mattei, R. Clemente, P.H. Pires Aguiar, Treatment of large and giant residual and recurrent vestibular schwannomas, *Skull Base* 17 (Mar. (2)) (2007) 109–117.
- [36] M.S. Schwartz, E. Kari, B.M. Strickland, K. Berliner, D.E. Brackmann, J.W. House, et al., Evaluation of the increased use of partial resection of large vestibular schwannomas: facial nerve outcomes and recurrence/regrowth rates, *Otol. Neurotol.* 34 (2013) 1456–1464.

- [37] C.W. Beatty, M.J. Ebersold, S.G. Harner, Residual and recurrent acoustic neuromas, *Laryngoscope* 97 (Oct. (10)) (1987) 1168–1171.
- [38] M. Bailo, N. Boari, F. Gagliardi, A. Franzin, M. Piloni, A. Spina, et al., Gamma knife radiosurgery for residual and recurrent vestibular schwannomas after previous surgery: clinical results in a series of 90 patients and review of the literature, *World Neurosurg.* 98 (Feb) (2017) 60–72.
- [39] *Cochrane Handbook for Systematic Reviews of Interventions*, The Cochrane Collaboration, 2020 Available at: www.cochrane.org/resources/handbook.
- [40] J.P. Ioannidis, Differentiating biases from genuine heterogeneity: distinguishing artefactual from substantive effects, in: H.R. Rothstein, A.J. Sutton, M. Borenstein (Eds.), *Publication Bias in Meta-Analysis: Prevention, Assessment and Adjustments*, John Wiley & Sons, Sussex, 2005, pp. 287–302.
- [41] J.P.A. Ioannidis, T.A. Trikalinos, The appropriateness of asymmetry tests for publication bias in meta-analyses: a large survey, *CMAJ* 176 (2007) 1091–1096.
- [42] N. Terrin, C.H. Schmid, J. Lau, I. Olkin, Adjusting for publication bias in the presence of heterogeneity, *Stat. Med.* 22 (2003) 2113–2126.