

Closure Technology) study showed that significant peri-device flow >5 mm occurred only in 1% of patients on 1-year TEE. In our study, 1 patient (0.5%) developed significant peri-device flow on 45-day TEE, and none had DRT.

For WATCHMAN programs that deviate from standard warfarin regimen post-LAAC, DRT is more common with single/dual antiplatelet therapy than OAC (warfarin and DOACs) (3). The rates of DRT were similar in patients receiving DOAC (0.9%) compared with warfarin (0.5%) in a retrospective multicenter study (4). Thus, a 45-day assessment may be more relevant in patients receiving single/dual antiplatelet therapy post-LAAC. Additionally, it calls into question the current practice of assessing DRT while on OAC at 45 days. It may be more reasonable to assess for DRT after discontinuation of OAC. This specific question requires further investigation.

In this retrospective analysis, we showed that the incidence of significant peri-device flow and DRT at 45 days is very low. Thus, a 45-day TEE post-WATCHMAN implantation may not be necessary for all patients, and OAC may be safely discontinued at 45 days without a TEE. Currently, the National Cardiovascular Data Registry Left Atrial Appendage Occlusion Registry requires documentation of device closure and absence of DRT at 45 days post-LAAC. Computed tomography is a reasonable alternative to TEE for device surveillance (5). In our opinion (not supported by the present study), the rationale for foregoing a 45-day TEE should also extend to the baseline TEE before LAAC. Use of computed tomography may be considered. Amid the COVID-19 pandemic, deferring 45-day TEE post-WATCHMAN implantation has the potential to minimize use of personal protective equipment and reduce preventable risks of viral transmission. Prospective trials are warranted to see whether this practice should be reconsidered even after the pandemic subsides (2).

Bryan E-Xin Tan, MD  
Jeremiah P. Depta, MD, MPH\*  
Bipul Baibhav, MD  
Deepak L. Bhatt, MD, MPH

\*Sands Constellation Heart Institute

Rochester Regional Health  
1425 Portland Avenue  
Rochester, New York 14621

E-mail: [Jeremiah.Depta@rochesterregional.org](mailto:Jeremiah.Depta@rochesterregional.org)

<https://doi.org/10.1016/j.jcmg.2020.05.015>

© 2020 Published by Elsevier on behalf of the American College of Cardiology Foundation.

Dr. Depta has been a consultant and on advisory boards for Edwards Lifesciences LLC, Boston Scientific, and WL Gore & Associates. Dr. Bhatt has been on advisory

boards for Cardax, Cereno Scientific, Elsevier Practice Update Cardiology, Level Ex, Medscape Cardiology, PhaseBio, PLx Pharma, Regado Biosciences; has been a member of the Board of Directors for Boston VA Research Institute, Society of Cardiovascular Patient Care, TobeSoft; has been Chair of the American Heart Association Quality Oversight Committee; is on Data Monitoring Committees for Baim Institute for Clinical Research (formerly Harvard Clinical Research Institute, for the PORTICO trial, funded by St. Jude Medical, now Abbott), Cleveland Clinic (including for the EXCEED trial, funded by Edwards), Duke Clinical Research Institute, Mayo Clinic, Mount Sinai School of Medicine (for the ENVISAGE trial, funded by Daiichi Sankyo), Population Health Research Institute; has received honoraria from the American College of Cardiology (Senior Associate Editor, Clinical Trials and News, [ACC.org](http://ACC.org); Vice-Chair, ACC Accreditation Committee), Baim Institute for Clinical Research (formerly Harvard Clinical Research Institute; RE-DUAL PCI clinical trial steering committee funded by Boehringer Ingelheim; AEGIS-II executive committee funded by CSL Behring), Belvoir Publications (Editor in Chief, Harvard Heart Letter), Duke Clinical Research Institute (clinical trial steering committees, including for the PRONOUNCE trial, funded by Ferring Pharmaceuticals), HMP Global (Editor in Chief, *Journal of Invasive Cardiology*), *Journal of the American College of Cardiology* (Guest Editor; Associate Editor), Medtelligence/ReachMD (CME steering committees), Level Ex, MJH Life Sciences, Population Health Research Institute (for the COMPASS operations committee, publications committee, steering committee, and USA national coleader, funded by Bayer), Slack Publications (Chief Medical Editor, *Cardiology Today's Intervention*), Society of Cardiovascular Patient Care (Secretary/Treasurer), WebMD (CME steering committees); Other: Clinical Cardiology (Deputy Editor), NCDR-ACTION Registry Steering Committee (Chair), VA CART Research and Publications Committee (Chair); has received grants from Abbott, Afimmune, Amarin, Amgen, AstraZeneca, Bayer, Boehringer Ingelheim, Bristol-Myers Squibb, Cardax, Chiesi, CSL Behring, Eisai, Ethicon, Ferring Pharmaceuticals, Forest Laboratories, Fractyl, Idorsia, Ironwood, Ischemix, Lexicon, Lilly, Medtronic, Pfizer, PhaseBio, PLx Pharma, Regeneron, Roche, Sanofi Aventis, Synaptic, The Medicines Company; has received royalties from Elsevier (Editor, *Cardiovascular Intervention: A Companion to Braunwald's Heart Disease*); is Site Co-Investigator for Biotronik, Boston Scientific, CSI, St. Jude Medical (now Abbott), Svelte; is a Trustee of the American College of Cardiology; and is involved in unfunded Research with FlowCo, Merck, Novo Nordisk, and Takeda. All other authors have reported that they have no relationships relevant to the contents of this paper to disclose. The authors attest they are in compliance with human studies committees and animal welfare regulations of the authors' institutions and Food and Drug Administration guidelines, including patient consent where appropriate. For more information, visit the [JACC: Cardiovascular Imaging author instructions page](https://www.jacc.org/author-instructions).

## REFERENCES

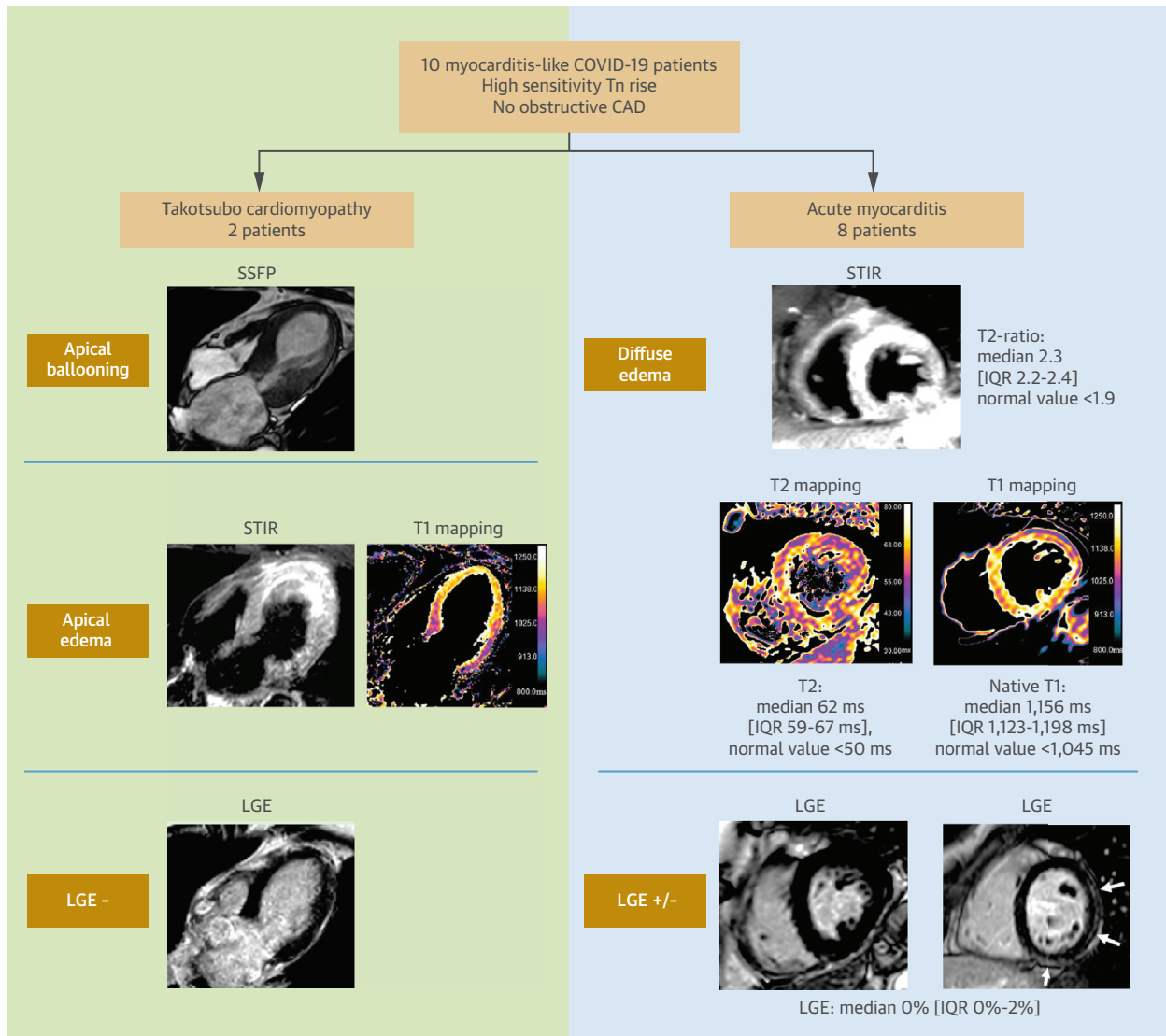
- Kirkpatrick JN, Mitchell C, Taub C, Kort S, Hung J, Swaminathan M. ASE statement on protection of patients and echocardiography service providers during the 2019 novel coronavirus outbreak. *J Am Coll Cardiol* 2020;75:3078-84.
- Wang X, Bhatt DL. COVID-19: an unintended force for medical revolution? *J Invasive Cardiol* 2020;32:E81-2.
- Søndergaard L, Wong YH, Reddy VY, et al. Propensity-matched comparison of oral anticoagulation versus antiplatelet therapy after left atrial appendage closure with WATCHMAN. *J Am Coll Cardiol Intv* 2019;12:1055-63.
- Enomoto Y, Gadiyaram VK, Gianni C, et al. Use of non-warfarin oral anti-coagulants instead of warfarin during left atrial appendage closure with the Watchman device. *Heart Rhythm* 2017;14:19-24.
- Qamar SR, Jalal S, Nicolaou S, Tsang M, Gilhofer T, Saw J. Comparison of cardiac computed tomography angiography and transoesophageal echocardiography for device surveillance after left atrial appendage closure. *Euro-Intervention* 2019;15:663-70.

## Cardiac Magnetic Resonance Characterization of Myocarditis-Like Acute Cardiac Syndrome in COVID-19



Novel coronavirus infection causes a systemic disease (coronavirus disease-2019 [COVID-19]) with, most frequently, respiratory involvement. In addition to systemic and respiratory complications, COVID-19 can reveal itself as a myocarditis-like syndrome

**FIGURE 1** CMR Findings In SARS-Cov-2+ Patients With a Myocarditis-Like Syndrome, With Acute Myocardial Injury in the Absence of Obstructive Coronary Artery Disease



CMR = cardiac magnetic resonance; COVID-19 = coronavirus disease-2019; IQR = interquartile range; LGE = late gadolinium enhancement; SARS-Cov-2 = severe acute respiratory syndrome-coronavirus-2; SSFP = steady state free precession; STIR = short tau inversion recovery; T2-ratio = myocardial/skeletal muscle intensity ratio; Tn = troponin.

(AMCovS), whose underlying mechanism is largely unknown. A limited number of case reports have described cardiac magnetic resonance (CMR) findings in AMCovS; only 2 of which included mapping (1,2).

This paper reports the first series of patients with AMCovS (n = 10; 8 females and 2 males; 52 ± 6 years of age) consecutively referred for CMR for suspected myocarditis between March 15 and April 20, 2020, in 4 Italian university hospitals. Local ethical committees approved or waived specific study approval, and the

study was conducted according to tenets of the Declaration of Helsinki. Eight of 10 patients (80%) experienced oppressive chest pain. The remaining 2 patients had dyspnea. All patients had unremarkable cardiological history and a low rate of cardiovascular risk factors (median 0 [interquartile range (IQR): 0 to 1]). High-sensitivity troponin (hsTn) concentrations were elevated (median hsTn T in 4 patients was 120 ng/l [IQR: 103 to 157 ng/l]; normal value <14 ng/l; median hsTn I value in 6 patients

was 1,626 ng/l [IQR: 1,340 to 2,538 ng/l]; normal value <40 ng/l). Electrocardiography alterations were observed in 8 of 10 patients, with ST-segment elevation in 6 of 10, ST depression in 1 of 10, and T-wave inversions in 1 of 10.

Obstructive coronary artery disease was excluded with invasive coronary angiography in the 8 patients with electrocardiography abnormalities. Furthermore, obstructive coronary artery disease was excluded with coronary computed tomography angiography in 1 patient with reduced ejection at echocardiography in the absence of electrocardiography alterations. Coronary artery disease was not investigated in 1 patient because there were no electrocardiographic and echocardiographic alterations.

All patients underwent CMR (1.5-T in 9 patients and 3-T in 1 patient) within 1 week from troponin rise and onset of cardiac symptoms (median of 3 days [IQR: 2 to 4 days]). CMR protocol included multiplanar cine imaging, short-tau inversion recovery (STIR), and late gadolinium enhanced (LGE) imaging. Native T1 and T2 mapping were available in 8 of 10 patients.

Cine images revealed normal left ventricle end-diastolic volume in all patients (median 67 ml/m<sup>2</sup> [IQR: 60 to 76 ml/m<sup>2</sup>]; normal value <90 ml/m<sup>2</sup>). Two patients, both females, 58 and 61 years of age, had severe depression of systolic function (ejection fraction <40%) with apical ballooning, apical edema, and absent LGE, suggesting Takotsubo cardiomyopathy. Both of these patients experienced a complete left ventricular function recovery in a few days.

The remaining 8 patients (6 females and 2 males; 50 ± 14 years of age) had no segmental wall motion abnormalities. Five patients had preserved ejection fraction (>55%), and 3 patients had mildly reduced ejection fraction (40% to 55%). In all cases, CMR showed diffuse intense myocardial edema, with increased myocardial-to-skeletal muscle intensity ratio on STIR images (median T2-ratio: 2.3 [IQR: 2.2 to 2.4]; normal value <1.9), increased native-T1 mapping (at 1.5-T: median 1,156 ms [IQR: 1,123 to 1,198 ms]; normal value <1,045 ms; at 3-T: 1,378 ms; normal value <1,240 ms) and increased T2 mapping (median 62 ms [IQR: 59 to 67 ms]; normal value <50 ms). (Figure 1). Extracellular volume fraction was only available for 2 of 10 cases. In both cases, the extracellular volume fraction was elevated (30% and 36%, respectively) as was native T1 and T2. Two patients had borderline wall thickening (wall thickness of 13 mm in both cases) in regions of intense edema and mild dysfunction.

Mild pericardial effusion was present in 6 of 8 patients (75%) (median: 5 mm [IQR: 3 to 11 mm]) without evidence of pericardial thickening (≤3 mm).

Surprisingly, LGE images were unremarkable (median 0% [IQR: 0% to 2%]). LGE images were completely negative in 5 of 8 patients. In the remaining 3 patients, a few thin and shadowed sub-epicardial striae of LGE were detectable in the lateral wall, accounting for 1%, 3%, and 3% of LV mass respectively (Figure 1).

Based on updated 2018 Lake Louise criteria, CMR findings, including T1 and T2 myocardial markers, resulted in diagnoses of acute myocarditis in all 8 patients.

All patients were discharged at the time of writing, with regression of cardiac injury markers and left ventricular functional recovery. Nevertheless, no prognoses could be inferred because of the limited population size.

The absence or very minimal amount of LGE observed in these patients with AMCoV agrees with the few histological results published to date, reporting limited or absent myocyte necrosis (1,3), and may suggest an indirect mechanism causing myocardial inflammation. Endomyocardial biopsy was not performed in the present patients, in consideration of clinical stability and rapid functional recovery.

This series suggests inflammation as a possible substrate underlying myocardial injury in COVID-19 patients. Diffuse edema can be the only CMR hallmark of myocardial inflammation in COVID-19, because LGE may be completely absent or minimal, revealing unremarkable myocyte necrosis.

Antonio Esposito, MD\*  
Anna Palmisano, MD  
Luigi Natale, MD  
Guido Ligabue, MD  
Giovanni Peretto, MD  
Luigi Lovato, MD  
Davide Vignale, MD  
Federica Fiocchi, MD  
Riccardo Marano, MD  
Vincenzo Russo, MD

\*Experimental Imaging Center, Radiology Unit  
IRCCS San Raffaele Hospital and Scientific Institute  
Vita-Salute San Raffaele University  
Via Olgettina 58-60  
20132 Milan  
Italy

E-mail: [esposito.antonio@hsr.it](mailto:esposito.antonio@hsr.it)  
<https://doi.org/10.1016/j.jcmg.2020.06.003>

The authors have reported that they have no relationships relevant to the contents of this paper to disclose.

The authors attest they are in compliance with human studies committees and animal welfare regulations of the authors' institutions and Food and Drug Administration guidelines, including patient consent where appropriate. For more information, visit the [JACC: Cardiovascular Imaging author instructions page](#).

## REFERENCES

1. Sala S, Peretto G, Gramegna M, et al. Acute myocarditis presenting as a reverse Tako-Tsubo syndrome in a patient with SARS-CoV-2 respiratory infection. *Eur Heart J* 2020;41:1861-2.
2. Inciardi RM, Lupi L, Zaccone G, et al. Cardiac involvement in a patient with coronavirus disease 2019 (COVID-19). *JAMA Cardiol* 2020;5: 819-24.
3. Tavazzi G, Pellegrini C, Maurelli M, et al. Myocardial localization of coronavirus in COVID-19 cardiogenic shock. *Eur J Heart Fail* 2020;22:911-5.

## Innovative Transthoracic Echocardiographic Imaging on Prone Ventilated Patients With COVID-19 Using a Transesophageal Probe



Coronavirus disease-2019 (COVID-19) is causing severe pneumonia leading to acute respiratory distress syndrome, a condition where prone ventilation for >12 h/day has proven beneficial (1). Transthoracic echocardiography (TTE) to assess COVID-19-related cardiac complications (2) is very challenging for patients in the prone position. The aim of this study was to examine the feasibility of an innovative use of a transesophageal echocardiography (TEE) probe to perform TTEs in patients with COVID-19 who were invasively ventilated in the prone position.

Twenty-one patients were examined. All scans were performed using an Affiniti or CVx system and the X7-2t or X8-2t TEE probes (Philips Healthcare, Andover, Massachusetts). In a small number of patients, several frequencies and harmonics were tested. The low fundamental frequency ("Pen" selection: 2.4 MHz) was found to provide the best image quality as visually assessed by 2 operators. The average duration of a scan with the TEE probe was 16 ± 3 min. In 18 of 21 patients (85.7%), conventional TTEs were performed using the same ultrasound machines and the S5-1 TTE probe (Philips) with the patients in the supine position. For those scans, the operators selected the frequency and harmonic functions based upon their discretion for optimal visualization (HGen: 1.6/3.2 MHz or HPen: 1.3/2.6 MHz). The studies were performed as part of routine clinical assessment or under ethical approval granted by the National Health Service Health Research Authority (REC20/EE/0131). The mean time between the 2 examinations was 3.6 days (range 0 to 12 days) and the order of the scans in each patient was random.

In order to acquire transthoracic images with the TEE probe, the operator stood on the left side of the patient at the level of their head, facing the patient's right side and caudally (Figure 1A). The probe was slid between the bed mattress and the patient's chest wall. Ultrasound gel was applied to the transducer surface. The direction of the probe was oblique from the patient's shoulder toward the mid-sternum. The transducer faced upward and was supported underneath by the operator's left hand. The probe shaft was held with the right hand to allow rotation, and the machine was operated by another operator. The tip of the probe was placed in the conventional left parasternal position, in the third or fourth left intercostal space. Images of the long axis of the heart were obtained at zero angle as in the conventional TTE parasternal long-axis view (Figure 1B). By increasing the angle to 60-120 degrees, a short axis view of the heart could be obtained, usually at the level of the mitral valve. Rotating the probe clockwise, the mid-papillary level and apical short axis views were obtained (Figure 1B), whereas with counterclockwise rotation, the great arteries were imaged. The application of color Doppler and pulsed and/or continuous wave Doppler allowed assessment of flow (Figure 1C).

The majority of patients were male (81%) and 48% were black. The mean age of the cohort was 55.9 ± 7.7 years, and the mean body mass index was 28.0 ± 4.6 kg/m<sup>2</sup>. Three patients (14.3%) had a history of coronary artery disease, 5 (23.8%) were diabetic, 3 (14.3%) were smokers, and 4 (19.1%) had a history of lung disease.

The TEE and TTE probe echocardiograms were reviewed and interpreted independently by 2 blinded readers, and the image quality was graded as poor, fair, or good, by using criteria previously described (3). From the TEE probe scans, 4 were graded as nondiagnostic (19.0%), 5 were poor (23.8%), 1 was fair (4.8%), and 11 were good (52.4%). From the 4 echocardiograms performed using the TEE probe, which were nondiagnostic, 2 correlated to poor conventional TTE image quality (both on female patients), and in the other 2, the conventional TTE was also nondiagnostic (both on male patients). The poor quality TEE probe scans corresponded to 3 poor and 1 good quality TTE probe scans (in 1 patient, a TTE probe scan was not available). The fair quality TEE probe scan corresponded to a fair quality TTE scan, and the 11 good quality TEE probe scans correlated to 1 fair and 8 good quality TTE probe scans (in 2 patients, TTE probe scans were not available).