



BRIEF REPORT

VEXAS Syndrome: A Case Series From a Single-Center Cohort of Italian Patients With Vasculitis

Francesco Muratore,¹ Chiara Marvisi,² Paola Castrignanò,² Davide Nicoli,¹ Enrico Farnetti,¹ Orsola Bonanno,¹ Rosina Longo,¹ Piera Zaldini,¹ Elena Galli,² Nicholas Balanda,³ David B. Beck,³ Peter C. Grayson,⁴  Nicolò Pipitone,¹ Luigi Boiardi,¹ and Carlo Salvarani² 

Objective. To identify patients with VEXAS syndrome (vacuoles, E1 enzyme, X-linked, autoinflammatory, somatic syndrome) from a single-center cohort of Italian patients with vasculitis, using a clinically oriented phenotype-first approach.

Methods. We retrospectively reviewed the clinical records of 147 consecutive male patients followed up in our vasculitis clinic from 2013 to date. All patients with a diagnosis of vasculitis and treatment-resistant manifestations of inflammation, persistently elevated inflammation markers, and hematologic abnormalities were identified. Bone marrow aspirates were examined for the presence of vacuoles. Sequencing of ubiquitin-activating enzyme E1 (UBA-1) was performed using genomic DNA from peripheral blood leukocytes or bone marrow tissue.

Results. Seven patients with vasculitis and concomitant features of VEXAS syndrome were identified. A final diagnosis of VEXAS syndrome was made in 3 of the 5 patients who underwent sequencing of UBA-1 (diagnosis was made postmortem for 1 patient). In all 3 patients, examination of the bone marrow aspirate revealed vacuoles characteristic of VEXAS syndrome, and all 3 patients met the definitive World Health Organization criteria for myelodysplastic syndrome. Cytogenetic analysis showed normal karyotypes in all 3 patients.

Conclusion. To our knowledge, this is the first report of VEXAS syndrome associated with antineutrophil cytoplasmic antibody (ANCA)-associated vasculitis. Our data emphasize the need to consider VEXAS syndrome when evaluating patients with various forms of systemic vasculitis. The novel association between VEXAS syndrome and ANCA-associated vasculitis reported herein warrants further investigation.

INTRODUCTION

Using a genotype-first approach, researchers recently identified somatic mutations affecting methionine 41 in the X-linked gene *UBA1*, which encodes ubiquitylation initiating E1 enzyme, in men with late-onset, treatment-refractory inflammatory syndrome and hematologic abnormalities. Clinical findings included recurrent fever, skin involvement, pulmonary infiltrate, ear and nose chondritis, venous thromboembolism, hematologic abnormalities, and bone marrow vacuoles. Most of the patients in this

population met the diagnostic criteria for various inflammatory syndromes and/or hematologic conditions, including relapsing polychondritis, myelodysplastic syndrome (MDS), polyarteritis nodosa, and giant cell arteritis. This disorder was named VEXAS syndrome (vacuoles, E1 enzyme, X-linked, autoinflammatory, somatic syndrome) (1). Since the initial description of the syndrome, pathogenic UBA-1 variants have been identified in 2 cohorts of patients with relapsing polychondritis (7.6% and 69% of cases, respectively) (2,3). The aim of the present study was to use a clinically oriented, phenotype-first approach to

¹Francesco Muratore, MD, Davide Nicoli, MD, PhD, Enrico Farnetti, MD, PhD, Orsola Bonanno, MD, Rosina Longo, MD, Piera Zaldini, MD, Nicolò Pipitone, MD, PhD, Luigi Boiardi, MD, PhD: Azienda Unità Sanitaria Locale-IRCCS di Reggio Emilia, Reggio Emilia, Italy; ²Chiara Marvisi, MD, Paola Castrignanò, MD, Elena Galli, MD, Carlo Salvarani, MD: Azienda Unità Sanitaria Locale-IRCCS di Reggio Emilia, Reggio Emilia, Italy, and Università di Modena e Reggio Emilia, Modena, Italy; ³Nicholas Balanda, BSc, David B. Beck, MD, PhD: National Human Genome Research Institute, NIH, Bethesda, Maryland; ⁴Peter C. Grayson, MD: National Institute of Arthritis and Musculoskeletal and Skin Diseases, NIH, Bethesda, Maryland.

Drs. Muratore and Marvisi contributed equally to this work.

Author disclosures are available at <https://onlinelibrary.wiley.com/action/downloadSupplement?doi=10.1002%2Fart.41992&file=art41992-sup-0001-Disclosureform.pdf>.

Address correspondence to Carlo Salvarani, MD, Department of Rheumatology, Azienda Unità Sanitaria Locale-IRCCS di Reggio Emilia, Viale Risorgimento 80, 42123 Reggio Emilia, Italy. Email: Salvarani.carlo@ausl.re.it.

Submitted for publication June 3, 2021; accepted in revised form October 1, 2021.

identify patients with VEXAS syndrome in a single-center cohort of Italian patients with vasculitis.

PATIENTS AND METHODS

Study subjects. To identify patients with suspected/confirmed vasculitis and clinical features of VEXAS syndrome, the clinical records of all consecutive male patients followed up in our vasculitis clinic from 2013 to date were retrospectively reviewed. The vasculitis clinic is part of the division of rheumatology at the Hospital of Reggio Emilia, which is a large tertiary care referral center for Italian patients with vasculitides.

Patients satisfying all the following criteria were included in the study: 1) recurrent fever and at least 1 of the following: skin involvement, pulmonary infiltrate, ear or nose chondritis, or venous thromboembolism; 2) a C-reactive protein (CRP) level of >20 mg/liter and at least 1 of the following: macrocytic anemia (hemoglobin value <12 gm/dl and mean corpuscular volume [MCV] >100 fl), thrombocytopenia (platelet count <130,000/mm³), neutropenia (neutrophil count <1,500/mm³), or a hematologic diagnosis of myelodysplastic syndrome (MDS); and 3) failure to respond to at least 1 synthetic or biologic disease-modifying antirheumatic drug (DMARD) and ongoing need for glucocorticoid therapy. Bone marrow aspirates from all patients included in the study were reviewed for the presence of the characteristic vacuoles restricted to myeloid and erythroid precursor cells (1). Sequencing of *UBA1* was performed using genomic DNA from peripheral blood leukocytes or bone marrow tissue.

Ethics considerations. The study was approved by the Reggio Emilia Provincial Ethics Committee. Written informed consent was obtained from all patients or their legal guardians.

Genetic screening. Genomic DNA was obtained from peripheral whole blood and formalin-fixed paraffin-embedded slides from bone marrow biopsies according to the standard procedures of the Maxwell 16 DNA extraction kit (Promega). We designed a new primer pair using Primer3Plus software to amplify a 251-bp region of *UBA1* exon 3 containing a mutation at p.Met41* (5'-TGGGTGGGAAAGTCTTTTGT-3' [forward] and 5'-CTGCCAGGTTAGGGGGTACT-3' [reverse]). Sequencing was performed on an Applied Biosystems 3500 Dx Series DNA analyzer using an ABI Prism BigDye Terminator v3.1 kit.

To verify our findings, additional whole blood and bone marrow samples from the patients were sent to the National Human Genome Research Institute laboratory at the National Institutes of Health. All *UBA1* mutations we found were confirmed.

In 1 individual (patient 2) who was not shown to have a *UBA1* mutation by Sanger sequencing, exome sequencing was performed to an average coverage of 100× (1). DNA raw reads were

aligned to the human genome reference GRCh38 using BWA-MEM2 (4). Somatic variant calling was performed on aligned reads using the Genome Analysis Toolkit Mutect2 (5). Germline variant assessment in *UBA1* was performed using the Integrative Genomics Viewer.

RESULTS

During the study period, 147 male patients were followed up in our vasculitis clinic. Of the 147 patients, 142 received the following diagnoses: large vessel vasculitis (55 patients), antineutrophil cytoplasmic antibody (ANCA)-associated vasculitis (36 patients), Behçet's syndrome (30 patients), primary central nervous system vasculitis (7 patients), cryoglobulinemic vasculitis (5 patients), polyarteritis nodosa (4 patients), IgA vasculitis (3 patients), and relapsing polychondritis (2 patients). Five additional patients referred for suspected vasculitis (3 for suspected Behçet's syndrome and 2 for suspected polyarteritis nodosa) received a final diagnosis of undifferentiated inflammatory syndrome with vasculitis features (6) when a vasculitis diagnosis could not be confirmed.

Seven of the 147 patients satisfied the inclusion criteria and were included in the study. Demographic and clinical characteristics of these patients are reported in Table 1. Patient 1 died before VEXAS syndrome had been described, and no bone marrow tissue or peripheral blood samples were available for genetic screening. Bone marrow aspirates from patient 2 did not show evidence of vacuolization, and genetic screening, both by Sanger and exome sequencing, did not reveal the previously reported pathogenic *UBA1* variant (2) or any candidate disease-causing variants. Examination of bone marrow aspirates from both patient 3 and patient 4 revealed evidence of vacuolization restricted to myeloid and erythroid precursor cells. Genetic screening by Sanger sequencing did not reveal the previously reported pathogenic *UBA1* variants in patient 3, and exome sequencing was not performed in this patient because there was not enough DNA available. Genetic screening was not performed in patient 4 because samples of bone marrow tissue or peripheral blood were not available. Mosaicism in other tissues was not investigated for patients 3 and 4. Finally, examination of bone marrow aspirates and genetic screening revealed vacuolization and *UBA1* somatic mutations in patients 5, 6, and 7. These patients received a final diagnosis of VEXAS syndrome (the diagnosis of patient 5 was made postmortem).

Case series. Patient 5. Patient 5, a 71-year-old man, was admitted to our vasculitis clinic with relapsing superficial and deep venous thrombosis, arthritis of the wrists, recurrent fever, weight loss, dyspnea, skin lesions, and testicular pain. These symptoms had begun 2 years prior and responded to high doses of glucocorticoids, but recurred each time the prednisone dosage was

Table 1. Demographic and clinical characteristics of the identified patients*

Characteristic	Patient						
	1	2	3	4	5	6	7
Age at onset, years	76	46	53	72	67	72	64
Death (age at death, years)	+ (79)	-	+ (59)	+ (74)	+ (75)	-	-
<i>UBA1</i> mutation	NT	-	-	NT	c.122 T>C, p.Met41Thr	c.121 A>G, p.Met41Val	c.122 T>C, p.Met41Thr
Key features							
Fever	+	+	+	+	+	+	+
Skin involvement	+	-	+	+	+	-	+
Pulmonary infiltrates	-	+	+	+	+	+	+
Ear/nose chondritis	-	-	-	-	-	-	+
DVT	+	+	-	+	+	-	+
Bone marrow vacuoles	NT	-	+	+	+	+	+
Macrocytic anemia	+	-	+	+	+	+	+
Other	Lobular panniculitis, testicular pain	Genital aphthosis		Testicular pain	Arthritis, testicular pain		Arthritis
Laboratory findings							
CRP, mg/liter	180	41	153	120	180	250	140
ESR, mm/hour	83	63	50	133	112	137	78
Treatment							
sDMARDs	AZA	AZA, CYC	MTX, AZA	AZA	AZA	CYC, MMF	MTX, AZA
b/tsDMARDs	ADA, IFX, ANK	IFX	RTX	-	ANK, RTX	RTX	upadacitinib
GCS	+	+	+	+	+	+	+
Clinical diagnosis							
Behçet's syndrome	-	+	-	-	-	-	-
RP	-	-	-	-	-	-	+
LCV	-	-	-	+	-	-	-
AAV	-	-	-	-	-	+	-
UIS	+	-	+	-	+	-	-
MDS	-	-	+	+	+	+	+

* NT = not tested; DVT = deep venous thrombosis; CRP = C-reactive protein; ESR = erythrocyte sedimentation rate; sDMARDs = synthetic disease-modifying antirheumatic drugs; AZA = azathioprine; CYC = cyclophosphamide; MTX = methotrexate; MMF = mycophenolate mofetil; b/tsDMARDs = biologic/targeted synthetic disease-modifying antirheumatic drugs; ADA = adalimumab; IFX = infliximab; ANK = anakinra; RTX = rituximab; GCS = glucocorticoids; RP = relapsing polychondritis; LCV = leukocytoclastic vasculitis; AAV = antineutrophil cytoplasmic antibody-associated vasculitis; UIS = undifferentiated inflammatory syndrome with vasculitis features; MDS = myelodysplastic syndrome.

reduced to <15 mg/day. Laboratory tests revealed increased levels of acute-phase reactants and macrocytic anemia (Table 1). Skin lesions on the lower leg and upper thigh of both legs were found to be erythematous purpuric, slightly infiltrated macules. Skin biopsy showed mild lymphocytic and granulocytic infiltration of the upper dermis without vasculitis. Computed tomography (CT) scan of the chest revealed diffuse bilateral opacities in the lungs. Bronchoalveolar lavage fluid cultures were negative. Examination of bone marrow aspirate revealed findings consistent with MDS with multilineage dysplasia. An initial diagnosis of undifferentiated inflammatory syndrome with vasculitis features was made, and treatment with prednisone (50 mg/day) and azathioprine (2 mg/kg/day) was started.

After 1 year, anakinra at 100 mg/day was added to the patient's treatment regimen due to the recurrence of inflammatory symptoms with prednisone dosages of <25 mg/day. Treatment with anakinra was stopped after a few injections because the patient experienced a severe cutaneous reaction. A course of 2 gm of rituximab (2 doses of 1 gm given 2 weeks apart) was subsequently started with no clinical response; thus, high doses of

glucocorticoids were maintained. The patient died in 2019 at the age of 74 years as a result of pulmonary complications. After the description of VEXAS syndrome in 2020 (1), reexamination of the bone marrow aspirate revealed numerous vacuoles in the myeloid and erythroid precursor cells, and DNA sequencing using bone marrow tissue revealed a pathogenic *UBA1* somatic mutation.

Patient 6. Patient 6, a 75-year-old man with a diagnosis of microscopic polyangiitis (MPA), was referred to our vasculitis clinic with persistent fever, weight loss, and dyspnea. MPA had been diagnosed 3 years prior based on renal biopsy showing necrotizing and crescentic glomerulonephritis, the presence of myeloperoxidase-ANCAs (MPO-ANCAs) (28 units/ml [normal range <3.5]), chest CT scan showing diffuse ground-glass opacities, and systemic symptoms. At the onset of symptoms, laboratory evaluations revealed rapidly progressive renal failure, increased levels of acute-phase reactants, and macrocytic anemia (Table 1). Examination of bone marrow aspirate revealed MDS with single-lineage dysplasia. The patient was started on prednisone (1 mg/kg/day) and oral cyclophosphamide

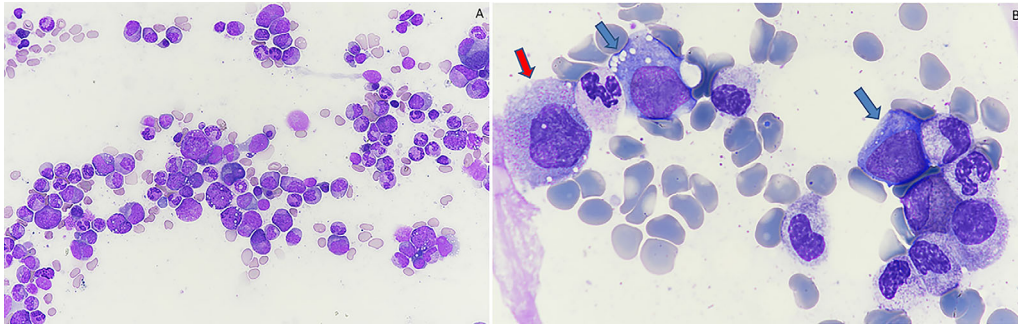


Figure 1. **A**, Bone marrow aspirate from patient 7, showing evidence of dysplasia and cytoplasmic vacuolization of the erythroid and myeloid precursor cells. **B**, Higher-magnification view of the bone marrow aspirate from patient 7, showing dysplasia (neutrophils with pseudo Pelger-Huët anomaly) and cytoplasmic vacuolization of the erythroid precursor cells (blue arrows) and myeloid precursor cells (red arrow). Stained with May-Grünwald-Giemsa stain; original magnification $\times 400$ in **A**; $\times 1,000$ in **B**.

(1.5 mg/kg/day). After 3 months, MPO-ANCAs disappeared, treatment with cyclophosphamide was stopped, and the prednisone dosage was tapered to a maintenance regimen of 5 mg/day.

Two years later, when the patient first presented to us, he was still taking prednisone 5 mg daily and he reported recurrence of fever, weight loss and dyspnea in the last 3 months. Laboratory tests showed increased levels of acute-phase reactants and pancytopenia and results of ANCA testing remained negative. An extensive evaluation excluded infections. Examination of a second bone marrow aspirate revealed findings consistent with MDS with multilineage dysplasia with ring sideroblasts. The prednisone dosage was increased to 1 mg/kg/day and a course of rituximab (2 doses of 1 gm given 2 weeks apart) was given because an MPA flare was suspected. Systemic symptoms recurred at each reduction of the prednisone dosage to <25 mg/day. The patient remained ANCA negative.

After 9 months, the patient was started on mycophenolate mofetil (2 gm/day) and intravenous immunoglobulin (0.4 gm/kg/day for 5 consecutive days every 4 weeks). Six months later, he developed fever and dyspnea became more severe. Chest CT scan showed worsened ground-glass opacities and pleural effusion. Intravenous cyclophosphamide was started (7.5 mg/kg) according to the European Vasculitis Study Group protocol, without clinical response. The patient remained dependent on high-dose glucocorticoids (25 mg/day of prednisone). After the description of VEXAS syndrome in 2020 (1), the 2 bone marrow aspirates from the patient were reviewed and both revealed numerous vacuoles in the myeloid and erythroid precursor cells. DNA sequencing using the last bone marrow aspirate showed a pathogenic mutation in the *UBA1* region and confirmed the diagnosis of VEXAS syndrome.

Patient 7. Patient 7, a 66-year-old man, was referred to our vasculitis clinic in 2019 with fever, deep venous thrombosis, arthritis of the wrists, dyspnea, painful migratory subcutaneous nodules, skin lesions, and recurrent episodes of ear and nose

chondritis. These symptoms had begun 2 years prior and responded to high doses of glucocorticoids, but recurred each time the prednisone dosage was reduced to <15 mg/day. Laboratory tests revealed increased levels of acute-phase reactants and macrocytic anemia (Table 1). Examination of bone marrow aspirate revealed features suggestive of MDS with multilineage dysplasia. Skin lesions on the upper thighs were found to be erythematous purpuric, slightly infiltrated macules. A diagnosis of relapsing polychondritis was made, and the patient was started on prednisone (0.5 mg/kg/day) and methotrexate (15 mg/week). The patient's systemic and cutaneous manifestations recurred each time the prednisone dosage was reduced to <15 mg/day. A skin biopsy showed lymphocytic and granulocytic infiltration of small vessels with fibrinoid necrosis. CT scan of the chest revealed diffuse pulmonary infiltrates. Treatment with methotrexate was stopped and the patient was started on azathioprine (2 mg/kg/day).

In December 2020, a few months after azathioprine treatment was begun, he was admitted to our rheumatology department with swelling of the neck, periorbital edema, diffuse cutaneous nodules, and fever. Examination of bone marrow aspirate revealed vacuoles in the erythroid and myeloid precursors and findings consistent with MDS with multilineage dysplasia (Figures 1A and B). DNA sequencing of the peripheral blood showed a pathogenic mutation in the *UBA1* region and confirmed the diagnosis of VEXAS syndrome. The patient was started on upadacitinib (15 mg/day) and prednisone (50 mg/day). The prednisone dosage was progressively reduced, and in June 2021 the patient had a flare of nasal chondritis while being treated with upadacitinib 15 mg/day and prednisone 10 mg/day. Prednisone was increased to 25 mg/day and symptoms resolved rapidly. At the patient's last follow-up (July 2021), his disease was in remission with upadacitinib 15 mg/day and prednisone 12.5 mg/day. The CRP level was 18 mg/liter, the hemoglobin level was 12.2 gm/dl (MCV 113 fl), and the ferritin level was 361 ng/ml.

DISCUSSION

Using a clinically oriented phenotype-first approach, we identified 7 patients with vasculitis and concomitant treatment-resistant systemic manifestations and hematologic abnormalities consistent with MDS. A final diagnosis of VEXAS syndrome was made in 60% of patients (3 of 5) who underwent sequencing of *UBA1*. In all 3 patients, examination of bone marrow aspirate revealed evidence of the characteristic vacuoles. The 2 patients who were not shown by genetic sequencing to have previously reported pathogenic *UBA1* variants were younger than the patients with a *UBA1* mutation, and only 1 patient (patient 3) had evidence of vacuoles indicative of VEXAS syndrome upon examination of bone marrow aspirate.

Somatic mutations in *UBA1* outside of codon 41 have recently been reported as a cause of VEXAS syndrome, but we could not test for these mutations in patient 3 because there was not enough DNA available to perform exome sequencing (7–9); therefore, the diagnosis of VEXAS syndrome cannot be completely ruled out. Examination of bone marrow tissue from another patient (patient 4) also showed the presence of vacuoles characteristic of VEXAS syndrome, but a DNA sample was unavailable, so the presence of pathogenic *UBA1* variants could not be determined. Our data confirmed that, in the right clinical setting, the presence of vacuoles in bone marrow aspirate is quite specific for VEXAS syndrome. Genetic sequencing for somatic *UBA1* mutations should be performed in all patients with treatment-resistant inflammatory syndrome, hematologic abnormalities, and evidence of vacuoles.

In the present study, definitive World Health Organization criteria for MDS were met by all 5 patients with evidence of vacuoles and by all 3 patients with a final diagnosis of VEXAS syndrome, and MDS diagnosis was confirmed by an expert hemopathologist (10). Investigations for mosaicism in other tissues were not performed in the 2 patients with MDS without VEXAS syndrome. Cytogenetic analysis showed normal karyotypes in all 5 patients. The higher proportion of MDS among patients in the present study compared with the original series described by Beck et al (6 of 25 patients [24%]) (1) may denote the progressive nature of hematologic abnormalities that can evolve into overt hematologic malignancy. Early detection of *UBA1* mutations may therefore identify patients with rheumatic diseases who may benefit from increased hematologic surveillance (2).

Our study confirms that patients with VEXAS syndrome were resistant to multiple DMARDs, and high-dose glucocorticoids were the only treatment that ameliorated severe inflammatory symptoms in the patients studied. Nevertheless, most of the patients died of disease-related causes or complications related to treatment. Transcriptome analysis of the peripheral blood and analysis of cytokines in the serum of patients with VEXAS syndrome showed highly activated inflammatory signatures in multiple pathways, including tumor necrosis factor, interleukin-6, and

interferon- γ (1). Components of the JAK/STAT pathway have been shown to be mutated or up-regulated in several hematologic malignancies, and JAK inhibitors have been approved for use in the treatment of some blood disorders (8). JAK inhibitors target multiple inflammatory cytokines simultaneously, and thus in complex inflammatory states such as VEXAS, JAK inhibitors may be more effective than inhibitors of a single cytokine. We therefore decided to treat patient 7 with the selective JAK1 inhibitor upadacitinib. The drug showed a steroid-sparing effect and a good safety profile. Further studies evaluating the efficacy and safety of JAK inhibitors in the treatment of patients with VEXAS syndrome are needed.

Because VEXAS syndrome is a newly identified genetic disease, knowledge of the complete clinical spectrum of the disease is continuously expanding. To our knowledge, patient 6 in our study represents the first reported case of VEXAS syndrome associated with ANCA-associated vasculitis. Patient 6 had concomitant manifestations of rapidly progressive renal failure, pulmonary involvement, inflammatory manifestations, anti-MPO-ANCA positivity, and myelodysplastic features. A diagnosis of MPA and MDS was made. Despite an initial period of remission, the patient developed inflammatory manifestations resistant to multiple immunosuppressants and requiring high doses of glucocorticoids. Reexamination of the 2 bone marrow aspirates (the first aspiration performed when the MPA diagnosis was made and the second 3 years later when systemic manifestations recurred) revealed numerous vacuoles in the myeloid and erythroid precursor cells. The pathogenic *UBA1* somatic mutation was found using a DNA sample from the second bone marrow aspirate. Unfortunately, the first bone marrow aspirate was unavailable for testing *UBA1* mutations.

Taken together, these findings support the hypothesis of a connection between ANCA-associated vasculitis and VEXAS syndrome, and in our patient a unique evolving condition cannot be excluded, particularly since necrotizing and crescentic glomerulonephritis has not been described in VEXAS syndrome. The link between these 2 conditions may be related to proinflammatory neutrophil activation with dysregulated neutrophil extracellular trap (NET) formation. Increasing research evidence suggests that dysregulated NET formation is central to ANCA-associated vasculitis pathogenesis (11), and functional studies of neutrophils obtained from patients with VEXAS syndrome have recently shown enhanced spontaneous NET formation, findings that confirm that proinflammatory neutrophil activation is also dysregulated in VEXAS syndrome (1).

The main limitation of this study is its retrospective nature. There may have been some selection bias related to the inclusion criteria we used. First, because more than half of the reported patients with VEXAS syndrome do not meet criteria for MDS (12), we could have excluded some patients who did not have significant hematologic abnormalities. Furthermore, since all patients were identified within a vasculitis clinic, there was likely

selection bias toward identification of VEXAS syndrome patients with severe inflammatory disease.

In conclusion, our findings emphasize the need to consider VEXAS syndrome when evaluating patients with many different forms of systemic vasculitis. The novel association between VEXAS syndrome and ANCA-associated vasculitis warrants further investigation.

ACKNOWLEDGMENTS

Open Access Funding provided by Università degli Studi di Modena e Reggio Emilia within the CRUI-CARE Agreement.

AUTHOR CONTRIBUTIONS

All authors contributed to drafting or critically revising the article for intellectual content and approved the final version of the article. Dr. Salvarani had full access to all of the data in the study and takes responsibility for the integrity of the data analysis.

Study conception and design. Muratore, Marvisi, Beck, Grayson, Pipitone, Salvarani.

Acquisition of data. Muratore, Marvisi, Castrignanò, Nicoli, Farnetti, Bonanno, Longo, Galli, Boiardi.

Analysis and interpretation of data. Muratore, Marvisi, Nicoli, Farnetti, Bonanno, Longo, Zaldini, Balanda, Beck, Grayson, Pipitone, Salvarani.

REFERENCES

1. Beck DB, Ferrada MA, Sikora KA, Ombrello AK, Collins JC, Pei W, et al. Somatic mutations in UBA1 and severe adult-onset autoinflammatory disease. *N Engl J Med* 2020;383:2628–38.
2. Ferrada MA, Sikora KA, Luo Y, Wells KV, Patel B, Groarke EM, et al. Somatic mutations in UBA1 define a distinct subset of relapsing polychondritis patients with VEXAS. *Arthritis Rheumatol* 2021;73:1886–95.
3. Tsuchida N, Kunishita Y, Uchiyama Y, Kirino Y, Enaka M, Yamaguchi Y, et al. Pathogenic UBA1 variants associated with VEXAS syndrome in Japanese patients with relapsing polychondritis. *Ann Rheum Dis* 2021 doi: 10.1136/annrheumdis-2021-220089. E-pub ahead of print.
4. Md V, Misra S, Li H, Aluru S. Efficient architecture-aware acceleration of BWA-MEM for multicore systems. *Proc-2019 IEEE 33rd Int Parallel Distrib Process Symp IPDPS 2019* 2019:314–24.
5. Cibulskis K, Lawrence MS, Carter SL, Sivachenko A, Jaffe D, Sougnez C, et al. Sensitive detection of somatic point mutations in impure and heterogeneous cancer samples. *Nat Biotechnol* 2013;31:213–9.
6. Lamprecht P, Pipitone N, Gross WL. Unclassified vasculitis [review]. *Clin Exp Rheumatol* 2011;29 Suppl 64:S81–5.
7. Poulter JA, Collins JC, Cargo C, de Tute RM, Evans P, Cardona DO, et al. Novel somatic mutations in UBA1 as a cause of VEXAS syndrome. *Blood* 2021;137:3676–81.
8. Oganessian A, Jachiet V, Chasset F, Hirsch P, Hage-Sleiman M, Fabiani B, et al. VEXAS syndrome: still expanding the clinical phenotype. *Rheumatology (Oxford)* 2021;60:e321–3.
9. Bourbon E, Heiblig M, Gerfaud-Valentin M, Barba T, Durel CA, Lega JC, et al. Therapeutic options in Vexas syndrome: insights from a retrospective series. *Blood* 2021;137:3682–4.
10. Arber DA, Orazi A, Hasserjian R, Thiele J, Borowitz MJ, Le Beau MM, et al. The 2016 revision to the World Health Organization classification of myeloid neoplasms and acute leukemia. *Blood* 2016;127:2391–405.
11. Nakazawa D, Masuda S, Tomaru U, Ishizu A. Pathogenesis and therapeutic interventions for ANCA-associated vasculitis [review]. *Nat Rev Rheumatol* 2019;15:91–101.
12. Obiorah IE, Beck DB, Wang W, Ombrello A, Ferrada MA, Wu Z, et al. Myelodysplasia and bone marrow manifestations of somatic UBA1 mutated autoinflammatory disease. *Blood* 2020;136:20–1.