

## Photodynamic therapy with topical aminolevulinic acid

Luca Negosanti, Valentina Pinto, Rossella Sgarzani, Francesca Negosanti, Guido Zannetti, Riccardo Cipriani

Luca Negosanti, Valentina Pinto, Rossella Sgarzani, Guido Zannetti, Riccardo Cipriani, Plastic Surgery Department, S.Orsola-Malpighi University Hospital, 40138 Bologna, Italy  
Francesca Negosanti, Dermatologic Clinic, Centro Dermatologico, 40138 Bologna, Italy

**Author contributions:** Negosanti L, Pinto V, Sgarzani R, Negosanti F, Zannetti G and Cipriani R contributed equally to this work.

**Correspondence to:** Dr. Luca Negosanti, MD, Plastic Surgery Department, S.Orsola-Malpighi University Hospital, Via Giuseppe Dagnini 3, 40138 Bologna, Italy. [luca.negosanti81@gmail.com](mailto:luca.negosanti81@gmail.com)

Telephone: +39-339-3120279 Fax: +39-51-397954

Received: October 18, 2013 Revised: December 26, 2013

Accepted: March 13, 2014

Published online: May 2, 2014

### Abstract

Photodynamic therapy (PDT) is a relatively new therapy in dermatology that uses the topical application of a porphyrin derivative to selectively destroy a cutaneous target. The action is implemented by the application of a specific light frequency. The ability of porphyrin to selectively target tumor tissue has been known since the 1960s. In the late 1970s, the underlying mechanism was defined, and Dougherty's discovery of the first chromophore led to the production and commercialization of Photofrin®. Many other chromophores that can act as photosensitizers have been studied since then, with aminolevulinic acid currently the most commonly used chromophore in clinical practice. PDT is simple, minimally invasive and can be administered on an outpatient basis. The efficacy of PDT has been proven for actinic keratosis, Bowen's disease and basal cell carcinoma; another of its well-known applications is the treatment of photoaging. Indications for its use are continuously increasing, and promising results are reported for various skin diseases. In this paper we report the mechanism of action of PDT with aminolevulinic acid, the literature concerning the most common diseases treated with PDT and the subsequent level of evidence.

© 2014 Baishideng Publishing Group Co., Limited. All rights reserved.

**Key words:** Photodynamic therapy; Aminolevulinic acid; Skin cancer

**Core tip:** Photodynamic therapy (PDT) with aminolevulinic acid is a relatively new therapy in dermatologic practice, and the indications for PDT are increasing continuously. PDT is based on the topical application of a porphyrin derivative followed by exposure of the treated area to a specific wavelength of light to selectively destroy a cutaneous target. A thorough knowledge of the mechanism of action of the treatment and its effects are necessary to provide the patient with an appropriate assessment and indication. In this paper we report the mechanism of action of PDT with aminolevulinic acid, the literature concerning the most common diseases treated with PDT and the subsequent level of evidence, according to the European Guidelines.

Negosanti L, Pinto V, Sgarzani R, Negosanti F, Zannetti G, Cipriani R. Photodynamic therapy with topical aminolevulinic acid. *World J Dermatol* 2014; 3(2): 6-14 Available from: URL: <http://www.wjgnet.com/2218-6190/full/v3/i2/6.htm> DOI: <http://dx.doi.org/10.5314/wjd.v3.i2.6>

### INTRODUCTION

Photodynamic therapy (PDT) with aminolevulinic acid (ALA) is a relatively new therapy in dermatologic practice. PDT is based on the topical application of a porphyrin derivative followed by the exposure to a specific light wavelength to selectively destroy a cutaneous target. The indications for PDT are continuously increasing (Table 1). In this paper, we report the mechanism of action of ALA-PDT, the literature concerning the most common diseases treated with PDT and the subsequent level of evidence, according to the European Guidelines.

**Table 1 Most common reported indications for photodynamic therapy in oncological and non-oncological skin diseases**

Oncological skin disease
Actinic keratoses
Bowen's disease
Basal cell carcinoma
Squamous cell carcinoma
Cutaneous T-cell lymphoma
Cutaneous B-cell lymphoma
Extra-mammary page't's disease
Non oncological skin disease
Acne vulgaris
Warts
Photorejuvenation
Other indications:
Cutaneous leishmaniasis
Localized scleroderma
Lichen sclerosus
Perioral dermatitis
Cutaneous mycosis

### Historical view

The use of light as a therapeutic tool was reported in 1900, when sunlight was used to activate eosin for tumor treatment<sup>[1,2]</sup>. In 1960, Winkelman<sup>[3]</sup> used a porphyrin to detect tumor tissue. In the same year, Schwartz isolated an impure hematoporphyrin derivative (HpD)<sup>[4]</sup>, and Lipson suggested that the derivate could be used as a photosensitizer to destroy neoplastic tissue<sup>[4]</sup>. The mechanism of cellular destruction was recognized as singlet oxygen production in 1976<sup>[5]</sup>.

Dougherty discovered that the HpD had a high singlet oxygen quantum yield, a maximum absorption in the red spectrum and was selectively retained in tumor tissue<sup>[6]</sup>. The active fraction of the HpD was then isolated and produced as Photofrin<sup>®</sup>. Dougherty can be considered the inventor of PDT.

Since the introduction of Photofrin<sup>®</sup> in medicine, many other photosensitizers have been studied, and ALA was recently introduced in PDT for the treatment of superficial skin lesions.

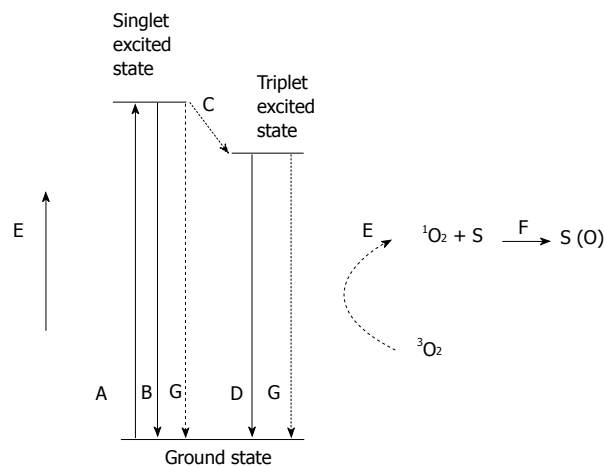
### Photochemistry

The mechanism of action of PDT can be explained by analyzing the photochemical reaction that generates singlet oxygen<sup>[1]</sup>.

A chromophore exposed to a light with a specific wavelength is excited to a singlet state that is unstable. From the singlet state, the chromophore passes to the ground state, either emitting a fluorescent photon or transforming into the stable triple state (Figure 1). In an aerobic environment, the chromophore transfers energy to ground state oxygen, producing singlet oxygen (<sup>1</sup>O<sub>2</sub>). The ability to produce singlet oxygen is one of the most important factors in determining the activity of a chromophore.

Singlet oxygen in an aqueous environment has a lifetime of 2 μs, and its energy is dissipated as heat in a spherical volume of 10 nm in diameter.

In conclusion, PDT can induce oxidative damage



**Figure 1 Jablonski diagram showing the various modes of excitation and relaxation in a chromophore.** A: Excitation; B: Fluorescence; C: Intersystem crossing; D: Phosphorescence; E: Non-radiative transfer of energy to singlet oxygen; F: Substrate oxidation by singlet oxygen; G: Internal conversion (adapted from Macdonald *et al*<sup>[1]</sup>).

that is localized near the point of production of singlet oxygen or in a region larger in diameter than a cell membrane; this induction can only occur in an oxygenated environment.

### Aminolevulinic acid

Among the different chromophores studied as photosensitizers, Δ<sup>5</sup>-aminolevulinic acid (ALA) is the most commonly used to treat skin disease.

ALA is a precursor of heme<sup>[7]</sup>, and overloading a cell with ALA forces the cell to produce protoporphyrin-IX (PP), which acts as photosensitizer.

Neoplastic cells present a relative reduction of ferrochelatase activity, which is responsible for the conversion of PP into heme. Therefore, PP production is faster than its conversion to heme, and PP accumulates in cells that become photosensitive.

ALA selectively accumulates in tumor cells because of its high reproduction rate<sup>[6,8]</sup>; the esterification of ALA alters its captation through the membrane from an active to passive mechanism, leading to high ALA penetration into cells.

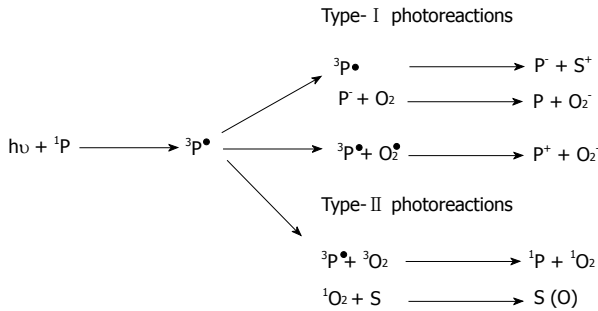
The association with iron chelation appears to increase porphyrin loading and light action, while the entry of porphyrin into cells is limited by an intact corneal layer.

By illuminating PP with adequate light, we can induce the production of singlet oxygen, which leads to damage that is confined to membranes and subcellular organs.

The light used to activate PP requires a wavelength greater than 600 nm to reduce adsorption from melanin and hemoglobin. The absorption peak of PP is from 630-635 nm.

ALA is offered on the market as a cream with a concentration of 20%.

More recently, methyl aminolevulinatate (MAL), a derivative of ALA, was introduced in clinical practice. MAL accumulates in tumor cells with a mechanism similar to



**Figure 2 Cellular damage mechanism.** Type- I and Type-II photoreactions, where  ${}^1P$  is a photosensitizer in a singlet ground state,  ${}^3P^1$  is a photosensitizer in a triplet excited state, S is a substrate molecule,  $P^{\cdot}$  is reduced photosensitizer molecule, S is an oxidized substrate molecule,  $O_2$  is molecular oxygen (triplet ground state),  $O_2^{\cdot}$  is the superoxide radical, P is the oxidized photosensitizer,  ${}^3O_2$  is triplet ground-state oxygen,  ${}^1O_2$  is oxygen in a singlet excited state, and S (O) is an oxygen adduct of a substrate (adapted from Macdonald *et al*<sup>[1]</sup>).

ALA and is hydrolyzed in the cytoplasm, releasing ALA into the cytosol. Unlike ALA, MAL is lipophilic.

### Cellular damage mechanism

PP is excited by light with an adequate wavelength and, during the subsequent relaxation phase, PP transfers energy to oxygen producing singlet oxygen (type II reaction) and free radicals (type I reaction) (Figure 2). The type II reaction is predominant in PDT<sup>[9,10]</sup>.

The damage induced in the mitochondrial membrane leads to enzymatic inhibition and a subsequent breakdown of the electron transport chain and cytochrome C release, which is responsible for apoptosis induced by caspase pathway activation<sup>[11,12]</sup> (Figure 3).

Oxygen free radicals also induce damage in endothelial cells, causing inflammation and platelet aggregation. The consequent thrombosis of intra-tumoral vessels starves neoplastic cells of oxygen and nutrients, promoting necrosis<sup>[13,14]</sup>.

Another effect induced by PDT is linked to indirect immune system activation against the tumor. The damage induced to tumoral tissues releases neoplastic antigens, which are captured by dendritic cells and presented to T lymphocytes, inducing a specific immune action against the tumor<sup>[15]</sup>.

All of the reported mechanisms are responsible for the damage induced by PDT to neoplastic tissues.

### Technique

The lesion is adequately treated with a curette to selectively “modify” the corneal layer (Figure 4). No bleeding should be present and hemostasis must be obtained in cases where bleeding occurs (Figure 5).

ALA 20% cream is then applied to the lesion using approximately 50 mg/cm<sup>2</sup>. The lesion is then occlusively dressed (Figure 6), and sun exposure must be avoided for at least 3 h<sup>[16]</sup>.

After 3 h, the dressing is removed, and the lesion is exposed to specific light for 12 min. The eyes must be protected during the exposure.

Pain during and/or after the treatment is the most common adverse effect and is most likely due to the direct stimulation of free nerve endings in the epidermis during irradiation and to the inflammatory environment induced by PDT<sup>[17,18]</sup>. It is particularly noticeable in locations such as the scalp, face and hands and is related to the extension of the treated area. It has been proven that topical anesthesia is not effective in reducing this type of pain<sup>[19,20]</sup>, whereas good results were reported using devices that blow cold air<sup>[21]</sup>. Erythema and edema are common after PDT; crust formation may also be observed, but complete healing is generally achieved in 2-6 wk (Figure 7).

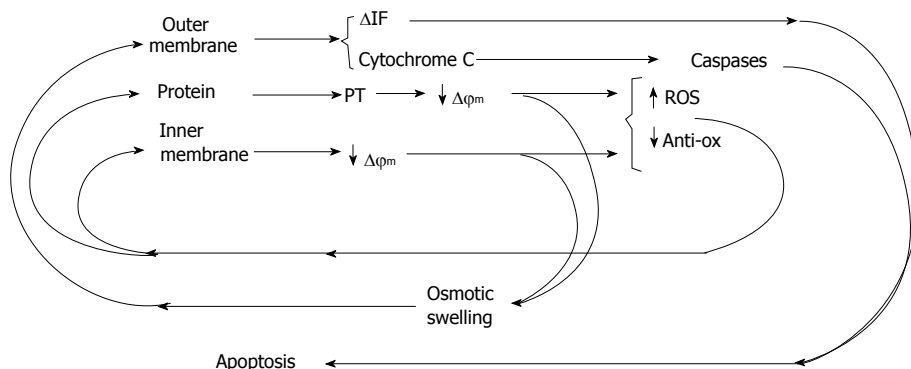
### Clinical applications

PDT is currently licensed for the treatment of actinic keratosis, Bowen’s disease and basal cell carcinoma, but there are several studies on the use of PDT for other skin diseases<sup>[22,23]</sup>, and the possible indications are increasing continuously. The reported results of PDT in various skin diseases are summarized in Table 2. The strength of the recommendation and the level of the evidence for these different indications are reported in Table 3.

**Actinic keratosis:** Actinic keratosis is a very frequently reported skin disease that can lead to squamous cell carcinoma in 5% to 20% of cases in 10-25 years. Treatment with PDT reported good results, with high remission rates. In 1997, Jeffes *et al*<sup>[24]</sup> reported a remission rate of 91% in the treatment of actinic keratosis of the face and scalp using ALA-PDT. Lower success rates (45%) were reported in trunk localizations, most likely due to less penetration of the photosensitizer. A comparison of different ALA concentrations led to Jeffes *et al*<sup>[24]</sup> assessment that a 20% concentration is preferable for clinical applications. Tschén *et al*<sup>[25]</sup> treated patients affected by actinic keratoses of the face and scalp with up to 2 sessions of ALA-PDT. He reported a clearance rate of 78% at 12 mo, with a recurrence rate of 19%; the cosmetic outcome was satisfactory in all cases, without any hyperpigmentation. Additionally, good results were reported for actinic cheilitis, with a complete clearance after 12 mo of follow up; the final aesthetic outcome was good, even if superficial peeling persisted for several months<sup>[26]</sup>.

ALA-PDT is an efficacious treatment for scalp and facial actinic keratosis, with high clearance rates and satisfactory cosmetic outcomes. The efficacy is higher using an ALA concentration of 20%. Actinic keratosis of the trunk and acral sites presents a lower remission rate in comparison to scalp and facial localization.

**Bowen’s disease:** PDT is an effective treatment option for Bowen’s disease. Remission rates of 89% were reported by Cairnduff *et al*<sup>[27]</sup> in 1994, and in 1996, Morton *et al*<sup>[28]</sup> reported higher clearance rates and better cosmetic outcomes with ALA-PDT compared with cryotherapy. More recently, in 2012, 29. López *et al*<sup>[29]</sup> reported a complete clearance of 90% in 23 lesions treated by MAL-PDT, with a good aesthetic result. In another study conducted



**Figure 3** Summary of the pathways and feedback loops involved in mitochondrially controlled apoptosis. Starbursts represent possible points at which photodynamic therapy initiates mitochondrially controlled apoptosis (adapted from Macdonald *et al*<sup>[41]</sup>).

**Table 2** Reported results of photodynamic therapy in different skin diseases

Ref.	Disease	Remission rate	Follow up	n
Jeffes <i>et al</i> <sup>[24]</sup> , 1997	AK	91% scalp, face 45% trunk	16 wk	40
Tschen <i>et al</i> <sup>[25]</sup> , 2006	AK scalp, face	78%	12 mo	101
Stender <i>et al</i> <sup>[26]</sup> , 1996	AK lip	100%	12 mo	3
Cairnduff <i>et al</i> <sup>[27]</sup> , 1994	BD	89%	18 mo	36
López <i>et al</i> <sup>[29]</sup> , 2012	BD	90%	12 mo	18
Truchuelo <i>et al</i> <sup>[30]</sup> , 2012	BD	76%	17 mo	47
Calzavara-Pinton <i>et al</i> <sup>[31]</sup> , 2008	SCC	57% microinvasive 26% nodular invasive	2 yr	55
Christensen <i>et al</i> <sup>[32]</sup> , 2009	BCC	68% single session 91% two session	6 yr	60
Christensen <i>et al</i> <sup>[33]</sup> , 2012	BCC	60% single session 87% two session	10 yr	60
Souza <i>et al</i> <sup>[34]</sup> , 2009	BCC	> 90% 60%	3 mo 5 yr	34
Soler <i>et al</i> <sup>[35]</sup> , 2001	BCC	89%	3 yr	350
Svanberg <i>et al</i> <sup>[49]</sup> , 1994	TCL	100%	6-14 mo	4
Orenstein <i>et al</i> <sup>[50]</sup> , 2000	TCL	100%	24-27 mo	2
Mori <i>et al</i> <sup>[51]</sup> , 2006	BCL	100%	8-24 mo	3
Shieh <i>et al</i> <sup>[52]</sup> , 2002	PD	50% 31%	6 mo 10 mo	5
Raspagliesi <i>et al</i> <sup>[54]</sup> , 2006	PD	57%	1-5 mo	7
Stender <i>et al</i> <sup>[58]</sup> , 2000	Hand-foot W	76%	18 wk	45
Fabbrocini <i>et al</i> <sup>[59]</sup> , 2001	Plantar W	75%	2 mo	64
Fehr <i>et al</i> <sup>[63]</sup> , 2002	Vulvar W	66%	12 mo	16
Stefanaki <i>et al</i> <sup>[64]</sup> , 2003	Male genital W	73%	12 mo	12

AK: Actinic keratosis; BD: Bowen’s disease; SCC: Squamous cell carcinoma; BCC: Basal cell carcinoma; TCL: Cutaneous T-cell lymphoma; BCL: Cutaneous B-cell lymphoma; PD: Extra-mammary Paget’s disease; W: Warts.

on 47 patients affected by Bowen’s disease, a complete clearance of 76% was reported after 17 mo from 2 sessions of MAL-PDT<sup>[30]</sup>.

**Invasive squamous cell carcinoma:** Squamous cell carcinoma presented a lower sensitivity to PDT in comparison with basal cell carcinoma. Clearance rates of 57% and 26% have been reported in microinvasive and nodular invasive squamous cell carcinoma, respectively, 2

**Table 3** Strength of recommendation and the level of evidence of the different indications of photodynamic therapy<sup>[24,25]</sup>

Disease	Strength of recommendation	Quality of evidence
Actinic keratoses	A	I
Bowen’s disease	A	I
Invasive squamous cell carcinoma	D	II -iii
Superficial basal cell carcinoma	A	I
Nodular basal cell carcinoma	A	I
NMSC in organ transplant recipients	B	I
Prevention of NMSC in organ transplant recipients	B	I
Field cancerization	B	I
Cutaneous T-cell lymphoma	C	II -iii
Extra-mammary Paget’s disease	D	III
Infectious and inflammatory dermatoses acne	A	I
Hand and foot warts	B	I
Genital warts	B	I
Cutaneous leishmaniasis	B	I
Photorejuvenation	B	I

Strength of recommendations: A: There is good evidence to support the use of the procedure; B: There is fair evidence to support the use of the procedure; C: There is fair evidence to support the rejection of the use of the procedure; D: There is good evidence to support the rejection of the use of the procedure. Quality of evidence: I: Evidence obtained from at least one properly designed, randomized control trial; II-i: Evidence obtained from well-designed control trials without randomization; II-ii: Evidence obtained from well-designed cohort or case control analytic studies preferably from more than one centre or research group; II-iii: Evidence obtained from multiple time series with or without the intervention. Dramatic results in uncontrolled experiments could also be regarded as this type of evidence; III: Opinions of respected authorities based on clinical experience, descriptive studies or reports of expert committees; IV: Evidence inadequate, owing to problems of methodology (e.g., sample size, or length of comprehensiveness of follow-up or conflicts in evidence).

years after treatment with MAL-PDT<sup>[31]</sup>. Considering the lower response rate and the metastatic potential, PDT is not the first choice for invasive squamous cell carcinoma treatment.

**Basal cell carcinoma:** PDT is particularly indicated for basal cell carcinoma treatment, especially in superficial carcinomas and in Gorlin Syndrome.

Several studies reported good results in the treatment

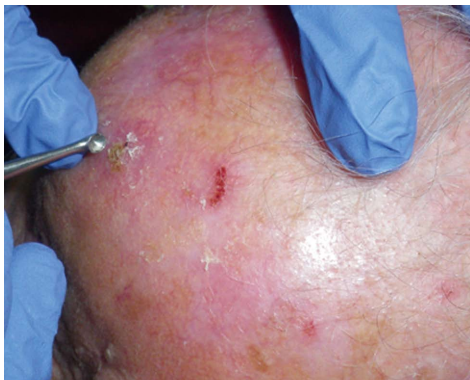

Figure 4 Lesion is treated with a curette to selectively remove the corneal layer.

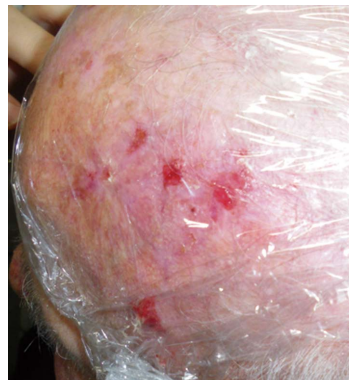


Figure 6 Cream is applied on the lesion and an occlusive dressing is then performed.

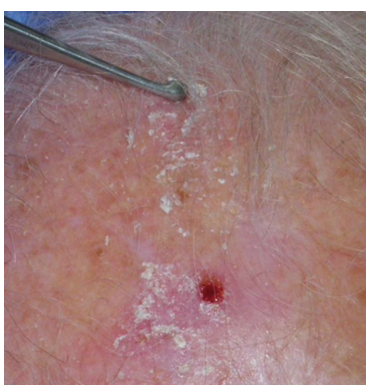

Figure 5 After curettage no bleeding might be present.

of basal cell carcinoma with PDT<sup>[32-35]</sup>, with clearance rates up to 90% at 3 years and 87% at 10 years.

Similar results have been reported in studies comparing PDT to cryotherapy, with PDT obtaining a better aesthetic outcome<sup>[36]</sup>. Good results were reported in patients affected by Gorlin Syndrome<sup>[37]</sup>, with a reduction in the need for surgical procedures.

Relatively poor results were obtained in invasive carcinoma and in morpheic basal cell carcinoma<sup>[38]</sup>; therefore, PDT must be considered not indicated in these cases.

#### Organ transplant recipients and field cancerization:

PDT has been studied for the treatment and prevention of non-melanoma skin cancer (NMSC) in organ transplant recipients. An important factor to emphasize is the reduced response rate in non-immunocompetent patients compared with immunocompetent patients, due to the role of the immune system in the action of PDT<sup>[39]</sup>. PDT cannot be considered as a first choice in the treatment of skin cancer in organ transplant recipients, nor can it play a significant role in the prevention of NMSC in non-immunocompetent patients<sup>[40]</sup>.

However, in immunocompetent patients with multiple clinical or subclinical cancerous skin lesions, PDT can be used to prevent the lesions from evolving into invasive carcinomas<sup>[41-43]</sup>. This preventive effect of PDT has been explained by the reduced expression of the proto-

oncogene p53 in treated tissues<sup>[44]</sup>.

**Cutaneous T-cell and B-cell lymphomas:** Dougherty *et al.*<sup>[45]</sup> and Forbes *et al.*<sup>[46]</sup> demonstrated the efficacy of PDT in the treatment of cutaneous T-cell lymphoma. The selective uptake of ALA and MAL into CD71<sup>+</sup> lymphocytes was observed<sup>[47]</sup>. Small series with good results are reported in the literature<sup>[48-50]</sup>. Satisfactory results were also reported by Mori *et al.*<sup>[51]</sup> in 3 patients affected by cutaneous B-cell lymphoma. The effectiveness of PDT in the treatment of cutaneous lymphomas has not been proven; therefore, PDT should not be considered an indication. Further studies are necessary to verify the application of PDT in this field.

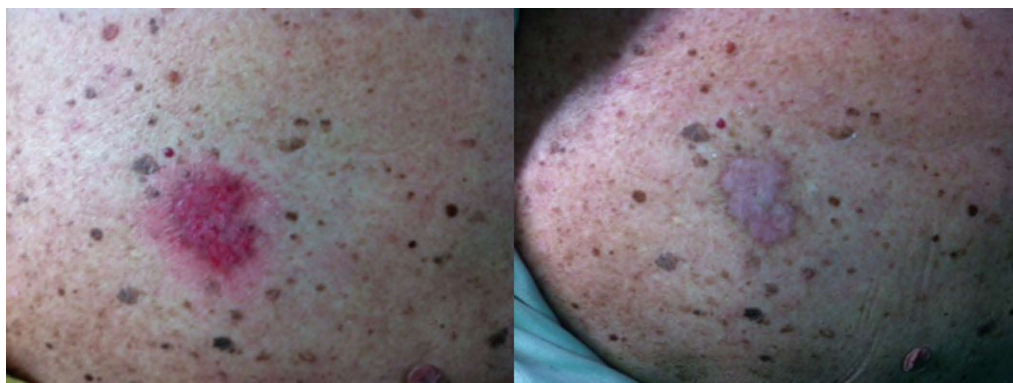**Extra-mammary Paget's disease:** Few reports have shown promising results in the treatment of Paget's disease<sup>[52-55]</sup>. A more appropriate role for PDT may be as an adjuvant therapy in association with radiotherapy or surgery<sup>[56]</sup>, as PDT not only induces tissue destruction but also causes a reduction in tumor cells' adhesive and metastatic capacities.

**Acne vulgaris:** PDT has been used with good results in the treatment of acne vulgaris.

It was noted that ALA accumulates in sebocytes, which are then destroyed by the photoreaction, reducing sebum excretion. Another positive effect is linked to production of porphyrins by *Propionibacterium acnes*, which became a target for PDT<sup>[57]</sup>.

**Warts:** Several studies have reported good results concerning the application of ALA-PDT for the treatment of warts<sup>[58-60]</sup>. Many comparative studies reported higher clearance rates in patients treated with ALA -PDT versus patients treated with a placebo<sup>[58,59]</sup> or cryotherapy<sup>[60]</sup>. Similar results were reported in hand and foot warts and in genital warts<sup>[61-64]</sup>. In the treatment of genital warts, PDT was reported to have clearance rates similar to other therapies, such as laser CO<sub>2</sub>, but lower recurrence rates.

It should be noted that studies regarding MAL-PDT in the treatment of warts are limited.



**Figure 7** Patient affected by multiple actinic keratosis of the scalp treated with photodynamic therapy with aminolevulinic acid; result after 3 wk from the 1<sup>st</sup> application.

Accurate curettage of lesions is mandatory to reduce typical hyperkeratosis, which limits the penetration of the photosensitizer.

**Other indications:** Some other indications for PDT are currently under study.

A review of patients affected by cutaneous leishmaniasis reported complete healing in 94%-100% of cases treated with PDT<sup>[65]</sup>. These results were confirmed by randomized trials<sup>[66]</sup>. The mechanism was studied in vivo by Kosaka *et al*<sup>[67]</sup>, who suggested that the clinical outcomes observed with ALA-PDT are the result of unspecific tissue destruction accompanied by the depopulation of macrophages rather than by the direct destruction of parasites, as observed by previous in vitro studies<sup>[68]</sup>. Several series have reported improvements in PDT-treated patients diagnosed with localized scleroderma<sup>[69,70]</sup>, lichen sclerosus<sup>[71]</sup>, perioral dermatitis<sup>[72]</sup> and cutaneous mycosis<sup>[73,74]</sup>.

These preliminary results appear to be promising, but further research is necessary to demonstrate the actual efficacy of PDT in the reported diseases.

**Photorejuvenation:** Many studies have reported good results for skin rejuvenation after the application of PDT<sup>[75-77]</sup>. PDT is useful for improving dyspigmentation, depigmentation, fine lines and roughness, skin smoothness and for reducing actinic elastosis<sup>[78]</sup>. Other techniques can be combined with PDT to improve results, acting synergistically to induce self-stimulated collagen biosynthesis (microneedling, ablative fractional lasers) or to improve photosensitizer penetration (curettage, peeling, lasers, microneedling). All of these treatments must be performed before PDT; chemical peeling can be applied immediately before PDT or up to 3 d (maximum) prior to PDT; curettage can be performed 2 wk prior to PDT; and lasers, microneedling and mechanical peeling can be applied immediately before PDT. Other aesthetic procedures can be associated with PDT; fillers can be used 2 wk after PDT, and botulinum toxin can be used 2 wk prior (at the earliest) to PDT. Pre-treatment can increase phototoxic effects, prolonging the downtime of

the patient. The expected aesthetic results are usually observed after 3-6 mo, and 2 or 3 sessions conducted every 4 wk are usually necessary. The scalp is more painful than other sites, whereas the hands are usually reported as minimally painful. The neck and décolleté present fewer skin appendages, thereby leading to more prolonged re-epithelization and erythema<sup>[79]</sup>.

ALA-PDT induces the deposition of collagen in the dermis, normalizes elastotic materials induced by photoaging and may even have a direct effect on the normalization of fibroblast morphology<sup>[80]</sup>. Marmur *et al*<sup>[81]</sup> observed a series of ultrastructural changes leading to clinical improvement. In the epidermis, ALA-PDT induces reorganization because of keratinocyte adhesion recovery. In the dermis, there is a recovery of the dermal extracellular matrix, which is demonstrated by the reappearance of anchoring fibrils, the displacement of elastosis and the superficial remodeling of dermal collagen.

## CONCLUSION

PDT is very useful in dermatology; PDT is minimally invasive, especially compared with surgery, and allows better results than non-surgical treatments, such as lasers and cryotherapy. In our experience, PDT was widely applied in over 250 patients affected by actinic keratoses, basal cell carcinomas and Bowen's disease, with excellent results. In our opinion, assessing the depth of a lesion to determine the appropriate indication for PDT compared with surgical treatment is important. In deeper lesions, or in particularly sensitive areas such as the face, PDT can be a useful treatment in association with surgery, as described by other authors. Skin cancers, especially if arising on actinic keratosis, often present ill-defined margins. In these cases, PDT may be useful to better define the edges of a lesion before surgical treatment. We have used this method in 14 patients diagnosed with basal cell carcinoma of the face with surrounding photodamaged skin; after 3 PDT sessions, the patients underwent surgery, and the excision margins were found to be free from disease in all of the cases. Additionally, we used PDT for the treatment of photoaging in 57 patients, with excellent

results after an average of 3-4 sessions. We believe that the other proposed indications require further research to verify the effectiveness of PDT.

## REFERENCES

- 1 **Macdonald IJ**, Dougherty TJ. Basic principles of photodynamic therapy. *J Porphyr Phthalocyanines* 2001; **105**: 105-129 [DOI: 10.1002/jpp.328]
- 2 **Ronchese F**. The fluorescence of cancer under the Wood light. *Oral Surg Oral Med Oral Pathol* 1954; **7**: 967-971 [PMID: 13194302 DOI: 10.1016/0030-4220(54)90295-9]
- 3 **Winkelman J**. Intracellular localization of "hematoporphyrin" in a transplanted tumor. *J Natl Cancer Inst* 1961; **27**: 1369-1377 [PMID: 14007508]
- 4 **Lipson RL**, BALDES EJ, OLSEN AM. The use of a derivative of hematoporphyrin in tumor detection. *J Natl Cancer Inst* 1961; **26**: 1-11 [PMID: 13762612]
- 5 **Weishaupt KR**, Gomer CJ, Dougherty TJ. Identification of singlet oxygen as the cytotoxic agent in photoinactivation of a murine tumor. *Cancer Res* 1976; **36**: 2326-2329 [PMID: 1277137]
- 6 **Dougherty TJ**. A brief history of clinical photodynamic therapy development at Roswell Park Cancer Institute. *J Clin Laser Med Surg* 1996; **14**: 219-221 [PMID: 9612186 DOI: 10.1089/clm.1996.14.219]
- 7 **Kennedy JC**, Marcus SL, Pottier RH. Photodynamic therapy (PDT) and photodiagnosis (PD) using endogenous photosensitization induced by 5-aminolevulinic acid (ALA): mechanisms and clinical results. *J Clin Laser Med Surg* 1996; **14**: 289-304 [PMID: 9612195]
- 8 **Zeitouni NC**, Shieh S, Oseroff AR. Laser and photodynamic therapy in the management of cutaneous malignancies. *Clin Dermatol* 2001; **19**: 328-338 [PMID: 11479045 DOI: 10.1016/S0738-081X(01)00170-5]
- 9 **Foote CS**. Mechanisms of photooxygenation. *Prog Clin Biol Res* 1984; **170**: 3-18 [PMID: 6531365]
- 10 **Henderson BW**, Dougherty TJ. How does photodynamic therapy work? *Photochem Photobiol* 1992; **55**: 145-157 [PMID: 1603846 DOI: 10.1111/j.1751-1097.1992.tb04222.x]
- 11 **Kessel D**, Luo Y. Photodynamic therapy: a mitochondrial inducer of apoptosis. *Cell Death Differ* 1999; **6**: 28-35 [PMID: 10200545 DOI: 10.1038/sj.cdd.4400446]
- 12 **Kessel D**, Luo Y. Mitochondrial photodamage and PDT-induced apoptosis. *J Photochem Photobiol B* 1998; **42**: 89-95 [PMID: 9540214 DOI: 10.1016/S1011-1344(97)00127-9]
- 13 **Henderson BW**, Dougherty TJ, Malone PB. Studies on the mechanism of tumor destruction by photoradiation therapy. *Prog Clin Biol Res* 1984; **170**: 601-612 [PMID: 6241700]
- 14 **Henderson BW**, Fingar VH. Relationship of tumor hypoxia and response to photodynamic treatment in an experimental mouse tumor. *Cancer Res* 1987; **47**: 3110-3114 [PMID: 3581062]
- 15 **Korbelik M**. Induction of tumor immunity by photodynamic therapy. *J Clin Laser Med Surg* 1996; **14**: 329-334 [PMID: 9612200]
- 16 **Larkö O**. Photodynamic therapy. *Australas J Dermatol* 2005; **46** Suppl 3: S1-S2; discussion S23-S25 [PMID: 15859298]
- 17 **Grapengiesser S**, Ericson M, Gudmundsson F, Larkö O, Rosén A, Wennberg AM. Pain caused by photodynamic therapy of skin cancer. *Clin Exp Dermatol* 2002; **27**: 493-497 [PMID: 12372093 DOI: 10.1046/j.1365-2230.2002.01065.x]
- 18 **Sandberg C**, Stenquist B, Rosdahl I, Ros AM, Synnerstad I, Karlsson M, Gudmundson F, Ericson MB, Larkö O, Wennberg AM. Important factors for pain during photodynamic therapy for actinic keratosis. *Acta Derm Venereol* 2006; **86**: 404-408 [PMID: 16955183 DOI: 10.2340/00015555-0098]
- 19 **Langan SM**, Collins P. Randomized, double-blind, placebo-controlled prospective study of the efficacy of topical anaesthesia with a eutetic mixture of lignocaine 2.5% and prilocaine 2.5% for topical 5-aminolevulinic acid-photodynamic therapy for extensive scalp actinic keratoses. *Br J Dermatol* 2006; **154**: 146-149 [PMID: 16403108 DOI: 10.1111/j.1365-2133.2005.06991.x]
- 20 **Skiveren J**, Haedersdal M, Philipsen PA, Wiegell SR, Wulf HC. Morphine gel 0.3% does not relieve pain during topical photodynamic therapy: a randomized, double-blind, placebo-controlled study. *Acta Derm Venereol* 2006; **86**: 409-411 [PMID: 16955184 DOI: 10.2340/00015555-0128]
- 21 **Pagliari J**, Elliott T, Bulsara M, King C, Vinciullo C. Cold air analgesia in photodynamic therapy of basal cell carcinomas and Bowen's disease: an effective addition to treatment: a pilot study. *Dermatol Surg* 2004; **30**: 63-66 [PMID: 14692930 DOI: 10.1111/j.1524-4725.2004.30011.x]
- 22 **Morton CA**, Szeimies RM, Sidoroff A, Braathen LR. European guidelines for topical photodynamic therapy part 1: treatment delivery and current indications - actinic keratoses, Bowen's disease, basal cell carcinoma. *J Eur Acad Dermatol Venereol* 2013; **27**: 536-544 [PMID: 23181594 DOI: 10.1111/jdv.12031.]
- 23 **Morton CA**, Szeimies RM, Sidoroff A, Braathen LR. European guidelines for topical photodynamic therapy part 2: emerging indications--field cancerization, photorejuvenation and inflammatory/infective dermatoses. *J Eur Acad Dermatol Venereol* 2013; **27**: 672-679 [DOI: 10.1111/jdv.12026. DOI: 10.1111/jdv.12026]
- 24 **Jeffes EW**, McCullough JL, Weinstein GD, Fergin PE, Nelson JS, Shull TF, Simpson KR, Bukaty LM, Hoffman WL, Fong NL. Photodynamic therapy of actinic keratosis with topical 5-aminolevulinic acid. A pilot dose-ranging study. *Arch Dermatol* 1997; **133**: 727-732 [PMID: 9197826 DOI: 10.1001/archderm.1997.03890420065007]
- 25 **Tschen EH**, Wong DS, Pariser DM, Dunlap FE, Houlihan A, Ferdon MB. Photodynamic therapy using aminolevulinic acid for patients with nonhyperkeratotic actinic keratoses of the face and scalp: phase IV multicentre clinical trial with 12-month follow up. *Br J Dermatol* 2006; **155**: 1262-1269 [PMID: 17107399 DOI: 10.1111/j.1365-2133.2006.07520.x]
- 26 **Stender IM**, Wulf HC. Photodynamic therapy with 5-aminolevulinic acid in the treatment of actinic cheilitis. *Br J Dermatol* 1996; **135**: 454-456 [PMID: 8949443 DOI: 10.1111/j.1365-2133.1996.tb01513.x]
- 27 **Cairnduff F**, Stringer MR, Hudson EJ, Ash DV, Brown SB. Superficial photodynamic therapy with topical 5-aminolevulinic acid for superficial primary and secondary skin cancer. *Br J Cancer* 1994; **69**: 605-608 [PMID: 8123497 DOI: 10.1038/bjc.1994.112]
- 28 **Morton CA**, Whitehurst C, Moseley H, McColl JH, Moore JV, Mackie RM. Comparison of photodynamic therapy with cryotherapy in the treatment of Bowen's disease. *Br J Dermatol* 1996; **135**: 766-771 [PMID: 8977678 DOI: 10.1046/j.1365-2133.1996.d01-1076.x]
- 29 **López N**, Meyer-Gonzalez T, Herrera-Acosta E, Bosch R, Castillo R, Herrera E. Photodynamic therapy in the treatment of extensive Bowen's disease. *J Dermatolog Treat* 2012; **23**: 428-430 [PMID: 21787214 DOI: 10.3109/09546634.2011.590789]
- 30 **Truchuelo M**, Fernández-Guarino M, Fleta B, Alcántara J, Jaén P. Effectiveness of photodynamic therapy in Bowen's disease: an observational and descriptive study in 51 lesions. *J Eur Acad Dermatol Venereol* 2012; **26**: 868-874 [PMID: 21740466 DOI: 10.1111/j.1468-3083.2011.04175.x]
- 31 **Calzavara-Pinton PG**, Venturini M, Sala R, Capezzer R, Parrinello G, Specchia C, Zane C. Methylaminolevulinic acid-based photodynamic therapy of Bowen's disease and squamous cell carcinoma. *Br J Dermatol* 2008; **159**: 137-144 [PMID: 18489606 DOI: 10.1111/j.1365-2133.2008.08593.x]
- 32 **Christensen E**, Skogvoll E, Viset T, Warloe T, Sundstrøm S. Photodynamic therapy with 5-aminolevulinic acid, dimethylsulfoxide and curettage in basal cell carcinoma: a

- 6-year clinical and histological follow-up. *J Eur Acad Dermatol Venereol* 2009; **23**: 58-66 [PMID: 18803580 DOI: 10.1111/j.1468-3083.2008.02946.x]
- 33 **Christensen E**, Mørk C, Skogvoll E. High and sustained efficacy after two sessions of topical 5-aminolaevulinic acid photodynamic therapy for basal cell carcinoma: a prospective, clinical and histological 10-year follow-up study. *Br J Dermatol* 2012; **166**: 1342-1348 [PMID: 22309486 DOI: 10.1111/j.1365-2133.2012.10878.x]
- 34 **Souza CS**, Felicio LB, Ferreira J, Kurachi C, Bentley MV, Tedesco AC, Bagnato VS. Long-term follow-up of topical 5-aminolaevulinic acid photodynamic therapy diode laser single session for non-melanoma skin cancer. *Photodiagnosis Photodyn Ther* 2009; **6**: 207-213 [PMID: 19932453 DOI: 10.1016/j.pdpdt.2009.09.001P]
- 35 **Soler AM**, Warloe T, Berner A, Giercksky KE. A follow-up study of recurrence and cosmesis in completely responding superficial and nodular basal cell carcinomas treated with methyl 5-aminolaevulinic acid-based photodynamic therapy alone and with prior curettage. *Br J Dermatol* 2001; **145**: 467-471 [PMID: 11531838 DOI: 10.1046/j.1365-2133.2001.04407.x]
- 36 **Basset-Seguín N**, Ibbotson SH, Emtestam L, Tarstedt M, Morton C, Maroti M, Calzavara-Pinton P, Varma S, Rølandts R, Wolf P. Topical methyl aminolaevulinic acid photodynamic therapy versus cryotherapy for superficial basal cell carcinoma: a 5 year randomized trial. *Eur J Dermatol* 2008; **18**: 547-553 [PMID: 18693158 DOI: 10.1684/ejd.2008.0472]
- 37 **Pauwels C**, Mazereeuw-Hautier J, Basset-Seguín N, Livideanu C, Viraben R, Paul C, Meyer N. Topical methyl aminolaevulinic acid photodynamic therapy for management of basal cell carcinomas in patients with basal cell nevus syndrome improves patient's satisfaction and reduces the need for surgical procedures. *J Eur Acad Dermatol Venereol* 2011; **25**: 861-864 [PMID: 21668511 DOI: 10.1111/j.1468-3083.2010.03854.x]
- 38 **Telfer NR**, Colver GB, Morton CA. Guidelines for the management of basal cell carcinoma. *Br J Dermatol* 2008; **159**: 35-48 [PMID: 18593385 DOI: 10.1111/j.1365-2133.2008.08666.x]
- 39 **Dragieva G**, Hafner J, Dummer R, Schmid-Grendelmeier P, Roos M, Prinz BM, Burg G, Binswanger U, Kempf W. Topical photodynamic therapy in the treatment of actinic keratoses and Bowen's disease in transplant recipients. *Transplantation* 2004; **77**: 115-121 [PMID: 14724445 DOI: 10.1097/01.TP.0000107284.04969.5C]
- 40 **Willey A**, Mehta S, Lee PK. Reduction in the incidence of squamous cell carcinoma in solid organ transplant recipients treated with cyclic photodynamic therapy. *Dermatol Surg* 2010; **36**: 652-658 [PMID: 19889154 DOI: 10.1111/j.1524-4725.2009.01384.x]
- 41 **Braathén LR**, Morton CA, Basset-Seguín N, Bissonnette R, Gerritsen MJ, Gilaberte Y, Calzavara-Pinton P, Sidoroff A, Wulf HC, Szeimies RM. Photodynamic therapy for skin field cancerization: an international consensus. International Society for Photodynamic Therapy in Dermatology. *J Eur Acad Dermatol Venereol* 2012; **26**: 1063-1066 [PMID: 22220503 DOI: 10.1111/j.1468-3083.2011.04432.x]
- 42 **Basset-Seguín N**, Baumann Conzett K, Gerritsen MJ, Gonzalez H, Haedersdal M, Hofbauer GF, Aguado L, Kerob D, Lear JT, Piaserico S, Ulrich C. Photodynamic therapy for actinic keratosis in organ transplant patients. *J Eur Acad Dermatol Venereol* 2013; **27**: 57-66 [PMID: 22151793 DOI: 10.1111/J.1468-3083.2011.04356]
- 43 **Apalla Z**, Sotiriou E, Chovarda E, Lefaki I, Devliotou-Panagiotidou D, Ioannides D. Skin cancer: preventive photodynamic therapy in patients with face and scalp cancerization. A randomized placebo-controlled study. *Br J Dermatol* 2010; **162**: 171-175 [PMID: 19863513 DOI: 10.1111/j.1365-2133.2009.09492.x]
- 44 **Bagazgoitia L**, Cuevas Santos J, Juarranz A, Jaén P. Photodynamic therapy reduces the histological features of actinic damage and the expression of early oncogenic markers. *Br J Dermatol* 2011; **165**: 144-151 [PMID: 21615716 DOI: 10.1111/j.1365-2133.2011.10270.x]
- 45 **Dougherty TJ**, Kaufman JE, Goldfarb A, Weishaupt KR, Boyle D, Mittleman A. Photoradiation therapy for the treatment of malignant tumors. *Cancer Res* 1978; **38**: 2628-2635 [PMID: 667856]
- 46 **Forbes IJ**, Cowled PA, Leong AS, Ward AD, Black RB, Blake AJ, Jacka FJ. Phototherapy of human tumours using haematoporphyrin derivative. *Med J Aust* 1980; **2**: 489-493 [PMID: 7207345]
- 47 **Morton CA**, McKenna KE, Rhodes LE. Guidelines for topical photodynamic therapy: update. *Br J Dermatol* 2008; **159**: 1245-1266 [PMID: 18945319 DOI: 10.1111/j.1365-2133.2008.08882.x]
- 48 **Wolf P**, Fink-Puches R, Cerroni L, Kerl H. Photodynamic therapy for mycosis fungoides after topical photosensitization with 5-aminolaevulinic acid. *J Am Acad Dermatol* 1994; **31**: 678-680 [PMID: 8089302 DOI: 10.1016/S0190-9622(08)81742-2]
- 49 **Svanberg K**, Andersson T, Killander D, Wang I, Stenram U, Andersson-Engels S, Berg R, Johansson J, Svanberg S. Photodynamic therapy of non-melanoma malignant tumours of the skin using topical delta-amino levulinic acid sensitization and laser irradiation. *Br J Dermatol* 1994; **130**: 743-751 [PMID: 8011500 DOI: 10.1111/j.1365-2133.1994.tb03412.x]
- 50 **Orenstein A**, Haik J, Tamir J, Winkler E, Trau H, Malik Z, Kostenich G. Photodynamic therapy of cutaneous lymphoma using 5-aminolaevulinic acid topical application. *Dermatol Surg* 2000; **26**: 765-769; discussion 765-769 [PMID: 10940064 DOI: 10.1046/j.1524-4725.2000.00056.x]
- 51 **Mori M**, Campolmi P, Mavilia L, Rossi R, Cappugi P, Pimpinelli N. Topical photodynamic therapy for primary cutaneous B-cell lymphoma: a pilot study. *J Am Acad Dermatol* 2006; **54**: 524-526 [PMID: 16488310 DOI: 10.1016/j.jaad.2005.10.016]
- 52 **Shieh S**, Dee AS, Cheney RT, Frawley NP, Zeitouni NC, Osseoff AR. Photodynamic therapy for the treatment of extramammary Paget's disease. *Br J Dermatol* 2002; **146**: 1000-1005 [PMID: 12072068 DOI: 10.1046/j.1365-2133.2002.04801.x]
- 53 **Mikasa K**, Watanabe D, Kondo C, Kobayashi M, Nakaseko H, Yokoo K, Tamada Y, Matsumoto Y. 5-Aminolaevulinic acid-based photodynamic therapy for the treatment of two patients with extramammary Paget's disease. *J Dermatol* 2005; **32**: 97-101 [PMID: 15906538]
- 54 **Raspagliesi F**, Fontanelli R, Rossi G, Ditto A, Solima E, Hanozet F, Kusamura S. Photodynamic therapy using a methyl ester of 5-aminolaevulinic acid in recurrent Paget's disease of the vulva: a pilot study. *Gynecol Oncol* 2006; **103**: 581-586 [PMID: 16793128 DOI: 10.1016/j.ygyno.2006.04.009]
- 55 **Zawislak AA**, McCarron PA, McCluggage WG, Price JH, Donnelly RF, McClelland HR, Dobbs SP, Woolfson AD. Successful photodynamic therapy of vulval Paget's disease using a novel patch-based delivery system containing 5-aminolaevulinic acid. *BJOG* 2004; **111**: 1143-1145 [PMID: 15383120 DOI: 10.1111/j.1471-0528.2004.00254.x]
- 56 **Henta T**, Itoh Y, Kobayashi M, Ninomiya Y, Ishibashi A. Photodynamic therapy for inoperable vulval Paget's disease using delta-aminolaevulinic acid: successful management of a large skin lesion. *Br J Dermatol* 1999; **141**: 347-349 [PMID: 10468815 DOI: 10.1046/j.1365-2133.1999.02991.x]
- 57 **Hongcharu W**, Taylor CR, Chang Y, Aghassi D, Suthamjariya K, Anderson RR. Topical ALA-photodynamic therapy for the treatment of acne vulgaris. *J Invest Dermatol* 2000; **115**: 183-192 [PMID: 10951234 DOI: 10.1046/j.1523-1747.2000.00046.x]
- 58 **Stender IM**, Na R, Fogh H, Gluud C, Wulf HC. Photodynamic therapy with 5-aminolaevulinic acid or placebo for recalcitrant foot and hand warts: randomised double-blind trial. *Lancet* 2000; **355**: 963-966 [PMID: 10768434 DOI: 10.1016/S0140-6736(00)90013-8]



- 59 **Fabbrocini G**, Di Costanzo MP, Riccardo AM, Quarto M, Colasanti A, Roberti G, Monfrecola G. Photodynamic therapy with topical delta-aminolaevulinic acid for the treatment of plantar warts. *J Photochem Photobiol B* 2001; **61**: 30-34 [PMID: 11485845 DOI: 10.1016/S1011-1344(01)00141-5]
- 60 **Stender IM**, Lock-Andersen J, Wulf HC. Recalcitrant hand and foot warts successfully treated with photodynamic therapy with topical 5-aminolaevulinic acid: a pilot study. *Clin Exp Dermatol* 1999; **24**: 154-159 [PMID: 10354167 DOI: 10.1046/j.1365-2230.1999.00441.x]
- 61 **Wang XL**, Wang HW, Wang HS, Xu SZ, Liao KH, Hillemanns P. Topical 5-aminolaevulinic acid-photodynamic therapy for the treatment of urethral condylomata acuminata. *Br J Dermatol* 2004; **151**: 880-885 [PMID: 15491431 DOI: 10.1111/j.1365-2133.2004.06189.x]
- 62 **Liang J**, Lu XN, Tang H, Zhang Z, Fan J, Xu JH. Evaluation of photodynamic therapy using topical aminolevulinic acid hydrochloride in the treatment of condylomata acuminata: a comparative, randomized clinical trial. *Photodermatol Photoimmunol Photomed* 2009; **25**: 293-297 [PMID: 19906163 DOI: 10.1111/j.1600-0781.2009.00467.x]
- 63 **Fehr MK**, Hornung R, Degen A, Schwarz VA, Fink D, Haller U, Wyss P. Photodynamic therapy of vulvar and vaginal condyloma and intraepithelial neoplasia using topically applied 5-aminolevulinic acid. *Lasers Surg Med* 2002; **30**: 273-279 [PMID: 11948597 DOI: 10.1002/lsm.10048]
- 64 **Stefanaki IM**, Georgiou S, Themelis GC, Vazgiouraki EM, Tosca AD. In vivo fluorescence kinetics and photodynamic therapy in condylomata acuminata. *Br J Dermatol* 2003; **149**: 972-976 [PMID: 14632801 DOI: 10.1111/j.1365-2133.2003.05553.x]
- 65 **van der Snoek EM**, Robinson DJ, van Hellemond JJ, Neumann HA. A review of photodynamic therapy in cutaneous leishmaniasis. *J Eur Acad Dermatol Venereol* 2008; **22**: 918-922 [PMID: 18624853 DOI: 10.1111/j.1468-3083.2008.02805.x]
- 66 **Asilian A**, Davami M. Comparison between the efficacy of photodynamic therapy and topical paromomycin in the treatment of Old World cutaneous leishmaniasis: a placebo-controlled, randomized clinical trial. *Clin Exp Dermatol* 2006; **31**: 634-637 [PMID: 16780497 DOI: 10.1111/j.1365-2230.2006.02182.x]
- 67 **Kosaka S**, Akilov OE, O'Riordan K, Hasan T. A mechanistic study of delta-aminolevulinic acid-based photodynamic therapy for cutaneous leishmaniasis. *J Invest Dermatol* 2007; **127**: 1546-1549 [PMID: 17218937 DOI: 10.1038/sj.jid.5700719]
- 68 **Abok K**, Cadenas E, Brunk U. An experimental model system for leishmaniasis. Effects of porphyrin-compounds and menadione on Leishmania parasites engulfed by cultured macrophages. *APMIS* 1988; **96**: 543-551 [PMID: 3395481 DOI: 10.1111/j.1699-0463.1988.tb05342.x]
- 69 **Karrer S**, Abels C, Landthaler M, Szeimies RM. Topical photodynamic therapy for localized scleroderma. *Acta Derm Venereol*; **80**: 26-27 [PMID: 10721828 DOI: 10.1080/000155500750012469]
- 70 **Karrer S**, Bosserhoff AK, Weiderer P, Landthaler M, Szeimies RM. Influence of 5-aminolevulinic acid and red light on collagen metabolism of human dermal fibroblasts. *J Invest Dermatol* 2003; **120**: 325-331 [PMID: 12542540 DOI: 10.1046/j.1523-1747.2003.12037.x]
- 71 **Hillemanns P**, Untch M, Pröve F, Baumgartner R, Hillemanns M, Korell M. Photodynamic therapy of vulvar lichen sclerosus with 5-aminolevulinic acid. *Obstet Gynecol* 1999; **93**: 71-74 [PMID: 9916959 DOI: 10.1016/S0029-7844(98)00321-4]
- 72 **Richey DF**, Hopson B. Photodynamic therapy for perioral dermatitis. *J Drugs Dermatol* 2006; **5**: 12-16 [PMID: 16485876]
- 73 **Sotiriou E**, Koussidou T, Patsatsi A, Apalla Z, Ioannides D. 5-Aminolevulinic acid-photodynamic treatment for dermatophytic tinea pedis of interdigital type: a small clinical study. *J Eur Acad Dermatol Venereol* 2009; **23**: 203-204 [PMID: 18452528 DOI: 10.1111/j.1468-3083.2008.02783.x]
- 74 **Sotiriou E**, Panagiotidou D, Ioannides D. 5-Aminolevulinic acid photodynamic therapy treatment for tinea cruris caused by *Trichophyton rubrum*: report of 10 cases. *J Eur Acad Dermatol Venereol* 2009; **23**: 341-342 [PMID: 18637974 DOI: 10.1111/j.1468-3083.2008.02880.x]
- 75 **Kohl E**, Torezan LA, Landthaler M, Szeimies RM. Aesthetic effects of topical photodynamic therapy. *J Eur Acad Dermatol Venereol* 2010; **24**: 1261-1269 [PMID: 20236377 DOI: 10.1111/j.1468-3083.2010.03625.x]
- 76 **Dover JS**, Bhatia AC, Stewart B, Arndt KA. Topical 5-aminolevulinic acid combined with intense pulsed light in the treatment of photoaging. *Arch Dermatol* 2005; **141**: 1247-1252 [PMID: 16230562 DOI: 10.1001/archderm.141.10.1247]
- 77 **Ruiz-Rodríguez R**, López L, Candelas D, Pedraz J. Photorejuvenation using topical 5-methyl aminolevulinic acid and red light. *J Drugs Dermatol* 2008; **7**: 633-637 [PMID: 18664154]
- 78 **Szeimies RM**, Lischner S, Philipp-Dormston W, Walker T, Hiepe-Wegener D, Feise K, Podda M, Prager W, Kohl E, Karrer S. Photodynamic therapy for skin rejuvenation: treatment options - results of a consensus conference of an expert group for aesthetic photodynamic therapy. *J Dtsch Dermatol Ges* 2013; **11**: 632-636 [PMID: 23650971 DOI: 10.1111/ddg.12119]
- 79 **Lehmann P**. Side effects of topical photodynamic therapy. *Hautarzt* 2007; **58**: 597-603 [PMID: 17579821 DOI: 10.1007/s00105-007-1363-4]
- 80 **Park JY**, Jang YH, Kim YS, Sohn S, Kim YC. Ultrastructural changes in photorejuvenation induced by photodynamic therapy in a photoaged mouse model. *Eur J Dermatol* 2013; **23**: 471-477 [PMID: 23797711 DOI: 10.1684/ejd.2013.2050]
- 81 **Marmur ES**, Phelps R, Goldberg DJ. Ultrastructural changes seen after ALA-IPL photorejuvenation: a pilot study. *J Cosmet Laser Ther* 2005; **7**: 21-24 [PMID: 16020212 DOI: 10.1080/147641700510037725]

**P- Reviewers:** Hu SCS, Kaliyadan F, Katiyar SK, Vasconcellos C  
**S- Editor:** Ma YJ **L- Editor:** A **E- Editor:** Wu HL





百世登

**Baishideng**®

Published by **Baishideng Publishing Group Co., Limited**

Flat C, 23/F., Lucky Plaza, 315-321 Lockhart Road,

Wanchai, Hong Kong, China

Fax: +852-31158812

Telephone: +852-58042046

E-mail: [bpgoffice@wjgnet.com](mailto:bpgoffice@wjgnet.com)

<http://www.wjgnet.com>

