

Challenges in restoration of extensor tendons function at the hand

Andrea Leti Acciaro¹, Giulia Colzani¹, Marta Starnoni^{2,3}, Roberto Adani¹

¹Division of Hand Surgery and Microsurgery – Modena University Hospital; ²Division of Plastic Surgery – Modena University Hospital; ³Clinical and Experimental Medicine PhD Program, University of Modena and Reggio Emilia, Modena, Italy.

Abstract. *Introduction:* The authors discuss challenges in extensor function restoration at the finger level following distal posterior interosseous or tendon complex injuries, according to the typologies of lesions or the specific patient requirements. *Materials:* The authors report on two cases describing challenging resolutions. One patient with EDC lag from zone 6B to 8 requiring FCU prolonged with cadaveric grafts. One young patient with distal posterior interosseous lesion requiring selective tendon transfers to EPL and EIP to restore selective and autonomous index extension. *Results:* In both cases the main goals were obtained, achieving high index of patient satisfaction and excellent outcomes with the restoration of the extension of the fingers. *Conclusions:* In distal posterior interosseous nerve lesion, high demanding patients may require selective function to restore fine motor skills, such as autonomous index extension. In extensor tendons loss of substance from zone 6 to 8, involving musculotendinous junction proximally and short remnants distally, by-pass tendon transfer prolonged with cadaveric grafts is required. The authors highlight the techniques available as escape plan according to the necessary solutions.

Key words: radial nerve lesion, hand tendon defect, extensor tendons, tendon transfer, tendon graft

Introduction

Tendon transfers in hand surgery involved a wide number of techniques with the purpose of restoration of one or more motor functions (1-8). The deficit can result from tendon or nerve damage. The surgical choices are determined by many factors: the damage itself, the type of lost function, the time elapsed since the initial injury and many other conditions related to the patient (age, comorbidities, joint stiffness, presence of scars, surrounding soft tissues conditions).

In this scenario, the restoration of finger extension is crucial for a complete functionality of the hand, especially in highly demanding people (6, 7).

The loss of finger extension can be secondary to tendon ruptures or to paralysis of the posterior interosseous nerve. In the first case, palliative surgery is

proposed when there is a loss of substance due to in-veterate damage or bad tendon quality which does not allow direct repair (e.g., rheumatoid arthritis). When a nerve paralysis subsists, in absence of spontaneous recovery after one year from the injury or after a failed repair, tendon transfers are proposed and they can be an early first choice in elderly patients (1-3).

This given, planning a tendon transfer surgery for finger extension restoration must consider all the issues related to the injury and the patient, and can include a wide range of possibilities.

When the damage involves the extensor tendons in zone 6-8 with a major loss of substance, the complexity of the treatment increases due to the possible need of grafts (4, 5).

In this article we describe two different cases of palliative transfers in order to restore finger extension

after a tendinous and nervous lesion respectively, focusing on the challenge of planning the best surgery for each one. The procedures were strongly patient-centered and differed enough from the traditional biomechanics of the most common tendon transfers. With this analysis we insist on the need to personalize the treatment, considering above all the functional requests of each patients, and trying to adapt and modify the traditional techniques to each specific case.

Case series

Patient 1

A 65-year-old man came to our attention complaining deficit of long fingers' extension after a previous ORIF of a distal radius fracture. His clinical history was unremarkable, with a good general health status. The surgical procedure was performed 4 months before in another hospital and consisted of ORIF with a volar locking plate. Subsequently, he started the standard rehabilitation program in order to recovery a satisfactory range of motion of the wrist. From the very beginning, however, he noticed the inability to extend the third and fourth fingers, so he decided to come to our hospital. Physical examination revealed a complete loss of extension of the third and fourth finger at the metacarpo-phalangeal joint level, with just a partial deficit at the second and at the fifth finger (Fig.1). We hypothesised the rupture of the extensor digitorum

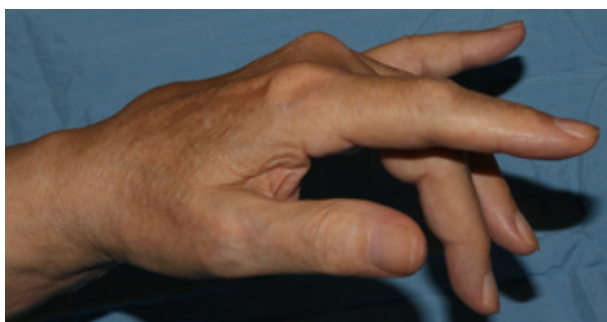

Figure 1: Preoperative features of the EDC deficit at the left hand. The major extension lag is recorded at the central long fingers due to the residual function of the extensor proprius of the second and little finger.

communis (EDC) at the wrist level, with preservation of the extensor indicis proprius (EIP) and extensor digiti minimi (EDM). We prescribed a scan that confirmed the complete lesion of the EDC at the wrist level with degeneration and loss of substance of the tendons. A CT-scan was performed that excluded any dorsal protrusion of the screws potentially responsible of tendon damage. After these exams, in the absence of any comorbidities such inflammatory-degenerative arthritis, we assumed that the rupture occurred at the time of the trauma through a crushing mechanism with his wristwatch during the forced hyperextension of the wrist in the fall, which was then passed unacknowledged. The closeness of the lesion to the myotendinous junction (MTJ) the muscular retraction, the tendon residual gap and degeneration, (Fig.2) and the time elapsed after trauma, convinced us not to consider a secondary repair even with grafts. We decided to transfer the flexor carpi ulnaris (FCU) to the EDC by an intercalated cadaver allograft (extensor hallucis longus). The proximal portion of the graft was sutured on the FCU, then the distal stump was divided in two heads, each of them sutured to the corresponding remnant of the third and fourth EDC (Fig.3). All the sutures were performed according to the side-to-side technique described by Friden and Lieber (9), because of its properties in strength and gliding, and adaptability in mismatched tendon size/shape and small distal remnants. We decided not to suture the second and fifth EDC because of the presence of intact EIP and EDM, the preserved extension pulling effect from the adjacent juncturae, and the observation in rheumatoid hands that the reconstruction of two fingers had better outcomes than surgery extended to more fingers. Postoperatively a plaster cast was applied in order to protect the sutures, but physical therapy was started immediately, removing the cast during active assisted mobilization.

Patient 2

A 17-year-old boy came to our attention after a lacerated wound on the dorsal aspect of the proximal third of his right forearm, sutured 14 months before in another hospital. After the trauma, he showed a paralysis of the extensor pollicis longus (EPL), EIP and

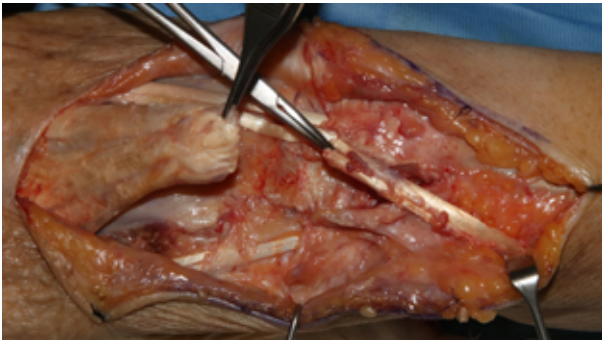


Figure 2: Intra-operative aspects of the EDC lesion occurred by the subcutaneous crushing and sliding action of the wristwatch.

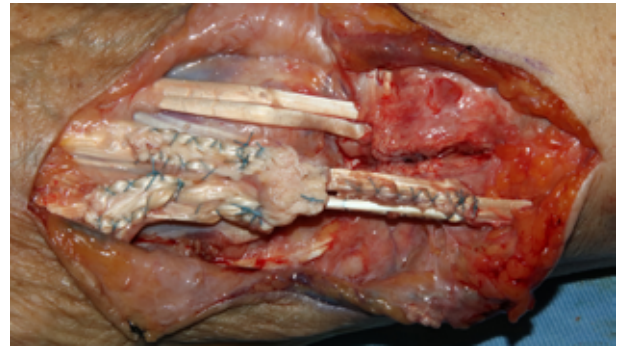


Figure 3: The FCU was transferred to the EDC and prolonged with a cadaveric allograft. All sutures were side-to-side ones, useful to achieve high strength and gliding.

EDM related to a partial posterior interosseous nerve (PIN) injury. The EDC had limited independent action whereas the EIP has independent muscle belly and no juncturae being able to perform specific actions such as pushing a button and pointing. Following the specific request of the patient to restore the independent extension of the thumb and second finger, we performed a transfer of the palmaris longus (PL) on the EPL and of the flexor digitorum superficialis (FDS) of the third finger on the EIP through the interosseous membrane in order to provide a reliable selective function of the index (Fig.5). We agreed not to treat the EDM deficit due to the presence of an active extension of the little finger provided by the EDC. A plaster cast was applied to protect the sutures, but physical therapy was started immediately, removing the cast during active assisted mobilization.

Results

In both cases, during the follow-up, the active and passive range of motion (ROM) of the wrist, metacarpo-phalangeal and inter-phalangeal joints of the long fingers and thumb were recorded. The grip and pinch strength were detected using the Jamar and pinch dynamometers. The subjective patient satisfaction was assessed. Because of such selective procedures, the DASH score was considered not useful in assessing the global functional recovery.

25 days after surgery the former patient started to play guitar, and at three months follow-up he re-

covered excellent extension of the fingers also during wrist extension (Fig.4), with no loss of finger flexion in fingertip-to-palm distance. He referred relevant satisfaction. Clinically, only a 15% of reduction in wrist flexion according to the FCU transfer was noted.

In the latter patient voluntary selective complete extension of the index and thumb (Fig.6) was achieved at 40 days post-operatively. No bowing of the donor digit was evident, and no reduction in flexion and grasping of the fingers was present.

Discussion

In our first patient the tendon gap with muscular retraction led us to choose a different motor to restore the lost function, and a flexor of the carpus was transferred and prolonged with a graft. Management of chronic lesion in extensor zone 6 to 8 may be very challenging for the possible proximal muscular retraction and distal short and degenerate remnants that limit the use of simple tendon grafts. With a transfer we can assure the recovery of valid strength. Moreover, the tightness of the sutures performed side-to-side ensure early mobilization with a lower risk of adhesions.

The second patient was treated with the consideration that he expressed the willingness to maintain an independent extension of the index and the thumb. The transfer for the EIP was passed through the interosseous membrane in order to provide a pulling vector as biomechanically physiological as possible. The third FDS was preferred for the transfer instead of the fourth, because

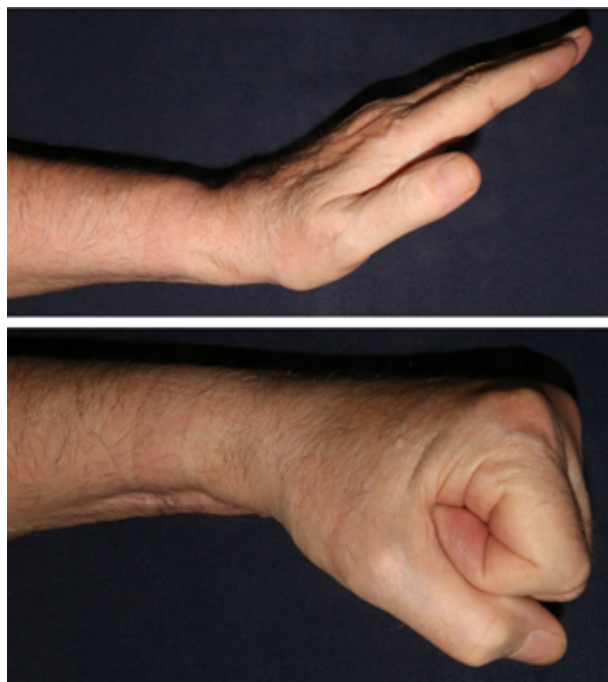


Figure 4: Clinical follow up with complete and excellent function in extension and flexion of the long fingers.

it is more important for grasping. The authors excluded (a priori) the surgical revision of the PIN to avoid any possible further iatrogenic damage of the nerve, considering the residual preserved EDC function.

Tendon transfers are performed to restore the missing function and performance at the hand and fingers. In selected, high demanding patients who also request fine motor skills, the other hand the tendon transfer harvesting is complicated by associated laceration, loss of tendon substance, and level of tendon lesion such as small distal remnants and proximal MTJ level (3, 6). In tendon reconstruction, it is needed to reestablish not only tendon continuity, but also gliding environments and surrounding structures. In presence of distal EDC lesion (zone 6A) the surgeon faces with challenges due to the short distal remnants, where the suture may avoid involvement of the extensor apparatus at the MPJ and the juncturae that allow extension by pull from adjacent mechanisms (8). In this case the authors proposed the side-to-side technique as escape plan (9, 10), achieving a short but strong suture with an excellent gliding surface, which is also useful for an early active rehabilitation program. When MTJ is damaged at the proximal level, another

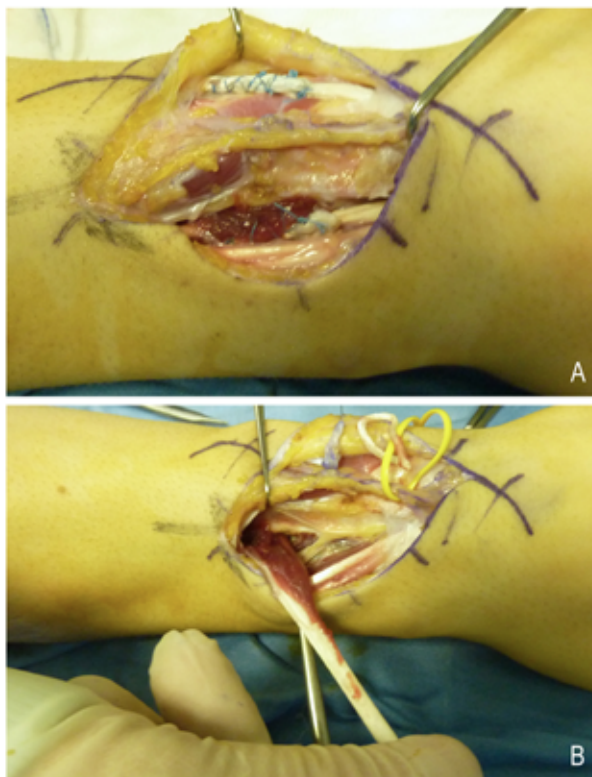


Figure 5: (A) Intra-operative features of the PL to EPL (passed into the second compartment) and III FDS to EIP transfers, harvested to separately address the extensors of the thumb and index. (B) Particular of the biomechanically recommended trans-membrane transfer of the III FDS.

motor unit is preferred. This is generally associate with a wide lesion and extensor cadaveric tendon allografts which are promising solutions to prolong tendon transfer by using sterilized and deep-freezing graft without decellularization. This results in outcomes comparable to autografting and doesn't produce an immunogenic reaction (3-13). In presence of chronic irreparable distal posterior interosseous nerve lesion and the more relevant EPL function restoring in young and high demanding patients, selective tendon transfers and the selective extension of the index separately from the rest of the fingers may be utilized. The authors addressed the issue of different transfers for each functional skill requested by the patient (Fig.5A). Palmaris longus (PL) to EPL and FDS of the middle finger to EIP were performed because it appeared logical to separately and address the extensors of the thumb and index according to the patient's desires. The authors underlined the relevance of

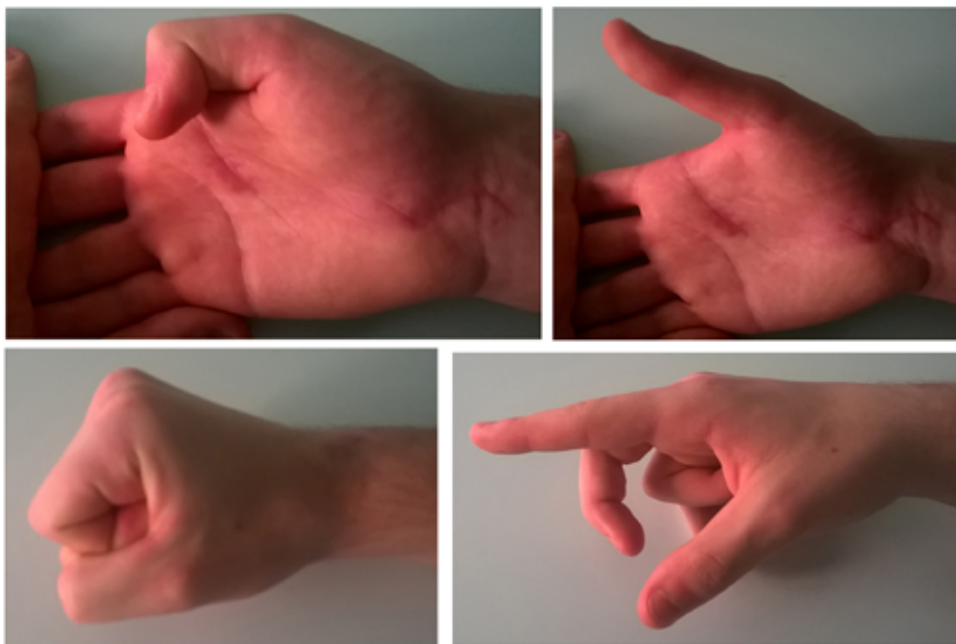


Figure 6: Clinical follow up with complete and useful extension and range of motion of the thumb and index, separately.

FDS transposition from the volar to the dorsal aspect through the interosseous membrane (Fig.5B) in order to provide a near to physiological, biomechanical vector of pull (6). The authors selected the third FDS because of the more relevant role of the flexors tendons of the ring finger for strength during the grasping of the hand.

Tendon and nervous damages are conditions that lend themselves to multiple surgical solutions. Many factors related to the patient and the type and timing of injury can reorientate different therapeutic choices, that could differ in many details and make difficult any attempt for standardization. Not always, a tendon or nervous lesion can be repaired directly. Most of the time we must approach chronic situations or multi-operated or traumatized sites. Tendon transfers can be an effective solution under specific conditions.

In all cases, the post-operative rehabilitation program is crucial for the final functional outcome, and must provide early active assisted mobilization.

Conclusion

Tendon transfers surgery may help establishing a finger extension both in chronic posterior interosseous nerve and tendons lesions. Several procedures are

available and offer excellent outcomes, but particular challenges are still evident and rely on the surgeon surgical skills (14-19). In distal posterior interosseous nerve lesion high demanding patients may require selective function to restore fine motor skills, such as autonomous index extension to push or indicate. In the presence of soft tissue scaring (20), the nerve surgical revision may have no indication in order to avoid proximal iatrogenic nerve damaging of the preserved wrist and EDC extension. The authors proposed selective tendon transfers to address selective extension of thumb and index finger separately from the rest of the fingers, highlighting the functional and biomechanical advantages in FDS going through the interosseous membrane. On the other hand, challenges are recorded in extensor tendons loss of substance from zone 6 to 8, involving MTJ proximally and short remnants distally, and in myostatic contracture in longstanding lesion. These both require tendon transfer and not only tendon graft. The authors described the strength and gliding advantages in side-to-side tendon suture and cadaveric allografts in FCU prolonged by EHL as bypass tendon transfer in EDC reconstruction. Proper postoperative care is crucial to the outcomes of the tendon transfer. Early active, assisted by qualified

physiotherapy rehabilitation program is mandatory (21), and the techniques selected by the authors are useful to achieve these programs.

Conflict of Interest: Each author declares that he or she has no commercial associations (e.g. consultancies, stock ownership, equity interest, patent/licensing arrangement etc.) that might pose a conflict of interest in connection with the submitted article

References

- Sammer DM, Chung KC. Tendon transfers: part I. Principles of transfer and transfers for radial nerve palsy. *Plast Reconstr Surg*. 2009, 123:169-177.
- Lowe JB, Sen SK, Mackinnon SE. Current approach to radial nerve paralysis. *Plast Reconstr Surg*. 2002, 110:1099-1113.
- Chattopadhyay A, McGoldrick R, Umnsky E, Chang J. Principles of tendon reconstruction following complex trauma of the upper limb. *Semin Plast Surg*. 2015, 29:30-39.
- Al-Quattan MM, Al Mohrij SA. A modified technique of two-staged extensor tendon reconstruction in zones 6-8 in a patient with absent palmaris/plantar tendons: A case report. *Int J Surg Case Reports*. 2019, 55:99-102.
- Oberlin C, Atchabayan A, Salon A, Bhatia A, Ovieve JM. The by-pass extensor tendon transfer. A salvage technique for loss of substance of the extensor apparatus in long fingers. *J Hand Surg Br*. 1995, 20(3):392-7.
- Krishnan KG, Schackert G. An analysis of results after selective tendon transfers through the interosseous membrane to provide selective finger and thumb extension in chronic irreparable radial nerve lesion. *Am J Hand Surg*. 2008, 33:223-31.
- Ropars M, Dreano T, Siret P, Belot N, Langlais F. Long-term results of tendon transfers in radial and posterior interosseous nerve paralysis. *J Hand Surg Br*. 2006; 31:502-6.
- Leti Acciaro A, Pilla F, Colzani G, Corradi N. A new sign allowing diagnosis in the pathologies of the extensor tendons of the hand. *Injury*. 2018, 49:1119-1125.
- Friden J, Tirrel TF, Bhola S, Lieber L. The mechanical strength of the side-to-side tendon repair with mismatched tendon size and shape. *J Hand Surg Eu*. 2015, 40:239-245.
- Schleh AC, Gohritz A, Wilmink B, Friden J, Schaefer DJ. Technical tip: side-to-side tendon suture as escape plan during extensor indicis tendon plasty in distal extensor pollicis longus rupture. *GMS Ger Plast Reconstr Aesthet Surg*. 2015,5:DOC07.
- Xie RG, Tang JB. Allograft tendon for second-stage tendon reconstruction. *Hand Clin*. 2012, 28(4):503-9.
- Chung US, Kim JH, Seo WS, Lee KH. Tendon transfer or tendon graft for ruptured finger extensor tendons in rheumatoid hands. *J Hand Surg Eur*. 2010, 35:279.
- Nakamura S, Katsuki M. Tendon grafting for multiple extensor tendon ruptures of fingers in rheumatoid hands. *J Hand Surg Br*. 2002, 27:326-8.
- Starnoni M, Pinelli M, De Santis G. Surgical Wound Infections in Plastic Surgery: Simplified, Practical, and Standardized Selection of High-risk Patients. *Plast Reconstr Surg Glob Open*. 2019;7(4):e2202. Published 2019 Apr 23. doi:10.1097/GOX.0000000000002202
- Starnoni M, Colzani G, De Santis G, Leti Acciaro A. Management of Locked Volar Radio-ulnar Joint Dislocation. *Plast Reconstr Surg Glob Open*. 2019;7(10):e2480. Published 2019 Oct 30. doi:10.1097/GOX.0000000000002480
- Starnoni M, Colzani G, De Santis G, Acciaro AL. Median Nerve Injury Caused by Screw Malpositioning in Percutaneous Scaphoid Fracture Fixation. *Plast Reconstr Surg Glob Open*. 2019;7(6):e2292. Published 2019 Jun 25.
- Starnoni M, De Santis G, Pinelli M. Fibula Free Flap Elevation without Tourniquet: Are Harmonic Scalpel Shears Useful?. *Plast Reconstr Surg Glob Open*. 2019;7(9):e2409. Published 2019 Sep 10. doi:10.1097/GOX.0000000000002409
- Starnoni M, Baccarani A, Pinelli M, Pedone A, De Santis G. Tattooing of the nipple-areola complex: What not to do. A case series. *Ann Med Surg (Lond)*. 2020 May 30;55:305-307. doi: 10.1016/j.amsu.2020.05.041. PMID: 32551103; PMCID: PMC7287191.
- Starnoni M, Pinelli M, Franceschini G, De Santis G. A Rare Case of Nipple-Areolar Complex Partial Necrosis following Micropigmentation: What to Learn? *Plast Reconstr Surg Glob Open*. 2019 Nov 27;7(11):e2494. doi: 10.1097/GOX.0000000000002494. PMID: 31942292; PMCID: PMC6908356.
- Benanti E, De Santis G, Leti Acciaro A, Colzani G, Baccarani A, Starnoni M. Soft tissue coverage of the upper limb: A flap reconstruction overview. *Ann Med Surg (Lond)*. 2020 Nov 6;60:338-343. doi: 10.1016/j.amsu.2020.10.069. PMID: 33224487; PMCID: PMC7666305.
- Yew Ng C, Chalmer J, Macdonald DJM, Mehta SS, Nuttal D, Watts AC. Rehabilitation regimens following surgical repair of extensor tendon injuries of the hand – a systematic review of controlled trials. *J Hand Microsurg*. 2012,4(2): 65-73.

Correspondence:

Arrived: 10 May 2020

Accepted: 29 July 2020

Dr. Marta Starnoni

Division of Plastic Surgery, Modena University Hospital,

Largo Pozzo 71, 41124 Modena, Italy

Phone: +393208268625

Email: martastarn@gmail.com