

Contents lists available at [ScienceDirect](https://www.sciencedirect.com)

International Journal of Surgery Case Reports

journal homepage: www.casereports.com

Surgical stabilization of severe flail chest with Judet and Sanchez-Lloret plates. A case report

Alessandro Stefani^{a,*}, Francesco Tormen^a, Adriana Scamporlino^{a,b}, Pamela Natali^a, Giorgio Cavallesco^c, Uliano Morandi^a^a Division of Thoracic Surgery, University of Modena and Reggio Emilia, Modena, Italy^b Clinical and Experimental Medicine PhD Program, University of Modena and Reggio Emilia, Modena, Italy^c Division of Thoracic Surgery, University of Ferrara, Ferrara, Italy

ARTICLE INFO

Article history:

Received 5 March 2021

Accepted 18 March 2021

Available online 22 March 2021

Keywords:

Thoracic trauma

Flail chest

Surgery

Case report

ABSTRACT

INTRODUCTION: Flail chest is now usually treated by conservative methods and surgical fixation remains indicated in selected cases. Different techniques can be used for fixation. The aim of this paper is to present a case in which Judet and Sanchez-Lloret plates were employed and to discuss the usefulness of this traditional technique.

PRESENTATION OF CASE: A 79-year-old woman was admitted for left thoracic trauma with severe antero-lateral flail chest. She was affected by COPD with chronic respiratory failure, ischemic heart disease, autoimmune thrombocytopenia treated on chronic steroid therapy and severe osteoporosis. CT-scan detected multiple rib fractures, left hemothorax and lung contusions. An initial conservative treatment of flail chest involved compressive bandage and then internal pneumatic stabilization in ICU, but it failed. The patient underwent successful surgical treatment of the flail chest by fixation of the anterior fractures from the second to the eight rib. Judet and Sanchez-Lloret plates were used. A bilateral pneumonia developed during the rehabilitation period and the patient died two months after operation.

DISCUSSION: Judet and Sanchez-Lloret plates represent a traditional technique for fixation of flail chest. This technique is less and less used and progressively replaced by newer materials, especially titanium plates with screws or intramedullary struts. Our patient had multiple comorbidities and a very fragile bones that advised against use of screws or intramedullary struts.

CONCLUSION: Judet and Sanchez-Lloret plates can be still considered a useful tool for the fixation of flail chest in cases of thin and fragile bones.

© 2021 The Authors. Published by Elsevier Ltd on behalf of IJS Publishing Group Ltd. This is an open access article under the CC BY-NC-ND license (<http://creativecommons.org/licenses/by-nc-nd/4.0/>).

1. Introduction

Flail chest (FC) is defined as a segment of the chest wall moving paradoxically with respect to the rest of the chest wall during respiration, resulting from multiple bifocal fractures of the ribs. FC can be a life-threatening condition, leading to acute respiratory distress syndrome [1]. Surgical fixation of FC has never gained widespread acceptance and the management of FC has gradually changed over the years, as a consequence of the improvement in ventilatory and intensive care techniques. Therefore, the mainstay of FC treatment has shifted from surgical stabilization towards more conservative methods [2,3]. However, there are evidences suggesting that surgi-

cal treatment remains the best option for FC in selected cases [4–7]. These are the cases in which the respiratory distress is mainly due to the paradoxical movements of the chest wall, and the patient cannot be weaned from the mechanical ventilation [8].

The aim of the surgical treatment is the resolution of the paradoxical movement of chest wall through rib fixation. A wide variety of techniques has been reported and several different materials have been used, such as plates, bars with or without screws, struts, wires and splints [9–13]. In this paper we describe a case of a severe FC, in a severely-ill patient, successfully fixed with Judet plates (JP) and Sanchez-Lloret plates (SLP). The aim of this report is to show that this traditional technique, far from being considered obsolete, remains a simple, safe and effective method for FC stabilization.

This work has been performed in line with SCARE criteria [14].

2. Case presentation

A 79-year-old woman was admitted to the Emergency Department for a blunt thoracic trauma from an accidental fall. She was a

* Corresponding author at: Division of Thoracic Surgery, University of Modena and Reggio Emilia, Via del Pozzo 71, 41120, Modena, Italy.

E-mail addresses: Alessandro.stefani@unimore.it (A. Stefani), tormen.francesco@gmail.com (F. Tormen), adrianascamporlino@gmail.com (A. Scamporlino), natali.pamela@aou.mo.it (P. Natali), cgg@unife.it (G. Cavallesco), uliano.morandi@unimore.it (U. Morandi).

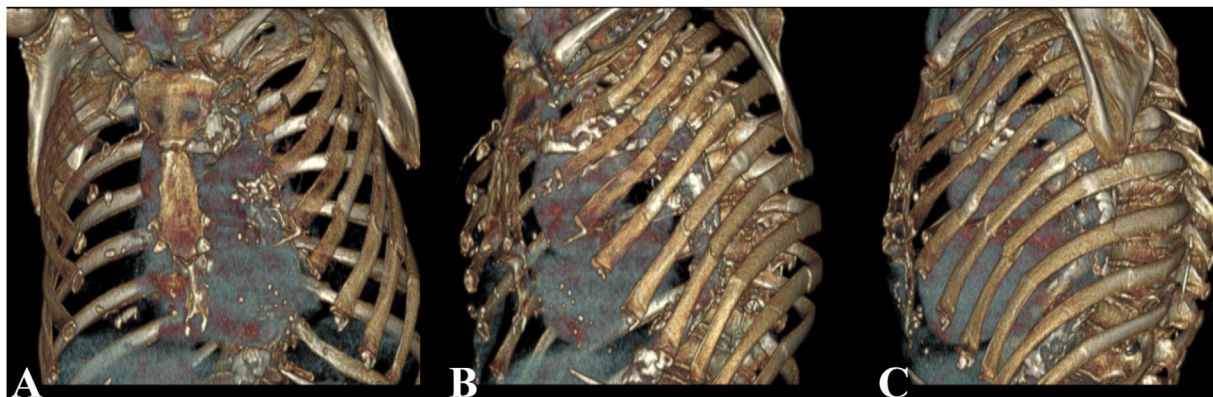


Fig. 1. Three-dimensional CT-scan reconstructions showing multiple double or triple rib fractures from the second to the eighth rib, with crushing of the anterolateral chest wall, and single fractures of the ninth and tenth rib.

former heavy smoker affected by COPD on chronic respiratory failure, treated with long-term oxygen therapy. She was also affected by mild renal failure, ischemic heart disease, autoimmune thrombocytopenia treated with long-term steroid therapy and severe osteoporosis. On physical examination, a severe left anterolateral FC was present. Chest x-rays detected multiple rib fractures on the left side, from the second to the tenth rib. CT-scan detected a left hemothorax and multiple lung contusions and precisely identified the site and the number of rib fractures (Fig. 1a,b,c). The emergency treatment required a closed-tube thoracostomy, allowing the evacuation of 1300 cc of blood, and blood transfusion. The patient was transferred in our Unit and the FC was initially treated with a conservative approach by external stabilization with a compressive bandage. A progressive impairment of the respiratory function was observed during the first week, requiring admission to the ICU. After two days of non-invasive ventilation the patient was intubated. Because the FC was still unstable, a treatment with internal pneumatic stabilization was started and continued for two weeks. During this time, pulmonary contusions progressively disappeared, atelectasis was successfully treated with repeated bronchial aspirations and a tracheostomy was performed. However, repeated attempts to wean the patient from the ventilatory support failed, due to the persistent severe instability of the left chest wall. Therefore, the patient underwent surgical fixation of the FC, one month after the hospital admission.

An anterolateral thoracotomy was performed along the fourth intercostal space. The serratus anterior muscle insertions were divided from the second to the seventh rib; a short segment of the anterior aspect of latissimus dorsi and of the lateral aspect of pectoralis major were sectioned. The pleural cavity was entered through the fifth intercostal space and explored through a thoracoscope. Six-hundred ml of fluid and a residual clotted hemothorax were evacuated. No other lesions were found. Two pleural drains were positioned before starting the costal stabilization. All the anterior fractures were fixed, from the second to the eighth rib. The ribs were exposed, in order to obtain a good placement of the metal plates; the dissection was performed only in the site of the fracture, preserving the integrity of the rest of the intercostal muscle. The dislocated segments were manually reduced. The double anterior fractures of the second and fourth rib were fixed with a SLP (one for each rib), while the single anterior fractures of the third, fifth, sixth and seventh ribs were fixed with a JP (one for each rib). To reach the anterior fracture of the eighth rib a second short incision was needed, caudally to the thoracotomy, and the fracture was fixed with a JP. Once the metal plates were placed, they were reinforced with a heavy non-absorbable suture at each anchoring site (Fig. 2). Chest wall was closed in layers, and a compressive bandage was applied. The operation time was 90 min.

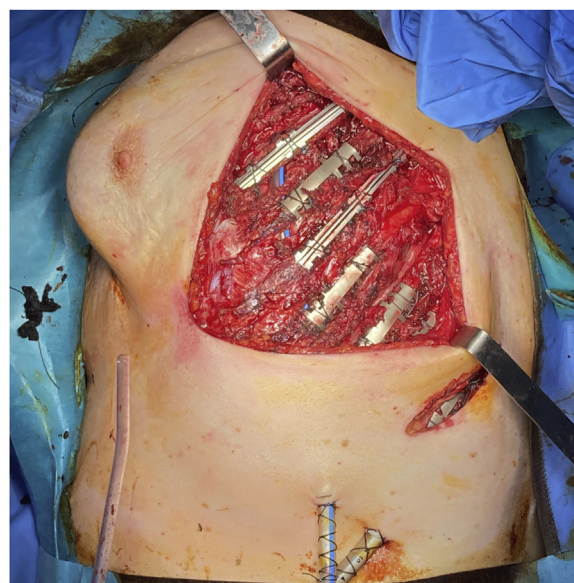

Fig. 2. Intra-operative pictures at the end of the fixation, showing the metallic plates in place: two SLP on the second and fourth rib and six JP on the third, fifth, sixth, seventh and eighth rib. The sutures around the plates are also visible, two for each plate.

Postoperative chest-x-ray showed the correct positioning of the plates (Fig. 3). Mechanical ventilation was continued for three days and then weaning was started. The weaning was completed in two weeks and the patient was supported through non-invasive ventilation for seven days more. No paradoxical movement of the left chest wall was observed during spontaneous respiration and the chest wall adequately expanded. The patient left the ICU 49 days after the admission and was sent to an inpatient rehabilitation facility. A respiratory support with a high-flow nasal cannula was initially necessary, then the support was shifted to conventional oxygen therapy, similar to that previously required by the patient. Unfortunately, an unexpected bilateral pneumonia developed during recovery, with a rapid deterioration of the respiratory function. The patient was readmitted to the ICU and died 6 days after, that is 3 months after the trauma.

3. Discussion

Currently, it is common for patients with FC to be managed with non-surgical methods, such as conservative methods (external compressive bandage of the chest, pain control, aggressive pulmonary physiotherapy, non-invasive ventilation) or internal

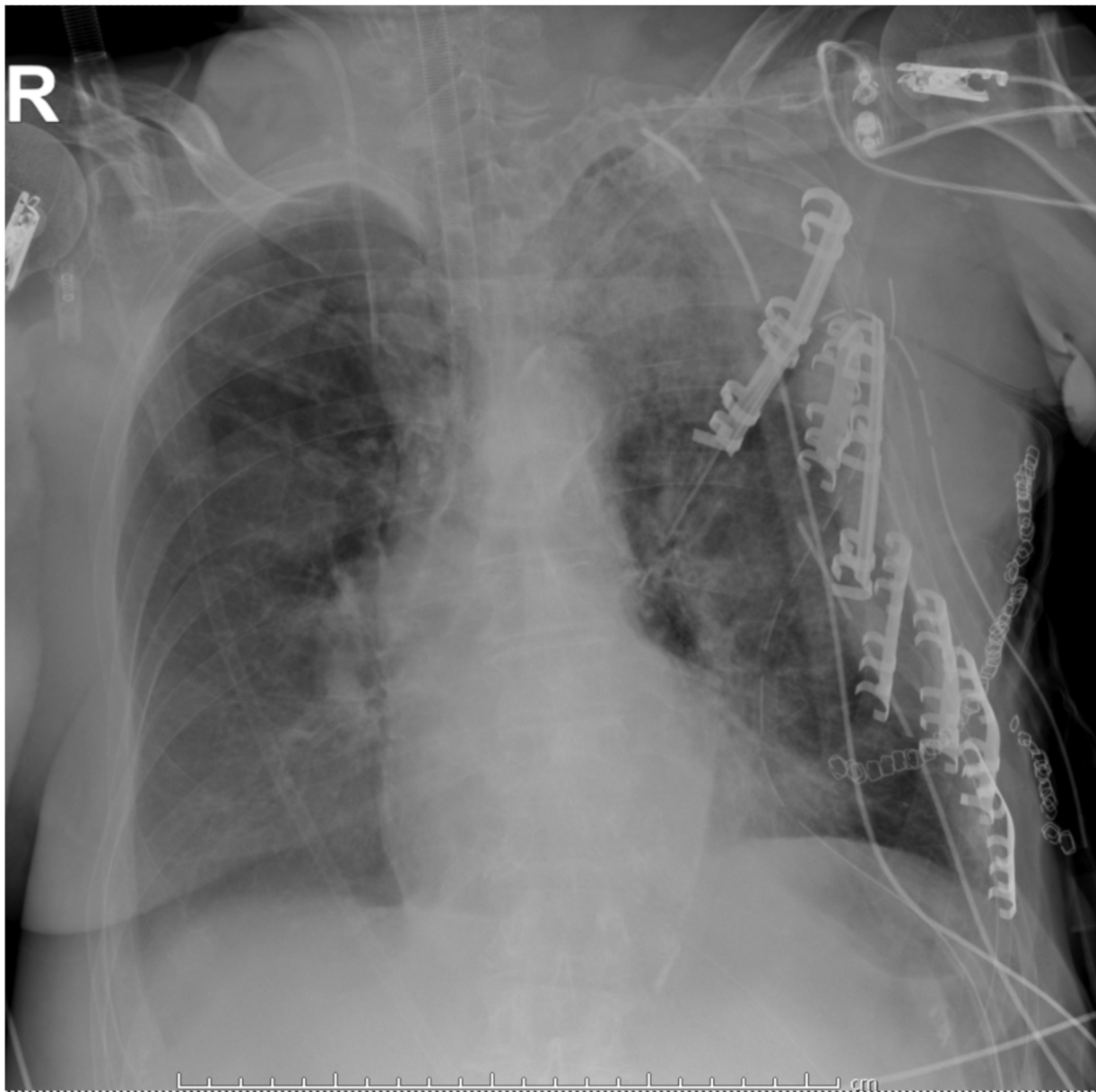


Fig. 3. Post-operative chest roentgenogram showing the left chest armor made of metallic plates.

pneumatic stabilization through invasive mechanical ventilation [8,15]. Although surgical fixation of flail segments has never gained widespread acceptance, there is now evidence that it may be indicated in selected cases [4–6]. A recent meta-analysis by Apampa and colleagues included four randomized controlled trials of surgical versus non-surgical treatment [7]: lower mortality, lower risk of pneumonia, reduced need of tracheostomy and decreased duration of mechanical ventilation and ICU stay were found as a result of fixation, compared to non-surgical treatment. However, although the published literature on surgical fixation has been rapidly growing, this technique remains unfamiliar to most surgeons and it now seems to be underutilized [16,17].

It is generally accepted that surgical fixation may be indicated in patients presenting with an acute respiratory distress which needs a ventilator support, provided that such a clinical condition is definitely sustained by the paradoxical movements of the FC [8]. In this case, once the respiratory and hemodynamic conditions of the patient have been stabilized, the operation should not be delayed. If other lung injuries or clinical conditions significantly contribute

to the respiratory distress (*i.e.* pulmonary contusions) and/or to the need of mechanical ventilation (*i.e.* cerebral lesions), a conservative treatment should be preferred [18]. The surgical treatment should be considered after all other traumatic lesions have disappeared but the FC remains unstable and it is identified as the only possible cause of a persistent respiratory distress, in the absence of other clinical conditions contraindicating an operation. Our case belongs to this second clinical scenario. The operation was delayed for a few days because of several co-morbidities of the patient. Moreover, the severe osteoporosis and long-term steroid therapy could have made the fixation troublesome or even ineffective. This high operative risk led us to an extreme attempt to wean the patient from the mechanical ventilation, before proposing surgical intervention.

Many different techniques have been described for rib fixation, either intramedullary or external to the fractured bones. Usually, not all the fractures of a FC require fixation to achieve stabilization [7]. In our patient the fixation of the anterior fractures was adequate to stabilize the FC. A great variety of materials for fixation has been proposed. Judet plates (for simple fractures) and Sanchez-

Lloret plates (for comminuted fractures) have been used in the past [9,13,19], but currently they are much less employed and replaced by newer materials, such as contoured titanium plates fixed to the ribs with screws or intramedullary splints [12]. But our patient was old and on long-term steroid therapy and she was affected by severe osteoporosis. Ribs were thin and extremely fragile. Screws would not have probably held on and intramedullary splints would have broken the bone from the inside. This is why we decided to use JP and SLP. The plates were placed over the fracture line and, by gradually bending the lateral hooks, they progressively grasped the rib and were firmly anchored to the bone. Thus, in this complex case, JP and SLP provided a simple, quick and effective fixation of fractured ribs without further fracturing or damaging the bone.

4. Conclusions

Several different materials are available for rib fixation of a FC. At present titanium plates secured with screws represent the preferred technique, while JP and SLP are less and less used. However, the traditional technique using this type of material can still be useful, especially in cases of thin and fragile bone.

Declaration of Competing Interest

The authors report no declarations of interest.

Sources of funding

This research did not receive any specific grant from funding agencies in the public, commercial, or not-for-profit sectors.

Ethical approval

Ethical board approval is not required for a single case report in our Center.

Consent

Written informed consent was obtained from the patient for publication of this case report and accompanying images. A copy of the written consent is available for review by the Editor-in-Chief of this journal on request.

Author contribution

Francesco Tormen and Pamela Natali collected data. Alessandro Stefani and Francesco Tormen wrote the manuscript. Adriana Scamporlino, Giorgio Cavallesco and Uliano Morandi revised and approved the manuscript.

Registration of research studies

Not applicable.

Guarantor

Alessandro Stefani is the guarantor of this study.

Provenance and peer review

Not commissioned, externally peer-reviewed.

References

- [1] B.T. Fligel, F.A. Luchette, R.L. Reed, T.J. Esposito, K.A. Davis, J.M. Santaniello, et al., Half-a-dozen ribs: the breakpoint for mortality, *Surgery* 138 (2005) 717–723.
- [2] G.C. Clark, W.P. Schechter, D.D. Trunkey, Variables affecting outcome in blunt chest trauma: flail chest vs pulmonary contusion, *J. Trauma* 28 (1988) 298.
- [3] M. Freedland, R.F. Wilson, J.S. Bender, M.A. Levison, The management of flail chest injury: factors affecting outcome, *J. Trauma* 30 (December (12)) (1990) 1460–1468.
- [4] A.J.M. Cataneo, D.C. Cataneo, F.H.S. De Oliveira, K.A. Arruda, R. El Dib, P.E. De Oliveira Carvalho, Surgical versus nonsurgical interventions for flail chest, *Cochrane Database Syst. Rev.* 29 (2015), CD009919.
- [5] R.B. Beks, J. Peek, M.B. de Jong, K.J.P. Wessem, C.F. Oner, F. Hietbrink, et al., Fixation of flail chest or multiple rib fractures: current evidence and how to proceed. A systematic review and meta-analysis, *Eur. J. Trauma Emerg. Surg.* 45 (2019) 631–644.
- [6] J.A. Leinicke, L. Elmore, B.D. Freeman, G.A. Colditz, Operative management of rib fractures in the setting of flail chest: a systematic review and meta-analysis, *Ann. Surg.* 258 (2013) 914–921.
- [7] A.A. Apampa, A. Ali, B. Kadir, Z. Ahmed, Safety and effectiveness of surgical fixation versus non-surgical methods for the treatment of flail chest in adult populations: a systematic review and meta-analysis, *Eur. J. Trauma Emerg. Surg.* (2021), <http://dx.doi.org/10.1007/s00068-021-01606-2>, published online 6 Feb 2021.
- [8] H. Pan, S.B. Johnson, Blunt and penetrating injuries of the chest wall, pleura, diaphragm, and lungs, in: J. LoCicero III, R.H. Feins, Y.L. Colson, G. Rocco (Eds.), *Shield's General Thoracic Surgery*, 8th edition, Wolters Kluwer, 2018, chapter 110.
- [9] R. Judet, Costal osteosynthesis, *Rev. Chir. Orthop. Reparatrice Appar. Mot.* 59 (Suppl. 1) (1973) 334–335.
- [10] J. Borrelly, G. Grosdidier, B. Wack, Surgical treatment of flail chest by sliding staples, *Rev. Chir. Orthop. Reparatrice Appar. Mot.* 71 (1985) 241–250.
- [11] R.J. Landreneau, J.M. Hinson Jr., S.R. Hazelrigg, J.A. Johnson, T.M. Boley, J.J. Curtis, Strut fixation of an extensive flail chest, *Ann. Thorac. Surg.* 51 (1991) 473–475.
- [12] M. Bottlang, W.B. Long, D. Phelan, D. Fielder, S.M. Madey, Surgical stabilization of flail chest injuries with MatrixRIB implants: a prospective observational study, *Injury, Int. J. Care Injured* 44 (2013) 232–238.
- [13] H. Tanaka, T. Yukioka, Y. Yamaguti, S. Shimizu, H. Goto, H. Matsuda, et al., Surgical stabilization or internal pneumatic stabilization? A prospective randomized study of management of severe flail chest patients, *J. Trauma* 52 (2002) 727–732.
- [14] R.A. Agha, M.R. Borrelli, R. Farwana, K. Koshy, A. Fowler, D.P. Orgill, For the SCARE Group, The SCARE 2018 statement: updating consensus Surgical Case Report (SCARE) guidelines, *Int. J. Surg.* 60 (2018) 132–136.
- [15] N. Dehghan, C. de Mestral, M.D. McKee, et al., Flail chest injuries: a review of outcomes and treatment practices from the National Trauma Data Bank, *J. Trauma Acute Care Surg.* 76 (2014) 462–468.
- [16] J.C. Mayberry, L.B. Ham, P.H. Schipper, et al., Surveyed opinion of American trauma, orthopedic, and thoracic surgeons on rib and sternal fracture repair, *J. Trauma* 66 (2009) 875–879.
- [17] J.D. Richardson, G.A. Franklin, S. Heffley, et al., Operative fixation of chest wall fractures: an underused procedure? *Am. Surg.* 73 (2007) 591–597.
- [18] B.L. Pettiford, J.D. Luketich, R.J. Landreneau, The management of flail chest, *Thorac. Surg. Clin.* 17 (2007) 25–33.
- [19] D. Di Fabio, D. Benetti, M. Benvenuti, G. Mombelloni, Surgical stabilization of post-traumatic flail chest. Our experience with 116 cases treated, *Minerva Chir.* 50 (March) (1995) 227–233.

Open Access

This article is published Open Access at [sciencedirect.com](https://www.sciencedirect.com). It is distributed under the [IJSCR Supplemental terms and conditions](#), which permits unrestricted non commercial use, distribution, and reproduction in any medium, provided the original authors and source are credited.