



BRIEF COMMUNICATION

Mild malformations of cortical development in sleep-related hypermotor epilepsy due to *KCNT1* mutations

Guido Rubboli^{1,2} , Giuseppe Plazzi^{3,4}, Fabienne Picard⁵, Lino Nobili⁶, Edouard Hirsch⁷, Jamel Chelly⁸, Richard A. Prayson⁹, Jean Boutonnat¹⁰, Manuela Bramerio¹¹, Philippe Kahane¹², Leanne M. Dibbens¹³, Elena Gardella^{1,14}, Stéphanie Baulac^{15,16,17,*}  & Rikke S. Møller^{1,14,*}

¹Danish Epilepsy Centre, Filadelfia, Dianalund, Denmark

²University of Copenhagen, Copenhagen, Denmark

³Department of Biomedical and Neuromotor Sciences, University of Bologna, Bologna, Italy

⁴IRCCS Institute of Neurological Sciences, Bologna, Italy

⁵Department of Clinical Neurosciences, University Hospitals and Medical School of Geneva, Geneva, Switzerland

⁶Epilepsy Surgery Center, Niguarda Hospital, Milan, Italy

⁷INSERM Unité 964: Génétique et Physiopathologie des Maladies Neuro Développementales Epileptogènes Epilepsy Unit « Francis Rohmer », Hautepierre Hospital, University Hospital, Strasbourg, France

⁸Service de Diagnostic Génétique, Hôpital Civil de Strasbourg, Hôpitaux Universitaires de Strasbourg, Strasbourg, France

⁹Department of Anatomic Pathology, Cleveland Clinic, Cleveland, Ohio

¹⁰Département d'Anatomie et de Cytologie Pathologiques Institut de Biologie et de Pathologie CHU de Grenoble, Grenoble, France

¹¹Department of Pathology, Niguarda Hospital, Milan, Italy

¹²Neurology Department, Grenoble-Alpes University and Hospital, Grenoble, France

¹³Epilepsy Research Group, School of Pharmacy and Medical Sciences, University of South Australia and Sansom Institute for Health Research, Adelaide, Australia

¹⁴Institute for Regional Health Services, University of Southern Denmark, Odense, Denmark

¹⁵Institut du Cerveau et de la Moelle, ICM, Inserm, U1127, F-75013 Paris, France

¹⁶CNRS, UMR 7225, F-75013 Paris, France

¹⁷Sorbonne Université, F-75013 Paris, France

Correspondence

Guido Rubboli, Danish Epilepsy Centre, Filadelfia/University of Copenhagen, Kolonivej 1, 4293 Dianalund (Denmark). Tel.: +45 58271648; Fax: +45 58 27 10 50; E-mail: guru@filadelfia.dk

Funding Information

This work was supported by the European Research Council (ERC 682345 to SB).

Received: 13 September 2018; Revised: 2 November 2018; Accepted: 18 November 2018

Annals of Clinical and Translational Neurology 2019; 6(2): 386–391

doi: 10.1002/acn3.708

*Contributed equally

Introduction

Sleep-related hypermotor epilepsy (SHE), formerly known as nocturnal frontal lobe epilepsy, is characterized by focal seizures with various motor manifestations occurring during sleep.¹ Autosomal dominant forms of SHE (ADSHE)

Abstract

Mutations in the sodium-activated potassium channel gene *KCNT1* have been associated with nonlesional sleep-related hypermotor epilepsy (SHE). We report the co-occurrence of mild malformation of cortical development (mMCD) and *KCNT1* mutations in four patients with SHE. Focal cortical dysplasia type I was neuropathologically diagnosed after epilepsy surgery in three unrelated MRI-negative patients, periventricular nodular heterotopia was detected in one patient by MRI. Our findings suggest that *KCNT1* epileptogenicity may result not only from dysregulated excitability by controlling Na⁺K⁺ transport, but also from mMCD. Therefore, pathogenic variants in *KCNT1* may encompass both lesional and nonlesional epilepsies.

have been associated with mutations of genes encoding subunits of the neuronal acetylcholine receptor (*CHRNA4*, *CHRN2*, *CHRNA2*) or proteins of the mTORC1/GATOR1 complex (*DEPDC5*, *NPRL2/3*).¹ Heterozygous missense mutations in *KCNT1* were reported in a severe form of ADSHE with normal MRI, drug-resistant seizures, intellectual

disability, and psychiatric features.² The *KCNT1* gene encodes a sodium-activated potassium channel that regulates excitability in neurons by contributing to the slow hyperpolarization that follows repetitive firing.

Malformations of cortical development (MCDs) have previously been documented in SHE,³ but only few studies have elucidated their genetic etiologies.⁴ Here, we report the co-occurrence, not described previously, of mild MCDs (mMCDs) and *KCNT1* pathogenic variants in four subjects with SHE.

Patients and Methods

We performed genetic diagnostic testing in one ADSHE patient (patient A.III.1) previously submitted to epilepsy surgery in whom mMCD was detected by histopathological examination, and in his family relatives (Fig. 1A). A cohort of further 36 published and unpublished patients with *KCNT1*-related SHE, collected through data sharing with Epilepsy and Genetic Centers in Europe and North America, was reviewed for MRI abnormalities and/or surgical treatment. We collected two additional patients with de novo *KCNT1* variants, one with ADSHE (patient B.III.2, Fig. 1B) and one with sporadic SHE (patient C). Both patients underwent epilepsy surgery before genetic

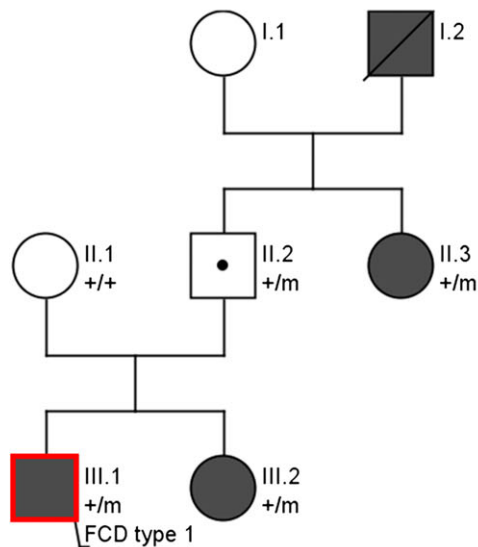
testing. A fourth patient (B.III.1) belonging to family B (Fig. 1B) showed MCD at the MRI. Electro-clinical phenotyping was performed by detailed clinical history and video-EEG monitoring including seizure recording. All patients had had 1.5 or 3 Tesla brain MRIs. Epilepsy surgery was performed after long-term scalp and intracranial video-EEG monitoring. Histopathological diagnosis on FFPE neuropathological surgical specimens was made according to the classification of the International League Against Epilepsy (ILAE) Diagnostic Methods Commission.⁵ Sequencing was performed on genomic blood DNA using targeted gene panels comprising known epilepsy genes including those known to cause MCD-related epilepsy (i.e., *DEPDC5*, *NPRL2/3*, *MTOR*).⁶ Informed consent from all participants and approval from the local ethics committees were obtained.

Results

Genetic findings

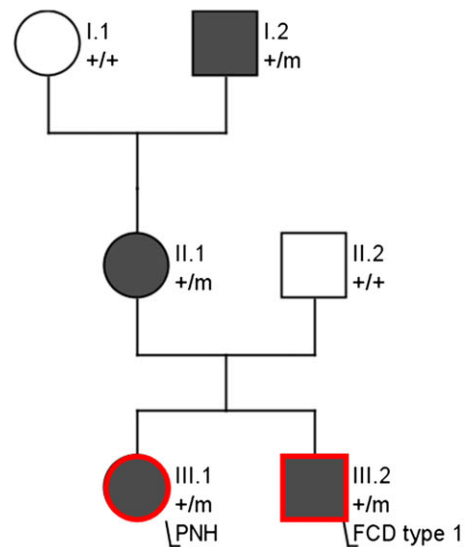
In family A, genetic analysis revealed a c.2849G>A; p.Arg950Gln *KCNT1* (NM_020822.2) missense mutation segregating in subjects A.III.1, A.III.2, inherited from their unaffected father, and found in A.II.3 (Fig. 1A), reflecting

Family A: c.2849G>A; p.Arg950Gln



A

Family B: c.2386T>C; p.Tyr976His



B

Figure 1. (A) Pedigree of family A (*KCNT1* c.2849G>A; p.Arg950Gln). (B) Pedigree of family B (*KCNT1* c.2386T>C; p.Tyr976His). The patient indicated with a dot is an unaffected carrier. Red contours indicate the presence of MCD, dark symbols indicate individuals with focal epilepsy. Individuals with *KCNT1* mutations are indicated by m/+, and those negative by +/+. FCD, focal cortical dysplasia; PNH, periventricular nodular heterotopia.

the incomplete penetrance seen in *KCNT1* families.⁷ Family B (c.2386T>C; p.Tyr796His *KCNT1*) was previously reported.² Patient C had a de novo c.2800G>A; p.Ala934Thr mutation. All *KCNT1* variants were considered as pathogenic given their: a) recurrence in other published SHE cases; b) absence in control databases (gnomAD); c) familial segregation/de novo occurrence (Fig. 1A), and d) in vitro gain-of-function effect of the Tyr796His and Ala934Thr variants on the current magnitude.

Electro-clinical phenotyping

Family A. Patient A.III.1 is a 23-year-old male with drug-resistant sleep-related frontal lobe seizures since 8 years of age (Table 1). Behavioral disturbances and neuropsychological deficits consistent with frontal lobe dysfunction appeared after epilepsy onset. 3T MRI was unremarkable. Epilepsy surgery was performed at age 14 to attempt to control seizures occurring several times per night, almost every night. After 2 years of postoperative seizure freedom, seizures reappeared with partially modified semiology (Table 1) reaching progressively the same frequency as before surgery (Engel class IV⁸). Histopathological examination (NeuN immunostaining) showed cortical dyslamination suggesting focal cortical dysplasia (FCD) type Ib (Fig. 2A). In patient A.III.2, seizures were drug-resistant, whereas in patient A.II.3 they were well controlled by carbamazepine. In both patients, 1.5T MRI was normal. Familial history, clinical, and EEG features were consistent with ADSHE.

Family B. All four affected members of this family were diagnosed with ADSHE. Patient B.III.2 (previously described²) suffered from drug-resistant sleep-related seizures since the age of 3 years. Brain MRI (1.5T) was unremarkable. At 21 years of age, he underwent epilepsy surgery with resection of the right mesio-lateral frontal region. Histopathological examination (Nissl staining) displayed cortical laminar disorganization indicative of FCD type Ib (not mentioned in the initial publication²) (Fig. 2B). Epilepsy improved and seizure semiology changed after surgery. At 14-years follow up he has only rare diurnal seizures with staring (Engel Class II). Patient B.III.1 is the 37-year-old sister with drug-resistant sleep-related frontal seizures. Brain MRI (1.5T) showed left periventricular nodular heterotopia (PNH) connected by a radial band with the normal-appearing overlying cortex (Fig. 2D). Both patients presented with learning disabilities, severe psychosis, and precocious puberty. Patients B.II.1 and B.I.2 had sleep-related seizures consistent with ADSHE. Brain MRI (1.5T) was normal in patient B.II.1 and not available in patient B.I.2.

Patient C is a 27-year-old female with drug-resistant sleep-related frontal lobe seizures since the age of 20 months (seizures occurred almost every night). Brain MRI (1.5T) showed discrete temporal lobe asymmetry. Two epilepsy surgeries were performed at the age of 6 and 25 years, without improvement of her epilepsy (Engel class IV, follow-up: 2 years). Histopathological analysis (NeuN immunostaining) after the second surgery showed abnormalities of cortical lamination and the presence of characteristic microcolumns in the occipital cortex consistent with FCD type Ia (Fig. 2C).

Discussion

In this study, we report the finding of mMCDs in patients with SHE due to pathogenic variants in *KCNT1*. Together with the *GATOR1*-encoding genes,⁹ this study emphasizes the genetic continuum between apparently nonlesional and lesional focal epilepsies.

Our four patients present with electro-clinical features compatible with SHE, and FCD type I or PNH. All patients suffered from severe refractory focal seizures, intellectual disability, and psychiatric disturbances consistent with the phenotype previously reported in *KCNT1*-related SHE.² In three unrelated patients, epilepsy surgery failed to achieve seizure freedom, although epilepsy severity markedly improved in one (Engel Class II). Neuropathological analysis detected dyslamination compatible with FCD type I, a type of FCD often associated with unsatisfactory seizure control after surgery, with less than 50% of patients achieving seizure freedom,¹⁰ probably due to the more diffuse nature of FCD type I as compared to FCD type II, which has a better postseizure outcome. The focal onset of seizures documented by intracranial EEG recordings in patients with FCD type I is likely to represent only a portion of a more diffuse epileptogenic network, which probably involves a larger amount of abnormal cortex.¹¹ Nevertheless, the transient seizure-free period followed by a change of seizure semiology observed in patients A.III.1 and B.III.2 indicates that the surgical intervention indeed impinged on the epileptogenic network, although the resection probably was not large enough to yield seizure freedom.

A role of *KCNT1* in provoking widespread epileptogenesis that sustains seizure propensity after epilepsy surgery is also possible. Structural and molecular alterations (such as ion channel expression/function) in the perilesional region, may also contribute to the epileptogenicity of focal MCDs.¹² The coexistence of two highly epileptogenic substrates (i.e., MCD and *KCNT1* mutation) could underlie the epilepsy severity in these patients. Indeed, *KCNT1* mutations and MCDs might reciprocally

Table 1. Electroclinical features, MRI, and pathological findings in patients with KCNT1-related SHE and MCD.

Case	Mutation	Ethnic backgr.	Age/sex/ Age at seiz. onset	Seizure semiology	Epilepsy syndr.	Interictal scalp EEG findings	MRI Findings (Tesla)	Intracranial/ scalp video-EEG findings	Surgery/ Age at surgery	Surgery outcome/follow-up/ seiz. semiology	Histo pathol.	Current TRT	Comorbidities
A.III.1	c.2849G>A; p.Arg950Gln	23 y/M/ Danish	8 y	Sleep-related HMS	ADSH	Bifrontal sharpwaves and bitemporal asynchronous sharpwaves	Unremarkable (3 T)	Sleep-related HMS (asymmetric posturing, choking, retching, distressed breathing) IEEG: R mesial fronto-central onset	Resection of the R mesial fronto-parietal regions/ 14 y	Engel Class IV/ 8 y/sleep-related HMS (tingling, choking, vocalizations)	FCD type Ib	CBZ, LTG, TPM, LCS, CNZ	Behavioral disturbances (impulsivity, attention deficit), poor executive functions
B.III.1	c.2386T>C; p.Tyr796His	37 y/F/ Italian	3 y	Sleep-related focal seizures with tonic posturing	ADSH	L fronto- temporal spikes, increased by sleep	L Periventric. nodular heterotopia with transmantlesigns (1.5 T)	Not performed	Not performed	-	-	CBZ, TPM	Severe psychosis, learning disabilities, precocious puberty
B.III.2	c.2386T>C; p.Tyr796His	35 y/M/ Italian	3 y	Sleep-related HMS, nocturnal wandering	ADSH	R fronto- temporal theta activity	Unremarkable (1.5 T)	Sleep-related HMS (pelvic thrusting, tonic posturing, pedaling) IEEG: R ant. cingular onset with spread to R mesial superior frontal gyrus and orbital region	Resection of the R anterior cingulate gyrus + lateral frontal cortex (F1, F2, post. F3)/21 y	Engel Class II (at present) 14 y/ rare diurnal seiz. with staring	FCD type Ib	CBZ, VPA, PB	Severe psychosis, learning disabilities, precocious puberty
C	c.2800G>A; p.Ala934Thr de novo	27 y/F/ French	1 y 8 m	Sleep-related R tonic motor seizures with consciousness impairment; infrequent daytime episodes with R lower limb atonia, sudden fall, consciousness impairment	SHE	Bilateral multifocal spikes	Discrete temporal lobe asymmetry (R > L) (1.5 Tesla) Uninformative (sequelae of the previous surgery) (3 Tesla)	(before first surgery): Sleep-related R sided tonic seiz., axial tonic seiz., "agitated" seiz. IEEG: L multifocal epileptogenic zone with centro-parietal predominance (before 2nd surgery): Sleep-related R side grimacing, seiz., R sided tonic clonic jerks Scalp EEG: L multifocal (parieto- post. temporal occipital), R fronto-temporal onset	First surgery: L centro-parietal resection/ 6 y 2nd surgery: L parieto-occipital (+ temporo- occipital junction) resection/ 25 y	Engel Class IV/ 2 y (after 2nd surgery)/ Semiology unchanged	FCD type Ia	CBZ, LEV, PB, VNS	Learning disabilities and delayed psychomotor development since 3 years of age. Worsening of the cognitive status and appearance of autistic features over the years.

HMS, hypermotor seizures; IEEG, intracranial EEG; CBZ, carbamazepine; LTG, lamotrigine; TPM, topiramate; LCS, lacosamide; CNZ, clonazepam; LEV, levetiracetam; CLB, clobazam; PB, phenobarbital; VPA, valproic acid; VNS, vagus nerve stimulator; periventr., periventricular; ant., anterior; backgr, background; SE, status epilepticus; y, years; mo, months; seiz., seizure; R, right; L, left.

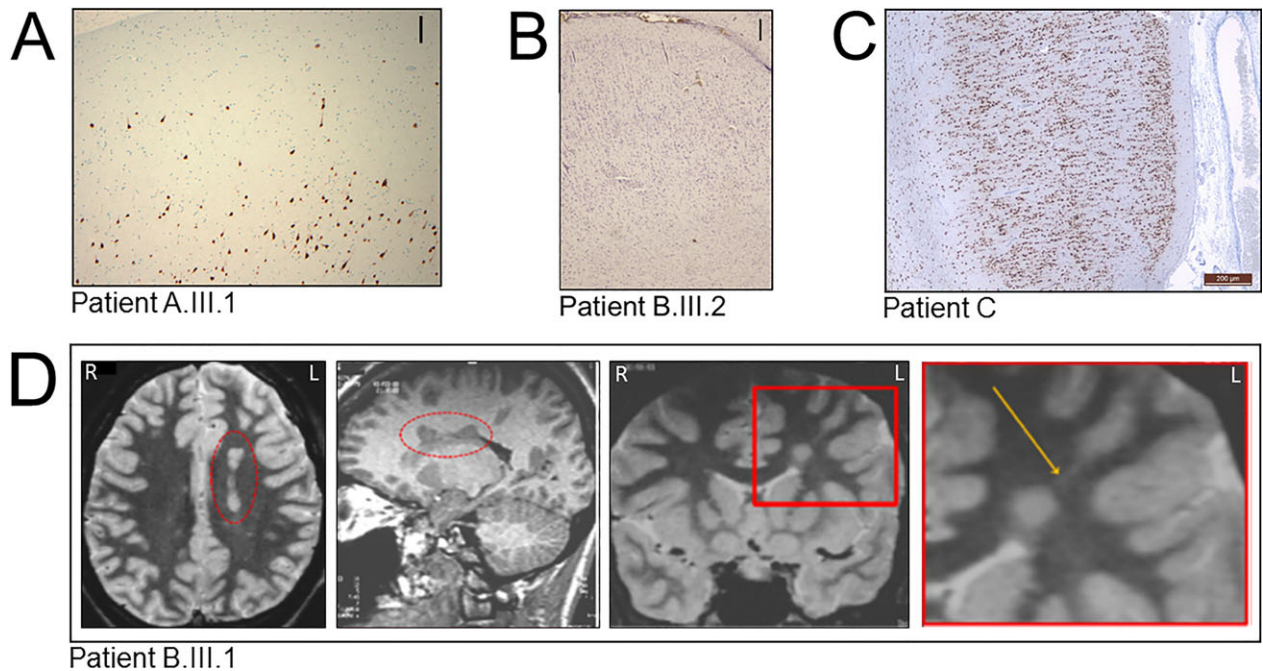


Figure 2. Neuropathological findings. (A) In individual A.III.1, NeuN staining highlights areas of underdeveloped or focal losses of cortical layer 2 and scattered malpositioned pyramidal type neurons in cortical layer 1, consistent with FCD type Ib (original magnification 100X). Scale bar: 250 μ m. (B) In individual B.III.2, Nissl-stained section shows a laminar disorganization of the cortex indicative of FCD type Ib. Scale bar: 250 μ m. (C) In individual C, NeuN staining section shows an abnormal cortical radial lamination and neurons with microcolumnar disposition consistent with FCD type Ia. No dysmorphic neurons or balloon cells were observed. Scale bar 200 μ m. (D) MRI of individual B.III.1 showing deep nodular heterotopia in the left frontal lobe. Axial T2 WI (first panel from the left) and sagittal 3D T1WI (second panel from the left) show a left periventricular nodular heterotopia (in the red dashed ellipse). Coronal IR T1WI (third panel from the left) and magnification of the area included in the red square (fourth panel from the left) show a single heterotopic nodule in the deep-periventricular left frontal white matter with the same signal intensity of the grey matter. The nodule is connected by a radial band (arrow) with the normal-appearing overlying cortex. R = right, L = left.

influence each other in developing the pathophysiological mechanisms that generate seizures, as suggested in patients with MCD carrying *SCN1A* mutations.¹³ An alternative hypothesis is the existence of a second-hit somatic mutation that would support the focal cortical lesion, as previously demonstrated in *DEPDC5*-related focal epilepsy,^{4,14} a hypothesis that could not be verified here because of the lack of resected epileptogenic cortex. Given the poor epilepsy surgery outcome, our findings raise the issue whether surgery is an effective treatment in *KCNT1*-related SHE, and, in a broader perspective, whether genetic testing should be included in the presurgical assessment of patients who are considered as possible candidates for epilepsy surgery.¹⁵

Interestingly, in the fourth nonoperated patient with ADSHE (patient B.III.1), MRI showed unilateral PNH, a type of MCD that has been shown to be associated with FCD type I in the cortex overlying the nodules.¹⁶ Negative MRI in three patients (A.III.2, A.II.3 and B.II.1) might depend on the limited sensitivity of current neuroimaging techniques to detect subtle abnormalities, especially FCD type I or, alternatively, it might suggest that

KCNT1 variants can be associated with lesional and non-lesional epilepsies even within the same family.

The contribution of ion channels in the pathogenesis of MCDs has previously been reported. For instance, dysplastic neurons present in FCDs display strong $K_v4.2$ expression.¹⁷ Recently, neuropathological investigations in a child diagnosed with a severe *KCNQ2*-related neonatal epileptic encephalopathy, revealed the presence of heterotopic neurons in the deep white matter.¹⁸ In a knockdown mouse model, *KCNK* potassium channels dysfunction, resulting in increased frequency of spontaneous calcium influx, impeded physiological neuronal migration in the developing cerebral cortex, possibly playing a role in the genesis of MCD via an activity-dependent mechanism.¹⁹ Lastly, MCDs in patients with *SCN1A* and *SCL35A2* mutations have been documented.^{13,20}

Our study supports an emerging view in which subtle structural brain changes (MRI-undetectable) can occur in epilepsies caused by mutations in ion channel genes and further emphasizes the need for repeated and careful review of high-resolution imaging for subtle

abnormalities, that may not be immediately appreciated, in patients with *KCNT1*-related focal epilepsies.

Acknowledgments

We thank Roberto Spreafico and Nadia Colombo for their helpful comments and suggestions on the manuscript. We are indebted to the patients and their families for their collaboration in performing this study. This work was supported by the European Research Council (ERC 682345 to SB).

Author contributions

G.R. and R.S.M.: concept and study design, data acquisition and analysis, drafting of the manuscript and figures; S.B.: concept and study design, drafting of the manuscript and figures; G.P., F.P., L.N., E.H., J.C., R.A.P., J.B., M.B., P.K., L.M.D., E.G.: data acquisition and analysis.

Conflict of Interest

None of the authors has any conflict of interest to disclose. We confirm that we have read the Journal's position on issues involved in ethical publication and affirm that this report is consistent with those guidelines.

References

1. Tinuper P, Bisulli F, Cross JH, et al. Definition and diagnostic criteria of sleep-related hypermotor epilepsy. *Neurology* 2016;86:1834–1842.
2. Heron SE, Smith KR, Bahlo M, et al. Missense mutations in the sodium-gated potassium channel gene *KCNT1* cause severe autosomal dominant nocturnal frontal lobe epilepsy. *Nat Genet* 2012;44:1188–1190.
3. Nobili L, Francione S, Mai R, et al. Surgical treatment of drug-resistant nocturnal frontal lobe epilepsy. *Brain* 2007;130:561–573.
4. Baulac S, Ishida S, Marsan E, et al. Familial focal epilepsy with focal cortical dysplasia due to *DEPDC5* mutations. *Ann Neurol* 2015;77:675–683.
5. Blümcke I, Thom M, Aronica E, et al. The clinicopathologic spectrum of focal cortical dysplasias: a consensus classification proposed by an ad hoc Task Force of the ILAE diagnostic methods commission. *Epilepsia* 2011;52:158–174.
6. Oates S, Tang S, Rosch R, et al. Incorporating epilepsy genetics into clinical practice: a 360° evaluation. *NPJ Genom Med.* 2018 May;10:13. <https://doi.org/10.1038/s41525-018-0052-9>.
7. Møller RS, Heron SE, Larsen LH, et al. Mutations in *KCNT1* cause a spectrum of focal epilepsies. *Epilepsia* 2015;56:e114–e120.
8. Engel J. Outcome with respect to epileptic seizures. In: Engel J Jr, ed. *Surgical treatment of the epilepsies*, 2nd ed. New York: Raven Press, 1993:609–621.
9. Marsan E, Baulac S. Mechanistic target of rapamycin (mTOR) pathway, focal cortical dysplasia and epilepsy. *Neuropathol Appl Neurobiol.* 2018;44:6–17.
10. Simpson SL, Prayson RA. Post-surgical outcome for epilepsy associated with type I focal cortical dysplasia subtypes. *Modern Pathol* 2014;27:1455–1460.
11. Frater JL, Prayson RA, Morris HH III, et al. Surgical pathologic findings of extratemporal-based intractable epilepsy: a study of 133 consecutive resections. *Arch Pathol Lab Med* 2000;124:545–549.
12. Wong M. Mechanisms of epileptogenesis in tuberous sclerosis complex and related malformations of cortical development with abnormal glioneuronal proliferation. *Epilepsia* 2008;49:8–21.
13. Barba C, Parrini E, Coras R, et al. Co-occurring malformations of cortical development and *SCN1A* gene mutations. *Epilepsia* 2014;55:1009–1019.
14. Ribierre T, Deleuze C, Bacq A, et al. Second-hit mosaic mutation in mTORC1 repressor *DEPDC5* causes focal cortical dysplasia-associated epilepsy. *J Clin Invest.* 2018;128:2452–2458.
15. Stevelink R, Sanders MW, Tuinman MP, et al. Epilepsy surgery for patients with genetic refractory epilepsy: a systematic review. *Epileptic Disord.* 2018;20:99–115.
16. Meroni A, Galli C, Bramerio M, et al. Nodular heterotopia: a neuropathological study of 24 patients undergoing surgery for drug-resistant epilepsy. *Epilepsia* 2009;50:116–124.
17. Aronica E, Boer K, Doorn KJ, et al. Expression and localization of voltage dependent potassium channel Kv4.2 in epilepsy associated focal lesions. *Neurobiol Dis* 2009;36:81–95.
18. Dalen Meurs-van Der Schoor C, van Weissenbruch M, Van Kempen M, et al. Severe neonatal epileptic encephalopathy and *KCNQ2* mutation: neuropathological substrate? *Front Pediatr* 2014;2:136. <https://doi.org/10.3389/fped.2014.00136>.
19. Bando Y, Hirano T, Tagawa Y. Dysfunction of *KCNK* potassium channels impairs neuronal migration in the developing mouse cerebral cortex. *Cereb Cortex* 2014;24:1017–1029.
20. Winawer MR, Griffin NG, Samanamud J, et al. Somatic *SLC35A2* variants in the brain are associated with intractable neocortical epilepsy. *Ann Neurol* 2018;83:1133–1146.