

This is a pre print version of the following article:

Robotic liver resection: hurdles and beyond / Di Benedetto, Fabrizio; Petrowsky, Henrik; Magistri, Paolo; Halazun, Karim J. - In: INTERNATIONAL JOURNAL OF SURGERY. - ISSN 1743-9191. - 82:(2020), pp. 155-162. [10.1016/j.ijssu.2020.05.070]

Terms of use:

The terms and conditions for the reuse of this version of the manuscript are specified in the publishing policy. For all terms of use and more information see the publisher's website.

07/05/2024 08:42

(Article begins on next page)

Journal Pre-proof

Robotic liver resection: hurdles and beyond

Fabrizio Di Benedetto, Henrik Petrowsky, Paolo Magistri, Karim J. Halazun

PII: S1743-9191(20)30453-2

DOI: <https://doi.org/10.1016/j.ijvsu.2020.05.070>

Reference: IJSU 5545

To appear in: *International Journal of Surgery*

Received Date: 28 February 2020

Revised Date: 7 April 2020

Accepted Date: 20 May 2020



Please cite this article as: Di Benedetto F, Petrowsky H, Magistri P, Halazun KJ, Robotic liver resection: hurdles and beyond, *International Journal of Surgery*, <https://doi.org/10.1016/j.ijvsu.2020.05.070>.

This is a PDF file of an article that has undergone enhancements after acceptance, such as the addition of a cover page and metadata, and formatting for readability, but it is not yet the definitive version of record. This version will undergo additional copyediting, typesetting and review before it is published in its final form, but we are providing this version to give early visibility of the article. Please note that, during the production process, errors may be discovered which could affect the content, and all legal disclaimers that apply to the journal pertain.

© 2020 Published by Elsevier Ltd on behalf of IJS Publishing Group Ltd.

Robotic liver resection: hurdles and beyond

Fabrizio Di Benedetto¹, Henrik Petrowsky², Paolo Magistri¹, Karim J. Halazun³

¹ *Hepato-pancreato-biliary Surgery and Liver Transplantation Unit, University of Modena and Reggio Emilia, Modena, Italy*

² *Swiss HPB & Transplant Center Zurich, Department of Surgery and Transplantation, University Hospital Zurich, Zurich, Switzerland*

³ *New York-Presbyterian/Weill Cornell Medical Center, New York, NY, USA*

Corresponding author:

Fabrizio Di Benedetto, MD PhD FACS
Hepato-Pancreato-Biliary Surgery and Liver Transplantation Unit
University Hospital of Modena "Policlinico"
University of Modena and Reggio Emilia
41124, Modena, Italy
Tel. +39 059 422 4740
Email. fabrizio.dibenedetto@unimore.it

International Journal of Surgery Author Disclosure Form

The following additional information is required for submission. Please note that failure to respond to these questions/statements will mean your submission will be returned. If you have nothing to declare in any of these categories, then this should be stated.

Please state any conflicts of interest

Authors have no conflict of interests to disclose

Please state any sources of funding for your research

None

Please state whether Ethical Approval was given, by whom and the relevant Judgement's reference number

No ethical approval was required.

Research Registration Unique Identifying Number (UIN)

Please enter the name of the registry, the hyperlink to the registration and the unique identifying number of the study. You can register your research at <http://www.researchregistry.com> to obtain your UIN if you have not already registered your study. This is mandatory for human studies only.

1. Name of the registry:
2. Unique Identifying number or registration ID:
3. Hyperlink to your specific registration (must be publicly accessible and will be checked):

Author contribution

Please specify the contribution of each author to the paper, e.g. study design, data collections, data analysis, writing. Others, who have contributed in other ways should be listed as contributors.

Fabrizio Di Benedetto : study design, manuscript drafting and critical review
Henrik Petrwoosky : manuscript drafting and critical review
Paolo Magistri : data collection and analysis, manuscript drafting
Karim J Halazun : manuscript drafting and critical review

Guarantor

The Guarantor is the one or more people who accept full responsibility for the work and/or the conduct of the study, had access to the data, and controlled the decision to publish. Please note that providing a guarantor is compulsory.

Fabrizio Di Benedetto

1 **Abstract:**

2
3
4 Laparoscopy is currently considered the standard of care for certain procedures such as left-lateral
5 sectionectomies and wedge resections of anterior segments. The role of robotic liver surgery is
6 still under debate, especially with regards to oncological outcomes. The purpose of this review is
7 to describe how the field of robotic liver surgery has expanded, and to identify current limitations
8 and future perspectives of the technology. Available evidences suggest that oncologic results after
9 robotic liver resection are comparable to open and laparoscopic approaches for hepatocellular
10 carcinoma and colorectal liver metastases, with identifiable advantages for cirrhotic patients and
11 patients undergoing repeat resections. Excellent outcomes and optimal patient safety can be only
12 achieved with specific hepato-biliary and general minimally invasive training to overcome the
13 learning curve.

14

15 **Keywords:**

16 HCC; CRLM; cirrhosis; cholangiocarcinoma; learning curve; LDLT; ICG

17

18
19

1. Introduction

20 The benefits of minimally invasive (MIS) approaches to the liver for both primary and metastatic
21 tumors have been clearly demonstrated over the last two decades (1). The introduction of robotic
22 technology in the field of liver surgery may make technically difficult MIS approaches to the liver
23 more feasible. Such resections include posterior sectionectomies and tumors located in superior
24 segments 4a and 8 (2). Although robotic surgery is rapidly growing and expanding in several
25 surgical fields, with favorable peri-operative outcomes, there are still concerns with regards to
26 mid- and long-term oncological outcomes, especially in complex hepatobiliary surgery (3)(4). The
27 aim of this study is to describe how the field of robotic liver surgery has expanded, identifying
28 current limitations and future directions for the robotic platform through the analysis of significant
29 technical considerations, with particular attention to oncological outcomes for both primary and
30 metastatic liver tumors.

31

2. Technical considerations

2.1 Patient positioning

34 For liver resections, patients are usually positioned supine, in a range of 20° to 35° reverse-
35 Trendelenburg, and can be slightly rotated to the left. A “bump” can be placed under the right
36 shoulder to allow an easier access to right and posterior segments by increasing the rotation. For
37 posterior lesions in segment 6/7, a left-sided position (left lateral decubitus) may be preferable for
38 easy access. With the Si DaVinci platform, a double docking is required for combined liver and
39 colonic resections, while using the novel Xi platform that allows multi-quadrant surgery in a single
40 docking will be sufficient. This is also possible due to the integrated table motion that couples the
41 robotic cart with the operating table allowing variations of table rotation and inclination during
42 surgery.

43 2.2 Port placement

44 Exploratory laparoscopy is recommended before docking the patient cart in order to assess the
45 resectability and safe insertion of trocars. The position of the trocars will differ according to the
46 robotic platform used. As a general rule, trocars should be positioned very high in the subcostal
47 and lateral line for the posterior superior segments and closer to the transverse umbilical line for
48 the anterior segments, shifting toward the left or right depending on the location of the lesion, to
49 create an adequate triangulation with enough space between the ports (6 to 10 cm on average,
50 depending on patient conformation) (5,6). The fourth robotic arm is generally positioned on the
51 left side to retract the liver and expose the transection plane. In major liver resections and
52 bisegmentectomies, a holding stich can be applied to the opposite surface of the transection
53 plane, which applies retraction inside the abdomen or percutaneously to further improve
54 exposure. Figure 1 shows an example of trocar placement with Si platform in case of right
55 hepatectomy and left lobectomy.

56 2.3 Parenchymal transection

57 One of the most common limitations of robotic liver surgery is that the system does not integrate
58 a Ultrasonic Aspirator (UA) for parenchymal transection. This limitation is probably the main factor
59 preventing smoother transition from open/laparoscopic to robotic liver surgery. Therefore,
60 surgeons have to create in between novel strategies to achieve safe parenchymal transection.
61 Despite missing device angulation and reduced motion, the daVinci® Harmonic ACE™ (Ethicon,
62 Somerville, NJ, USA) remains the most appropriate tool for parenchymal transection, together
63 with a meticulous vascular and biliary dissection assisted by bipolar forceps. However, some
64 robotic surgeons might prefer the assistance of bed-side laparoscopic UA transection as long as no
65 comparable robotic transection device is available.

66 2.4 Indocyanine green fluorescence

67 In liver surgery, indocyanine green (ICG) fluoroscopy can improve the visualization of the biliary
68 tree anatomy and offers a useful method to distinguish between tumor and normal liver
69 parenchyma. In particular, it has been reported that ICG demarcation facilitates performing true
70 anatomical resections with minimally invasive approach, with help of selective occlusion of the
71 specific Glissonian pedicles (7). For biliary tree visualization we have standardized the
72 administration in the OR of 1 mg ICG before induction. ICG infusion might be also used for direct
73 lesion identification where tumors are usually hypo-fluorescent with no ICG uptake (8). Long-term
74 comparative results in terms of oncological benefit are still pending (9).

75 *2.5 Learning curve*

76 Learning robotic liver resection is generally considered easier compared to standard laparoscopy,
77 thanks to the flexibility and stability of the instruments. However, gaining proficiency in a novel
78 surgical technique brings potential harm to patients at the beginning of the surgeons learning
79 curve. This is the reason why every first attempt to use the robot for surgical procedures should be
80 preceded by extensive simulation and wet lab training. It is advisable to start the robotic program
81 with the help of a proctor to increase the safety of the procedure. In terms of outcomes, Chen et
82 al. demonstrated that for major hepatectomies, the robotic learning curve can be divided into
83 three phases: initial (phase 1, 15 patients), intermediate (phase 2, 25 patients), and mature (phase
84 3, 52 patients) (10). The literature shows that lengths of surgery and hospital stay are improved
85 after overcoming the initial phase, while the intermediate phase was required to reduce the
86 overall blood loss (310 mL during phase 2 vs 109 mL during phase 3, $p=0.003$). Similarly, even in
87 the context of an experienced HPB high-volume center, Magistri et al. showed that at least 30
88 cases of robotic liver resection are required to reduce operative time, blood loss, and hospital stay
89 (11).

90

91 **3 Oncological outcomes**

92 *4.1 Primary liver tumors*

93 In the setting of cirrhotic patients, minimally invasive liver surgery is associated with a great
94 benefit in terms of reducing the risks of liver decompensation and related complications (12). A
95 recent literature review including ten studies on robotic liver resection for HCC with a total of 302
96 patients reported ranges of disease-free (DFS) and overall survival (OS) at 2 years of 72%-84% and
97 94%-98%, respectively (13). Table 1 provides data from studies with at least 20 cases of robotic
98 HCC. It has been proposed that a robotic approach may also improve the access to the abdomen
99 in cases of tumor recurrence with potential requirement of a liver transplant in the future,
100 opening to the possibility of its adoption for both down-staging and bridging strategies (14).

101 A recent review from China reported 4 studies on the use of robotic approach for hilar
102 cholangiocarcinoma (15). Among those, two studies presented case series of at least 10 patients
103 (3,16), while the other two were case reports (17,18). In the study by Xu and colleagues, outcomes
104 were not favorable, resulting in a longer operative time, higher post-operative morbidity and
105 shorter recurrence-free survival (RFS) compared to open surgery (16). Notably, in the larger series
106 published by Liu et al., only 3 patients underwent a formal anatomical left hepatectomy, while the
107 others were treated with tumor resection and biliary reconstruction or drainage. Moreover, 1 case
108 of port-site metastasis was reported (3). The experience with hilar cholangiocarcinoma is too
109 limited so far to draw conclusions on its feasibility, and should be reserved to highly experienced
110 centers.

111 Finally, few data are available on robotic liver resection for intra-hepatic cholangiocarcinoma, and
112 no significant data on oncological outcomes are currently available (16,19,20).

113 *4.2 Secondary liver tumors*

114 In patients with liver metastases, several studies already demonstrated the non-inferiority of
115 minimally invasive surgery versus classical open approach. A recent multi-institutional study from
116 high-volume centers in the United States reported a propensity-matched comparison between
117 laparoscopic and robotic liver resection for metastatic colorectal cancer (20). No statistically
118 significant differences were found in terms of perioperative death, overall and high-grade
119 complications, surgical margin status, and need for readmission or reintervention. After a median
120 follow-up of almost 3 years, there were no statistically significant differences in OS and DFS
121 between the robotic and laparoscopic group (61% versus 60% $p=0.78$, and 38% versus 44% $p=0.62$,
122 respectively). Table 2 presents data from studies with at least 20 cases of robotic resections for
123 colorectal liver metastasis (CRLM). It has been also reported that minimally invasive liver surgery
124 allows a parenchymal-sparing approach with the possibility to easily access the liver in case of
125 recurrence and consequently facilitates repeated liver resection (21,22). This is of particular
126 importance in the natural history of CRLM. From a technical point of view, combined colorectal
127 and liver surgery in case of synchronous CRLM may require a double docking when using the Si
128 platform, which may be relevant for the length of surgery.

129

130 **4 Robotic procurement for living donation**

131 Robotic liver procurement for living donor liver transplant is currently less developed
132 compared to kidney procurement and transplantation for living donation, currently the standard
133 of care in kidney procurements. (21–23). Laparoscopic donor hepatectomy, either pure or hybrid,
134 has been successfully applied to both left and right procurement from living donors. It has been
135 proven safe and effective and is associated with fast recovery to daily activities in expert centers
136 (24–26). In 2016, Chen et al. reported a series of 13 patients who underwent living donor robotic
137 right hepatectomy for liver transplantation (27). In this study, robotic surgery resulted in better

138 pain control and enabled a faster return to work without affecting liver transplant outcomes and
139 with similar outcomes to laparoscopic approaches, when compared with the traditional open
140 approach.

141

142 **5 Costs and financial burden**

143 Several analyses on costs of robotic surgery have been reported so far, with controversial
144 results about the balance between costs and benefits (28). A recent analysis demonstrated that
145 robotic surgery performs better as compared to laparoscopic and open liver resections in terms of
146 costs, hospital stay, and risk of readmission (29). Such uncertainty may be related to the difficulty
147 to compare overall costs, in particular among different healthcare systems and regulations
148 worldwide. A paper comparing costs of robotic and laparoscopic left lateral sectionectomy showed
149 no differences in terms of the total surgical supply (\$5'130 vs. \$4'408, $p=0.401$) (30). Notably, this
150 analysis was performed without indirect costs for robotic surgery excluding initial purchase and
151 maintenance, that significantly increase the costs of robotic procedure. Taken together, data in
152 literature are too heterogeneous so far to clearly solve the issue of costs comparison between
153 robotic surgery and other techniques.

154

155 **6 Discussion**

156 On February 2019 the US Food and Drug Administration (FDA) released a safety
157 communication about the use of robotic-assisted surgical systems for every surgical specialty (31).
158 This warning was mainly related to the use of robotic surgery for hysterectomy, and cited the
159 outcomes of a clinical trial published on November 2018 in the New England Journal of Medicine
160 (32). This study analyzed radical hysterectomy for various uterine and cervical malignancies and
161 showed inferior DFS and OS for the minimally invasive (laparoscopic and robotic) compared to the

162 open group. This observation initiated an intense debate in the gynecologic community in the
163 setting of already widespread acceptance of minimally invasive approaches for gynecological
164 neoplasia. However, these inferior results appear to be related to the learning curve rather than
165 the used instrumentation approach. Improved credentialing protocols are needed to guarantee
166 the best results for safety and oncological outcomes (33).

167 Several studies focused on the comparison between laparoscopic and robotic surgery, failing
168 to identify clear advantages on one over another approach (34). It should be taken into account
169 that robotic surgery offers a different approach from standard laparoscopy, tending to an overall
170 increased control of the surgical field and, therefore, improved safety in the correct hands. Beside
171 being aware of the existence of other robotic platforms, it should be clarified that all available
172 evidences herein analyzed are referred to *da Vinci* platforms (Intuitive, Sunnyvale, CA, US). The
173 use of robotic surgery should be reserved to highly specialized centers in order to maximize the
174 opportunities to offer radically curative treatment without compromising safety. This statement is
175 also consistent with the latest definition of robotic liver surgery at the Morioka conference, where
176 robotic surgery was proposed to be in the development phase of the IDEAL grading system (Idea,
177 Development, Exploration, Assessment and Long Term Follow Up Collaboration) (35,36). Despite
178 some reservations towards robotic liver surgery, even advanced procedures such as major
179 vascular reconstructions and Associating Liver Partition and Portal vein ligation for Staged
180 hepatectomy (ALPPS) have been successfully performed with a partial (37) or full robotic approach
181 (38-40) in advanced minimally invasive centers. ALPPS is well known to be technically demanding
182 even with a traditional open approach (41-43), however, minimally invasive approaches, especially
183 at stage one, may reduce the incidence of inter-stage complications and facilitate better
184 tolerability of the inter-stage course (44).

185 With regards to instrumentation, the lack of an efficient robotic transection device as the UA is
186 the most important limitation of robotic liver surgery. There are current difficulties in product
187 development, which clearly delay the introduction of a fully compatible robotic UA device. In
188 addition, there is an ongoing debate of whether the use of laparoscopic UA by the bedside
189 surgeon may be the solution, challenging the efficiency of the robotic approach in terms of loss of
190 control by the console surgeon during parenchymal transection. Another limitation of this set-up
191 is that significant resources that will be required, since two experienced surgeons will be needed
192 to perform the procedure, one console surgeon and one bedside surgeon using the UA. This
193 demand of experienced manpower might be a hurdle for many centers to implement this
194 technology. Many robotic liver surgeons consider their parenchymal transection technique a
195 return to the classical open approach of parenchymal crush (45), in a finer, magnified, and precise
196 fashion (Figure 3). However, such approach may not be widely applicable, and instrumentation
197 still represents a barrier, for example, to robotic living donor hepatectomy. While growing,
198 experiences in this field remain sparse with little data available.

199
200 The spatial distance between the operating and robotic platform and its considerable size
201 remain an important obstacle, making undocking and gaining access to the patient potentially
202 difficult in emergency scenarios. (46,47). Due to the improved agility in narrow spaces and tremor
203 filtration, the robot may provide an easier dissection of the hilum, which is crucial in this setting.
204 Robotic approaches for liver malignancies are becoming more common, with a growing number of
205 reports being published. While reasonable data on DFS and OS are available for HCC and CRLM,
206 little is known on intrahepatic cholangiocarcinoma, but this might be related in parts to the lower
207 prevalence of this disease. Only few cases are reported for hilar cholangiocarcinoma (15,17),
208 although biliary reconstruction is feasible and reproducible as demonstrated in the experiences

209 with robotic pancreaticoduodenectomies. Furthermore, the requirements for extensive
210 resections and vascular reconstructions make these hilar tumors difficult to treat with the robotic
211 approach. In addition, the absence of haptic feedback, which is still important in the evaluation of
212 perihilar tumor spread in open surgery, may contribute to inferior outcomes. There is general
213 agreement that these advanced robotic procedures require a dedicated learning curve, which may
214 be longer than that for standard robotic resections of intrahepatic tumors (10,11).

215 Another limiting factor of robotic surgery is the operative time, that is in the majority longer
216 compared to other approaches. From a practical point of view, robotic cart docking has been
217 considered the most time-consuming part of robotic surgery. Nowadays, this step is usually fast
218 and comparable to laparoscopic trocar placement due to the advancement of the robotic
219 technology. However, robotic surgery is still slower than standard laparoscopy for two main
220 reasons. First, the operating surgeon controls camera and instruments, therefore camera
221 adjustments require stopping of instrument motion even if for few seconds. Second, the exchange
222 of operating instruments requires disconnections, which takes longer compared to classic
223 laparoscopic or open surgery.

224 In conclusion, robotic surgery has become an important tool in the armamentarium of liver
225 surgeons. Currently only major vascular resection and advanced hilar cholangiocarcinoma are
226 considered relative contraindications for a robotic approach to the liver. Robotic surgery does not
227 replace laparoscopy, but it has great potential for future technological developments including
228 real-time navigation and augmented reality in a single expandable platform (Figure 4). Robotic
229 hepatobiliary surgery should not be approached without specific training in hepatobiliary and
230 general minimally invasive surgery in order to overcome the steep learning curve. In addition, it
231 requires a profound knowledge of the machine, since well-trained robotic surgeons need to know
232 the mechanisms of this tool and the principles of troubleshooting. Moreover, different skill sets

233 are required and should be taught when compared to standard surgical training in order to gain
 234 robotic competence. Indications can be pushed in experienced centers to better define outcomes
 235 and technical principles, which should finally translate in improved safety and better surgical as
 236 well oncological outcomes.

237 **Provenance and peer review**

238 Commissioned, externally peer-reviewed

239

240

241 **7 References:**

242

- 243 1. Ciria R, Cherqui D, Geller DA, Briceno J, Wakabayashi G. Comparative Short-term
 244 Benefits of Laparoscopic Liver Resection: 9000 Cases and Climbing. *Ann Surg.* 2016
 245 Apr;263(4):761–77.
- 246 2. Di Benedetto F, Tarantino G, Magistri P. Chasing the right path: tips, tricks and challenges
 247 of robotic approach to posterior segments. *Hepatobiliary Surg Nutr.* 2019;8(5):512–514.
- 248 3. Liu QD, Chen JZ, Xu XY, Zhang T, Zhou NX. Incidence of port-site metastasis after
 249 undergoing robotic surgery for biliary malignancies. *World J Gastroenterol.* 2012;18(40):5695–
 250 5701.
- 251 4. Liu R, Wakabayashi G, Kim H-J, Choi G-H, Yiengpruksawan A, Fong Y, et al.
 252 International consensus statement on robotic hepatectomy surgery in 2018. *World J Gastroenterol.*
 253 2019 Mar 28;25(12):1432–44.
- 254 5. Giulianotti PC, Bianco FM, Daskalaki D, Gonzalez-Ciccarelli LF, Kim J, Benedetti E.
 255 Robotic liver surgery: technical aspects and review of the literature. *Hepatobiliary Surg Nutr.* 2016
 256 Aug;5(4):311–21.
- 257 6. Cillo U, Carlis LGD, editors. *Liver Transplantation and Hepatobiliary Surgery: Interplay of*
 258 *Technical and Theoretical Aspects* [Internet]. Springer International Publishing; 2020 [cited 2019
 259 Dec 3]. (Updates in Surgery). Available from: <https://www.springer.com/gp/book/9783030197612>
- 260 7. Berardi G, Wakabayashi G, Igarashi K, et al. Full Laparoscopic Anatomical Segment 8
 261 Resection for Hepatocellular Carcinoma Using the Glissonian Approach with Indocyanine Green
 262 Dye Fluorescence. *Ann Surg Oncol.* 2019;26(8):2577–2578
- 263 8. Gonzalez-Ciccarelli LF, Quadri P, Daskalaki D, Milone L, Gangemi A, Giulianotti PC.
 264 Robotic approach to hepatobiliary surgery. *Chir Z Alle Geb Oper Medizen.* 2017 Jan;88(Suppl
 265 1):19–28.
- 266 9. Marino MV, Podda M, Fernandez CC, Ruiz MG, Fleitas MG. The application of
 267 indocyanine green-fluorescence imaging during robotic-assisted liver resection for malignant
 268 tumors: a single-arm feasibility cohort study. *HPB.* 2019 Aug 10;
- 269 10. Chen P-D, Wu C-Y, Hu R-H, Chen C-N, Yuan R-H, Liang J-T, et al. Robotic major
 270 hepatectomy: Is there a learning curve? *Surgery.* 2017;161(3):642–9.
- 271 11. Magistri P, Guerrini GP, Ballarin R, Assirati G, Tarantino G, Di Benedetto F. Improving
 272 Outcomes Defending Patient Safety: The Learning Journey in Robotic Liver Resections. *BioMed*
 273 *Res Int.* 2019;2019:1835085.
- 274 12. European Association for the Study of the Liver. Electronic address:
 275 easloffice@easloffice.eu, European Association for the Study of the Liver. *EASL Clinical Practice*
 276 *Guidelines: Management of hepatocellular carcinoma.* *J Hepatol.* 2018 Jul;69(1):182–236.
- 277 13. Magistri P, Tarantino G, Assirati G, et al. Robotic liver resection for hepatocellular
 278 carcinoma: A systematic review. *Int J Med Robot.* 2019;15(4):e2004.

- 279 14. Magistri P, Olivieri T, Assirati G, Guerrini GP, Ballarin R, Tarantino G, et al. Robotic Liver
280 Resection Expands the Opportunities of Bridging Before Liver Transplantation. *Liver Transplant*
281 *Off Publ Am Assoc Study Liver Dis Int Liver Transplant Soc.* 2019 Jul;25(7):1110–2.
- 282 15. Hu HJ, Wu ZR, Jin YW, et al. Minimally invasive surgery for hilar cholangiocarcinoma:
283 state of art and future perspectives. *ANZ J Surg.* 2019;89(5):476–480.
- 284 16. Xu Y, Wang H, Ji W, et al. Robotic radical resection for hilar cholangiocarcinoma:
285 perioperative and long-term outcomes of an initial series. *Surg Endosc.* 2016;30(7):3060–3070
- 286 17. Zhu Z, Liu Q, Chen J, et al. Robotic surgery twice performed in the treatment of hilar
287 cholangiocarcinoma with deep jaundice: delayed right hemihepatectomy following the right-hepatic
288 vascular control. *Surg Laparosc Endosc Percutan Tech.* 2014;24(5):e184–e190.
- 289 18. Giulianotti PC, Sbrana F, Bianco FM, Addeo P. Robot-assisted laparoscopic extended right
290 hepatectomy with biliary reconstruction. *J Laparoendosc Adv Surg Tech A.* 2010;20(2):159–163.
- 291 19. Goja S, Singh MK, Chaudhary RJ, Soin AS. Robotic-assisted right hepatectomy via anterior
292 approach for intrahepatic cholangiocarcinoma. *Ann Hepato-Biliary-Pancreat Surg.* 2017
293 May;21(2):80–3.
- 294 20. Sucandy I, Giovannetti A, Spence J, Ross S, Rosemurgy A. Robotic caudate lobe liver
295 resection following robotic left hepatectomy for cholangiocarcinoma. *J Hepato-Biliary-Pancreat*
296 *Sci.* 2019 Jul 31;
- 297 21. Tzvetanov I, Bejarano-Pineda L, Giulianotti PC, Jeon H, Garcia-Roca R, Bianco F, et al.
298 State of the art of robotic surgery in organ transplantation. *World J Surg.* 2013 Dec;37(12):2791–9.
- 299 22. Giacomoni A, Centonze L, Di Sandro S, Lauterio A, Ciravegna AL, Buscemi V, et al.
300 Robot-Assisted Harvesting of Kidneys for Transplantation and Global Complications for the Donor.
301 *Transplant Proc.* 2017 May;49(4):632–7.
- 302 23. Giacomoni A, Di Sandro S, Lauterio A, Concione G, Buscemi V, Rossetti O, et al. Robotic
303 nephrectomy for living donation: surgical technique and literature systematic review. *Am J Surg.*
304 2016 Jun;211(6):1135–42.
- 305 24. Samstein B, Griesemer A, Cherqui D, Mansour T, Pisa J, Yegiants A, et al. Fully
306 laparoscopic left-sided donor hepatectomy is safe and associated with shorter hospital stay and
307 earlier return to work: A comparative study. *Liver Transplant Off Publ Am Assoc Study Liver Dis*
308 *Int Liver Transplant Soc.* 2015 Jun;21(6):768–73.
- 309 25. Samstein B, Cherqui D, Rotellar F, Griesemer A, Halazun KJ, Kato T, et al. Totally
310 laparoscopic full left hepatectomy for living donor liver transplantation in adolescents and adults.
311 *Am J Transplant Off J Am Soc Transplant Am Soc Transpl Surg.* 2013 Sep;13(9):2462–6.
- 312 26. Halazun KJ, Przybyszewski EM, Griesemer AD, Cherqui D, Michelassi F, Guarrera JV, et
313 al. Leaning to the Left: Increasing the Donor Pool by Using the Left Lobe, Outcomes of the Largest
314 Single-center North American Experience of Left Lobe Adult-to-adult Living Donor Liver
315 Transplantation. *Ann Surg.* 2016;264(3):448–56.
- 316 27. Chen P-D, Wu C-Y, Hu R-H, Ho C-M, Lee P-H, Lai H-S, et al. Robotic liver donor right
317 hepatectomy: A pure, minimally invasive approach. *Liver Transplant Off Publ Am Assoc Study*
318 *Liver Dis Int Liver Transplant Soc.* 2016 Nov;22(11):1509–18.
- 319 28. Mejia A, Cheng SS, Vivian E, Shah J, Oduor H, Archarya P. Minimally invasive liver
320 resection in the era of robotics: analysis of 214 cases. *Surg Endosc.* 2020 Jan;34(1):339–48.
- 321 29. Cortolillo N, Patel C, Parreco J, Kaza S, Castillo A. Nationwide outcomes and costs of
322 laparoscopic and robotic vs. open hepatectomy. *J Robot Surg.* 2019 Aug;13(4):557–65.
- 323 30. Packiam V, Bartlett DL, Tohme S, Reddy S, Marsh JW, Geller DA, et al. Minimally
324 invasive liver resection: robotic versus laparoscopic left lateral sectionectomy. *J Gastrointest Surg*
325 *Off J Soc Surg Aliment Tract.* 2012 Dec;16(12):2233–8.
- 326 31. US Food and Drug Administration. Caution when using robotically-assisted surgical devices
327 in women’s health including mastectomy and other cancer-related surgeries: FDA safety
328 communication [Internet]. 2019. Available from:
329 <http://www.fda.gov/medicaldevices/safety/alertandnotices/ucm632142.htm>

- 330 32. Ramirez PT, Frumovitz M, Pareja R, et al. Minimally Invasive versus Abdominal Radical
331 Hysterectomy for Cervical Cancer. *N Engl J Med*. 2018;379(20):1895–1904
- 332 33. Sheetz KH, Dimick JB. Is It Time for Safeguards in the Adoption of Robotic Surgery?.
333 *JAMA*. 2019;321(20):1971–1972
- 334 34. Tsilimigras DI, Moris D, Vagios S, Merath K, Pawlik TM. Safety and oncologic outcomes
335 of robotic liver resections: A systematic review. *J Surg Oncol*. 2018 Jun;117(7):1517–30.
- 336 35. Wakabayashi G, Cherqui D, Geller DA, Buell JF, Kaneko H, Han HS, et al.
337 Recommendations for laparoscopic liver resection: a report from the second international consensus
338 conference held in Morioka. *Ann Surg*. 2015 Apr;261(4):619–29.
- 339 36. McCulloch P, Altman DG, Campbell WB, Flum DR, Glasziou P, Marshall JC, et al. No
340 surgical innovation without evaluation: the IDEAL recommendations. *Lancet Lond Engl*. 2009 Sep
341 26;374(9695):1105–12.
- 342 37. Krishnamurthy J, Naragund AV, Mahadevappa B. First Ever Robotic Stage One ALPPS
343 Procedure in India: for Colorectal Liver Metastases. *Indian J Surg*. 2018;80(3):269–271.
- 344 38. Machado MAC, Surjan RC, Makdissi F. Robotic ALPPS [published online ahead of print,
345 2019 Nov 4]. *Ann Surg Oncol*. 2019;10.1245/s10434-019-08027-x.
- 346 39. Vicente E, Quijano Y, Ielpo B, Fabra I. First ALPPS procedure using a total robotic
347 approach. *Surg Oncol*. 2016 Dec;25(4):457.
- 348 40. Di Benedetto F, Assirati G, Magistri P. Full robotic ALPPS for HCC with intrahepatic portal
349 vein thrombosis [published online ahead of print, 2020 Feb 3]. *Int J Med Robot*. 2020;e2087.
350 doi:10.1002/rcs.2087
- 351 41. Raptis DA, Linecker M, Kambakamba P, Tschuor C, Müller PC, Hadjittofi C, et al.
352 Defining Benchmark Outcomes for ALPPS. *Ann Surg*. 2019 Nov;270(5):835–41.
- 353 42. Linecker M, Kuemmerli C, Kambakamba P, Schlegel A, Muiesan P, Capobianco I, et al.
354 Performance validation of the ALPPS risk model. *HPB*. 2019;21(6):711–21.
- 355 43. Lang H, de Santibañes E, Schlitt HJ, Malagó M, van Gulik T, Machado MA, et al. 10th
356 Anniversary of ALPPS-Lessons Learned and quo Vadis. *Ann Surg*. 2019 Jan;269(1):114–9.
- 357 44. Machado MA, Makdissi FF, Surjan RC, Basseres T, Schadde E. Transition from open to
358 laparoscopic ALPPS for patients with very small FLR: the initial experience. *HPB (Oxford)*.
359 2017;19(1):59–66.
- 360 45. Lin TY. A simplified technique for hepatic resection: the crush method. *Ann Surg*. 1974
361 Sep;180(3):285–90.
- 362 46. Di Benedetto F, Magistri P, Halazun KJ. Use of robotics in liver donor right hepatectomy.
363 *Hepatobiliary Surg Nutr*. 2018 Jun;7(3):231–2.
- 364 47. Miller C. Preparing for the inevitable: The death of a living liver donor. *Liver Transplant*
365 *Off Publ Am Assoc Study Liver Dis Int Liver Transplant Soc*. 2014 Nov;20 Suppl 2:S47-51.
- 366 48. Lai ECH, Yang GPC, Tang CN. Robot-assisted laparoscopic liver resection for
367 hepatocellular carcinoma: short-term outcome. *Am J Surg* 2013;205:697–702
- 368 49. Wu Y-M, Hu R-H, Lai H-S, et al. Robotic-assisted minimally invasive liver resection. *Asian*
369 *J Surg* 2014;37:53–7
- 370 50. Chen P-D, Wu C-Y, Hu R-H, et al. Robotic Versus Open Hepatectomy for Hepatocellular
371 Carcinoma: A Matched Comparison. *Ann Surg Oncol*. 2017;24:1021-1028
- 372 51. Magistri P, Tarantino G, Guidetti C, et al. Laparoscopic versus robotic surgery for
373 hepatocellular carcinoma: the first 46 consecutive cases. *J Surg Res* 2017;217:92–9
- 374 52. Wang WH, Kuo KK, Wang SN, Lee KT. Oncological and surgical result of hepatoma after
375 robot surgery. *Surgical Endoscopy* 2018;32:3918–3924
- 376 53. Khan S, Beard RE, Kingham PT, et al. Long-Term Oncologic Outcomes Following Robotic
377 Liver Resections for Primary Hepatobiliary Malignancies: A Multicenter Study. *Ann Surg Oncol*.
378 2018;25(9):2652–2660. doi:10.1245/s10434-018-6629-9
- 379 54. Guerra F, Guadagni S, Pesi B, Furbetta N, Di Franco G, Palmeri M, et al. Outcomes of
380 robotic liver resections for colorectal liver metastases. A multi-institutional analysis of minimally

381 invasive ultrasound-guided robotic surgery. Surg Oncol. 2019 Mar;28:14–8.
382
383
384
385
386

Journal Pre-proof

387 **Figure 1: Trocar disposition**

- 388 a) Right hepatectomy with DaVinci Si robotic platform
389 b) Left lateral sectionectomy with DaVinci Si robotic platform

390

391

392 **Figure 2: Use of ICG fluorescence:**

- 393 a) ICG ("Firefly Technology") During Left Hepatectomy showing biliary bifurcation
394 b) ICG with lack of enhancement of neuroendocrine tumor during robotic hepatectomy
395 c) Demonstration of biliary trifurcation with low take off of right posterior duct during robotic
396 right hepatectomy

397

398

399 **Figure 3: Robotic approach to the liver**

- 400 a) Hilar dissection: left hepatic artery
401 b) Hilar dissection: left portal vein
402 c) Right hepatic vein dissection
403 d) Parenchymal transection: use of Maryland bipolar forceps

404

405

406 **Figure 4: An example of 3D model for pre-operative surgical planning for HCC**

407

408

409

410

411

412

413

414

415

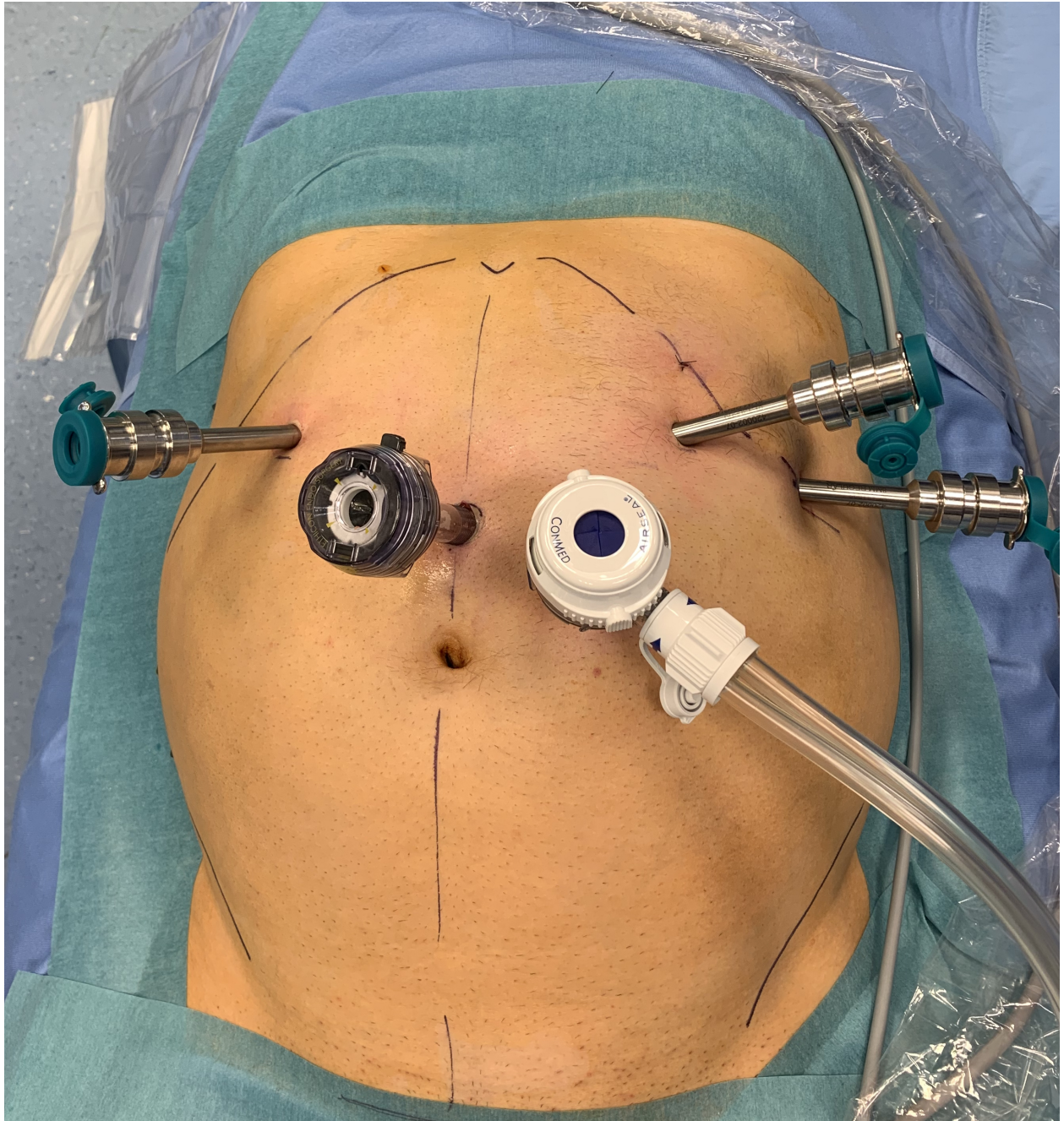
416

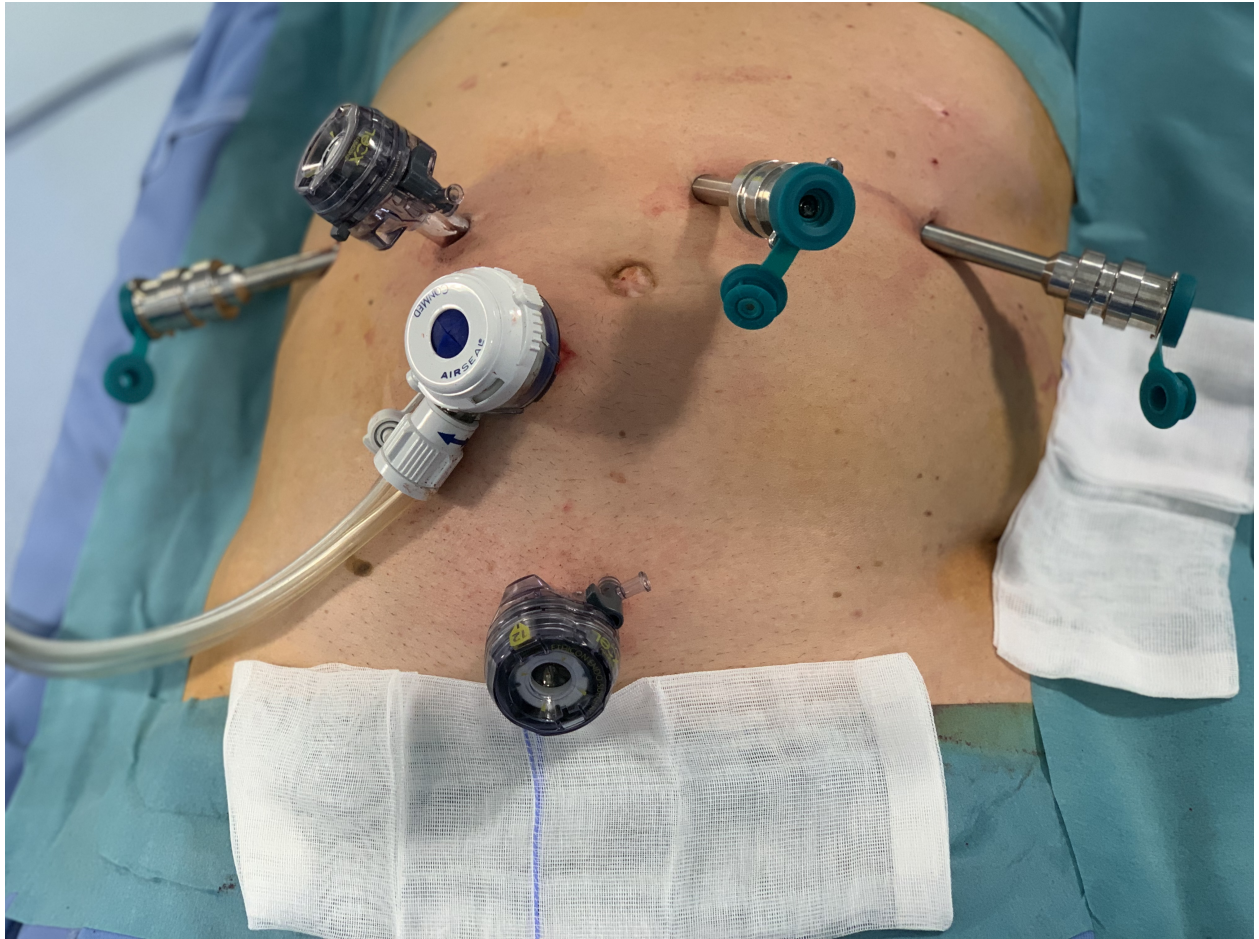Table 1. Robotic resection for HCC in literature

Author	Year	No. of HCC patients	Minor/major resections	Complications rate	Hospital stay	Oncologic follow-up data
Lai et al. (48)	2013	42	32/10	3 (7.1%)	6.2 (days, mean)	n.a.
Wu et al. (49)	2014	38	n.a.	3 (8%)	7.9 (days, mean)	n.a.
Chen et al. (50)	2017	81	47/34	4 (4.9%)	7.5 (days, median)	3-years DFS 72.2% OS 92.6 %
Magistri et al. (51)	2017	22	20/2	2 (9.1%)	5.1 (days, mean)	n.a.
Wang et al. (52)	2018	63	63/0	7 (11.1%)	6.2 (days, mean)	3-years DFS 71.9% OS 97.7%
Khan et al. (53)	2018	34	23/11	12 (35.2%)	4 (days, median)	During a F-U of 75 months 44% patients had recurrence of which the majority (n=10) recurred in the liver

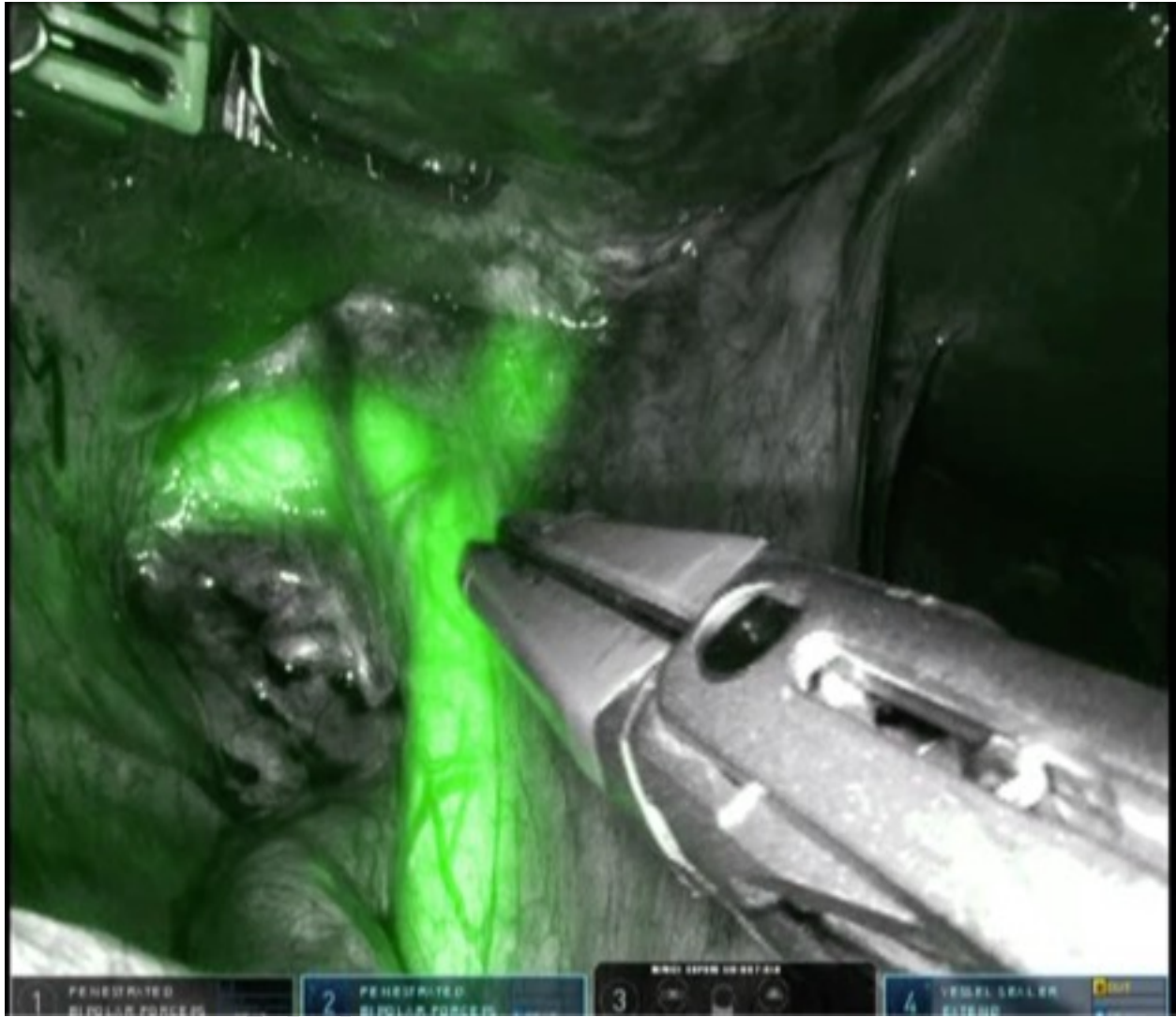
Table 2. Robotic resection for CRLM in literature

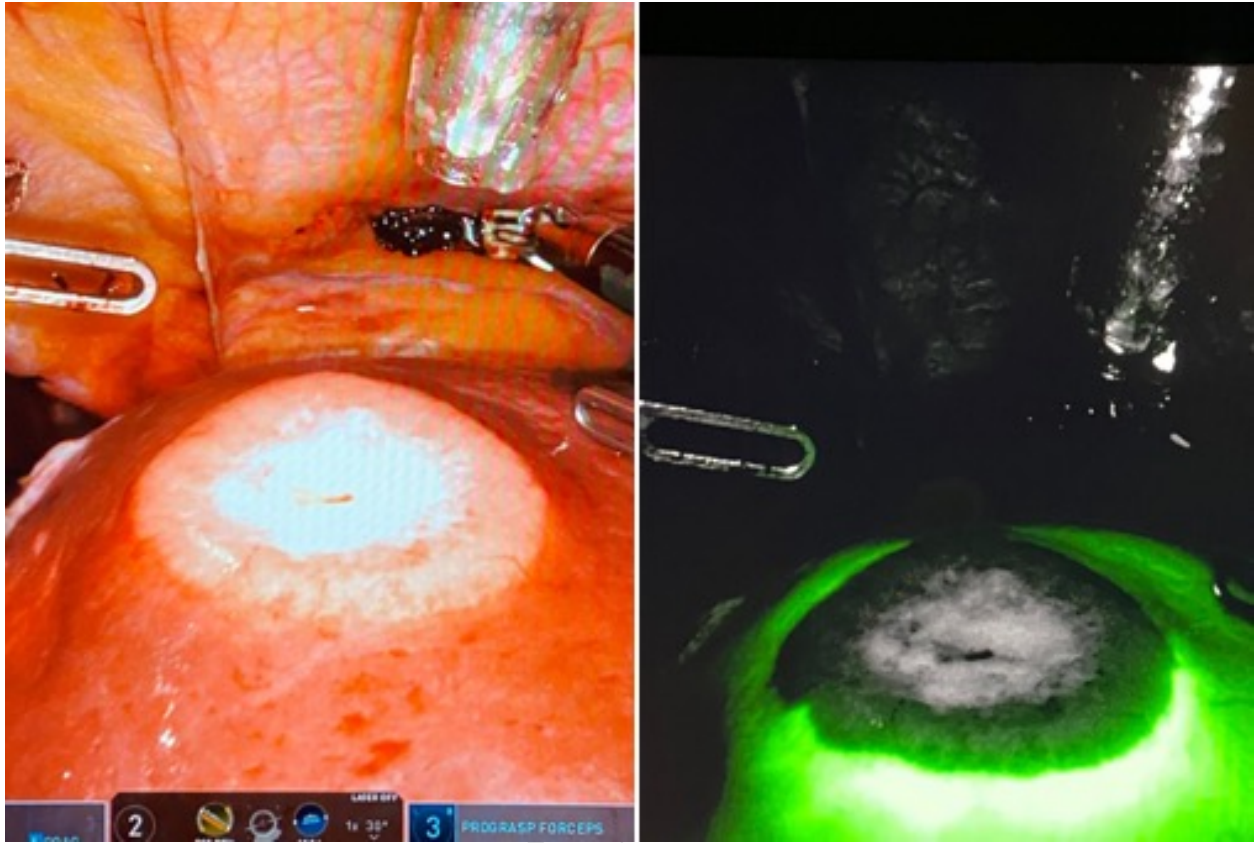
Author	Year	No. of patients	Minor/major resections	Complications rate	Length of hospital stay	Survival
Beard et al. (20)	2019	115	97/18	36 (31.3%)	5 (days, median)	5-years OS 61%, DFS 38%
Guerra et al. (54)	2019	59	78/4	16 (27%)	6.7 (days, mean)	3-years OS 66.1%



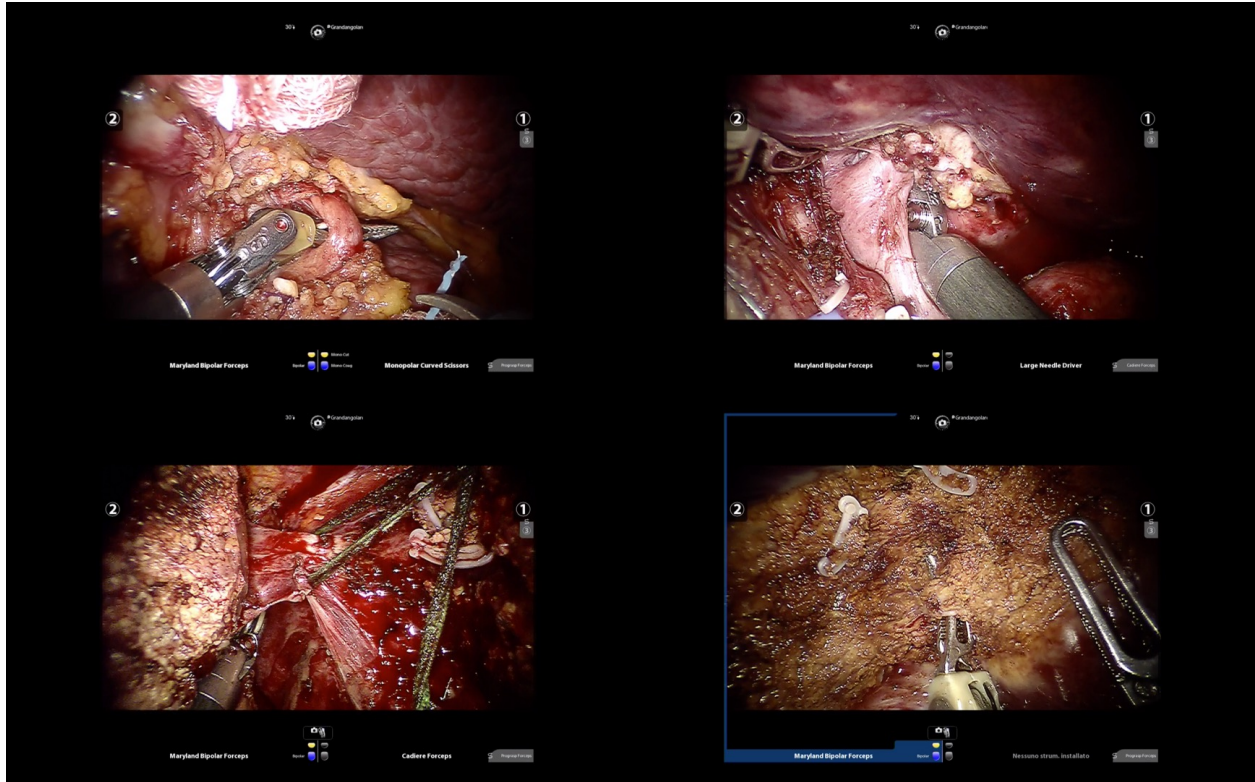


Journal

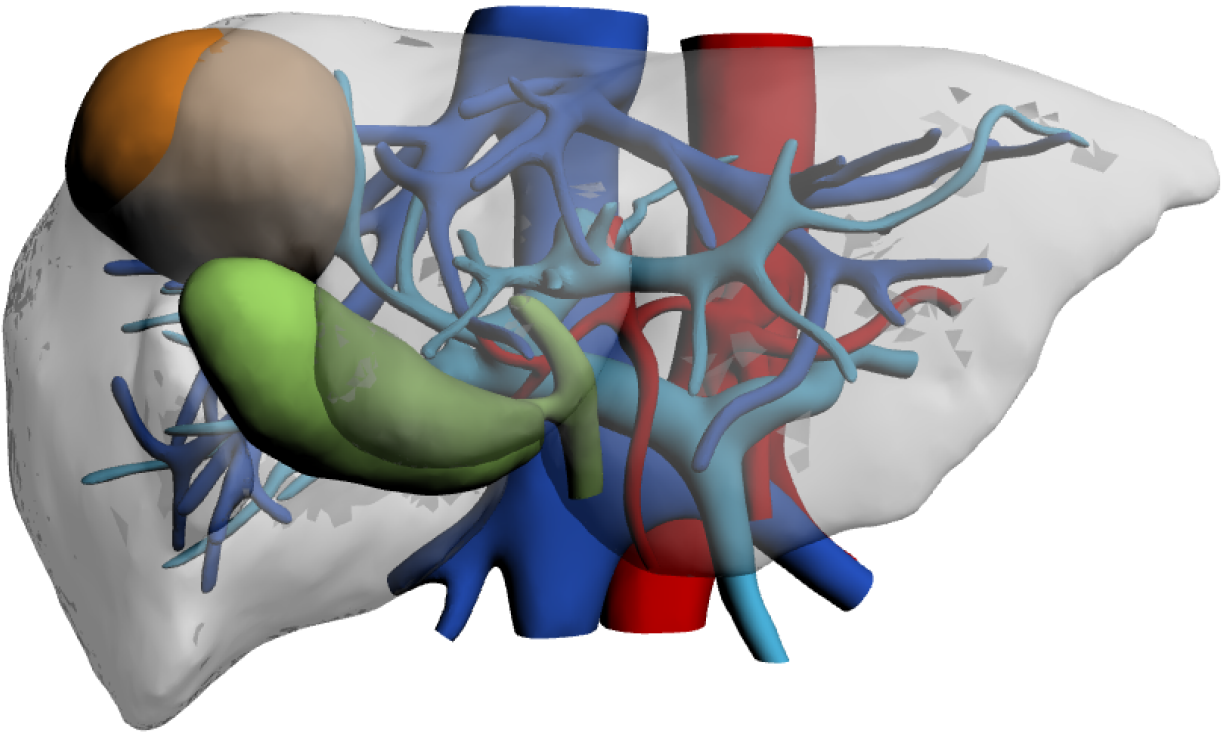








Journal Pre-proof



Journal Pre-proof

Highlights:

- Robotic surgery is an important tool in the armamentarium of liver surgeons
- Outcomes of robotic liver resection for hepatocellular carcinoma and colorectal liver metastases are comparable to laparoscopy and open
- Advanced procedure can be safely performed in expert centers
- Robotic surgery has great potential for further future technological developments

Journal Pre-proof

Data are available for sharing upon request to the corresponding author

Journal Pre-proof

Fabrizio Di Benedetto: Conceptualization, Methodology, Writing- Original draft preparation, Editing, Supervision

Paolo Magistri: Data curation, Writing- Original draft preparation, Editing.

Henrik Petrowsky: Writing- Reviewing and Editing, Supervision

Karim J. Halazun: Writing- Reviewing and Editing, Supervision

Journal Pre-proof