

The Use of Cold Atmospheric Plasma Device in Flap Elevation

Massimo Pinelli, MD; Marta Starnoni, MD; Giorgio De Santis, MD

Dear Sir,

We have found a lot of interest in the use of a cold atmospheric plasma device (Renuvion/J-Plasma; Apyx Medical, Clearwater, Fla.). This surgical instrument can be used for both therapeutic and cosmetic applications. It has been used in different fields (from general to gynecology surgery) for open and laparoscopic cases.¹ In plastic/cosmetic surgery, radio frequency helium plasma has been shown to be very effective for skin rejuvenation and skin tightening and also for rhinophyma reduction and skin cancer treatment.²

We have focused our attention on the use of J-Plasma in flap elevation. In fact, in an attempt to improve and enhance surgical techniques and patient care, the use of surgical instruments different from traditional electro-surgery for flap elevation is widely described in the literature. For example, the use of harmonic scalpel has been reported in the latissimus dorsi, deep inferior epigastric perforator, and fibula flap harvest.³⁻⁵

The technical advantages of J-Plasma when compared with conventional electro-surgical devices include minimal lateral and depth of thermal spread, a high level of precision, and less smoke, odor, and eschar. Moreover, the ability to provide consistent power across a wide range of tissue impedances makes it effective on many tissue types.²

We have experienced this surgical instrument for the dissection of osteoseptocutaneous flaps (12 cases of fibula free flap), fasciocutaneous flaps (10 cases of radial free forearm flap) (Fig. 1), and musculocutaneous flaps (15 cases of latissimus dorsi flap) without any observed complications. The setting of the instrument used was different in fibula free flap (J-Plasma mode, at 4-L flow and 30% power), radial free forearm flap (J-Plasma mode, at 3-L flow and 20% power), and latissimus dorsi flap (J-Plasma mode, at 4-L and 50% power) harvest.

We would like to share our experience in the attempt to facilitate the setting of this instrument for plastic surgeons interested in its use in flap elevation.

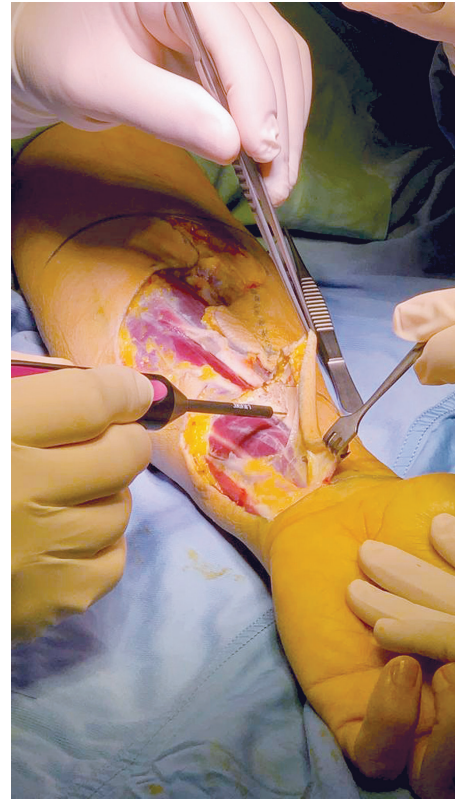


Fig. 1. Use of cold atmospheric plasma device in radial-free forearm flap elevation.

In our experience, we have observed significant differences between the use of the J-Plasma cool helium plasma and the traditional monopolar electro-surgery in flap elevation such as simultaneous tissue dissection and hemostasis, the absence of muscle contraction, the absence of fat necrosis without oil formation and tissue burn during dissection, and surgeons' reduced fear of unintended tissue trauma.

Our limited use in few cases, coupled with good outcomes, has allowed us to continue with the use of this surgical device moving forward. In our opinion, this instrumental device can be very useful in plastic surgery not only for skin tightening but also for pedicle and free flap elevation utilizing the proper settings.

Marta Starnoni, MD

Modena University Hospital
Largo Pozzo 71
41124 Modena
Italy

E-mail: martastarn@gmail.com

DISCLOSURE

The authors have no financial interest to declare in relation to the content of this article.

From the Department of Medical and Surgical Sciences, Division of Plastic Surgery, University of Modena and Reggio Emilia, Modena, Italy.

Received for publication March 3, 2020; accepted March 16, 2020.

Copyright © 2020 The Authors. Published by Wolters Kluwer Health, Inc. on behalf of The American Society of Plastic Surgeons. This is an open-access article distributed under the terms of the Creative Commons Attribution-Non Commercial-No Derivatives License 4.0 (CCBY-NC-ND), where it is permissible to download and share the work provided it is properly cited. The work cannot be changed in any way or used commercially without permission from the journal.

Plast Reconstr Surg Glob Open 2020;8:e2815; doi: 10.1097/GOX.0000000000002815; Published online 22 May 2020.)

REFERENCES

1. Pedroso JD, Gutierrez MM, Volker KW, et al. Thermal effect of J-plasma(R) energy in a porcine tissue model: implications for minimally invasive surgery. *Surg Technol Int*. 2017;30:19–24.
2. Gentile RD. Renuvion/J-plasma for subdermal skin tightening facial contouring and skin rejuvenation of the face and neck. *Facial Plast Surg Clin North Am*. 2019;27:273–290.
3. Starmoni M, De Santis G, Pinelli M. Fibula free flap elevation without tourniquet: are harmonic scalpel shears useful? *Plast Reconstr Surg Glob Open*. 2019;7:e2409.
4. Baccarani A, Starmoni M, De Santis G. Ultrasonic cutting and coagulating device in implant-based breast reconstruction. *Plast Reconstr Surg Glob Open*. 2018;6:e2020.
5. Lee YJ, Kim HY, Han HH, et al. Comparison of dissection with harmonic scalpel and conventional bipolar electrocautery in deep inferior epigastric perforator flap surgery: a consecutive cohort study. *J Plast Reconstr Aesthet Surg*. 2017;70:222–228.