

Rapidly fatal West Nile virus meningoencephalitis in an immunocompetent patient: a case report

Date : 14-05-2019

- [Brugioni Lucio](#)
- [Brief Report and Case Report](#)

Rapidly fatal West Nile virus meningoencephalitis in an immunocompetent patient: a case report

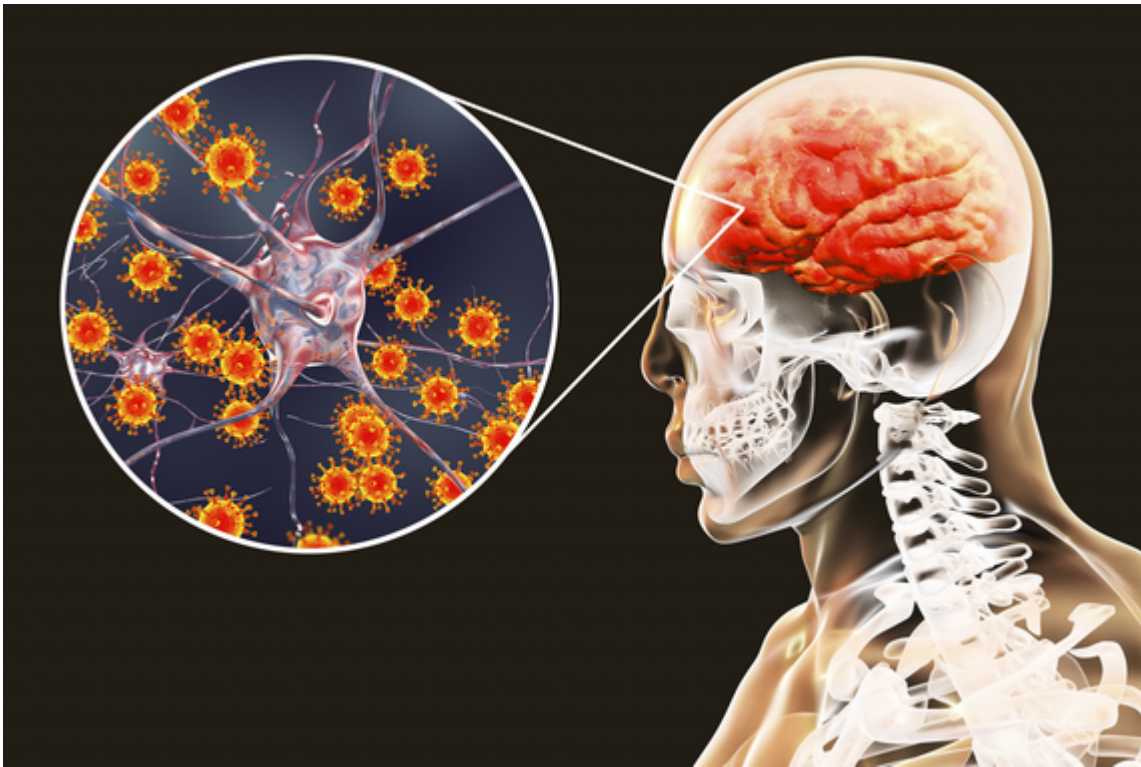
- [2/2019-giugno](#)
- [ISSN 2532-1285](#)
- <https://doi.org/10.23832/ITJEM.2019.022>



Brugioni Lucio¹, Ciaffi Sara¹, De Niederhausern Francesca¹, Gozzi Chiara¹, Ognibene Chiara¹, Borsatti Andrea¹, Martella Pietro¹, Romagnoli Elisa¹, Rosa Maria Cristina¹, Vivoli Daniela¹, Francesca Mori², Piani Federica³



- 1) Medicina Interna ed Area Critica, Azienda Ospedaliero Universitaria Policlinico di Modena, Modena, Italia
- 2) Scuola di Specializzazione in Medicina d'Emergenza ed Urgenza, Università di Modena e Reggio Emilia, Modena, Italia
- 3) Scuola di Specializzazione in Medicina Interna, Università di Bologna, Dipartimento di Scienze mediche e Chirurgiche, Bologna, Italia



Abstract

Background

West Nile virus (WNV) is a Flaviviridae most often transmitted by mosquitos. Clinical manifestations vary from no symptoms to neuroinvasive disease. Mortality is rare, but patients with neuroinvasive disease have a fatality rate of 4-14%. Diagnosis is made on epidemiological, clinical and serological criteria. Treatment is based on symptomatic and support therapy. WNV neuroinvasive disease seems associated to advancing age and diabetes, but poor prognosis risk factors are still not clearly recognized.

During 2017-2018 10 patients affected by WNV infection were admitted to our Hospital (Policlinico of Modena): 3 patients had a rapid fatal outcome and 3 needed intensive care transfer. We report the most representative case.

Case Report

A 81-yr-old man from Emilia-Romagna was admitted to our unit with a 6 days history of fever ($>38^{\circ}\text{C}$), fatigue, nausea, vomiting, hiccough and mild cognitive impairment treated with amoxicillin. Past medical history: type 2 diabetes mellitus, arterial hypertension, permanent pacemaker for type 3 atrioventricular block. Referred exposure to farm animals. No recent travels abroad. Chest x-ray showed a retrocardiac opacity, so empiric levofloxacin was started for suspected community acquired pneumonia. After two days the patient began lethargic with a Glasgow Come Score < 8 . Neuroinvasive WNV disease was confirmed by electroencephalogram and rachicentesis. Before serologic results acyclovir and dexamethasone were initiated without benefit and patient died on the fifth day after admission.

Conclusions

Risk factors for poor prognosis related to WNV Infection are still not clearly identified. Our patient underwent unexpected rapid clinical deterioration before invasive treatment could positively affect prognosis. This underlines the importance of clinical alert to WNV infections during transmission season in endemic areas and the necessity of more data on fatal WNV cases to define criteria to promptly recognize high-risk patients.

Keywords

encephalitis; meningoencephalitis; neuroinvasive disease; West Nile virus; fatal meningoencephalitis.

Introduction

West Nile virus (WNV) is a mosquito-borne single positive-stranded RNA virus of the family Flaviviridae. Different mosquito species can acquire and transmit WNV¹, *Culex* genus is the most involved². Transmission of WNV infection was also reported through blood transfusion, organ transplantation, sexual contact and vertically, through the placenta^{3,4,5,6,7}. The predominant reservoir are birds⁸. The resulting illness varies from no symptoms or influenza-like symptoms to neuroinvasive disease. In particular neuroinvasive disease occurs in less than 1% of the infections with a fatality rate of about 10%^{2,9,10}. From epidemiological data we know that advancing age and diabetes are associated with the risk of developing WNV neuroinvasive disease^{9,11}. Probably other chronic conditions (e.g. chronic heart failure) can predispose to neuroinvasive disease^{11,12}. In contrast risk factors for poor prognosis are still not clearly recognized. No therapy is currently approved for use in humans. Since the beginning of the 2017 transmission season, Italy has been one of the most affected Country in the EU Members States and neighboring countries (first in in 2018 with 576 reported cases¹³), and Emilia-Romagna one of the region with the higher incidence. Both lineage 1 and 2 are present in Italy. The disease incidence has increased since 2008^{11,14}, and during the two year period 2017-2018 an increase has been registered in Europe. Data collected by our Institution (Policlinico of Modena) have confirmed the European trend^{2,15}: of 10 patients affected by West Nile Virus infection, 8 of them were admitted in 2018. Most of the patients affected (7 of 10) were primarily admitted in Infectivology, 2 were referred to our unit (Internal Medicine and Critical Care) and 1 to Hematology. 3 cases had a rapid fatal outcome, including the 2 patients admitted in 2017. About 1/3 (3 of 10) of cases needed transfer in intensive care, and 2 of them survived. We report the most representative case.

Case Report

A 81-yr-old man from Emilia-Romagna region was admitted to our unit with fever (>38°C, 100.4°F) since last 6 days, fatigue, nausea, vomiting, hiccough and mild cognitive impairment referred by his family. His medical history was significant for: type 2 diabetes mellitus, arterial hypertension, permanent pacemaker since September 2016 for type 3 atrioventricular block. His current history was notable for exposure to farm animals. He had not travelled abroad in the previous months.

At admission examination, the patient was aware and spatial and temporal oriented. The remaining physical examination was normal. His vital signs were: blood pressure 150/70 mmHg, heart rate 88/min, oxygen saturation 97%, respiratory rate 24/min, temperature 38°C (100.4°F). The laboratory findings showed: hemoglobin 12.5 g/dL, hematocrit 34.4%, leukocytes $7 \times 10^3/\text{mm}^3$, PLT $171 \times 10^3/\text{mm}^3$, C-reactive protein 0.6 mg/dL, glucose 293 mg/dL and sodium 130 mEq/L. Kidney and liver function tests were normal. Chest X-ray showed a bad-defined *retro cardiac opacity* in the left lung. The abdominal ultrasound was negative. Since the patient took amoxicillin for 5 days before admission, empiric levofloxacin was initiated for suspected community acquired pneumonia. Two sets of blood cultures and urine culture were collected without growth of any

microorganism. Pneumococcal and Legionella urinary antigen tests were negative. The patient persisted febrile despite antipyretic therapy (Figure 1).

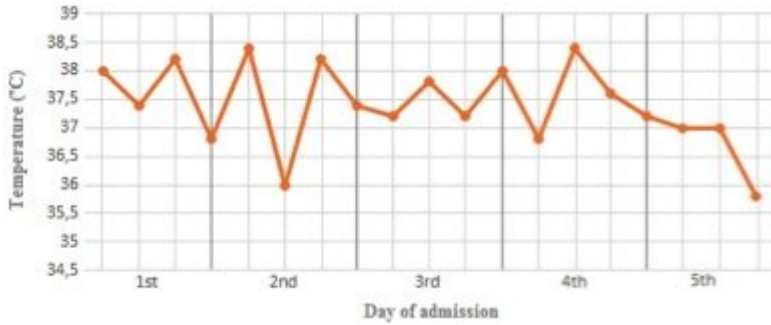


Figure 1. Patient's temperature chart. Auricular temperature was taken four times a day (6 a.m., 12 a.m., 18 p.m., 12 p.m.)

On the third day of admission the patient began lethargic with a Glasgow come score < 8. A head CT scan showed a slightly enlarged ventricular system without evidence of ischemic or hemorrhagic stroke, space-occupying lesions or asymmetry (Figure 2).

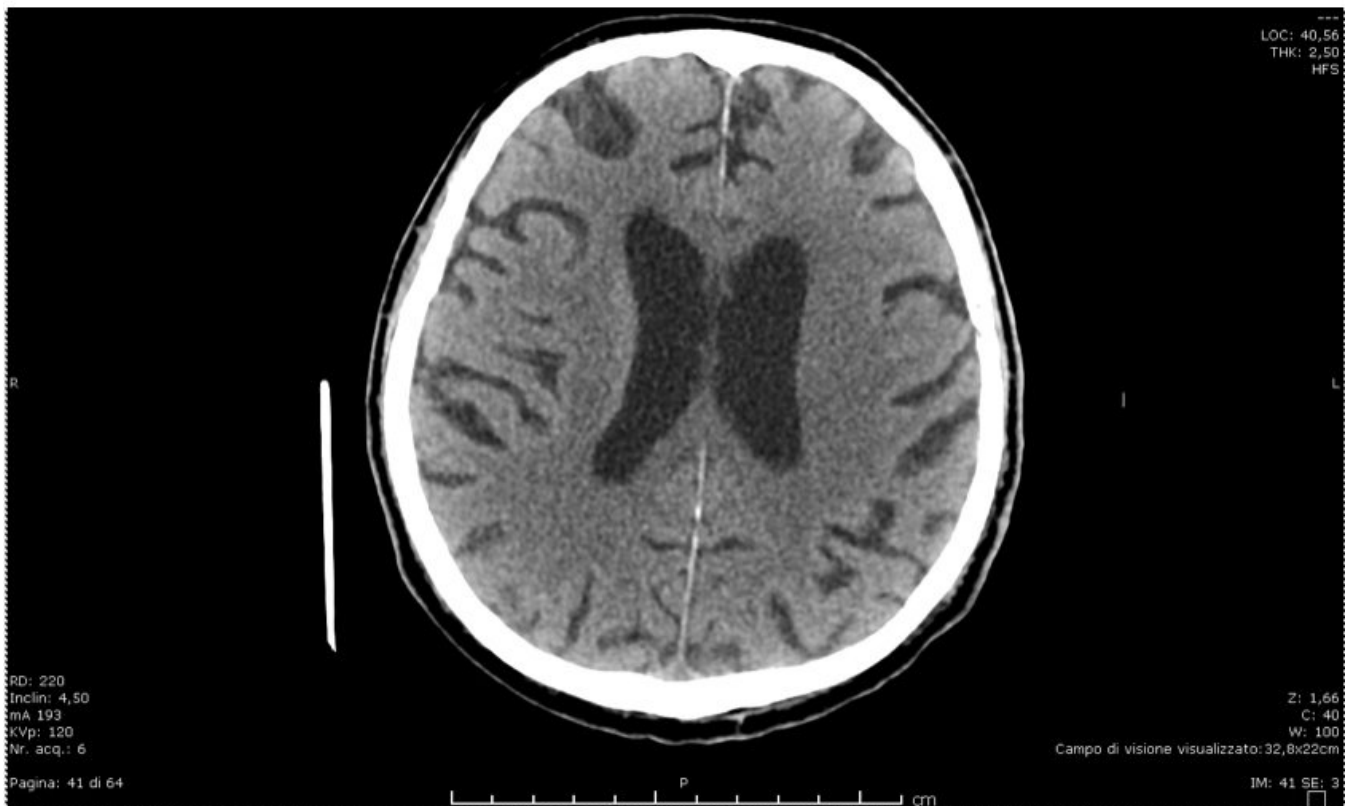

Figure 2. Head CT scan of the patient. There is a mild dilatation of the ventricular system without others

abnormalities

An electroencephalogram (EEG) was performed with the evidence of diffuse slower theta EEG background without focal anomalies. Thus, EEG was indicative of diffuse brain injury. It was impossible to perform magnetic resonance imaging because of the pacemaker contraindication. Analysis of cerebrospinal fluid (CSF) demonstrated 14 cells/ μ L (norm: < 4 cells/ μ L) with a predominance of lymphocytes and monocytes, 229 mg/dL protein (norm: 12–60 mg/dL), 118 mg/dL glucose (norm: 40–80 mg/dL) and 3.1 mmol/L lactate (norm: 0.5–2.4 mmol/L). CSF culture was negative for bacteria, fungi and mycobacteria. Real-time polymerase chain reaction analysis of CSF did not detect any virus, bacteria or yeast. On the advice of Infectivologist we started therapy with acyclovir 750mg t.i.d. and dexamethasone 3g q.i.d.. The patient died the next day, on the fifth day after admission. Finally liquor serology showed the presence of immunoglobulin (Ig)M and IgG against West Nile Virus.

Conclusions

As underlined above, risk factors for poor prognosis are still not clearly identified to date.

A variety of factors might contribute to fatal outcome (e.g. immunosuppression states, diabetes, age) but more comprehensive epidemiologic and clinical summaries are needed. Our patient had an advanced age and suffered from diabetes mellitus and arterial hypertension. He underwent unexpected rapid clinical deterioration before any invasive treatment could be carried out. Thus, data on larger numbers of fatal WNV cases may help to promptly recognize high-risk patients who could benefit from early invasive management.

References

1. Colpitts TM, Conway MJ, Montgomery RR, Fikrig E. West Nile Virus: Biology, Transmission, and Human Infection. *Clin Microbiol Rev.* 2012 Oct; 25(4):635–648.
2. Data from World Health Organisation: <http://www.euro.who.int/en/countries/italy/news/news/2018/8/west-nile-virus-infections-spik-e-in-southern-and-central-europe>
3. Groves JA, Shafi H, Nomura JH, Herron RM, Baez D, Dodd RY et al.. A probable case of West Nile virus transfusion transmission. *Transfusion.* 2017 Mar; 57(3pt2):850-856. doi: 10.1111/trf.14018. Epub 2017 Feb 5.
4. Julander JG, Winger QA, Rickords LF, Shi PY, Tilgner M, Binduga-Gajewska I, et al. West Nile virus infection of the placenta. *Virology.* 2006 Mar 30;347(1):175-82. Epub 2006 Jan 9.
5. Kelley RE, Berger JR, Kelley BP. West Nile virus meningo-encephalitis: possible sexual transmission. *J La State Med Soc.* 2016 Jan-Feb; 168(1):21-2. Epub 2016 Feb 15.
6. O'Leary DR, Kuhn S, Kniss KL, Hinckley AF, Rasmussen SA, Pape WJ, et al. Birth outcomes following West Nile Virus infection of pregnant women in the United States: 2003-2004. *Pediatrics.* 2006 Mar; 117(3):e537-45.
7. Roos KL. West Nile encephalitis and myelitis. *Curr Opin Neurol* 2004; 17: 343-6
8. Ciota AT. West Nile virus and its vectors. *Curr Opin Insect Sci.* 2017 Aug; 22:28-36. doi: 10.1016/j.cois.2017.05.002. Epub 2017 May 9. Review.
9. Nash D, Mostashari F, Fine A, Miller J, O'Leary D, Murray K et al. The outbreak of West Nile virus infection in the New York City area in 1999. *N Engl J Med.* 2001 Jun 14; 344(24):1807-14.
10. Papa A. West Nile virus infections in humans—Focus on Greece. Review article. *Journal of Clinical Virology*, Volume 58, Issue 2, October 2013, Pages 351-353
11. Rizzo C, Napoli C, Venturi G, Pupella S, Lombardini L, Calistri P, et al. West Nile virus transmission: results from the integrated surveillance system in Italy, 2008 to 2015. *Euro Surveill.* 2016 Sep 15;21(37).

12. Bode AV, Sejvar JJ, Pape WJ, Campbell GL, Marfin AA. West Nile virus disease: a descriptive study of 228 patients hospitalized in a 4-county region of Colorado in 2003. *Clin Infect Dis*. 2006 May 1; 42(9):1234-40. Epub 2006 Mar 30.
13. ECDC: Epidemiological update: West Nile virus transmission season in Europe, 2018 <https://ecdc.europa.eu/en/news-events/epidemiological-update-west-nile-virus-transmission-season-europe-2018>
14. European Centre for Disease Prevention and Control (ECDC). West Nile virus infection Surveillance Atlas. Available from: <https://ecdc.europa.eu/en/west-nile-fever/surveillance-and-disease-data/disease-data-ecdc>.
15. ECDC: Transmission of West Nile virus, June to December 2018 -Table of cases, 2018 transmission season. <https://ecdc.europa.eu/en/publications-data/transmission-west-nile-virus-june-december-2018-table-cases-2018-transmission>