

Case Report

Clinical Management of Acinic Cell Carcinoma of the Lacrimal Gland

Alexandre Anesi^a Sara Negrello^a Donatella Lucchetti^b
Giuseppe Pollastri^a Lorenzo Trevisiol^c Licia Badiali^d Andrea Lazzerini^d
Gian Maria Cavallini^d Luigi Chiarini^a

^aCranio-Maxillo-Facial Surgery Unit, University Hospital of Modena, Modena, Italy;

^bInstitute of General Pathology, Catholic University of the Sacred Heart, Rome, Italy;

^cUnit of Dentistry and Maxillo-Facial Surgery, University of Verona, Verona, Italy;

^dInstitute of Ophthalmology, University Hospital of Modena, Modena, Italy

Keywords

Lacrimal gland tumor · Acinic cell carcinoma · Low grade malignancies · Salivary gland tumors · Lateral orbitotomy · Piezosurgery

Abstract

To report a case of acinic cell carcinoma occurred in the lacrimal gland. A 59-year-old man was admitted because of sudden blurring of vision, progressive proptosis of the left eye, and mild double vision in left and down directions of the gaze (Hess-Lancaster test). His medical history detailed controlled bilateral keratoconus and open angle glaucoma. On examination, the best corrected visual acuity decreased from 8/20 till 1/50 in one week. There was a swelling of the left upper eyelid. A hard and tender mass was palpated in the superior temporal left orbit. Ultrasound scan showed an extraconal solid mass, situated in the superior lateral corner of the orbit. Computed tomography and magnetic resonance imaging (MRI) revealed a mass of two centimeters in diameter, with round well-defined outline, within the lacrimal gland. We performed an enucleoresection of the mass, via a coronal approach and a lateral orbitotomy by a piezosurgical device. The lesion appeared nodular, brownish, measuring about 2 × 1.5 cm.

Histopathological findings were consistent with acinic cell carcinoma with a microcystic, focally papillary-cystic growth of pattern. Follow-up MRI outcomes led to removal of the residual lacrimal gland for suspicion of recurrence. No tumor recurrences were detected at 7-year follow-up.

© 2019 The Author(s)
Published by S. Karger AG, Basel

Introduction

Lacrimal pathologies arise from all the structures related to the gland: epithelial tissue, lymphoid tissue, nervous and vascular tissue. Inflammatory and lymphoid lesions are two to three times more common than epithelial tumors that account for only 20–30% of lesions. The normal lacrimal gland is clinically impalpable and is located behind the supero-temporal orbital rim, in a hollow of the frontal bone called lacrimal fossa. Space occupying lesions of the lacrimal gland and its fossa constitute approximately 5% to 25% of orbital masses upon biopsy [1]. Epithelial tumors usually arise from the orbital lobe of the lacrimal gland and tend to spread posteriorly within the orbit, along its lateral margin. However, around 17% of epithelial tumors arise from the palpebral segment and may be clinically visible in the fornix of the conjunctiva [2].

The initial diagnosis is often wrong because these masses could be confused with a heterogeneous group of inflammatory lesions or benign neoplasms. The histopathologic classification of epithelial lacrimal gland tumors is identical to that used in salivary gland tumors, as originally proposed by Foote and Frazell [3]. Rootman et al. in 2009 proposed an histopathologic type classification of lacrimal tumors, dividing the tumors into low and high grade on the basis of the World Health Organization classification of salivary gland neoplasm, although some histopathologic type have been described only in case report series (Table 1) [4, 5]. In order of frequency, the most common epithelial tumors are: benign mixed tumor or pleomorphic adenoma, adenoid cystic carcinoma and adenocarcinoma. Other rare variants of carcinoma are also seen, such as mucoepidermoid carcinoma and squamous cell carcinoma of the lacrimal gland [6–8].

In this paper, we focused on clinical management of low grade malignant primary epithelial tumors of the lacrimal gland, in particular on acinic cell carcinoma (AcCC) and we presented a case report.

Case Report/Case Presentation

In January 2012 a 59-year-old man was referred to the ophthalmologist for a sudden blurring of vision and orbital swelling on the left eye; his medical history detailed a bilateral keratoconus and open angle glaucoma, well controlled with topical therapy. The best corrected visual acuity decreased from 8/20 till 1/50 in one week. A corneal edema in the left eye was detected by physical examination and the retina was not detectable. In order to investigate the disease, the physician required an orbital ultrasound scan, which showed an extraconal solid mass with round well-defined outline, situated in the superior lateral corner of the left

orbit. The patient was then admitted to treat this intra-orbital tumor at Cranio-Maxillo-Facial Unit, University Hospital of Modena.

The patient had a proptosis of the left eye at the time of admission into the hospital (Fig. 1a). There was a swelling of the left upper eyelid. A hard and tender mass was palpated in the superior temporal left orbit. The patient complained of mild double vision in left and down directions of the gaze, with a pathologic Hess-Lancaster test. The horizontal separation of perceived images by the patient and the worsening of diplopia in left gaze suggested limitation of left lateral rectus movement, since double vision is often worse in the field of action of the weakened ocular muscle.

Computed tomography (CT) revealed a mass which was 2 × 2.5 cm in size, well circumscribed, of ovoid shape, within the left lacrimal fossa, with a central region hypodense to muscle and homogeneous soft tissue density border (Fig. 1a, e). The tumor displaced medially the lateral rectus muscle (Fig. 1c). The mass did not appear well separable from the lacrimal gland and a slight scalloping of the greater sphenoid wing was evident (Fig. 1a). MRI showed an oval mass in the left lacrimal fossa, about two centimeters in diameter that appeared within normal lacrimal gland tissue. Tumor was heterogeneous, with mild and irregular enhancement following administration of contrast medium (gadolinium) (Fig. 1c, d, f–h). Radiologist described a solid mass within the lacrimal gland, hypothesizing a pleomorphic adenoma. However, since imaging findings were not pathognomonic, we decided to proceed with complete excision of the mass, without a diagnostic incisional biopsy. Preoperative CT and MR imaging were consistent with a completely localized disease within the lacrimal gland. To approach this malignancy we chose a coronal approach to get an easy control of the lacrimal fossa and aesthetically and functionally preserve the eyelid and periorbital skin. After general anesthesia and local injection of lidocaine and epinephrine (lidocaine and epinephrine 1:200,000), a bicoronal skin incision was made a few millimeters behind the hairline and just anterior to the tragus of the left ear, extending approximately to the superior temporal line on the opposite side. The scalp flap was developed anteriorly to expose the orbital margin from the superior orbital rim to the zygomatic arch; so the facial nerve preservation was achieved [9]. Then, the temporalis muscle was dissected subperiosteally and retracted posteriorly to completely expose the lateral orbital rim and the outer surface of the great sphenoid wing. The periorbita was elevated from the inner surface of the lateral wall of the orbit. After preplating the lateral orbital rim with two titanium microplates, a lateral orbitotomy was performed using a piezoelectric osteotome (Piezosurgery® Medical; MT1–10 tip; Mectron Medical Technology, Carasco, Italy), because less traumatic for orbital content and to improve osteotomic bone healing [10–12]. The former osteotomy was made just above the zygomatic-frontal suture line and the latter approximately 1, 5 cm below. The lateral orbital rim was out-fractured with a rongeur, removed and preserved in saline solution. The periorbita was opened, showing a mass of approximately 2 cm, adherent to the lacrimal gland (Fig. 2a). The lesion was well demarcated within the lacrimal gland and enucleoresection was performed. The periorbital fascia was relocated and the lateral orbital rim was reinserted in its correct anatomic position and fixated with previous pre-platted two microplates and screws (Fig. 2b) [13], without the need for a bone substitute [14–21]. A drain tube was placed; the muscular fascia, subcutaneous tissue and skin suturing is performed without any local flaps [22]; a firm compressive dressing is applied for 48 hours and then removed.

On gross examination the lesion appeared nodular, brownish, measuring about 2 × 1.5 cm. Histopathological examination demonstrated a monomorphic epithelial tumor, composed of basophilic cells with prominent nucleoli and granular cytoplasm. Microcystic and focal papillary areas were present (Fig. 3a). Melanin pigment deposition was occasionally revealed (Fig. 3b). Immunohistochemistry revealed positivity for cytokeratin 7. Immunohistochemical analyses using S-100 protein, p63 (transformation-related protein 63), CD34 (cluster of designation 34), TTF1 (thyroid transcription factor-1), CD 10 (cluster of designation 10) and muscle actin antibodies were negative. Histopathological findings were consistent with acinic cell carcinoma (AcCC) with a microcystic, focally papillary-cystic growth of pattern. The mass appeared well-circumscribed, and did not involve the margins of resection. There was no evidence of vascular nor perineural invasion. Neither mitosis nor necrosis was observed. Proliferation rate was 2–4%, according to MIB-1 (antibody against Ki-67 protein) proliferation index. According to American Joint Committee on Cancer (AJCC) Eight Edition Staging System for lacrimal gland carcinomas, the staging of this AcCC is T1N0M0 [23].

The postoperative course was uneventful, exophthalmos and ocular pain slowly subsided. Acuity vision improved and the patient was discharged 3 days after the operation. Early postoperative head CT scan showed complete removal; contrast chest CT scan and ultrasound scan of the liver were performed to assess pulmonary or liver metastases, which resulted respectively normal. The patient's case was debated at our local head & neck cancer multidisciplinary team meeting. Given the low grade malignancy of this tumor and the apparent radical excision of the mass, the meeting decided for no other postoperative treatment and to carry out a careful follow-up in order to notice any eventual recurrence. MRI at 6 months showed an area of solid tissue of about 1.5 cm characterized by a low enhancement in the left lacrimal fossa. The patient did not present any clinical signs of disease. Considering the lack of specificity of MRI in detecting a low grade malignancy recurrence, we decided to perform the complete removal of the residual lacrimal gland under general anesthesia through the previous coronal access. Histological examination of the surgical specimen revealed normal lacrimal gland and fibrous tissue free from cancer.

Visual acuity was 8/20 fifteen months after surgery; the keratoconus did not get worse and no corneal edema and flare were present in anterior chamber. Intraocular pressure was 14 mm Hg without changes in topical therapy. The patient did not refer diplopia. Hess-Lan-caster test showed recovery of extraocular muscles action. The patient is now free from disease at 7-year follow-up. Hyaluronic acid eye drops (Xailin HA, Visufarma, s.p.a., Rome, Italy) were provided in the post-operative period for the left eye, to compensate for the reduced lacrimation that would now affect that eye. As time goes by tears from accessory lacrimal glands were sufficient to maintain a stable tear layer on the cornea, and artificial tears use have come to be not regular. No tumor recurrences were detected at 7-year follow-up.

Discussion

AcCC is very rare in lacrimal gland and exceptional in the sinonasal tract [24]. The imaging characteristics of lacrimal gland tumors are nonspecific, with most lesions having a generally benign appearance, often appearing on CT and on MRI as a pleomorphic adenoma [25]. No papers are present in the English literature about positron emission tomography/computed

tomography (PET/CT) for AcCC of the lacrimal gland, whereas PET/CT may identify primary adenoid cystic carcinoma of the lacrimal gland [26].

The initial management of low grade malignant primary epithelial tumors of the lacrimal gland is complete surgical resection with tumor-free margins, given the difficulty in preoperatively differentiating malignant from benign lesions. Incisional biopsy for diagnosis is often avoided because this procedure is occasionally associated with local recurrences [27, 28]. The histological examination of surgical specimen remains the only method for a correct diagnosis. For small tumors of lacrimal apparatus Skinner et al. (2011) in a large study recommended evaluating eye-preserving surgery; adenoid cystic carcinoma was present in nearly half of these group of patients, histotype characterized by the worst prognosis between malignant neoplasia. Although the mainstay of treatment for malignant lacrimal gland tumors is surgery, the option among orbital sparing conservative surgery followed by postoperative radiation and orbital exenteration/cranio-facial approaches is debated [29–31]. Major evidences on postoperative radiotherapy effectiveness in local control of disease in lacrimal gland malignancies come from adenoid cystic carcinoma cases retrospective analysis [8], and are not appropriate to low grade malignancies.

Only four other cases of acinic cell carcinoma in the lacrimal gland have been reported in patients from 18 to 78 years of age (Table 2, Table 3) [32–35] and one case was present in case series of Verdijk et al. [36]. Two of these lesions showed a benign clinical behavior, while two proved to be aggressive, characterized by histopathological infiltrative comportment: bone involvement, intracranial extensions and local recurrence (Table 2, Table 3). In our case the mass was completely situated within the orbital lobe of the gland in the lacrimal fossa, without bone erosion. At the time of diagnosis no lymph nodal localization or distant metastasis were detected. Our patient was treated through an eye-sparing surgery that is excision of the mass together with a cuff of normal gland tissue around the lesion, followed 6 months later by residual gland removal for suspicion of recurrence. Considering the favorable prognostic factor (the malignancy is completely localized within normal lacrimal gland tissue, the lack of perineural and vascular invasion, the low mitotic index, the absence of mitosis and necrosis, and the integrity of the cortical bone and the surrounding soft tissue) and the disabling complications of more postoperative treatments, nor more therapies had been applied. Expected survival and freedom of metastasis for this patient is good, according to the state of low grade malignancy for AcCC and the staging ($\leq T2$) [31].

TNM classification for primary carcinomas of the lacrimal gland is significantly changed from the AJCC Cancer Staging Manual, 7th Edition staging system. Comparing seventh and eighth edition of the AJCC staging system, we can note that the attention for bone involvement has gained importance [5, 23]. Broadly speaking, local extent of cancer contribute in determining appropriate treatment [37], and for carcinoma high T number often relates to more extensive surgery. In orbital pathology extensive and demolitive surgery corresponds to exenteration orbitae, while more and more authors recommend globe-preserving surgery, based on similar survival outcomes to those in patients treated with an orbital exenteration [31].

T1 or T2 – a mild score – can indifferently correspond to orbital sparing surgery or orbital exenteration in seventh and eighth edition of AJCC Staging Manual, lacrimal gland carcinoma staging system (Table 2, Table 3). In clinical practice the following factors determine the surgical extent in lacrimal gland malignancies: infiltrated orbital tissue beyond lacrimal capsule, sphenoid bone involvement, intracranial extension, dura involvement suspicion, high grade

carcinoma, treatment of recurrence [31, 38, 39]. According to us the correlation between high T score and wide surgical excision (exenteration orbitae) is not strong for AcCC (Table 2, Table 3) and for other low grade carcinomas of the lacrimal gland, in both last two editions of the AJCC staging system manual, lacrimal gland carcinoma staging system. However, it is important to remember that changes undertaken by the authors of the AJCC Cancer Staging Manual, 8th Edition lacrimal gland carcinoma staging system are aimed to determining which factor—tumor size or periosteal or bone invasion – is the most important factor in defining outcome for these malignancies [23].

In our opinion, considering the limited literature inherent lacrimal gland AcCC, the clinical care of low grade malignancy should considerate some aspects. Diffusion of the malignancy outside of lacrimal gland, history of recurrences, periosteal involvement, bone erosion, dural infiltration, high mitotic index, and presence of perineural and vascular invasion can predict a poor outcome: in this situation radical surgery even or without eye-preserving is necessary; adjuvant radiation therapy is mandatory or consider neutron therapy, if available. We recommend eye-preserving surgery for a new onset of a localized low grade malignancy of lacrimal gland, to be carried out by an entire en bloc removal of the lacrimal gland through a lateral orbitotomy for wide exposure in large lesions [39]. A close follow up through MR imaging is advisable. However, as the imaging characteristics of AcCC are nonspecific, a suspicion of recurrence disclosed during imaging follow-up requires a surgical biopsy. More studies for low grade malignancies of the lacrimal gland supported by large numbers of patients are needed.

Statement of Ethics

Due to the retrospective nature of this study, it was granted an exemption by the Institutional Review Board of the University Hospital of Modena, Italy. All procedures performed involving human participant were in accordance with the 1964 Helsinki Declaration and its later amendments or comparable ethical standards.

The patient consented to publication of this report and clinical photographs.

Disclosure Statement

The authors have no conflicts of interest to declare.

Funding Sources

No funding was received for this work.

Author Contributions

Conceptualization: Alexandre Anesi; Lorenzo Trevisiol.

Methodology: Donatella Luchetti, Alexandre Anesi.

Data curation: Giuseppe Pollastri, Andrea Lazzerini, Licia Badiali.

Writing original draft preparation: Alexandre Anesi; Sara Negrello.

Writing review and editing: Alexandre Anesi; Luigi Chiarini; Gian Maria Cavallini.

References

- 1 Montalban A, Liétin B, Louvrier C, Russier M, Kemeny JL, Mom T, et al. Malignant lacrimal sac tumors. *Eur Ann Otorhinolaryngol Head Neck Dis*. 2010 Nov;127(5):165–72.
- 2 Vangveeravong S, Katz SE, Rootman J, White V. Tumors arising in the palpebral lobe of the lacrimal gland. *Ophthalmology*. 1996 Oct;103(10):1606–12.
- 3 Foote FW Jr, Frazell EL. Tumors of the major salivary glands. *Cancer*. 1953 Nov;6(6):1065–133.
- 4 Rootman J, White VA. Changes in the 7th edition of the AJCC TNM classification and recommendations for pathologic analysis of lacrimal gland tumors. *Arch Pathol Lab Med*. 2009 Aug;133(8):1268–71.
- 5 Edge BS, Byrd D, Compton C, Fritz A, Greene F, Trotti A. Carcinoma of the Lacrimal Gland. In: Esmaeli B, Byrd D, Compton C, Fritz A, Greene F, Trotti A, editors. *AJCC Cancer Staging Manual*. 7th ed. New York: Springer; 2010. pp. 569–75.
- 6 Eviatar JA, Hornblass A. Mucoepidermoid carcinoma of the lacrimal gland: 25 cases and a review and update of the literature. *Ophthalm Plast Reconstr Surg*. 1993;9(3):170–81.
- 7 Perzin KH, Jakobiec FA, Livolsi VA, Desjardins L. Lacrimal gland malignant mixed tumors (carcinomas arising in benign mixed tumors): a clinico-pathologic study. *Cancer*. 1980 May;45(10):2593–606.
- 8 Wright JE, Rose GE, Garner A. Primary malignant neoplasms of the lacrimal gland. *Br J Ophthalmol*. 1992 Jul;76(7):401–7.
- 9 Baccarani A, Starnoni M, Zaccaria G, Anesi A, Benanti E, Spaggiari A, et al. Obturator Nerve Split for Gracilis Free-flap Double Reinnervation in Facial Paralysis. *Plast Reconstr Surg Glob Open*. 2019 Jun;(6):e2106.
- 10 Nordera P, Spanio di Spilimbergo S, Stenico A, Fornezza U, Volpin L, Padula E. The cutting-edge technique for safe osteotomies in craniofacial surgery: the piezosurgery bone scalpel. *Plast Reconstr Surg*. 2007 Dec;120(7):1989–95.
- 11 Chiarini L, Albanese M, Anesi A, Galzignato PF, Mortellaro C, Nocini P, et al. Surgical treatment of unilateral condylar hyperplasia with piezosurgery. *J Craniofac Surg*. 2014 May;25(3):808–10.
- 12 Anesi A, Ferretti M, Cavani F, Salvatori R, Bianchi M, Russo A, et al. Structural and ultrastructural analyses of bone regeneration in rabbit cranial osteotomy: piezosurgery versus traditional osteotomes. *J Craniomaxillofac Surg*. 2018 Jan;46(1):107–18.
- 13 Fior A, Anesi A, Nocini PF. Evolution in Bone Synthesis. *Atlas of Mandibular and Maxillary Reconstruction with the Fibula Flap*. Cham: Springer International Publishing; 2019. pp. 85–92.
- 14 Bellucci D, Salvatori R, Cannio M, Luginina M, Orru R, Montinaro S, et al. Bioglass and bioceramic composites processed by Spark Plasma Sintering (SPS): biological evaluation Versus SBF test. *Biomed Glas*. 2018;4(1):21–31.
- 15 Bellucci D, Sola A, Salvatori R, Anesi A, Chiarini L, Cannillo V. Sol-gel derived bioactive glasses with low tendency to crystallize: synthesis, post-sintering bioactivity and possible application for the production of porous scaffolds. *Mater Sci Eng C*. 2014 Oct;43:573–86.
- 16 Bellucci D, Sola A, Anesi A, Salvatori R, Chiarini L, Cannillo V. Bioactive glass/hydroxyapatite composites: mechanical properties and biological evaluation. *Mater Sci Eng C*. 2015 Jun;51:196–205.
- 17 Bellucci D, Anesi A, Salvatori R, Chiarini L, Cannillo V. A comparative in vivo evaluation of bioactive glasses and bioactive glass-based composites for bone tissue repair. *Mater Sci Eng C*. 2017 Oct;79:286–95.
- 18 Bellucci D, Salvatori R, Cannio M, Luginina M, Orrù R, Montinaro S, et al. Bioglass and bioceramic composites processed by Spark Plasma Sintering (SPS): biological evaluation Versus SBF test. *Biomed Glas*. 2018 Jan;4(1):21–31.
- 19 Bellucci D, Salvatori R, Anesi A, Chiarini L, Cannillo V. SBF assays, direct and indirect cell culture tests to evaluate the biological performance of bioglasses and bioglass-based composites: three paradigmatic cases. *Mater Sci Eng C*. 2019 Mar;96:757–64.
- 20 Bellucci D, Sola A, Salvatori R, Anesi A, Chiarini L, Cannillo V. Role of magnesium oxide and strontium oxide as modifiers in silicate-based bioactive glasses: effects on thermal behaviour, mechanical properties and in-vitro bioactivity. *Mater Sci Eng C*. 2017 Mar;72:566–75.
- 21 Nocini PF, Anesi A, Fior A. Bone Augmentation. *Atlas of Mandibular and Maxillary Reconstruction with the Fibula Flap*. Cham: Springer International Publishing; 2019. pp. 53–65.

- 22 Salgarelli AC, Bellini P, Magnoni C, Anesi A, Collini M. Synergistic use of local flaps for total lower lip reconstruction. *Dermatol Surg*. 2011 Nov;37(11):1666–70.
- 23 White VA, Esmaeli B, Dutton J, Heegaard S, Vivian Y, Sauerwein WA, et al. Lacrimal Gland Carcinoma. In: Amin MB, Greene F, Edge SB, editors. *AJCC Cancer Staging Manual*. 8th ed. New York: Springer; 2017. pp. 833–9.
- 24 Eveson JW, Nagao T, Nagao T. Diseases of the Salivary Glands. In: Barnes L, editor. *Surgical Pathology of the Head and Neck*. 3rd ed. New York: CRC; 2008. pp. 484–657.
- 25 Som PM, Margaret SB. Salivary Glands: Anatomy and pathology. In: Som PM, Curtin HD, editors. *Head and neck imaging*. 4th ed. St. Louis (Missouri): Mosby; 2003. pp. 2005–133.
- 26 Hui KH, Pfeiffer ML, Esmaeli B. Value of positron emission tomography/computed tomography in diagnosis and staging of primary ocular and orbital tumors. *Saudi J Ophthalmol*. 2012 Oct;26(4):365–71.
- 27 Zoumalan CI, Zoumalan RA, Cockerham KP. Surgical management of lacrimal gland tumors. *Oper Tech Otolaryngol Neck Surg*. 2008 Dec;19(4):252–7.
- 28 Alicandri-Ciuffelli M, Bonali M, Piccinini A, Marra L, Ghidini A, Cunsolo EM, et al. Surgical margins in head and neck squamous cell carcinoma: what is ‘close’? *Eur Arch Otorhinolaryngol*. 2013 Sep;270(10):2603–9.
- 29 Esmaeli B, Golio D, Kies M, DeMonte F. Surgical management of locally advanced adenoid cystic carcinoma of the lacrimal gland. *Ophthalm Plast Reconstr Surg*. 2006 Sep-Oct;22(5):366–70.
- 30 Esmaeli B, Ahmadi MA, Youssef A, Diba R, Amato M, Myers JN, et al. Outcomes in patients with adenoid cystic carcinoma of the lacrimal gland. *Ophthalm Plast Reconstr Surg*. 2004 Jan;20(1):22–6.
- 31 Skinner HD, Garden AS, Rosenthal DI, Ang KK, Morrison WH, Esmaeli B, et al. Outcomes of malignant tumors of the lacrimal apparatus: the University of Texas MD Anderson Cancer Center experience. *Cancer*. 2011 Jun;117(12):2801–10.
- 32 De Rosa G, Zeppa P, Tranfa F, Bonavolontà G. Acinic cell carcinoma arising in a lacrimal gland. First case report. *Cancer*. 1986 May;57(10):1988–91.
- 33 Rosenbaum PS, Mahadevia PS, Goodman LA, Kress Y. Acinic cell carcinoma of the lacrimal gland. *Arch Ophthalmol*. 1995 Jun;113(6):781–5.
- 34 Jang J, Kie JH, Lee SY, Kim SJ, Lew H, Hong SW, et al. Acinic cell carcinoma of the lacrimal gland with intracranial extension: a case report. *Ophthalm Plast Reconstr Surg*. 2001 Nov;17(6):454–7.
- 35 Bannister M, Lawson G. Papillary-cystic variant of acinic cell carcinoma in the lacrimal gland. *Case Rep Ophthalmol Med*. 2014;2014:285485.
- 36 Verdijk R, Pecorella I, Mooy C. The orbit, including the lacrimal gland and lacrimal drainage system. *Eye Pathology. An illustrated Guide*. Berlin, Heidelberg: Springer Berlin Heidelberg; 2015. pp. 547–54.
- 37 Gress DM, Edge SB, GF et al. Principles of Cancer Staging. In: Amin MB, Greene F, Edge SB, editors. *AJCC Cancer Staging Manual*. 8th ed. New York: Springer; 2017. pp. 3–5.
- 38 von Holstein SL, Coupland SE, Briscoe D, Le Tourneau C, Heegaard S. Epithelial tumours of the lacrimal gland: a clinical, histopathological, surgical and oncological survey. *Acta Ophthalmol*. 2013 May;91(3):195–206.
- 39 Shields JA. Lacrimal gland primary epithelial tumors. In: Shields JA, Shields CL, editors. *Eyelid, conjunctival, and orbital tumors: atlas and textbook*. 2nd ed. Philadelphia: Lippincott Williams & Wilkins; 2008. pp. 700–14.

Gian Maria Cavallini and Luigi Chiarini share last authorship.

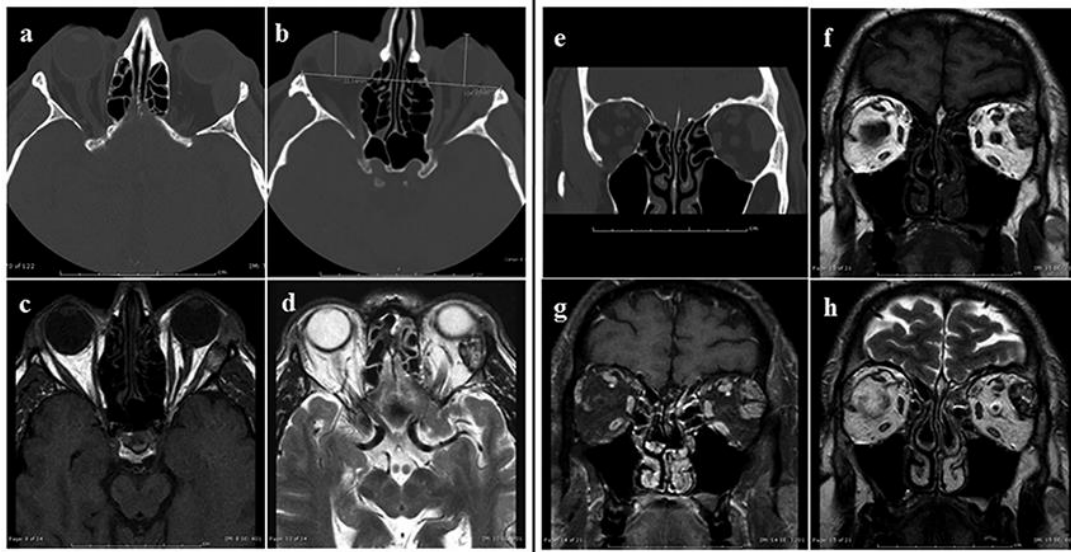


Fig. 1. Images of a solid mass (acinic cell carcinoma) within the left lacrimal gland. **(a)** Axial CT-scan images show an oval mass (2 × 2.5 cm) of heterogeneous density associated with the left lacrimal gland. There is a modest scalloping of the great wing of the left sphenoid bone. **(b)** CT-scan in axial view. The interzygomatic line was used as a reference for measuring the exophthalmos. 22.14 mm in right eye versus 25.65 mm in left one. Exophthalmos amounts of 3.51 mm. **(c)** T1-weighted spin-echo MR imaging of the tumor. The contour of the lesion is evident, as well as the separation between the mass and the extraocular muscle, the rectus lateralis muscle. **(d)** T2-weighted turbo spin-echo MR imaging shows an oval well defined mass in the superolateral extraocular compartment of the left orbit within lacrimal fossa; it is in contact with the postero-superior outline of the ocular globe. **(e)** coronal CT-scan images show an oval mass of heterogeneous density associated with the lacrimal gland. **(f)** T1-weighted spin-echo coronal MR imaging of the tumor. The outline of the lesion is evident; the density of the mass is not homogenous. **(g)** T1-weighted contrast-enhanced fat-suppressed spin-echo MR imaging. The tumor is well limited and presents a mild contrast-enhancement. **(h)** T2-weighted turbo spin-echo MR imaging. The tumor has well-defined borders and irregular density in the superolateral extraocular compartment of the left orbit within lacrimal fossa.

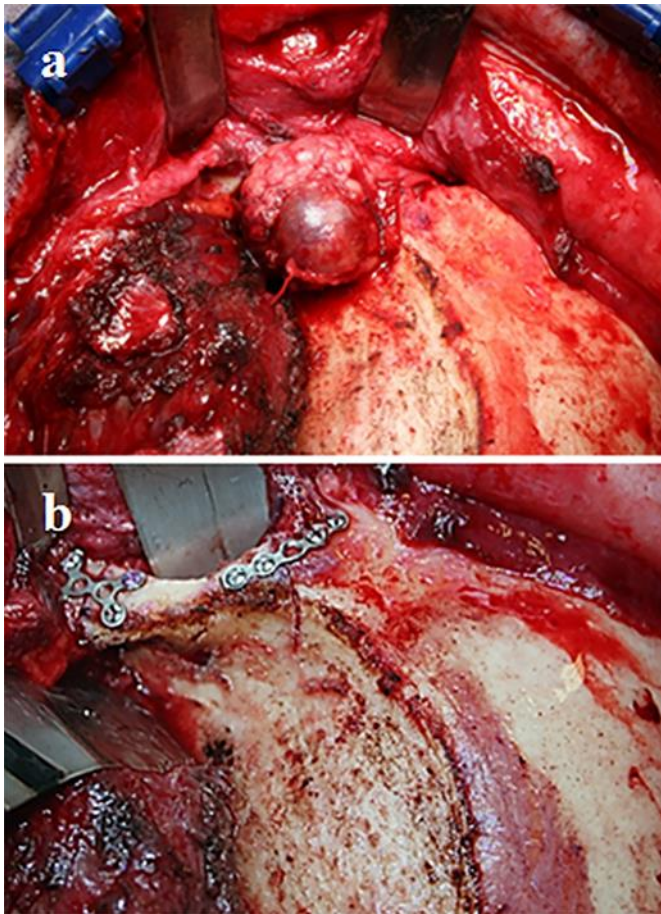


Fig. 2. Intraoperative views. **(a)** The left lacrimal fossa was exposed by means of the coronal approach, the skeletonization of the temporal fossa and the lateral orbitotomy was performed with piezosurgical scalpel. The acinic cell carcinoma appeared as a well circumscribed red-bluish mass within the lacrimal gland. **(b)** The left lateral orbital rim is easily repositioned throughout the pre-platted titanium plates. The osteotomic lines are thin and the matching with the orbital rim is accurate because a piezosurgical device was used.

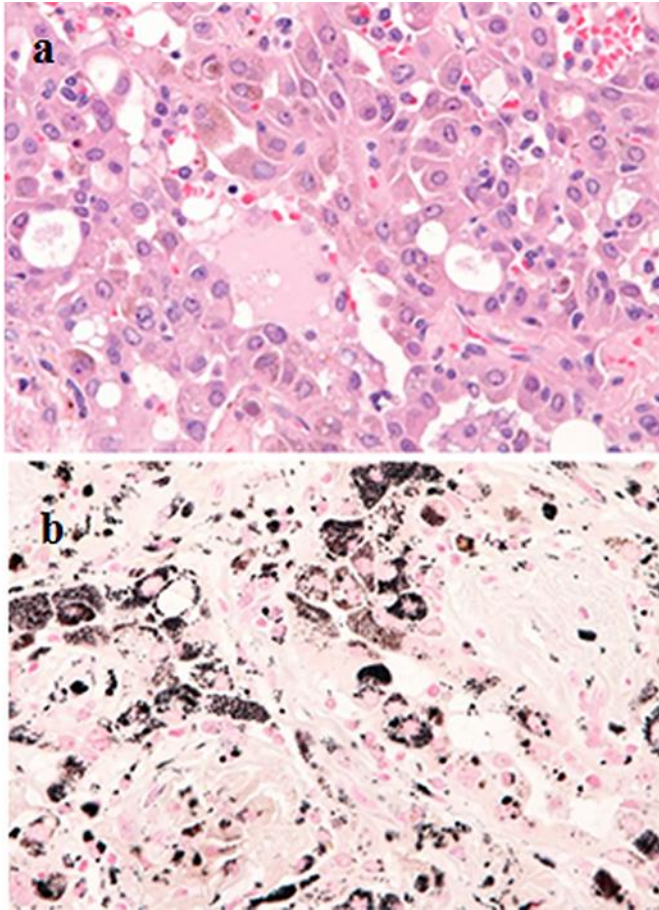


Fig. 3. (a) Light micrograph. The tumor was composed of basophilic cells with prominent nucleoli and intracytoplasmic fine granules of brownish pigment arranged in a solid and microcystic growth pattern (hematoxylin-eosin stain, 200× magnifications). (b) Light micrograph. Melanin pigments occasionally deposit in the interstitium (Masson-Fontana stain, 200× magnification).

Table 1. Histopathologic type of low grade malignant primary epithelial tumors of the lacrimal gland [23]

Carcinoma ex pleomorphic adenoma (see WHO classification for definition)
Polymorphous low-grade carcinoma
Mucoepidermoid carcinoma, grades 1 and 2
Epithelial-myoeithelial carcinoma
Cystadenocarcinoma and papillary cystadenocarcinoma
Acinic cell carcinoma
Basal cell adenocarcinoma
Mucinous adenocarcinoma

Table 2. Clinical history of the reported cases of acinic cell carcinoma of the lacrimal gland in the English literature and the present case report

Author (year reported)	Sex	Age at the time of diagnosis	Presentation	Imaging	Preoperative incisional biopsy and Treatment (globe-sparing surgery/orbital exenteration)	Pathology and pathology related variables	AJCC TNM	
							7th edition	8th edition
De Rosa et al., 1986 [32]	F	59	Painless exophthalmos, intraocular pressure raising, visual acuity reduced; Funduscopic examination: prominent retinal folds, engorgement of intraocular veins	CT: a large, round cystic mass in the right lacrimal fossa	No incisional biopsy; Globe-sparing surgery Temporal orbitotomy and total removal of the lesion respecting the thin capsule; No post-operative treatment Follow-up did not showed neither local relapses nor metastases	Gross examination: a nodular capsulated mass (30 mm in diameter); on cutting it appeared cystic with a yellowish, intralacrimonial fluid; Histopathological pattern: mixed pattern (solid and acinic with small microcystic spaces); Immunohistology not performed; The lesion appeared completely encapsulated; Some rests of the lacrimal gland could be identified; Neither perineural nor vascular infiltration was observed	pT2N0M0	pT2aN0M0
Rosenbaum et al., 1995 [33]	F	18	Previous surgery and radiotherapy for "adenocarcinoma of the lacrimal gland" in the same site (1985) For 2 years marked proptosis and inferior displacement of the right globe that showed limited motility; A prominent superolateral right orbital mass was easily palpable; Visual acuity reduced	CT: massive retrobulbar and extraconal orbital tumor demonstrating mixed cystic and solid components; No intracranial extension was noted; Present associated sclerosis of the greater sphenoid wing and erosive changes of the superior, posterior, and lateral orbital walls	In 1985: a right lateral orbitotomy was performed for "adenocarcinoma of the lacrimal gland;" Four months later, she received cobalt 60 (45 Gy) external beam irradiation to the right orbit for tumor recurrence In 1988: incisional biopsy revealed a diagnosis of "poorly differentiated adenocarcinoma;" One month later an exenteration of the right orbit was performed	1988: Gross examination of the exenteration specimen: a firm, multinodular mass; measuring 37×28×31 mm; on cutting the tumor appeared multinodular, brown-tan, and showed a large cystic cavity containing friable brown material; No normal lacrimal gland tissue was grossly identified; The tumor deformed the globe superiorly and was adherent to the temporal portions of the upper and lower lids; Histopathological pattern: predominantly microcystic Immunohistology performed; No bone involvement was described	rpT2N0M0	rpT2aN0M0
Jang et al., 2001 [34]	M	51	Intermittent swelling of the temporal upper eyelid for 2 years; Painful proptosis and headache for two months Reduced visual acuity; A hard and tender mass was palpated in the superior-temporal orbit	CT: a 33 x 23 mm mass with homogeneous enhancement in the superior temporal orbit; The mass displaced the eye inferiorly and eroded the orbital roof and wall; T2-weighted MRI showed an intermediate signal density; Enhancement of the lesion after administration of gadolinium contrast Intracranial extension was evident on the coronal scan; No evidence for distant metastasis	Incisional biopsy: acinic cell carcinoma Exenteration of the right orbit with excision of dura and sphenoid bone and removal of the intracranial mass through a transcranial approach; No post-operative treatment No recurrence after 2 ½ years follow-up	Gross examination: a yellowish-gray, solid, firm mass, measuring 35 x 25 mm was in the retrobulbar area; The mass had an infiltrative border not involving the margins; Histopathological pattern: solid and microcystic pattern Immunohistology performed; Perineural invasion was no evident The normal palpebral segment of the lacrimal gland was seen in the adjacent eyelid Dura and sphenoid bone were involved by the tumor	pT4bN0M0	pT2cN0M0

The AJCC TNM staging score of both the seventh and eighth editions was reported [5, 23]. Tumor size, periosteal and bone invasion are separately staged in the AJCC Cancer Staging Manual, 8th Edition lacrimal gland carcinoma staging, for understanding how these factors correlate with survival for these malignancies. No stage groupings are currently recommended for lacrimal gland carcinomas. The authors of lacrimal gland carcinoma staging in AJCC Cancer Staging Manual, 8th Edition pointed out the frailty of this classification due to the lack of large studies [23]. In the five case reports of AcCC here discussed we can compare the staging score among seventh and eighth edition of AJCC staging system, and some observations can be made. A downgrading in T staging can be noticed in the case described by Jang [34] from T4b to T2c, respectively in seventh and eighth edition of the AJCC staging system. No significant changes in staging are detectable comparing the seventh and eighth edition of the AJCC staging system in reviewing the other 3 cases of AcCC of the literature and the case report here described. Focusing on surgical treatment for AcCC of the lacrimal gland, we can note that the tumor extent in the case reported by Rosenbaum [33] required an orbital exenteration because of globe and eyelid involvement. Orbital exenteration is related to high morbidity, but according to the seventh and eighth edition of the AJCC staging system, T number (T2) in Rosenbaum's case [33] is analogue to T scoring in De Rosa's case [32], in Bannister and Lawson's case [35], and in the case here presented, in all of which orbital sparing surgery was successfully used and not orbital exenteration. In conclusion, the correlation between high T score and wide surgical excision (exenteration orbitae) is not strong for AcCC and for other low grade carcinomas of the lacrimal gland, in both last two editions of the AJCC staging system manual lacrimal gland carcinoma staging system.

Table 3. Clinical history of the reported cases of acinic cell carcinoma of the lacrimal gland in the English literature and the present case report (continued)

Author (year reported)	Sex	Age at the time of diagnosis	Presentation	Imaging	Preoperative incisional biopsy and Treatment (globe-sparing surgery/orbital exenteration)	Pathology and pathology related variables	AJCC TNM	
							7th edition	8th edition
Bannister and Lawson, 2014 [35]	F	78	A 12-month history of a mass over the right eye No pain or change in periocular sensation; Normal visual acuity	CT: Supraorbital mass arising from the palpebral lobe of the lacrimal gland, without orbital erosion	No incisional biopsy; Globe-sparing surgery; Orbitotomy and entire lacrimal gland removal No post-operative treatment; No recurrence	Histopathological pattern: papillary-cystic variant AcCC; The lesion appeared completely within the lacrimal gland; Some rests of the lacrimal gland could be identified; No immunohistochemical analysis; No tumor size was specified <i>(comment by the author, Anesi A.)</i>	No tumor size was specified in the paper; The mass did not overtake the normal gland boundaries So we can roughly infer that the mass did not exceed 20 mm and staging score could be pT1N0M0 <i>(comment by the author, Anesi A.)</i>	No tumor size was specified in the paper; The mass did not overtake the normal gland boundaries So we can roughly infer that the mass did not exceed 20 mm and staging score could be pT1aN0M0 <i>(comment by the author, Anesi A.)</i>
Anesi et al., 2019	M	59	Sudden blurring of vision and supraorbital swelling on the left eye; Visual acuity reduced from 8/20 to 1/50 in one week The patient had a proptosis of the left eye; A hard and tender mass was palpated in the superior temporal left orbit; The patient complained of mild double vision in left and down directions of the gaze, with a pathologic Hess-Lancaster test	CT: a 20×25 mm mass; well circumscribed, of ovoid shape, within the left lacrimal fossa; The tumor displaced medially the lateral rectus muscle; The mass did not appear well separable from the lacrimal gland and a slight scalloping of the great wing of the sphenoid was evident MR: an oval mass in the left lacrimal fossa, about 2 cm in diameter within the lacrimal gland; Tumor was heterogeneous, with mild and irregular enhancement following administration of contrast medium (gadolinium)	No incisional biopsy; Globe-sparing surgery; Coronal approach, lateral orbitotomy and entire lacrimal gland removal respecting the thin capsule No post-operative treatment; No recurrence after 7 years	Gross examination: nodular and brownish lesion, measuring about 20×15 mm; Histopathological examination: monomorphic epithelial tumor, composed of basophilic cells; Histopathological pattern: microcystic and focal papillary AcCC Melanin pigment deposition was occasionally revealed (Fig. 3b) Immunohistochemistry performed The mass appeared well-circumscribed, without involvement of the resection margins; a non-pathological portion of the lacrimal gland was identified (Fig. 3a); No evidence of vascular nor perineural invasion; Neither mitosis nor necrosis were observed Proliferation rate was 2–4 percent according to MIB-1 proliferation index	pT1N0M0	pT1aN0M0

The AJCC TNM staging score of both the seventh and eighth editions was reported [5, 23]. Tumor size, periosteal and bone invasion are separately staged in the AJCC Cancer Staging Manual, 8th Edition lacrimal gland carcinoma staging, for understanding how these factors correlate with survival for these malignancies. No stage groupings are currently recommended for lacrimal gland carcinomas. The authors of lacrimal gland carcinoma staging in AJCC Cancer Staging Manual, 8th Edition pointed out the frailty of this classification due to the lack of large studies [23]. In the five case reports of AcCC here discussed we can compare the staging score among seventh and eighth edition of AJCC staging system, and some observations can be made. A downgrading in T staging can be noticed in the case described by Jang [34] from T4b to T2c, respectively in seventh and eighth edition of the AJCC staging system. No significant changes in staging are detectable comparing the seventh and eighth edition of the AJCC staging system in reviewing the other 3 cases of AcCC of the literature and the case report here described. Focusing on surgical treatment for AcCC of the lacrimal gland, we can note that the tumor extent in the case reported by Rosenbaum [33] required an orbital exenteration because of globe and eyelid involvement. Orbital exenteration is related to high morbidity, but according to the seventh and eighth edition of the AJCC staging system, T number (T2) in Rosenbaum's case [33] is analogue to T scoring in De Rosa's case [32], in Bannister and Lawson's case [35], and in the case here presented, in all of which orbital sparing surgery was successfully used and not orbital exenteration. In conclusion, the correlation between high T score and wide surgical excision (exenteration orbitae) is not strong for AcCC and for other low grade carcinomas of the lacrimal gland, in both last two editions of the AJCC staging system manual lacrimal gland carcinoma staging system.