



Association between precuneus volume and autobiographical memory impairment in posterior cortical atrophy: Beyond the visual syndrome

Samrah Ahmed^{a,*,1}, Muireann Irish^{b,c,1}, Clare Loane^a, Ian Baker^d, Masud Husain^{a,e}, Sian Thompson^f, Cristina Blanco-Duque^g, Clare Mackay^h, Giovanna Zamboni^a, David Foxe^b, John R. Hodges^{c,i}, Olivier Piguet^{b,c}, Christopher Butler^a

^a Nuffield Department of Clinical Neurosciences, University of Oxford, John Radcliffe Hospital, Oxford, UK

^b The University of Sydney, School of Psychology and Brain & Mind Centre, Sydney, Australia

^c Australian Research Council Centre of Excellence in Cognition and its Disorders, Sydney, Australia

^d Russell Cairns Unit, Oxford University Hospitals NHS Trust, John Radcliffe Hospital, Oxford, UK

^e Department of Experimental Psychology, University of Oxford, John Radcliffe Hospital, Oxford, UK

^f Department of Clinical Neurology, Oxford University Hospitals NHS Trust, Oxford, UK

^g Department of Physiology, Anatomy and Genetics, University of Oxford, Oxford, UK

^h Department of Psychiatry, University of Oxford, Oxford, UK

ⁱ The University of Sydney, Clinical Medical School and Brain & Mind Centre, Sydney, Australia

ARTICLE INFO

Keywords:

Posterior cortical atrophy
Autobiographical memory
Visual imagery
Alzheimer's disease

ABSTRACT

Posterior cortical atrophy is a neurodegenerative syndrome characterised by progressive disruption of visual and perceptual processing, associated with atrophy in the parieto-occipital cortex. Current diagnostic criteria describe relative sparing of episodic memory function, but recent findings suggest that anterograde memory is often impaired. Whether these deficits extend to remote memory has not been addressed. A large body of evidence suggests that the recollection of an autobiographical event from the remote past coincides with the successful retrieval of visual images. We hypothesised that the profound visual processing deficits in posterior cortical atrophy would result in impaired autobiographical memory retrieval. Fourteen posterior cortical atrophy patients, eighteen typical Alzheimer's disease patients and twenty-eight healthy controls completed the Autobiographical Interview. Autobiographical memory in posterior cortical atrophy was characterised by a striking loss of internal, episodic detail relative to controls and to same extent as typical Alzheimer's disease patients, in conjunction with an increase in external details tangential to the memory described. The memory narratives of posterior cortical atrophy patients showed a specific reduction in spatiotemporal and perceptual detail. Voxel-based morphometry analysis revealed atrophy of the parieto-occipital cortices in posterior cortical atrophy but relatively spared hippocampi bilaterally, compared with characteristic atrophy of the medial temporal lobes in typical Alzheimer's disease. Analysis of brain regions showing posterior cortical atrophy-specific atrophy revealed a correlation between perceptual details in autobiographical memory and grey matter density in the right precuneus. This study demonstrates remote memory impairment in posterior cortical atrophy despite relatively preserved medial temporal lobe structures. The results demonstrate, for the first time, profound autobiographical memory impairment in PCA and suggest that this is driven by the well-recognised deficits in higher-order visual processing. The findings are discussed in the context of posterior parietal contributions to imagery and memory, and the clinical implications of autobiographical memory impairment for diagnostic and management protocols in posterior cortical atrophy.

1. Introduction

Posterior cortical atrophy (PCA) is a clinical syndrome characterised by progressive impairment of visuospatial and visuo-perceptual function

that is not attributable to ocular disease (McMonagle et al., 2006; Tang-Wai et al., 2004). Prominent visual impairment in object and space perception is often accompanied by other neuropsychological features of posterior cortical dysfunction such as alexia, agraphia, acalculia,

* Corresponding author at: Nuffield Department of Clinical Neurosciences, University of Oxford, John Radcliffe Hospital, Oxford, OX3 9DU Oxford, UK.

E-mail address: Samrah.ahmed@ndcn.ox.ac.uk (S. Ahmed).

¹ These authors contributed equally to the work.

apraxia (Ahmed et al., 2016b) and elements of Balint's syndrome (simultanagnosia, ocular ataxia and oculomotor apraxia). PCA is typically an early onset dementia, with symptoms beginning in the fifth or sixth decade of life. The most common underlying cause is Alzheimer's pathology (Renner et al., 2004). Cerebral atrophy in PCA is centred on the parieto-occipital and temporo-occipital cortices, a pattern that contrasts with the early medial temporal lobe involvement seen in typical Alzheimer's disease (tAD) (Kas et al., 2011; Whitwell et al., 2007).

Episodic memory is considered to be relatively preserved in PCA (McMonagle et al., 2006; Migliaccio et al., 2009). However, when directly probed, PCA patients frequently describe deficits in everyday memory function (Migliaccio et al., 2009; Shakespeare et al., 2015b). Most recently, Ahmed et al. (2016a) showed that encoding and retrieval of new verbal information, measured using a standardised screening tool, was impaired in two thirds of PCA patients tested. Importantly, these patients were examined relatively early in the disease course, with an average symptom duration of twenty-four months.

Far less is known regarding the status of remote memory in PCA. It is unclear if the recollection of autobiographical events is impaired to the same extent as new learning and, if so, what the underlying cause of the impairment is. Autobiographical memory (ABM) encompasses memories for the specific, personal events of one's life (Conway and Rubin, 1993), requiring the retrieval of rich contextual details (Conway and Pleydell-Pearce, 2000), emotional connotations (Piefke et al., 2003), and general conceptual knowledge (Irish and Piguet, 2013), all bound within a unique spatiotemporal framework (Piolino et al., 2009). Functional neuroimaging studies of healthy individuals have described a distributed “core” memory network for ABM retrieval, comprising frontal and medial temporal regions, lateral temporal and sensory association cortices, as well as posterior parietal and occipital regions (Cabeza and St Jacques, 2007; Rissman et al., 2016; Svoboda et al., 2006). Despite the distributed nature of the ABM core network, research efforts have placed disproportionate emphasis on the contributions of the medial temporal lobe (MTL) and prefrontal regions. It is generally held that ABM recall leads to increased activation across multiple regions of sensory and association cortex, which process the experienced visual, auditory and somatosensory stimuli associated with the event. The MTL then binds together information in these disparate brain regions to form a coherent, associative memory trace (Squire, 1992).

ABMs are instilled with rich sensory-perceptual details, many of which are visual (Greenberg and Knowlton, 2014). The fundamental role of mental imagery in ABM retrieval has long been acknowledged, from Aristotle's assertion that images form the basis of thought (Aristotle, c.350 BC.), to modern neuroscientific examination (e.g. (Kosslyn et al., 2001; Luria, 1987; Rubin and Greenberg, 1998)). The experience of recollecting an autobiographical event from the remote past coincides with the successful retrieval of visual images (Brewer, 1996; Rubin, 2006). Activation of the visual cortex during ABM retrieval is proposed to drive activity in other sensory association cortices, to produce a cascade of activation similar to that present during the original experience (Rubin, 2006). By this view, damage to posterior neocortical sites that store visual information should give rise to global impairments in ABM, extending far beyond the loss of visual memories alone. Moreover, in contrast to the pattern often reported after MTL damage, there should be no ‘temporal gradient’ in ABM since the imagery deficit would affect memories from all time periods equally. Neuropsychological studies corroborate this proposal (Greenberg et al., 2005; Ogden, 1993a; Rubin, 2006). Rubin and Greenberg (1998) reviewed eleven cases from the literature in which damage to visual cortex was accompanied by anterograde and severe retrograde amnesia, with no sparing of early memories. The authors interpreted these findings as a ‘visual memory-deficit amnesia’ primarily driven by lack of visual input to memory.

Given the characteristic posterior neocortical atrophy and relatively spared MTL region in early stages of PCA (Kas et al., 2011), the status of

ABM in this disease is of particular interest, affording a unique opportunity to explore the role of the posterior neocortex in ABM retrieval. Moreover, from a clinical perspective, improved understanding of the profile and mechanisms of memory dysfunction in PCA may aid the early recognition and diagnosis of this relatively rare syndrome, with implications for management and intervention.

To our knowledge, only one previous case study has examined ABM in PCA. Thompson et al. (2003) administered the Autobiographical Memory Interview (Kopelman et al., 1989) to a PCA patient, BB, who showed impairment compared with healthy controls on retrieval of both autobiographical incidents and personal semantic facts, but performance was significantly higher than in tAD patients. The mechanisms of this impairment remain unexplored. The visuo-spatial and perceptual deficits in PCA reflect damage to the dorsal occipito-parietal and the ventral occipito-temporal visual streams (Gardini et al., 2011; Migliaccio et al., 2016). These pathways contain the primary and associative visual areas, and the latter in particular has been shown to be involved in the retrieval of remote memories, as well as in visual imagery processes (Gardini et al., 2011). Only one case study has examined visual imagery in PCA in detail, revealing impairment in the ability to generate mental images of objects and scenes (Gardini et al., 2011). It is plausible to postulate then, that the characteristic profile of neurodegeneration in PCA would impair ABM as a function of disrupted visual imagery.

This study examined the features and neuroanatomical substrates of ABM in PCA. We hypothesised, first, that PCA patients would show impairment in ABM retrieval, with a specific absence of visuo-perceptual detail from memory narratives. Secondly, we hypothesised that the degree of ABM impairment in PCA would correlate with performance on visual imagery tests. Thirdly, we expected to see a global impairment of ABM retrieval, irrespective of time period. Finally, we predicted that ABM deficits would correlate with posterior neocortical, but not medial temporal lobe, atrophy.

2. Material and methods

2.1. Participants

Fourteen PCA patients were recruited through the Oxford Cognitive Disorders Clinic, Oxford, UK. Diagnosis was established by a senior behavioural neurologist (CRB, ST or MH) and neuropsychologists (IB and SA). All patients fulfilled consensus criteria for PCA, based upon clinical assessment, brain imaging and detailed neuropsychological assessment. Briefly, PCA patients displayed any of the core features of simultanagnosia with or without optic ataxia or ocular apraxia, constructional apraxia, visual field defect, elements of Gerstmann's syndrome or environmental disorientation, with any of the supportive features of alexia, ideomotor or dressing apraxia, or prosopagnosia (McMonagle et al., 2006; Tang-Wai et al., 2004). Clinical magnetic resonance imaging (MRI) confirmed focal atrophy in the occipital and parietal lobes.

PCA patients were compared with twenty-eight healthy controls and eighteen tAD patients. tAD patients and healthy controls were recruited from FRONTIER research group at Neuroscience Research Australia, and from local community clubs. Healthy control participants were defined as having no objective cognitive impairment on neuropsychological screening tests (scored between 27 and 30 on the Mini-Mental State Examination (Folstein et al., 1975), 0 on the Clinical Dementia Rating scale (Morris, 1997), and 85 or above on the Addenbrooke's Cognitive Examination-Revised (Mioshi et al., 2006). Controls had no prior history of psychiatric illness, significant head injury, or cerebrovascular disease, and were not prescribed any medication known to affect cognition. tAD patients fulfilled consensus criteria, based upon clinical assessment conducted by a senior behavioural neurologist (JRH), detailed neuropsychological assessment, and structural brain imaging. tAD patients showed marked impairment in episodic memory,

Table 1
Demographic and clinical characteristics of control and patient groups. Standard deviation given in brackets. Total scores achievable on neuropsychological tests, where applicable, in brackets in right column. Values in bold indicate significant group differences.

	Controls	tAD	PCA	Controls vs. tAD	Controls vs. PCA	PCA vs. tAD
Demographics						
<i>n</i>	28	18	14			
Age (years)	69.5 (5.7)	66.9 (8.7)	64.9 (7.7)	0.550	0.151	0.815
Education (years)	11.8 (3.3)	12.8 (3.4)	13.9 (2.4)	0.644	0.122	0.686
Gender (m:f)	8:20	14:4	7:7	0.001	0.172	0.101
Symptom duration (years)	–	2.9 (2.1)	4.0 (2.2)	–	–	0.170
DASS ^a depression scale (normal range 0–9)	1.8 (2.4)	4.5 (4.2)	6.3 (10.3)	0.343	0.069	0.804
DASS anxiety scale (normal range 0–7)	1.2 (1.8)	2.9 (2.9)	3.8 (3.4)	0.122	0.012	0.709
DASS stress scale (normal range 0–14)	3.2 (3.2)	4.9 (5.0)	5.9 (5.6)	0.551	0.215	0.904
Neuropsychological profile						
Memory						
RAVLT immediate recall (15)	10.0 (3.0)	3.1 (2.9)	5.2 (3.0)	0.000	0.000	0.180
RAVLT delayed recall (15)	10.0 (2.7)	2.5 (2.8)	4.3 (4.2)	0.000	0.000	0.361
RAVLT correct recognition (15)	13.7 (1.4)	9.6 (4.5)	13.4 (1.6)	0.000	0.988	0.001
RAVLT false positives (35)	2.5 (2.5)	7.7 (7.4)	10.6 (7.6)	0.017	0.000	0.401
Rey immediate recall (18)	14.7 (5.6)	4.0 (4.3)	0.78 (1.1)	0.000	0.000	0.293
Language						
Pyramids and Palm Trees ^a (52)	51.2 (0.87)	47.9 (2.5)	48.8 (3.0)	0.016	0.056	0.792
Category fluency ^a	18.6 (4.0)	11.1 (5.0)	10.3 (6.8)	0.000	0.000	0.961
Executive function						
FAS ^a	44.4 (12.3)	31.0 (13.5)	33.8 (17.2)	0.008	0.078	0.925
Hayling sentence completion ^a (7)	5.4 (1.0)	4.1 (1.4)	3.8 (1.4)	0.003	0.000	0.836
Hayling response inhibition (7)	5.8 (0.67)	4.4 (2.0)	3.5 (2.1)	0.013	0.000	0.344
Attention						
Digit span forwards and backwards (32)	18.8 (4.2)	14.6 (4.0)	14.4 (3.9)	0.004	0.005	0.997
Visuospatial function						
VOSP dot counting ^a (10)	9.8 (0.57)	9.6 (0.63)	4.5 (3.7)	0.990	0.000	0.000
VOSP position discrimination ^a (20)	19.6 (0.89)	19.4 (1.3)	14.1 (3.9)	0.997	0.000	0.000
VOSP cube analysis (10)	9.1 (0.96)	7.9 (2.8)	2.0 (2.5)	0.354	0.000	0.000
Rey-Osterrieth complex figure copy ^a (18)	30.4 (3.0)	29.3 (5.8)	2.0 (3.4)	0.753	0.000	0.000
Visual imagery						
Demographics						
<i>n</i>	28	–	14			
Age (years)	63.2 (6.0)	–	64.9 (7.7)	–	0.443	–
Education (years)	15.5 (2.6)	–	13.9 (2.4)	–	0.070	–
Gender (m:f)	12:16	–	7:7	–	0.661	–

Table 1 (continued)

	Controls	tAD	PCA	Controls vs. tAD	Controls vs. PCA	PCA vs. tAD
Symptom duration (years)	–	–	4.0 (2.2)	–	–	–
Spatial imagery						
Spatial relations: categorical (12)	11.4 (0.85)	–	9.0 (2.0)	–	0.001	–
Spatial relations: metric (12)	10.7 (1.1)	–	8.6 (2.3)	–	0.004	–
Spatial relations: total (24)	22.1 (1.5)	–	17.6 (3.4)	–	0.000	–
Non-spatial imagery						
Animal imagery (20)	17.6 (1.2)	–	15.6 (1.7)	–	0.000	–
Letter imagery (20)	19.4 (0.8)	–	16.5 (3.0)	–	0.004	–

Abbreviations: DASS Depression anxiety stress scale; PCA Posterior cortical atrophy; RAVLT Rey auditory verbal learning task; tAD typical Alzheimer's disease; VOSP Visual object and space perception.

^a Missing data: Data was missing for some tests due to the test not being administered at the time of data collection in controls and ADs, or due to refusal to continue in AD and PCA patients. Reduced sample sizes were present for: Rey fig. (AD *n* = 16; PCA *n* = 9), RAVLT (AD *n* = 15), PPT (NC *n* = 1; AD *n* = 8; PCA *n* = 13), FAS (AD *n* = 17; PCA *n* = 13, Hayling AD *n* = 17), VOSP cube analysis (NC *n* = 16; AD *n* = 13; PCA *n* = 11), VOSP dot counting (NC *n* = 18), VOSP position discrimination (NC *n* = 16; PCA *n* = 9), Category fluency (PCA *n* = 13), DASS (PCA *n* = 11).

with relatively preserved behaviour and personality, and characteristic bilateral medial temporal, with other more general atrophy (McKhann et al., 1984; McKhann et al., 2011). All patients and controls were fully proficient in English.

All groups were comparable for age and years of education (Table 1). PCA and tAD patients were comparable for symptom duration, i.e. time since the first symptom was noticed. Sex was not evenly distributed ($\chi^2(2) = 10.64, p = 0.005$) due to a greater number of females in the control group. Neither PCA nor tAD patients demonstrated evidence of depressed mood (normal range 0–9) or elevated stress levels (normal range 0–14) as assessed by the Depression Anxiety Stress Scale (DASS; (Lovibond and Lovibond, 1995)). PCA patients did show significantly raised anxiety levels compared to controls, however the group average (3.8) was still well within the normal range (0–7).

An independent sample of comparable healthy controls recruited in Oxford, UK (see Table 1) was used to compare visual imagery scores with the PCA group, as the control and tAD groups from Australia had not been administered these tests.

Imaging analysis was conducted in an independent group of tAD and control patients. Behavioural data were not available in any of these patients due to the earlier acquisition of this data under a different research protocol. Eleven tAD patients and thirty-two healthy controls were diagnosed as above, recruited from the Oxford Project to Investigate Memory and Aging and the Memory and Amnesia Project, University of Oxford, UK (described fully in (Zamboni et al., 2013)). tAD, PCA and controls were comparable for age (tAD: mean = 69.4 years, SD = 6.0; PCA: mean = 63.7 years, SD = 7.2; controls: mean = 64.7 years, SD = 7.4; $p = 0.12$) and education (tAD: mean = 13.3 years, SD = 6.0; PCA: mean = 14.1 years, SD = 2.2; controls: mean = 14.5 years, SD = 3.5; $p = 0.59$). There was no significant difference in symptom duration between tAD and PCA patients (tAD: mean = 45.4 months, SD = 33.9; PCA: mean = 49.0 months, SD = 29.0; $p = 0.80$).

The study was approved by the National Research Ethics Service South Central - Hampshire B and Oxford C and the South Eastern Sydney Local Health District and the University of New South Wales human ethics committees. All participants provided written informed consent in accordance with the Declaration of Helsinki.

2.2. Assessment of autobiographical memory

Autobiographical memory was examined using a shortened version of the Autobiographical Interview (AI; (Levine et al., 2002)). This instrument has been employed previously in dementia cohorts (Irish et al., 2011a; McKinnon et al., 2006) and permits the segmentation of episodic from semantic details across life epochs. Briefly, participants were asked to provide a detailed description of a personally experienced event that occurred at a specific time and place from four different life epochs: Teenage Years (11–17 years), Early Adulthood (18–35 years), Middle Adulthood (36–55 years) and Recent Time (within the last year). The Early Childhood epoch (up to age 11) was omitted to shorten the test session and reduce the burden of testing on patients.

The AI was administered according to the standardised protocol. If participants were unable to retrieve an event independently, a list of typical events for each epoch was presented (see (Levine et al., 2002) for a full description). The test session proceeded with participants speaking extemporaneously about the event in question (free recall), following which general probes were used to encourage greater recall of details. Finally, specific probes targeting five discrete categories were provided (Event, Time, Place, Perceptual, and Emotion/Thoughts). The specific probe condition was administered after all events were retrieved via the free recall and general probe conditions, ensuring that the specific probe process did not contaminate the recall of subsequent memories.

All interviews were recorded and transcribed. The AI scoring protocol requires the segmentation of each retrieved memory into informational details, defined as a unique occurrence, observation or thought, typically expressed as a grammatical clause. Each detail was classified as “internal” or “external”. Internal details directly related to the main episode being described and were located within a specific spatiotemporal context, conveying a sense of episodic re-experiencing. These details were then assigned to one of five separate categories (Event, Time, Place, Perceptual and Emotion/Thoughts). Otherwise, details were labeled as external if they consisted of autobiographical events tangential or unrelated to the main event, semantic facts, repetitions, or metacognitive statements. Details from each category were summed to form internal and external composite scores. Because the effect of general probing on general performance is minimal in comparison to that of specific probing (Levine et al., 2002), free recall and general probing scores were combined, resulting in two composite scores for each epoch: (i) low retrieval support (free recall + general probe), referred to here as “free recall”, and (ii) high retrieval support condition (total score following probing), referred to here as “probed recall”. (Representative excerpts of ABM transcripts provided in Appendix A).

A ratio of internal-to-total details was calculated to provide a measure of the proportion of details per memory from the total number of details produced, representing a proxy measure for episodic re-experiencing in autobiographical recall (Levine et al., 2002; Murphy et al., 2008). The ratio was calculated by the formula: total internal details / (total internal details + total external details). The ratio provides information about the proportion of the narrative that can be taken to reflect “episodic richness” (Levine et al., 2002) of ABMs, taking into account all other details generated, particularly extemporaneous information produced (external details), and therefore unbiased by the total verbal output.

Inter-rater reliability of scoring across sites was examined using a two way random effects model. Raters in Oxford and Sydney each scored nineteen randomly selected narratives, produced by controls, tAD and PCA patients. Both raters were blinded to group membership. The following intraclass correlation coefficients were achieved, reflecting strong reliability across categories: Internal free recall: 0.88, Internal probed recall: 0.95, External free recall: 0.92, External probed recall: 0.83.

2.3. Background neuropsychological tests

Standardised neuropsychological tests was administered to evaluate patient and control function in five domains: *Memory*, assessed using the Rey Auditory Verbal Learning Test (RAVLT; (Rey, 1964); *language*, assessed using the word version of the Pyramids and Palm Trees (PPT; (Howard and Patterson, 1992)) and category fluency (Morris et al., 1989), *executive function*, measured using the FAS letter fluency task (Benton and Hamsher, 1976), and the Hayling sentence completion test (Burgess and Shallice, 1996), *attention*, assessed using digit span forwards and backwards (Wechsler, 2014); and finally, *visuospatial function*, measured using three tests from the Visual Object and Space Perception (VOSP; (Warrington and James, 1991) battery (dot counting, position discrimination and cube analysis), and the Rey-Osterrieth Complex figure (Rey, 1941).

2.4. Experimental visual imagery tests

2.4.1. Spatial imagery

The Spatial Relations Test (adapted from (Kosslyn, 1987; Policardi et al., 1996)) comprises metric questions, assessing access to knowledge of the salient parts of an object (e.g. is an iron wider in front or behind?), and categorical questions, probing knowledge of the spatial relationships between parts (e.g. is a bicycle saddle located above or below the pedals?).

2.4.2. Non-spatial visual imagery

In the Letter Shape Test (Farah, 1985) participants imagine the uppercase version of twenty letters, and determine if the letter consists of straight lines (e.g. L), curved lines (e.g. O) or both (e.g. G). In the Tail Judgement Test (Farah, 1988) participants determine if a list of twenty animals has a long or short tail in relation to its body size.

2.5. Voxel-based morphometry

2.5.1. Whole brain analyses

Structural data were analysed with an optimised protocol of the FSL-Voxel Based Morphometry (VBM) processing stream (Douaud et al., 2007). In brief, images were brain extracted using the brain extraction tool (BET) (Smith, 2002) prior to tissue segmentation using the FMRIB Automatic Segmentation Tool (FAST). Images were non-linearly registered to standard space and an average study-specific template was created. All images were then non-linearly aligned to the study-specific template and modulated for correction of local field expansion or contraction by dividing the Jacobian of the warp field. Modulated images were then smoothed with an isotropic kernel with a sigma of 3 mm. Finally, voxel-wise statistics were employed using a general linear model with non-parametric permutation testing (Winkler et al., 2014) and 5000 permutations per contrast. To investigate differences in cortical grey-matter between patients and controls, regression models were applied with separate directional contrasts (i.e. *t*-tests). Results were defined as significant at $p < 0.05$ corrected for multiple comparisons using the Threshold-Free Cluster Enhancement (TFCE) approach (Smith and Nichols, 2009) carried out in Randomise with 5000 permutations per contrast. Correlations between performance on internal-to-total-ratio, total probed internal details, total probed external detail, and grey matter intensity within the PCA patient group were also investigated using the TFCE approach in Randomise with 5000 permutations per contrast and significance defined as $p < 0.05$. Age and sex were included as covariates in all analyses.

2.5.2. Region of interest analyses

A subsequent analysis was conducted to investigate anatomical correlates of total spatiotemporal and perceptual details, interrogating only those regions in which atrophy was specific to PCA patients. Within-group effects were investigated using a binary mask of the

PCA < tAD grey matter density differences from the VBM output. In addition, a mask of the hippocampus was used to determine the specificity of any effect, we have previously shown that hippocampal integrity correlated with the retrieval of recent and remote ABMs in tAD {Irish, 2014 #337}. A binary mask of the bilateral hippocampi was taken from the Harvard-Oxford cortical structural atlas. Correlations were performed between grey-matter density within these masks and performance on total spatiotemporal and perceptual details using the TFCE approach in Randomise with 5000 permutations per contrast and significance defined as $p < 0.05$. Age and sex were included as covariates in all analyses.

2.6. Statistical analysis

Normality of distribution of the data was examined using Shapiro-Wilk tests. Group differences in demographic, clinical, and cognitive characteristics were examined using one-way analysis of variance with Sidak post hoc tests or independent samples t -tests. Chi-squared tests based on the frequency patterns of dichotomous variables, were used to examine sex differences. AI metrics were examined using Kruskal-Wallis nonparametric tests, with pairwise comparisons performed using Mann-Whitney tests. Spearman's rank correlation coefficient was used to explore relationships between AI metrics and neuropsychological variables. Bonferroni correction was applied for multiple comparisons. Two-tailed tests were conducted with alpha level set at 0.05.

3. Results

3.1. Neuropsychological profile

Neuropsychological assessment revealed characteristic cognitive profiles in each patient group (Table 1). PCA patients were impaired on all tests of visuospatial function, episodic memory and attention relative to control participants. Variable deficits were evident on tests of executive function and language consistent with previous literature documenting cognitive impairment in domains beyond the defining visuospatial impairment {Ahmed et al., 2016b #264; Crutch et al., 2013 #202; Crutch et al., 2017 #344; McMonagle et al., 2006 #170} tAD patients were impaired compared to controls on all tests of episodic memory, language, attention and executive function, but not on visuospatial function. PCA patients performed significantly worse than tAD on all tests of visuospatial function, in accordance with the phenotypic deficits in this group. Performance in other cognitive domains was comparable.

3.2. Overall performance on the AI

3.2.1. Internal vs. external details

Both patient groups showed significantly poorer retrieval of internal details, relative to controls in both the free (tAD $p = 0.001$; PCA $p = 0.001$) and probed conditions (tAD $p = 0.000$; PCA $p = 0.000$), with no significant differences between PCA and tAD (free $p = 0.237$; probed $p = 0.464$) (Fig. 1). External detail production was significantly higher in the PCA group compared to controls in the free ($p = 0.003$) and probed ($p = 0.000$) conditions, and compared to tAD in the probed condition ($p = 0.006$). In contrast, tAD patients did not differ significantly from controls for external detail production (free $p = 0.260$; probed $p = 0.327$).

Within group comparisons showed that controls produced a significantly greater number of internal details compared to external details in the probed condition ($p = 0.000$). Conversely, PCA patients produced a significantly greater number of external details compared to internal details in the free ($p = 0.003$), and probed ($p = 0.004$) conditions. tAD patients showed the same pattern in the free condition ($p = 0.001$) only, suggesting that high retrieval support conferred the ability to constrain narratives to internal details in tAD only, with no

such benefit for PCA patients.

To explore the effect of uneven distribution of sex in the control and tAD group, a t -test was computed between males and females for internal and external detail scores. There were no significant differences between sex groups in the tAD patients. However, females in the control group did produce significantly more external details in total after probed recall ($p = 0.009$). Several studies have shown that females recall longer and more detailed ABMs compared to males (e.g. (Pillemer et al., 2003; Pohl et al., 2005; St Jacques et al., 2011)), suggested to reflect natural sex differences in episodic memory retrieval (St Jacques et al., 2011). Importantly, the sex difference does not affect internal details, or analyses within the PCA patients as the main group of interest here.

3.2.2. Internal-to-total ratio

The internal-to-total ratio was significantly lower in PCA ($p = 0.000$) and tAD ($p = 0.002$) patients compared to controls, and significantly lower in PCA patients than tAD ($p = 0.000$) (Fig. 2).

3.3. ABM retrieval across life epochs

In the subsequent analyses, the overall pattern of results was similar in the free recall and probed recall conditions, therefore only data pertaining to the probed condition are reported (in accordance with previous studies (Irish et al., 2011a; Levine et al., 2002)).

3.3.1. Probed recall of internal details across life epochs

Compared to controls, PCA and tAD recalled significantly fewer internal details following structured probing in early adulthood (PCA $p = 0.002$; tAD $p = 0.002$), middle adulthood (PCA $p = 0.008$; tAD $p = 0.001$) and in recent years (PCA $p = 0.001$; tAD $p = 0.001$). (Fig. 3a). There were no significant differences between PCA and tAD in any epoch (all p values > 0.01). Interestingly, PCA patients produced numerically fewer details compared to tAD patients across the majority of the lifespan, but particularly in the most remote teenage epoch and recent epoch.

Within group comparisons across life epochs showed that controls recalled significantly more recent probed internal details compared to the teenage epoch ($p = 0.007$), indicative of a recency effect, commonly observed in healthy adults (Irish et al., 2011b; Kopelman et al., 1989; Levine et al., 2002). A recency effect was not observed in PCA or tAD.

3.3.2. Probed recall of external details across life epochs

There were no significant differences between controls and tAD on probed recall of external detail across the lifespan (all p values > 0.01) (Fig. 3b). In contrast, PCA patients produced significantly greater amounts of external detail compared to controls across the lifespan (teenage $p = 0.002$; early adulthood $p = 0.003$; middle adulthood $p = 0.011$; recent $p = 0.000$), and in the recent epoch compared to tAD ($p = 0.002$). A similar pattern of results was also evident in the remote epochs, but these differences did not survive Bonferroni correction ($p = 0.034$ – 0.082 ; $p > 0.01$). Within group comparisons revealed no significant differences between epochs in any group.

3.3.3. Internal-to-total ratio across life epochs

Compared to controls, PCA patients showed a significantly reduced internal-to-total ratio across the lifespan (teenage years, $p = 0.001$; early adulthood $p = 0.000$; middle adulthood $p = 0.001$; recent years $p = 0.000$). tAD patients were also impaired compared to controls in early adulthood ($p = 0.003$), middle adulthood ($p = 0.008$) and recent years ($p = 0.010$), but not in the teenage years ($p = 0.026$). Comparing the two patient groups, tAD patients had a significantly higher internal-to-total ratio in the recent epoch only ($p = 0.000$) (Fig. 3c).

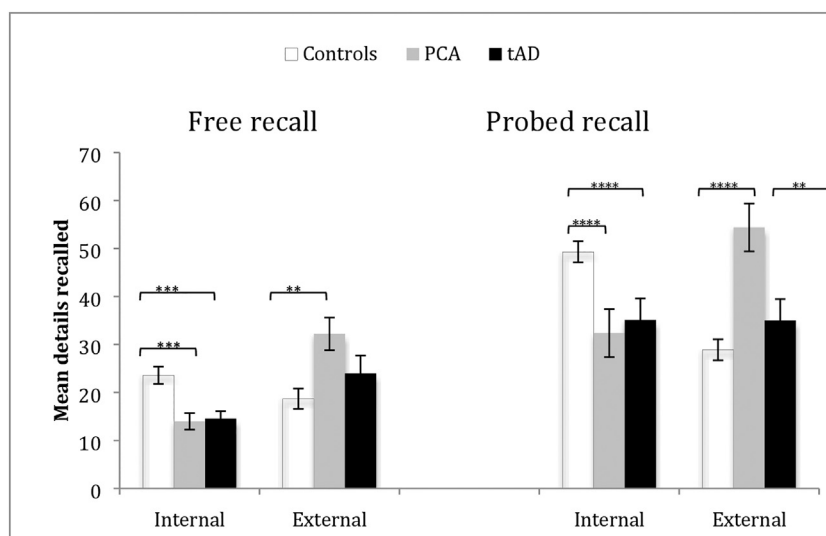


Fig. 1. Total scores for internal and external details, summed across all time period, for free and probed retrieval conditions. Error bars represent standard error of mean. (**p < 0.01; ***p < 0.001; ****p < 0.0001).

Abbreviations: PCA Posterior cortical atrophy; tAD typical Alzheimer's disease.

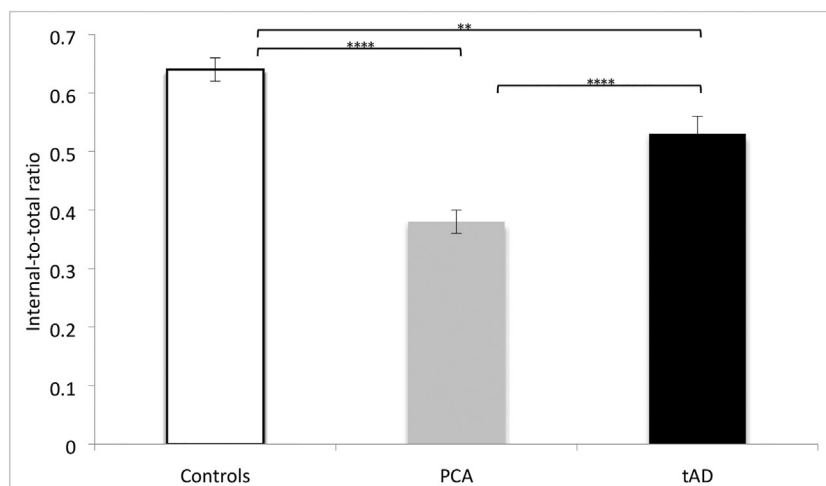


Fig. 2. The ratio of internal-to-total details produced by each group. Error bars represent the standard error of the mean. (**p < 0.01; ****p < 0.0001).

Abbreviations: PCA Posterior cortical atrophy; tAD typical Alzheimer's disease.

3.4. Retrieval of contextual details

To determine whether impairments in ABM reflect the differential disruption of specific details in each patient group, group differences in subcategories of contextual detail were considered. In keeping with previous studies, place and time categories were aggregated into a “spatiotemporal details” category because of the limited range of possible details compared to the other categories (Irish et al., 2011a). Retrieval scores are expressed as averages across life epochs.

Probed recall of Internal contextual details. PCA patients produced significantly fewer spatiotemporal details (p = 0.000) and perceptual details (p = 0.000) overall, compared to controls (Fig. 4a). PCA patients produced significantly fewer spatiotemporal details compared to tAD (p = 0.001). In contrast, tAD patients generated significantly fewer event details (p = 0.000) compared to controls.

3.4.1. Probed recall of external contextual details

PCA patients produced significantly more external details across all categories compared to controls (event p = 0.002; semantic p = 0.004; repetitions p = 0.000; other p = 0.000). PCA patients also produced significantly more external events (p = 0.014) and other details

(p = 0.000) compared to tAD. There were no significant differences between controls and tAD patients on any category (all p values > 0.01)(Fig. 4b).

3.5. Relationship of ABM with visual imagery and other cognitive domains

Spearman's correlations were computed between total internal and external details and internal-to-total details ratio, and categories of impaired contextual detail in tAD (events) and PCA patients (spatiotemporal, perceptual), with (i) performance on tests of visual imagery; and (ii) memory, language and attention and executive function (see Table 1 for list of tests).

3.5.1. Visual imagery

PCA patients were significantly impaired compared to controls on both spatial and non-spatial imagery tests (see Table 1), suggesting a global visual imagery deficit. No correlations were identified in PCA patients or healthy controls.

3.5.2. Other cognitive domains

There were no significant correlations with internal details or

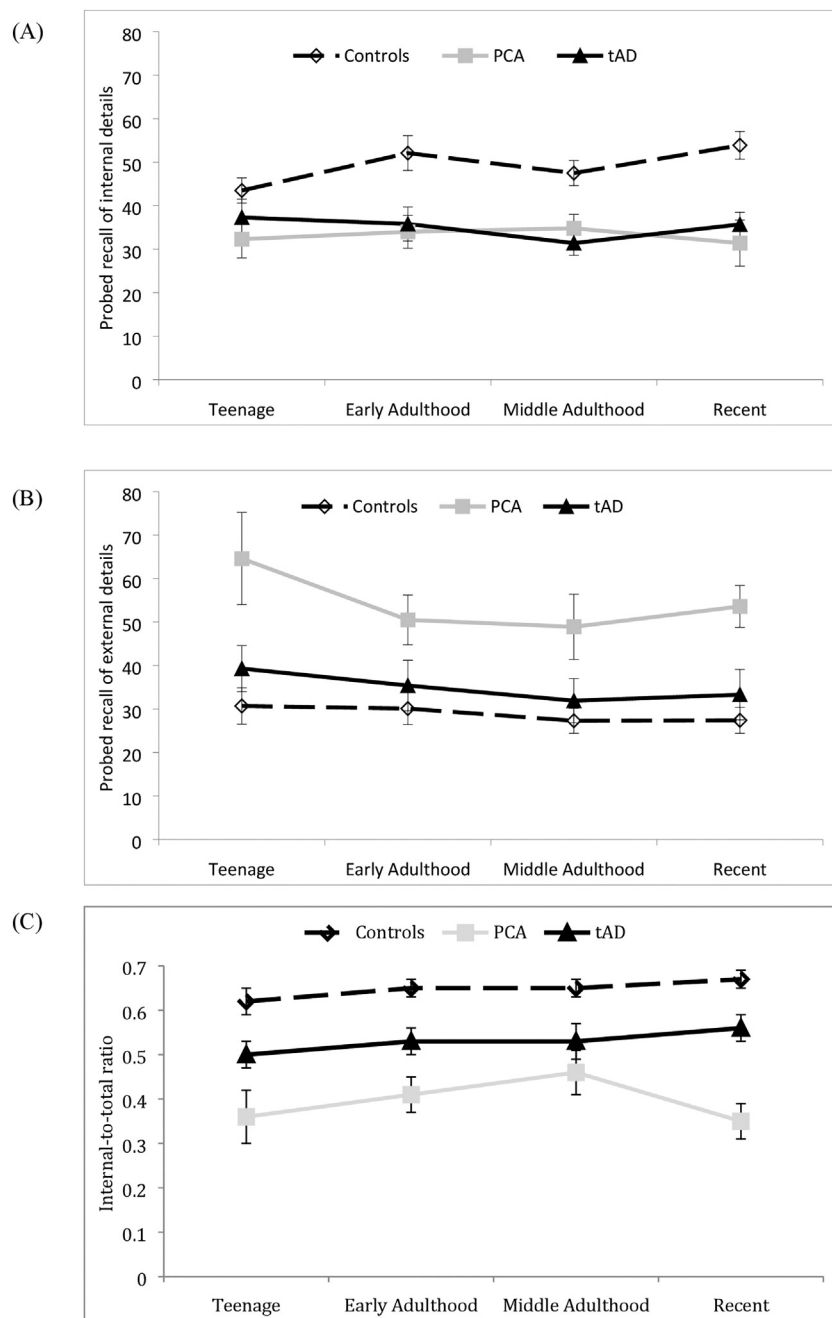


Fig. 3. Profile of probed recall of (A) internal details; (B) external details; and (C) internal-to-total ratio across life epochs. Error bars represent standard error of mean. Abbreviations: PCA Posterior cortical atrophy; tAD typical Alzheimer's disease.

internal-to-total ratio in PCA. A significant negative correlation between total external details and Hayling response inhibition was found ($p < 0.01$) in PCA. Finally, there was a significant positive correlation between perceptual details and delayed recall on the RAVLT ($p < 0.01$) in PCA patients.

In tAD patients there was a significant positive correlation between total internal details and category fluency ($p < 0.01$) and letter fluency ($p < 0.01$), and a significant negative correlation between internal-to-total ratio and Hayling sentence completion ($p < 0.01$). Total external details correlated with category fluency ($p < 0.01$).

No significant correlations were found between any of the neuropsychological measures and AI metrics in the controls.

3.6. Voxel-based morphometry

3.6.1. Whole brain analyses

VBM analysis revealed significant decreases in grey matter density in both patient groups relative to controls (Fig. 5). Relative to controls, PCA patients showed characteristic pronounced bilateral changes in the lateral occipital cortex, and in lateral and medial parietal regions (Table 2). Medial temporal regions were largely spared except for grey matter density reduction in the parahippocampal gyrus bilaterally. Critically, there was no significant decrease in hippocampal grey matter density. The pattern of atrophy observed is consistent with previous reports in the literature (Kas et al., 2011).

tAD patients showed significant widespread decreases in grey matter density, relative to controls, in the medial temporal lobe, extending to frontal regions. Posterior regions of the brain showed

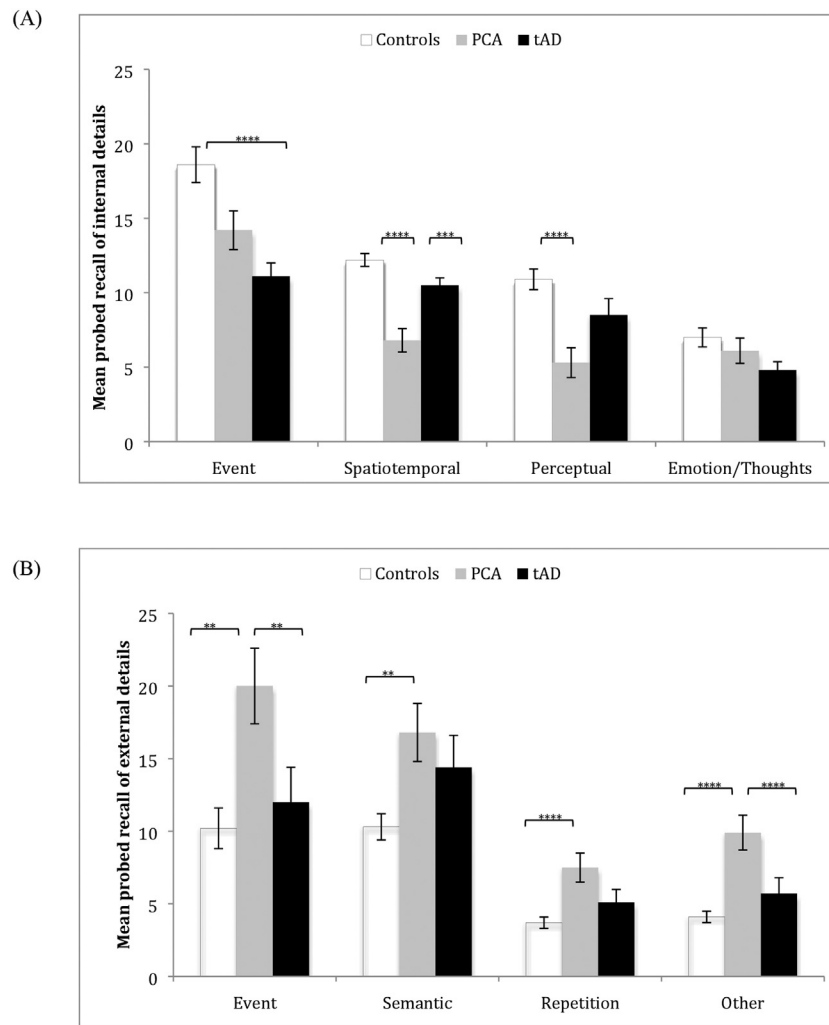


Fig. 4. Segmentation of probed recall of (A) internal details; and (B) external details into contextual categories. Error bars represent standard error of mean. (** $p < 0.01$; *** $p < 0.001$; **** $p < 0.0001$).

Abbreviations: PCA Posterior cortical atrophy; tAD typical Alzheimer's disease.

atrophy in the occipito-temporal gyrus and regions of the parietal lobe.

Comparing the two patient groups, PCA patients demonstrated significant decreases in grey matter density compared to tAD patients bilaterally in the occipital lobes, and lateral parietal regions. No regions demonstrated reduced grey matter density in tAD compared with PCA patients following statistical corrections. To demonstrate that characteristic differences between tAD and PCA patient groups were present, comparison between the two patient groups was explored at an uncorrected, whole brain threshold of $p < 0.005$, tAD patients showed significant grey matter density decreases compared to PCA patients in bilateral hippocampus, bilateral parahippocampal gyrus, left paracingulate gyrus, bilateral anterior cingulate, bilateral superior frontal gyrus, left middle frontal gyrus, bilateral temporal pole, and bilateral insula.

Correlational analysis in the PCA group alone, revealed no significant correlations between total internal details, total external details and internal-to-total ratio and whole brain grey matter density.

3.6.2. Region of interest analyses

Analyses within the PCA < tAD mask revealed a significant correlation between perceptual details and grey matter density in the right precuneus ($p < 0.05$). No correlations were detected in relation to spatiotemporal details (Fig. 6). No correlations were detected within the hippocampal mask.

4. Discussion

In contrast to the widely held view that memory function is relatively preserved in PCA, our patients showed striking deficits in retrieval of ABMs, comparable to those observed in tAD. There was, however, a specific reduction of spatiotemporal and perceptual details from PCA patients' narratives, in line with our hypothesis that PCA causes a 'visual memory deficit amnesia'.

4.1. Overall profile of ABM impairment in PCA

Both PCA and tAD patients showed significantly reduced production of internal details compared to controls, reflecting difficulties with episodic re-experiencing of ABMs, evident across all life epochs. Additionally, PCA patients demonstrated a lower internal-to-total detail ratio than the tAD group, predominantly due to the over production of external, off target details within the ABM narrative. This result is clinically significant, particularly since current diagnostic protocols (McMonagle et al., 2006; Tang-Wai et al., 2004) state that episodic memory is relatively preserved in PCA. Research has only recently begun to delve further into memory function in PCA, and has already demonstrated poor anterograde memory equivalent to that observed in tAD (Ahmed et al., 2016a). The findings of this study show that this impairment of episodic memory in PCA extends to the autobiographical

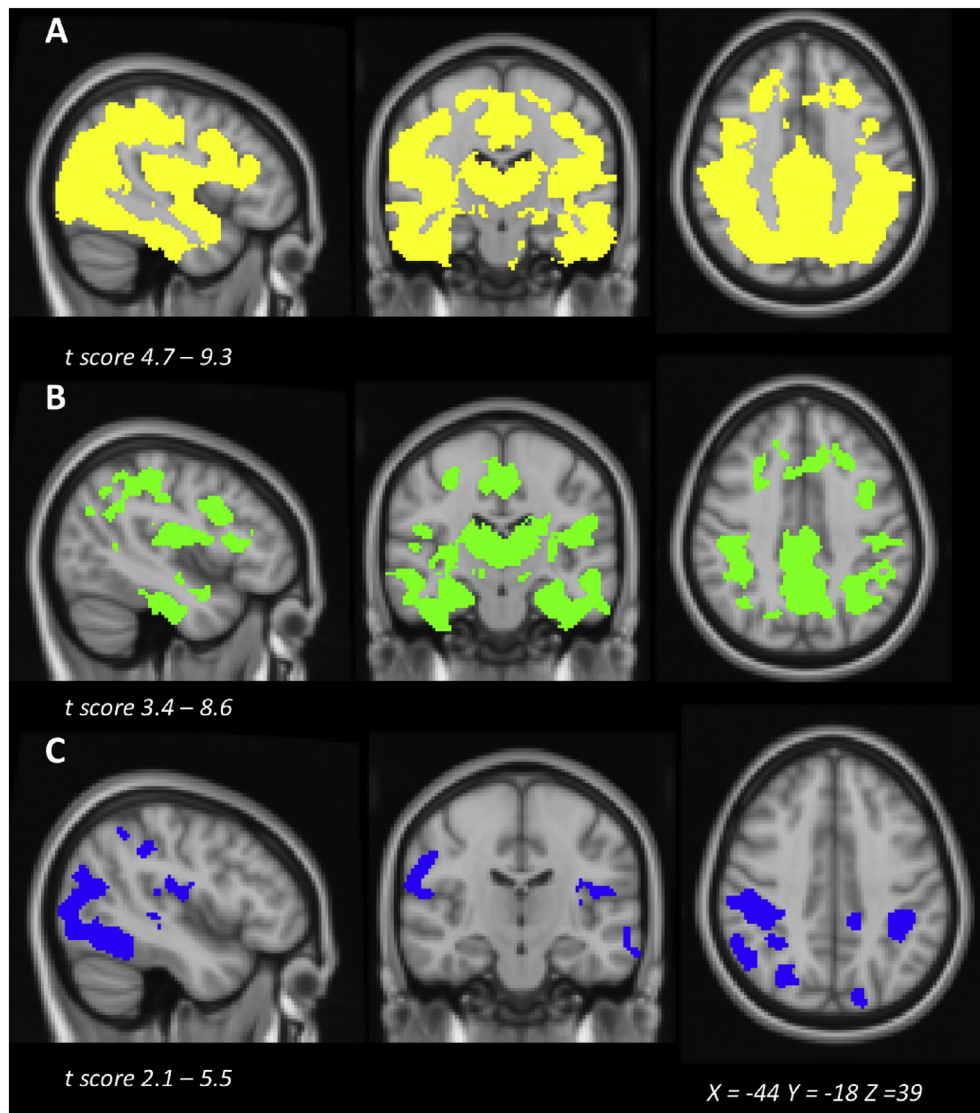


Fig. 5. Voxel based morphometry maps displaying reduced grey matter density in (A) = controls > Posterior cortical atrophy; (B) = controls > typical Alzheimer's disease and (C) = Posterior cortical atrophy < typical Alzheimer's disease. All comparisons were significant at $p < 0.05$ family-wise error corrected using threshold-free cluster enhancement method. All images in radiological display convention.

Table 2

Results from voxel-based morphometry analyses. All clusters were significant at $p < 0.05$ family-wise error corrected using threshold-free cluster enhancement method. For brevity only those clusters above 1000 contiguous voxels are reported.

Contrast	Regions	Cluster size	Coordinates (in MNI space, peak intensity)	t Value
PCA < controls	Bilateral thalamus, bilateral caudate, bilateral putamen, bilateral inferior temporal gyrus, bilateral middle temporal gyrus, bilateral superior temporal gyrus, bilateral parahippocampal gyrus, bilateral lateral occipital cortex, bilateral occipital fusiform gyrus, right angular gyrus, right supramarginal gyrus, bilateral precuneus, right postcentral gyrus, bilateral precentral gyrus, bilateral anterior and posterior cingulate, bilateral paracingulate cortex, bilateral brainstem.	84,040	-22, -88, -46	9.34
tAD < controls	Bilateral thalamus, bilateral caudate, bilateral putamen, bilateral hippocampus, bilateral parahippocampal gyrus, bilateral temporal fusiform cortex, bilateral inferior temporal gyrus, bilateral middle temporal gyrus, bilateral superior temporal gyrus, bilateral parietal operculum cortex, bilateral posterior cingulate, bilateral paracingulate gyrus, bilateral frontal pole, bilateral inferior frontal gyrus, bilateral superior frontal gyrus, bilateral subcallosal cortex, bilateral temporal pole, bilateral insula, left supramarginal gyrus.	41,226	-34, -12, -48	8.61
PCA < tAD	Bilateral lingual gyrus, bilateral lateral occipital cortex, bilateral temporal occipital fusiform cortex, bilateral inferior temporal gyrus, right middle temporal gyrus, right angular gyrus, right supramarginal gyrus, bilateral superior parietal lobule, right precuneus, bilateral occipital pole, right postcentral gyrus.	7773	28, -44, 66	5.23

Abbreviations: PCA Posterior cortical atrophy; tAD typical Alzheimer's disease; MNI Montreal Neurological Institute.

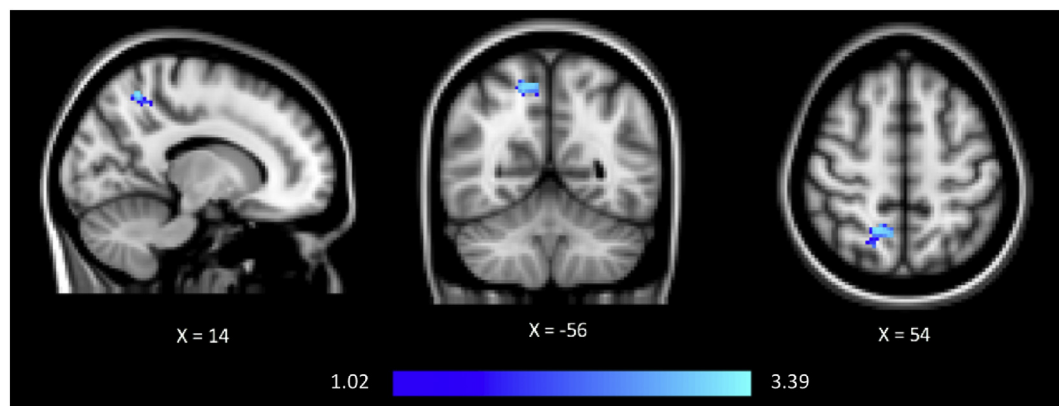


Fig. 6. Voxel-based morphometry maps displaying correlation between reduced grey matter density in right precuneus and perceptual details in Posterior cortical atrophy patients. Findings were significant at $p < 0.05$ family-wise error corrected using threshold-free cluster enhancement method, and the Posterior cortical atrophy $<$ typical Alzheimer's disease difference from the voxel-based morphometry analysis as a mask. Colour bar indicated t-score. Figure displayed at $p < 0.005$ uncorrected, for visualisation purposes. All images in radiological display convention.

domain. The mechanisms underlying ABM impairment in PCA cannot be solely attributed to the failure of strategic retrieval processes. Even with rigorous prompting across different categories of episodic detail, PCA patients did not reach control levels, suggesting that impairment in PCA is due to degradation of the memory traces themselves.

The profile of ABM impairment in tAD matches that described in previous studies using the AI (e.g. (Barnabe et al., 2012; Irish et al., 2011a; Irish et al., 2014)), revealing a specific loss of event details during ABM retrieval relative to controls, representing the degradation of central elements of the ABM trace. Given that our results largely replicate those of previous studies, the emphasis in the following discussion will therefore be on the profile of ABM impairment in PCA.

4.2. The role of visual perception and imagery

Analyses of contextual details revealed a unique profile of deficits in the PCA group, compared to other dementia groups. Despite rigorous and specific prompting, PCA patients showed a paucity of spatio-temporal and perceptual details relative to controls, and impaired provision of spatiotemporal details relative to the tAD group. In addition, PCA patients showed a global visual imagery deficit. Taken together, the results support our proposal that ABM impairment in PCA is mediated by disrupted access to visual information integral to the ABM trace.

There was also a relationship between the provision of perceptual details and delayed recall on the RAVLT. The neural correlates of this memory index in PCA are, as yet, unknown, however the relationship may be a function of parietal atrophy and visual imagery processes. Previous studies in older persons with memory complaints have reported metabolic correlates of RAVLT delayed recall with medial parietal regions, including the precuneus (Brugnolo et al., 2014). The precuneus, as we discuss later, is associated with visual imagery related to memory processes. The relationship of perceptual details and the RAVLT may then be a function of impaired visual representation of the word list (Cavanna and Trimble, 2006).

Theoretical accounts hold that successful retrieval of ABM is complex, drawing on several cognitive processes but relying critically on a visual imagery data source (see (Conway and Pleydell-Pearce, 2000; Rubin, 2006)). The successful invoking of long-term visual representations is posited to reactivate other non-visual details related to the event (Rubin and Greenberg, 1998). By this view, if the visual store is compromised, access to at least some of the basic informational units that comprise the memory will be lost, leading to ABM impairment. Patient studies corroborate the pivotal role of visual imagery. For example, patient M.H., who sustained occipital lesions following an accident, showed severe retrograde amnesia attributed to his inability to use

visual cues to activate remote memories (Ogden, 1993b). The ABMs that M.H. could successfully retrieve appeared to be largely mediated by non-visual sensory modalities such as sounds and smells. Similarly, young adults with congenital and acquired blindness have been shown to produce ABMs that lack specificity, are low in contextual details, and more closely represent semantic or abstracted representations (Goddard and Pring, 2001).

By contrast, ABM recall in tAD was related to tasks of executive function and fluency, suggesting that the underlying mechanisms for ABM in tAD are one of episodic retrieval and expression. Although visual imagery was not tested in tAD, impaired processing of visual information is unlikely to be the root cause underlying the ABM impairment in tAD, given that visuospatial functioning and recall of spatiotemporal and perceptual details on the AI was within the control range.

4.3. Neural basis of ABM in PCA

PCA patients showed a characteristic pattern of atrophy in the occipital cortex and lateral and medial posterior parietal cortex relative to controls and tAD. In contrast, tAD patients showed a typical pattern of atrophy in medial temporal lobe structures, including the hippocampus bilaterally, extending into frontal and posterior regions of the brain. Region of interest analysis revealed a correlation between the level of perceptual details and reduced grey matter density in the right precuneus. Perceptual processes and visual imagery are considered phenomenologically similar, sharing common representations in the brain (Kosslyn et al., 1997; Pearson et al., 2015). Neuroimaging studies report an overlap in neural activation during visual imagery and perception tasks, maximal in frontal and parietal regions, including the precuneus (Ganis et al., 2004; Kosslyn et al., 1997). The precuneus has long been linked with mental and visuospatial imagery capabilities (Dhindsa et al., 2014; Gardini et al., 2011; Ranganath and Ritchey, 2012), visual perspective taking (Fretton et al., 2014; St Jacques et al., 2016), as well as episodic memory retrieval (see (Cavanna and Trimble, 2006) for a review)). In a recent example, St Jacques et al. (2016) asked participants to generate ABMs and to describe these from their own visual perspective or from the perspective of an observer. Manipulating mental imagery during retrieval in order to shift perspective and accurately narrate a memory was related to neural activation in the precuneus. Taken together, the neuroimaging results have interesting implications for our understanding of the processes that underlie successful re-examination of our personal memories. Retrieval of ABMs is postulated to be a product of the interaction of a distributed “core” network of regions, including frontal, posterior parietal and medial temporal regions with a major role for the hippocampus (Svoboda et al.,

2006). Secondary regions are proposed to subserve processes that enhance ABMs, such as emotional processing in the amygdala and visual imagery in the occipital and posterior parietal regions. Crucially, the hippocampi were relatively spared in PCA compared to controls participants. Notably, tAD patients demonstrated significantly greater hippocampal atrophy compared to the PCA group, although this difference did not survive conservative statistical correction, most likely due to the relatively small sample size in the patient groups. As such, we suggest that poor ABM retrieval in PCA is not primarily attributable to defective hippocampal memory processing. Instead, our results suggest that the ABM deficit is driven by posterior parietal atrophy, in particular in the precuneus, through a reduced capacity for visual imagery (Kosslyn et al., 1997).

4.4. Profile of external details

PCA patients produced an inflated level of external details, significantly higher than controls and tAD, and irrespective of time period. Previous literature has suggested that high external scores are age-related, more common in the later decades of life (Levine et al., 2002), but may also be a marker of pathology with similar patterns of elevation observed in other neurodegenerative conditions, such as semantic dementia and Parkinson's disease (Irish et al., 2011a; Irish et al., 2012; Souchay and Smith, 2013). High external scores were driven by increased production of 'event' and 'other' details, suggesting that PCA patients were unable to constrain their search to one specific event. Instead, PCA patients provided a series of smaller events, which were lacking in contextual details). External scores were negatively correlated with the Hayling response inhibition task, adding weight to the argument that PCA patients are more tangential, producing more off-target information, or a series of events that were only marginally related to the main event.

4.5. Clinical implications

ABM serves several functions. Successful recollection of personally salient events is essential for maintaining a coherent sense of identity and a sense of self over time (Conway et al., 2004), and ABM dysfunction is associated with loss of identity in Alzheimer's disease (Addis and Tippett, 2004). ABM is also proposed to serve a directive function (Bluck et al., 2005), with past memories acting as a reference for solving current problems and guiding action. ABM provides an important foundation for envisaging the future and mounting evidence converges to reveal profound disturbances in future thinking in patient groups with ABM impairment. Finally, ABM serves a social function, aiding in the development and maintenance of social bonds by furnishing a person with knowledge with which to converse and build intimacy. Impaired ABM has been shown to be associated with increased levels of carer burden and changes in the quality of the patient-carer relationship in younger-onset dementia syndromes (Kumfor et al., 2016). The loss of ABM in patients with PCA will therefore have significant, but currently under-appreciated, impacts upon day-to-day living, and further study is warranted here.

There are several strengths to this study. Firstly, the AI is a well-validated and detailed measure of ABM that has been used extensively in the dementias (Barnabe et al., 2012; Irish et al., 2011a; McKinnon et al., 2006). Secondly, the sample size in PCA was relatively large, given the rarity of the syndrome, and was similar to cohorts described in other prospective, neurobehavioural studies of PCA (Shakespeare et al., 2015a; Yong et al., 2015). However, the patient and control groups were recruited over two separate study sites, introducing the possibility of variability in the neuropsychological and AI assessment, although high inter-rater reliability was recorded for the scoring (see Methods). Further, cross-cultural studies of ABM retrieval have not tended to find significant differences between Western societies in ABM retrieval curves across the lifespan (e.g., Conway et al.,

2005 #305)) suggesting that cultural differences in participants across the two sites has little influence on ABM content and retrieval. Finally, we were limited to the use of existing tasks of visual imagery which, while evidence-based (Farah, 1985; Farah, 1988), were not designed specifically to probe visual imagery as hypothesised to be implicated in PCA. Despite this, PCA patients were significantly impaired on these tasks compared to controls.

5. Conclusions

In summary, we present evidence for striking ABM dysfunction in PCA, a syndrome typically viewed as a disorder of higher visual processing with relatively spared memory processing. ABM impairment in PCA is characterised by a specific dearth of spatiotemporal and perceptual details, is accompanied by widespread problems with visual imagery, and correlates with atrophy in the precuneus. Our findings highlight the significance of visual imagery in ABM retrieval and provide new insights into the clinical phenotype of PCA.

Funding

SA is supported by the NIHR Oxford Biomedical Research Centre and Alzheimer's Research UK (ARUK-NSG2017-4). MI is supported by an Australian Research Council Future Fellowship (FT160100096). MH is supported by the Wellcome Trust. CBD is supported by the Wellcome Trust and the Clarendon Fund at the University of Oxford. OP is supported by an NHMRC Senior Research Fellowship (APP1103258). CRB is supported by a Medical Research Council Clinician Scientist Fellowship (MR/K010395/1). This work was also supported, in part, by funding the National Health and Medical Research Council (NHMRC) of Australia program grant (APP1037746), and the Australian Research Council (ARC) Centre of Excellence in Cognition and its Disorders (CE110001021).

Acknowledgments

We are indebted to the patients and families for their kind participation in our research.

Appendix A. Representative transcript from a (i) PCA patient, (ii) tAD patient, and (iii) control participant, describing a memory from the Early Adulthood period under the Free Recall condition. Transcripts have been modified to remove any identifying information. Experimenter prompts given in italics

A.1. PCA patient

I, er, finished my apprenticeship. And I went - I was then forced into the Air Force, and, and I went as a, an engine mechanic, and I was, er, erm did all my service on the Rock of Gibraltar. And one day, on the Rock of Gibraltar, the, er I was repairing an engine on one of the planes. You overhauled an engine, and put it in back in the __. And it was what they called the Station Flight. And the Commanding Officer had to get his, er, time in for flying. So he took this aeroplane, which was an Avro Anson. It's a very old plane. And in Gibraltar, the, er, runway is just above sea level. It's, er, sea either end. Anyway, he went up in this plane. And usually, they after you've done a repair, they usually force the engineer up with you. And on this oc- occasion, he didn't. Anyway, he came in to approach er, to land and his part, part of this exercise, was to, er, come in on one engine. Anyway, he came er, he flew in, and, er, he decided he had to, er, get the solo engine running to land. And instead of, er, put, put er, making his other engine work, he __ the one he already had. So he went straight into the water. And they said he was, er, on top of the plane. Er, plane went down under in one minute, and for 59 s of that, he was sitting on top of the plane. And anyway, erm, what happened was that, er, er, we had what we call a c a form

700, which is the overhaul documents that you, you did on the plane. So I was grounded, literally grounded, and, erm, I was, er, all I ever was has to do was sweep the floor, and all that sort of thing. But he came er, after a while, it was decided it was gross pilot's error. So I got away with that one. And, erm, all sorts of things happened when I was at Gibraltar. I mean, for example, er, the Americans, they had a base at Cas-Casablanca and, er, they came in on what they called the whisky run. And they, er, came in with this plane, and it was a Dakota, which has got a tail flag on it. Well, it came in, and, er, the wheel at the back collapsed. So it went all the way up the runway with sparks flying, and rear wheel dragging behind. So what they did, they got a big crane, lifted it up, tied it up with rope and all that and had to go back again, er, er, with it all roped up. That's the sort of thing.

Is there anything else you can tell me about that one? Any more, any more details that you remember?

Erm, no. Well, I could tell, tell you another s- story. It's the same time. Erm, er, they had, er, in Rabat, in Morocco. I mean it's, it's Muslim countries, you know. Erm, and they've got the embassy at Rabat. And, er, anyway, I er, they wanted to take whisky and everything from Gibraltar to Rabat, to bring into the embassy. And, erm, so I went in as co-pilot and flew down to Rabat. And I did- never knew at the time that being such a strict Muslim country that it was illegal to bring alcohol in. And the, er, moment we landed, they brought in, erm, a jeep to pick it all up, and rushed us off to the embassy, and they rushed us back. And I never realised at the time, they could of locked me up for bringing in the whisky.

A.2. tAD patient

Okay I'll take my parents visiting um, um, one of the shattering things for me was to take mum and dad around to see the sights of Rome and millions of people go there every year to see those sights and my father described the Colosseum as um, "a bunch of rocks" and you know ah, and "they could have polished it off a bit you know made it into something that could be quite usable instead of this round space" and um, so there was that real um... It was good to see them but it was good to see them go home too um, because they it was like um, they bought me down to my world again. It reminded me of my childhood, what appeared to me to be very limited having gone to university and then gone overseas um...

Okay so had you, had you gone into the Colosseum with your parents? Yes.

Maybe you could tell me about that part of the day? Is that something you can remember quite well or can tell me about?

Yes I can remember it um, it was that shock factor I suppose um... Mum was struggling with um, moving around so I was trying to assist her and you know she's my mother and we are in the Colosseum but um, she's my mother and here's Dad who's... here's Dad sort of saying you know a "bunch of rocks" you know. "Why didn't they cement the floor down there and they could have concerts" and things like that you know um, so it was like I... that tension between delighting in them being there and being really annoyed with ah, the world that they bought across there was you know number 11 D— Street C—, B— and I knew that I had moved on from that and I really, really struggled and there was a level of dislike coming into our being together.

A.3. Control participant

Well within that period the one that stands out is the wedding day you mentioned which was um in the UK, having gone over there as a young dentist in nineteen sixty-two, I was married on the first of April nineteen sixty-four. My wife V— and the specific day was interesting because it was freezing, and it wasn't the type of weather that we expected, and actually snowed on the day. It was good, very pleasant. My brother had come from Australia to be best man and um, the place was called G— in M— in England and at that stage, we had

known one another for only a year or so. But the memorable thing about it apart from the joy of being married was that it was so cold. Um, I had arrived at the church a little late and I think that the tradition is that the wife was supposed to arrive late so she was there actually before me in a car and had to keep going around and around the block until I arrived! Um, it was a very nervous time for me because I hadn't been married before because of my job but ah and in the church, being nervous as I was after being encouraged by the priest to turn around and see my wife coming down the aisle which wasn't natural, ha ha! Brought up in rather a strict catholic upbringing as I was, in church the idea was that you look ahead so he had to tell me, "It's quite alright to turn around and look at your bride coming down the aisle. She looks quite beautiful" and he was right. Um, and that day knowing the weather was very short, all the photographs had to be take outside the church where people were absolutely freezing half to death...[continues].

References

- Addis, D.R., Tippett, L.J., 2004. Memory of myself: autobiographical memory and identity in Alzheimer's disease. *Memory* 12 (1), 56–74.
- Ahmed, S., Baker, I., Husain, M., Thompson, S., Kipps, C., Hornberger, M., et al., 2016a. Memory impairment at initial clinical presentation in posterior cortical atrophy. *J. Alzheimers Dis.* 52 (4), 1245–1250.
- Ahmed, S., Baker, I., Thompson, S., Husain, M., Butler, C.R., 2016b. Utility of testing for apraxia and associated features in dementia. *J. Neurol. Neurosurg. Psychiatry* 87 (11), 1158–1162.
- Autho, c.350 BC. *De Anima (On the Soul) Vol.*, H. Lawson-Tancred, ed. Penguin Classics, London.
- Barnabe, A., Whitehead, V., Pilon, R., Arsenault-Lapierre, G., Chertkow, H., 2012. Autobiographical memory in mild cognitive impairment and Alzheimer's disease: a comparison between the Levine and Kopelman interview methodologies. *Hippocampus* 22 (9), 1809–1825.
- Benton, A.L., Hamsher, K., 1976. *Multilingual Aphasia Examination*, Vol. AJA Associates, Iowa City, University of Iowa.
- Bluck, S., Alea, N., Haberman, T., Rubin, D.C., 2005. A tale of three functions: the self-reported uses of autobiographical memory. *Soc. Cogn.* 23 (1), 91–117.
- Brewer, W.F., 1996. What is recollective memory? In: R., D.C. (Ed.), *Remembering our Past: Studies in Autobiographical Memory*. Vol. Cambridge University Press, New York.
- Brugnolo, A., Morbelli, S., Arnaldi, D., De Carli, F., Accardo, J., Bossert, I., et al., 2014. Metabolic correlates of Rey auditory verbal learning test in elderly subjects with memory complaints. *J. Alzheimers Dis.* 39 (1), 103–113.
- Burgess, P.W., Shallice, T., 1996. Response suppression, initiation and strategy use following frontal lobe lesions. *Neuropsychologia* 34 (4), 263–272.
- Cabeza, R., St Jacques, P., 2007. Functional neuroimaging of autobiographical memory. *Trends Cogn. Sci.* 11 (5), 219–227.
- Cavanna, A.E., Trimble, M.R., 2006. The precuneus: a review of its functional anatomy and behavioural correlates. *Brain* 129 (Pt 3), 564–583.
- Conway, M.A., Pleydell-Pearce, C.W., 2000. The construction of autobiographical memories in the self-memory system. *Psychol. Rev.* 107 (2), 261–288.
- Conway, M.A., Rubin, D.C., 1993. The structure of autobiographical memory. In: Collins, A.F., Gathercole, S.E., Conway, M.A., Morris, P.E. (Eds.), *Theories of Memory*. Vol. Lawrence Erlbaum Associates, Hillsdale, pp. 103–137.
- Conway, M.A., Singer, J.A., Tagini, A., 2004. The self and autobiographical memory: correspondence and coherence. *Soc. Cogn.* 22, 491–529.
- Conway, M.A., Wang, Q., Hanyu, K., Haque, S., 2005. A cross-cultural investigation of autobiographical memory. *J. Cross-Cult. Psychol.* 36 (6), 739–749.
- Crutch, S.J., Lehmann, M., Warrem, J.D., Rohrer, J.D., 2013. The language profile of posterior cortical atrophy. *J. Neurol. Neurosurg. Psychiatry* 84 (4), 460–466.
- Crutch, S.J., Schott, J.M., Rabinovici, G.D., Murray, M., Snowden, J.S., Van der Flier, W.M., Dickerson, B.C., Vandenbergh, R., Ahmed, S., Bak, T.H., Boeve, B.F., Butler, C., Cappa, S.F., Ceccaldi, M., de Souza, L.C., Dubois, B., Felician, O., Galasko, D., Graff-Radford, J., Graff-Radford, N.R., Hof, P.R., Krolak-Salmon, P., Lehmann, M., Magnin, E., Mendez, M.F., Nestor, P.J., Onyike, C.U., Pelak, V.S., Pijnenberg, Y., Primativo, S., Rossor, M.N., Ryan, N.S., Scheltens, P., Shakespeare, T.J., Suarez Gonzalez, A., Tang-Wai, D.F., Yong, K.X., Carrillo, M., Fox, N.C., 2017. Consensus classification of posterior cortical atrophy. *Alzheimers Dement.* 13 (8), 870–884.
- Dhindsa, K., Drobinin, V., King, J., Hall, G.B., Burgess, N., Becker, S., 2014. Examining the role of the temporo-parietal network in memory, imagery, and viewpoint transformations. *Front. Hum. Neurosci.* 8 (709).
- Douaud, G., Smith, S., Jenkinson, M., Behrens, T., Johansen-Berg, H., Vickers, J., et al., 2007. Anatomically related grey and white matter abnormalities in adolescent-onset schizophrenia. *Brain* 130 (Pt 9), 2375–2386.
- Farah, M.J., 1985. Psychophysical evidence for a shared representational medium for mental images and percepts. *J. Exp. Psychol.* Gen. 114 (1), 91–103.
- Farah, M.J., 1988. Is visual imagery really visual? Overlooked evidence from neuropsychology. *Psychol. Rev.* 95 (3), 307–317.
- Folstein, M.F., Folstein, S.E., McHugh, P.R., 1975. "Mini-mental state". A practical method for grading the cognitive state of patients for the clinician. *J. Psychiatr. Res.*

- 12 (3), 189–198.
- Freton, M., Lemogne, C., Bergouignan, L., Delaveau, P., Lehericy, S., Fossati, P., 2014. The eye of the self: precuneus volume and visual perspective during autobiographical memory retrieval. *Brain Struct. Funct.* 219 (3), 959–968.
- Ganis, G., Thompson, W.L., Kosslyn, S.M., 2004. Brain areas underlying visual mental imagery and visual perception: an fMRI study. *Brain Res. Cogn. Brain Res.* 20 (2), 226–241.
- Gardini, S., Concari, L., Pagliara, S., Ghetti, C., Venneri, A., Caffarra, P., 2011. Visuo-spatial imagery impairment in posterior cortical atrophy: a cognitive and SPECT study. *Behav. Neurol.* 24 (2), 123–132.
- Goddard, L., Pring, L., 2001. Autobiographical memory in the visually impaired: initial findings and impressions. *Br. J. Vis. Impair.* 19 (3), 108–113.
- Greenberg, D.L., Knowlton, B.J., 2014. The role of visual imagery in autobiographical memory. *Mem. Cogn.* 42 (6), 922–934.
- Greenberg, D.L., Eacott, M.J., Brechin, D., Rubin, D.C., 2005. Visual memory loss and autobiographical amnesia: a case study. *Neuropsychologia* 43 (10), 1493–1502.
- Howard, D., Patterson, K., 1992. *The Pyramids and Palm Trees*, Vol. Thames Valley Test Company, Bury St Edmunds.
- Irish, M., Piguët, O., 2013. The pivotal role of semantic memory in remembering the past and imagining the future. *Front. Behav. Neurosci.* 7 (27).
- Irish, M., Hornberger, M., Lah, S., Miller, L., Pengas, G., Nestor, P.J., et al., 2011a. Profiles of recent autobiographical memory retrieval in semantic dementia, behavioural-variant frontotemporal dementia, and Alzheimer's disease. *Neuropsychologia* 49 (9), 2694–2702.
- Irish, M., Lawlor, B.A., O'Mara, S.M., Coen, R.F., 2011b. Impaired capacity for autoegetic reliving during autobiographical event recall in mild Alzheimer's disease. *Cortex* 47 (2), 236–249.
- Irish, M., Addis, D.R., Hodges, J.R., Piguët, O., 2012. Considering the role of semantic memory in episodic future thinking: evidence from semantic dementia. *Brain* 135 (Pt 7), 2178–2191.
- Irish, M., Hornberger, M., El Wahsh, S., Lam, B.Y., Lah, S., Miller, L., et al., 2014. Grey and white matter correlates of recent and remote autobiographical memory retrieval—insights from the dementias. *PLoS One* 9 (11), e113081.
- Kas, A., de Souza, L.C., Samri, D., Bartolomeo, P., Lacomblez, L., Kalafat, M., et al., 2011. Neural correlates of cognitive impairment in posterior cortical atrophy. *Brain* 134 (Pt 5), 1464–1478.
- Kopelman, M.D., Wilson, B.A., Baddeley, A.D., 1989. The autobiographical memory interview: a new assessment of autobiographical and personal semantic memory in amnesic patients. *J. Clin. Exp. Neuropsychol.* 11 (5), 724–744.
- Kosslyn, S.M., 1987. Seeing and imagining in the cerebral hemispheres: a computational approach. *Psychol. Rev.* 94 (2), 148–175.
- Kosslyn, S.M., Thompson, W.L., Alpert, N.M., 1997. Neural systems shared by visual imagery and visual perception: a positron emission tomography study. *NeuroImage* 6 (4), 320–334.
- Kosslyn, S.M., Ganis, G., Thompson, W.L., 2001. Neural foundations of imagery. *Nat. Rev. Neurosci.* 2 (9), 635–642.
- Kumfor, F., Teo, D., Miller, L., Lah, S., Mioshi, E., Hodges, J.R., et al., 2016. Examining the relationship between autobiographical memory impairment and carer burden in dementia syndromes. *J. Alzheimers Dis.* 51 (1), 237–248.
- Levine, B., Svoboda, E., Hay, J.F., Winocur, G., Moscovitch, M., 2002. Aging and autobiographical memory: dissociating episodic from semantic retrieval. *Psychol. Aging* 17 (4), 677–689.
- Lovibond, S.H., Lovibond, P.F., 1995. *Manual for the Depression Anxiety Stress Scales*, Vol. Psychology Foundation of Australia, Sydney, Australia.
- Luria, A.R., 1987. *The Mind of a Mnemonist*, Vol. Harvard University Press, Cambridge, Massachusetts.
- McKhann, G., Drachman, D., Folstein, M., Katzman, R., Price, D., Stadlan, E.M., 1984. Clinical diagnosis of Alzheimer's disease: report of the NINCDS-ADRDA Work Group under the auspices of Department of Health and Human Services Task Force on Alzheimer's Disease. *Neurology* 34 (7), 939–944.
- McKhann, G.M., Knopman, D.S., Chertkow, H., Hyman, B.T., Jack Jr., C.R., Kawas, C.H., et al., 2011. The diagnosis of dementia due to Alzheimer's disease: recommendations from the National Institute on Aging-Alzheimer's Association workgroups on diagnostic guidelines for Alzheimer's disease. *Alzheimers Dement.* 7 (3), 263–269.
- McKinnon, M.C., Black, S.E., Miller, B., Moscovitch, M., Levine, B., 2006. Autobiographical memory in semantic dementia: implication for theories of limbic-neocortical interaction in remote memory. *Neuropsychologia* 44 (12), 2421–2429.
- McMonagle, P., Deering, F., Berliner, Y., Kertesz, A., 2006. The cognitive profile of posterior cortical atrophy. *Neurology* 66 (3), 331–338.
- Migliaccio, R., Agosta, F., Rascovsky, K., Karydas, A., Bonasera, S., Rabinovici, G.D., et al., 2009. Clinical syndromes associated with posterior atrophy: early age at onset AD spectrum. *Neurology* 73 (19), 1571–1578.
- Migliaccio, R., Gallea, C., Kas, A., Perlberg, V., Samri, D., Trotta, L., et al., 2016. Functional connectivity of ventral and dorsal visual streams in posterior cortical atrophy. *J. Alzheimers Dis.* 51 (4), 1119–1130.
- Mioshi, E., Dawson, K., Mitchell, J., Arnold, R., Hodges, J.R., 2006. The Addenbrooke's Cognitive Examination Revised (ACE-R): a brief cognitive test battery for dementia screening. *Int. J. Geriatr. Psychiatry* 21 (11), 1078–1085.
- Morris, J.C., 1997. Clinical dementia rating: a reliable and valid diagnostic and staging measure for dementia of the Alzheimer type. *Int. Psychogeriatr.* 9 (Suppl. 1) 173–6; discussion 177–8).
- Morris, J.C., Heyman, A., Mohs, R.C., Hughes, J.P., van Belle, G., Fillenbaum, G., et al., 1989. The Consortium to Establish a Registry for Alzheimer's Disease (CERAD). Part I. Clinical and neuropsychological assessment of Alzheimer's disease. *Neurology* 39 (9), 1159–1165.
- Murphy, K.J., Troyer, A.K., Levine, B., Moscovitch, M., 2008. Episodic, but not semantic, autobiographical memory is reduced in amnesic mild cognitive impairment. *Neuropsychologia* 46 (13), 3116–3123.
- Ogden, J.A., 1993a. Visual object agnosia, prosopagnosia, achromatopsia, loss of visual imagery, and autobiographical amnesia following recovery from cortical blindness: case MH. *Neuropsychologia* 31 (6), 571–589.
- Ogden, J.A., 1993b. Visual object agnosia, prosopagnosia, achromatopsia, loss of visual imagery, and autobiographical amnesia following recovery from cortical blindness: case M.H. *Neuropsychologia* 31 (6), 571–589.
- Pearson, J., Naselaris, T., Holmes, E.A., Kosslyn, S.M., 2015. Mental imagery: functional mechanisms and clinical applications. *Trends Cogn. Sci.* 19 (10), 590–602.
- Piefke, M., Weiss, P., Zilles, K., Markowitsch, H., Fink, G., 2003. Differential remoteness and emotional tone modulate the neural correlates of autobiographical memory. *Brain* 126 (3), 650–668.
- Pillemer, D.B., Wink, P., DiDonato, T.E., Sanborn, R.L., 2003. Gender differences in autobiographical memory styles of older adults. *Memory* 11 (6), 525–532.
- Piolino, P., Desgranges, B., Eustache, F., 2009. Episodic autobiographical memories over the course of time: cognitive, neuropsychological and neuroimaging findings. *Neuropsychologia* 47 (11), 2314–2329.
- Pohl, R.F., Bender, M., Lachmann, G., 2005. Autobiographical memory and social skills of men and women. *Appl. Cogn. Psychol.* 19, 745–759.
- Policardi, E., Perani, D., Zago, S., Grassi, F., Fazio, F., Ladavas, E., 1996. Failure to evoke visual images in a case of long-lasting cortical blindness. *Neurocase* 2 (5), 381–394.
- Ranganath, C., Ritchey, M., 2012. Two cortical systems for memory-guided behaviour. *Nat. Rev. Neurosci.* 13 (10), 713–726.
- Renner, J.A., Burns, J.M., Hou, C.E., DW Jr., McKeel, Storandt, M., Morris, J.C., 2004. Progressive posterior cortical dysfunction: a clinicopathologic series. *Neurology* 63 (7), 1175–1180.
- Rey, A., 1941. Psychological examination of traumatic encephalopathy. *Arch. Psychol.* 28, 286–340.
- Rey, A., 1964. *L'examen clinique en psychologie*, Vol. Presses Universitaires de France, Paris.
- Rissman, J., Chow, T.E., Reggente, N., Wagner, A.D., 2016. Decoding fMRI signatures of real-world autobiographical memory retrieval. *J. Cogn. Neurosci.* 28 (4), 604–620.
- Rubin, D.C., 2006. The basic-systems model of episodic memory. *Perspect. Psychol. Sci.* 1 (4), 277–311.
- Rubin, D.C., Greenberg, D.L., 1998. Visual memory-deficit amnesia: a distinct amnesic presentation and etiology. *Proc. Natl. Acad. Sci. U. S. A.* 95 (9), 5413–5416.
- Shakespeare, T.J., Kaski, D., Yong, K.X., Paterson, R.W., Slattery, C.F., Ryan, N.S., et al., 2015a. Abnormalities of fixation, saccade and pursuit in posterior cortical atrophy. *Brain* 138 (Pt 7), 1976–1991.
- Shakespeare, T.J., Yong, K.X., Foxe, D., Hodges, J., Crutch, S.J., 2015b. Pronounced impairment of everyday skills and self-care in posterior cortical atrophy. *J. Alzheimers Dis.* 43 (2), 381–384.
- Smith, S.M., 2002. Fast robust automated brain extraction. *Hum. Brain Mapp.* 17 (3), 143–155.
- Smith, S.M., Nichols, T.E., 2009. Threshold-free cluster enhancement: addressing problems of smoothing, threshold dependence and localisation in cluster inference. *NeuroImage* 44 (1), 83–98.
- Souchay, C., Smith, S.J., 2013. Autobiographical memory in Parkinson's disease: a retrieval deficit. *J. Neuropsychol.* 7 (2), 164–178.
- Squire, L.R., 1992. Declarative and nondeclarative memory: multiple brain systems supporting learning and memory. *J. Cogn. Neurosci.* 4 (3), 232–243.
- St Jacques, P.L., Conway, M.A., Cabeza, R., 2011. Gender differences in autobiographical memory for everyday events: retrieval elicited by SenseCam images versus verbal cues. *Memory* 19 (7), 723–732.
- St Jacques, P.L., Szpunar, K.K., Schacter, D.L., 2016. Shifting visual perspective during retrieval shapes autobiographical memories. *NeuroImage* 148, 103–114.
- Svoboda, E., McKinnon, M.C., Levine, B., 2006. The functional neuroanatomy of autobiographical memory: a meta-analysis. *Neuropsychologia* 44 (12), 2189–2208.
- Tang-Wai, D.F., Graff-Radford, N.R., Boeve, B.F., Dickson, D.W., Parisi, J.E., Crook, R., et al., 2004. Clinical, genetic, and neuropathologic characteristics of posterior cortical atrophy. *Neurology* 63 (7), 1168–1174.
- Thompson, J.C., Beswick, T., Foster, J.K., Snowden, J.S., 2003. New learning and remote memory in atypical Alzheimer's disease. *Cortex* 39 (4–5), 751–766.
- Warrington, E.K., James, M., 1991. *Visual Object and Space Perception Battery*, Vol. Thames Valley Test Co., Bury St Edmunds, Suffolk.
- Weschler, D., 2014. *Weschler Adult Intelligence Scale*, Vol. Pearson, UK.
- Whitwell, J.L., Jack Jr., C.R., Kantarci, K., Weigand, S.D., Boeve, B.F., Knopman, D.S., et al., 2007. Imaging correlates of posterior cortical atrophy. *Neurobiol. Aging* 28 (7), 1051–1061.
- Winkler, A.M., Ridgway, G.R., Webster, M.A., Smith, S.M., Nichols, T.E., 2014. Permutation inference for the general linear model. *NeuroImage* 92(2), 381–397.
- Yong, K.X., Rajdev, K., Shakespeare, T.J., Leff, A.P., Crutch, S.J., 2015. Facilitating text reading in posterior cortical atrophy. *Neurology* 85 (4), 339–348.
- Zamboni, G., Wilcock, G.K., Douaud, G., Drazich, E., McCulloch, E., Filippini, N., et al., 2013. Resting functional connectivity reveals residual functional activity in Alzheimer's disease. *Biol. Psychiatry* 74 (5), 375–383.