

## Salvage Procedure after Sternochondroplasty for Pectus Excavatum

Aramini B<sup>1\*</sup>, Morandi U<sup>1</sup>, Santis GD<sup>2</sup> and Baccarani A<sup>2</sup>

<sup>1</sup>Division of Thoracic Surgery, Department of Medical and Surgical Sciences for Children and Adults, University of Modena and Reggio Emilia, Modena, Italy

<sup>2</sup>Division of Plastic Surgery, Department of Medical and Surgical Sciences for Children and Adults, University of Modena and Reggio Emilia, Modena, Italy

### Abstract

Vacuum-Assisted Closure (VAC) in association to flap reconstruction is a well-established approach for treating complicated wounds.

The authors present a case of soft-tissue breakdown with hardware exposure in a patient treated with modified Ravitch procedure for pectus excavatum. VAC therapy was applied in association to multiple debridement procedures and final flap closure. This was achieved without the need for hardware removal, thus maintaining adequate skeletal fixation. To our knowledge this approach has not yet been described into the literature after sternochondroplasty procedure.

Aggressive debridement and VAC therapy before final closure may represent a new, conservative method for managing surgical complications after sternochondroplasty procedures.

**Keywords:** Pectus excavatum correction; Vacuum-assisted closure

### Introduction

Pectus excavatum is a depression of the sternum and of costal cartilages, with reduction in the anteroposterior diameter of the thorax. It is the most common chest wall deformity requiring surgical correction. As previously described [1,2], modified Ravitch procedure is one of the most common open approach.

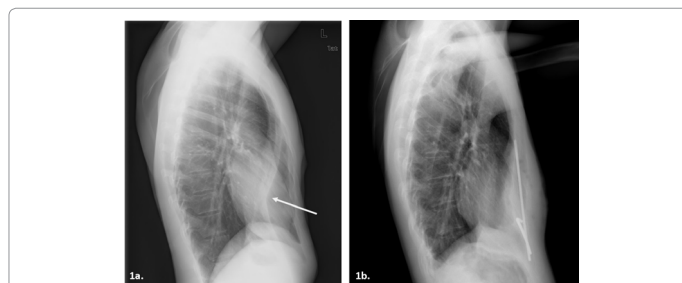
### Case Presentation

A 23-year-old man underwent surgical correction of a severe pectus excavatum deformity at our Institution (Figures 1a and 1b). Surgery was performed according to the reported technique. In the immediate postoperative period, a minimal bilateral pneumothorax occurred and was conservatively treated with bed rest until complete resolution. The patient was discharged on postoperative day 7. Four weeks later, the patient returned to our Hospital for the dehiscence of the wound in presence of serum. The hardware was exposed. Microbiological samples from the wound were negative. The patient was afebrile and presented no significant general symptoms. A therapy with Piperacillin/Tazobactam was started. The patient was then referred to the Plastic Surgery Unit. Multiple debridement procedures in association to VAC were advised after a multidisciplinary counsel involving infectivologists and a detailed analysis of the wound (Figure 2a).

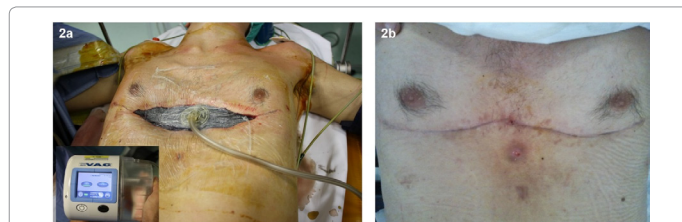
The patient was checked every two days. Every time the wound was debrided and washed with 5 liters pulsatile jet irrigation system. Next a VAC dressing foam was applied to fill all the undermined area and the skin was sutured almost completely over the sponge. A small spot of dressing remained exposed to allow for the suction pad to be applied. Negative pressure was set at 125 mm Hg.

This treatment allowed for a significant improvement of the local condition of the wound within the first 10 days. The effective response to VAC therapy after surgical debridement and wound irrigation led us to attempt a salvage procedure. The decision of not removing the hardware was taken and a closure of the wound was thus performed. A full thickness fasciocutaneous abdominal flap was harvested and superiorly advanced to close the defect.

The postoperative course was uneventful, and the patient was discharged 7 days after closure (Figure 1b). At the 1-year follow up, the chest wall was clinically and radiologically stable, the surgical scars were well settled, and no hardware exposure occurred. Hardware removal was then performed under general anesthesia 14 months after wound closure. At one-year follow-up after hardware removal, the patient



**Figure 1:** a. Preoperative chest X-ray; b. Seventh-day after wound closure chest X-ray.



**Figure 2:** a. Intraoperative VAC positioning; b. Result one year after surgery.

showed no deformity recurrence, Haller index was 2.56, and stable and cosmetically acceptable scars (Figure 2b).

### Discussion

VAC therapy is a well-established technical resource in managing complicated wounds, increasing arteriolar dilatation, blood flow and oxygenation. It also reduces edema and the bacterial bioburden, allowing for granulation tissue to grow and support healing [3,4].

**\*Corresponding author:** Beatrice Aramini, Division of Thoracic Surgery, Department of Medical and Surgical Sciences for Children and Adults, University of Modena and Reggio Emilia, Modena, Italy, Tel +39 059 205 6511; E-mail: [beatrice.aramini@unimore.it](mailto:beatrice.aramini@unimore.it)

Received March 29, 2018; Accepted April 04, 2018; Published April 10, 2018

**Citation:** Aramini B, Morandi U, Santis GD, Baccarani A (2018) Salvage Procedure after Sternochondroplasty for Pectus Excavatum. J Clin Case Rep 8: 1097. doi: 10.4172/2165-7920.10001097

**Copyright:** © 2018 Aramini B, et al. This is an open-access article distributed under the terms of the Creative Commons Attribution License, which permits unrestricted use, distribution, and reproduction in any medium, provided the original author and source are credited.

Hardware exposure in presence of a contaminated wound usually requires generous debridement and hardware removal on a standard practice basis [4].

In the presented case, hardware removal would have determined a skeletal collapse with failure of the corrective procedure and subsequent permanent deformity. For this reason, all our efforts were to maintain the internal fixation. A literature analysis revealed no standard management of complications associated to this specific sternochondroplasty procedure. Thus, a conservative approach was considered and successfully attempted.

From the reconstructive standpoint, a number of procedures have been described to restore medial chest wall defects. These include both pedicled and free flaps, both with muscle or fasciocutaneous. The “reconstructive ladder principle” suggests the simple procedure being considered first to avoid donor site morbidity and further complications associated to more sophisticated procedures [5]. With respect to this concept, a reverse abdominoplasty flap allowed for a tension-free closure, no additional scars and a good skin match. This aspect is of great relevance when considering the high expectations of these types of young patients.

## Conclusion

A successful salvage approach has been described. Personalized care, multidisciplinary counseling and prompt surgical planning are recommended for managing such complications. Hardware salvage and eventual stable deformity correction may be achieved by combining VAC therapy, multiple debridement procedures and flap closure.

## References

1. Ravitch MM (1977) Congenital deformities of the chest wall and their operative correction. *Br J Dis Chest* 73: 208-208
2. Lodi R, Morandi U, Spagna G (1990) Correzione chirurgica delle malformazioni della parete toracica anteriore. *La Chir Torac* 43: 73-77.
3. Morandi U, Stefani A, Ruggiero C (1997) Surgical correction of pectus excavatum. Modalities, techniques and results at distance. *Gastroenterology International* 10: 671-672.
4. Morykwas MJ, Argenta LC, Shelton BEI, McGuirt W (1997) Vacuum-assisted closure: a new method for wound control and treatment: animal studies and basic foundation. *Ann Plast Surg* 38: 553-562.
5. Pradka SP, Ong YS, Zhang SJ, Bacarani A (2009) Increased signs of acute rejection with ischemic time in a rat musculocutaneous allotransplant model. *Transpl Proc* 41: 531-536.