

## BRIEF COMMUNICATION

# Lotus Birth Associated With Idiopathic Neonatal Hepatitis



Antonella Tricarico<sup>a</sup>, Valentina Bianco<sup>b</sup>, Anna Rita Di Biase<sup>b</sup>,  
Lorenzo Iughetti<sup>b</sup>, Fabrizio Ferrari<sup>a</sup>, Alberto Berardi<sup>a,\*</sup>

<sup>a</sup> Neonatal Intensive Care Unit, Department of Mother and Child, University Hospital, Modena, Italy

<sup>b</sup> Pediatric Unit, Department of Mother and Child, University Hospital, Modena, Italy

Received Jul 31, 2015; received in revised form Oct 3, 2015; accepted Nov 30, 2015

Available online 22 June 2016

## 1. Introduction

“Lotus Birth” (LB) is a holistic practice in which the umbilical cord is not cut after birth.<sup>1</sup> Drying and mummification of the umbilical cord usually leads to detachment from the baby’s navel a few days after birth. The UK Royal College of Obstetricians and Gynecologists in 2013 warned of the potential risks of LB practice.<sup>2</sup> It is unknown whether LB practice can increase the risks of the postpartum period or can lead to neonatal complications. Infections could spread to the baby, because at the postdelivery stage, the placenta has no circulation and is especially prone to infection. We describe the first case of a newborn with complicated LB delivery. The baby had persistent jaundice caused by idiopathic neonatal hepatitis that spontaneously recovered after the first months of life.

## 2. Case Report

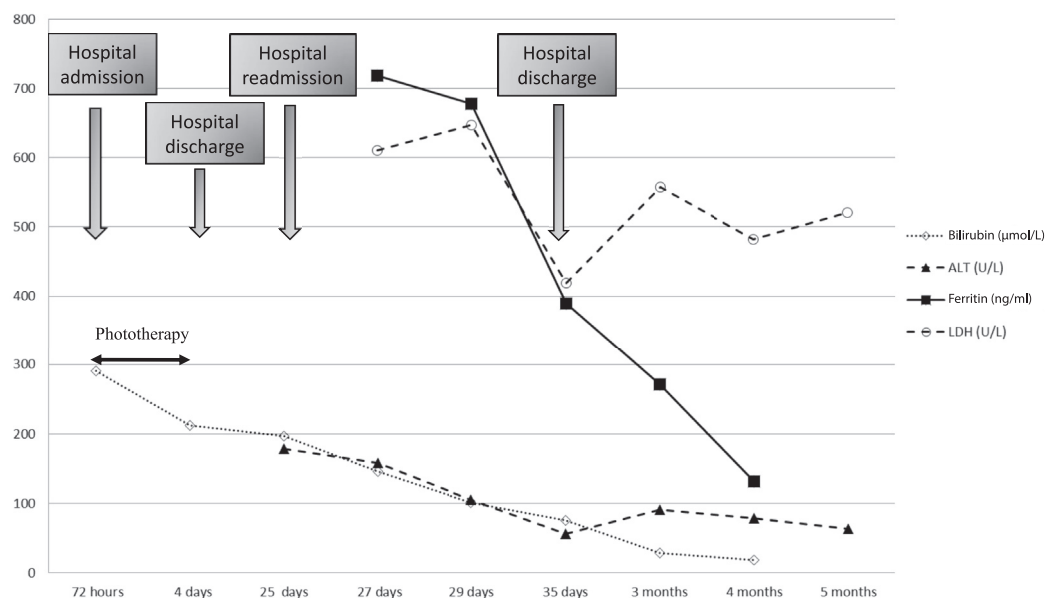
A 32-year-old Caucasian mother had a spontaneous home delivery at 40 weeks’ gestation. Group B streptococcus screening and serology for *Toxoplasma gondii*, rubella, cytomegalovirus, herpes simplex, and other viruses were

negative. The Apgar score (reported by the midwife) was 4 and 7 at 1 minute and 5 minutes, respectively; birth weight was 3400 g. As per the wishes of the parents, the umbilical cord was not clamped and cut. The midwife suggested that the placenta be kept in a bag at the same level as the newborn. The subsequent course after delivery was uneventful.

The baby was admitted to the hospital at age 72 hours because of jaundice [total serum bilirubin levels (capillary sampling): 291  $\mu\text{mol/L}$ , hematocrit 60%], lethargy, poor feeding and a slight increase in body temperature (37.4°C). On admission, the umbilical cord was cut and the neonate phototherapy was initiated. Bilirubin levels dropped to 212  $\mu\text{mol/L}$  after 6 hours. The temperature spontaneously normalized after admission and C-reactive protein levels yielded normal results. The newborn appeared well at the age of 4 days and was discharged home without further investigation. In the following days, the baby had poor feeding, insufficient weight gain, poor responsiveness and jaundice; therefore, he was readmitted to the emergency department at 25 days old (weight 3650 g). The newborn was wakeful but presented with a mildly enlarged liver. The family history was clinically uninformative and the mother reported a history of exclusive breastfeeding. Blood testing revealed raised values of alanine aminotransferase, serum ferritin, and lactate dehydrogenase and unconjugated hyperbilirubinemia (Figure 1). Both gamma-glutamyl transpeptidase (183 U/L) and bile acid levels (51  $\mu\text{mol/L}$ )

\* Corresponding author. Neonatal Intensive Care Unit, University Hospital, Via del Pozzo, 71–41124 Modena (MO), Italy.

E-mail address: [berardi.alberto@policlinico.mo.it](mailto:berardi.alberto@policlinico.mo.it) (A. Berardi).



**Figure 1** Changes in bilirubin, alanine aminotransferase, ferritin, and lactate dehydrogenase levels during the first months of life. ALT = alanine aminotransferase; LDH = lactate dehydrogenase.

were abnormal at admission but normalized within a few days. The direct Coombs test was negative (mother's blood Type A positive; infant's Type A negative, father's Type O negative). Serum immunoglobulin levels (*Toxoplasma gondii*, Epstein–Barr Virus, parvovirus, adenovirus, enterovirus), cytomegalovirus early antigen pp76, viral and bacterial cultures (blood, urine, and feces), reticulocyte count, clotting tests, ammonium, lactate, genetic test for Wilson's disease, thyroid function, and abdomen ultrasound studies were normal. Erythrocyte enzymes and alpha1-antitrypsin deficiency was excluded. The infant gained weight and laboratory tests were gradually improving when he was discharged home (37 days old). Mild hypertransaminasemia persisted up to the age of 18 months, when the liver function was normalized. At 3 years old, the child is well.

### 3. Discussion

A rise in unconjugated bilirubin levels during the first 2 weeks of life is common, particularly in breastfed neonates. Jaundice persisting beyond 14 days of life is less frequent and usually, further causes of jaundice must be excluded.<sup>3,4</sup>

In the present case, the infant presented with a complication of LB. There was a close temporal relationship between LB and the onset of clinical symptoms. The baby had persistent jaundice associated with a severe increase in aspartate and alanine aminotransferases without evidence of cholestasis. Recovery occurred spontaneously after the first months of life. Hepatobiliary, hematological, metabolic, endocrine, and genetic disorders were ruled out.

Laboratory data were consistent with "acute pure cytolytic syndrome", a form of hepatitis that reflects an acute isolated hepatocyte injury. Acute pure cytolytic

syndrome is characterized by severe increases in aspartate and alanine aminotransferases, with normal or moderately abnormal gamma-glutamyl transpeptidase.<sup>5</sup>

Although microbiological data was uninformative, clinical and laboratory data suggest that the cytolysis was due to an infection.

The present case suggests that LB may lead to neonatal hepatitis.

However, we do not know whether home delivery was a further source of complications of LB. The literature does not provide any data on the safety of LB. To ascertain whether LB is more frequently associated with neonatal complications than cutting of the umbilical cord, we have launched a prospective, multicenter study in our country.

### Conflicts of interest

Authors have no conflict of interest to declare.

### References

1. Buckley SJ. Lotus birth: a ritual for our times. *Midwifery Today Int Midwife* 2003;(67):36–8.
2. Royal College of Obstetricians and Gynaecologists 2013. RCOG statement on umbilical non-severance or "lotus birth." Available at <https://www.rcog.org.uk/en/news/rcog-statement-on-umbilical-non-severance-or-lotus-birth>. Accessed July 11, 2016.
3. Hannam S, McDonnell M, Rennie JM. Investigation of prolonged neonatal jaundice. *Acta Paediatr* 2000;**89**:694–7.
4. Banakar MK, Subbarayan A. A study of prolonged jaundice screen in healthy term babies. *Indian J Clin Biochem* 2008;**23**:286–9.
5. Whitehead MW, Hawkes ND, Hainsworth I, Kingham JG. A prospective study of the causes of notably raised aspartate aminotransferase of liver origin. *Gut* 1999;**45**:129–33.