

See discussions, stats, and author profiles for this publication at: <https://www.researchgate.net/publication/228501522>

A New Approach in the Management of Triangular Fossa Auricular Defects: The Posterior Auricular Artery Perforator Antihelix-Conchal Flap (PAAP Flap)

Article · January 2010

CITATIONS

0

READS

54

6 authors, including:



Alessio Baccarani

Università degli Studi di Modena e Reggio E...

36 PUBLICATIONS 479 CITATIONS

SEE PROFILE



Pietro Loschi

Azienda Ospedaliero Universitaria Policlinico...

23 PUBLICATIONS 91 CITATIONS

SEE PROFILE



Giorgio De Santis

Università degli Studi di Modena e Reggio E...

27 PUBLICATIONS 451 CITATIONS

SEE PROFILE

A New Approach in the Management of Triangular Fossa Auricular Defects: The Posterior Auricular Artery Perforator Antihelix-Conchal Flap (PAAP Flap)

Alessio Baccarani*, Antonio Pedone, Giovanna Petrella, Pietro Loschi, Barbara Pompei and Giorgio De Santis

Division of Plastic and Reconstructive Surgery, University of Modena and Reggio Emilia, Largo Pozzo 71, 41100 Modena, Italy

Abstract: *Background:* The reconstruction of extensive scapha or triangular fossa defects to the ear still represents a challenge considering the lack of local simple surgical procedures. *Objective:* To present a new perforator flap which is a modification of the Elsayh and Ladocsi chondrocutaneous rotation flaps. *Patients and Methods:* Ten patients, in whom the oncological resection to the triangular fossa did not include cartilage, but skin and perichondrium. Defects no larger than 3 cm in diameter were treated. The dissection of the flap was carried out from lateral to medial on the anterior sub-perichondrial plane. The flap was thus raised without the cartilage component but with the anterior perichondrium branched with the perforating vessels. *Results:* All flaps survived and treated patients presented good aesthetic results. *Conclusions:* We think that this procedure represents a valuable option to be considered in reconstructing well selected composite defects to upper ear.

Keywords: Ear reconstruction, triangular fossa, perforator flaps.

INTRODUCTION

Reconstruction of extensive scapha or triangular fossa defects to the ear after malignancy resection may still

procedures. In 1985 Dr. Elsayh from Atlanta described a rotation-advancement composite flap from the antehelix, which included skin, perichondrium and cartilage [1]. In

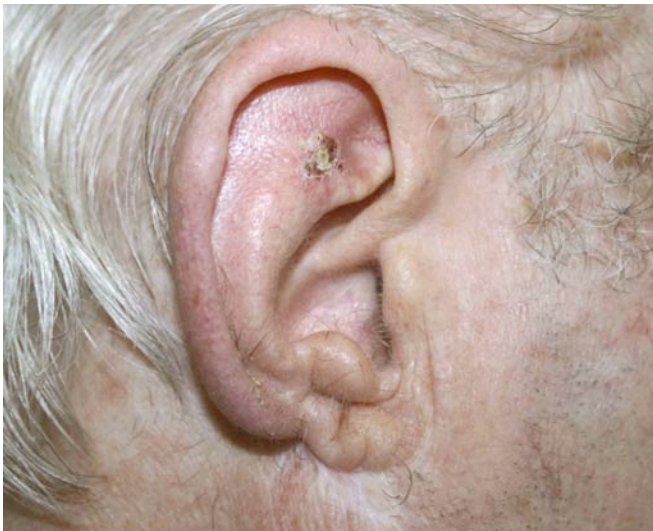

Fig. (1). Squamous-cell carcinoma involving the right ear triangular fossa.

represent a challenging problem for the plastic or maxillo-facial surgeon. Over the years just a few specific local reconstructive techniques have been proposed as possible

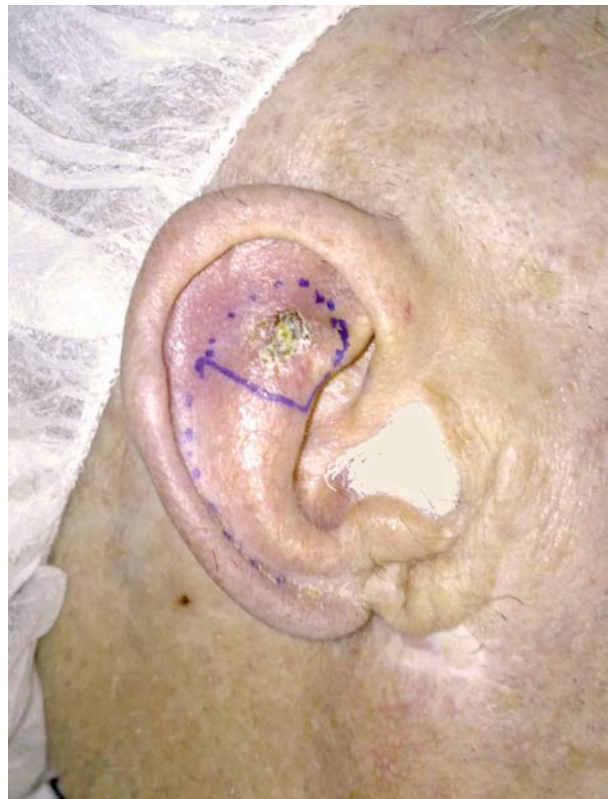

Fig. (2). Pre-operative planning including malignancy resection and flap design.

*Address correspondence to this author at the Division of Plastic and Reconstructive Surgery, University of Modena and Reggio Emilia, Largo Pozzo 71, 41100 Modena, Italy; Tel: +39 059 422 3692; Fax: +39 059 422 2454; E-mail: alessio.baccarani@unimore.it

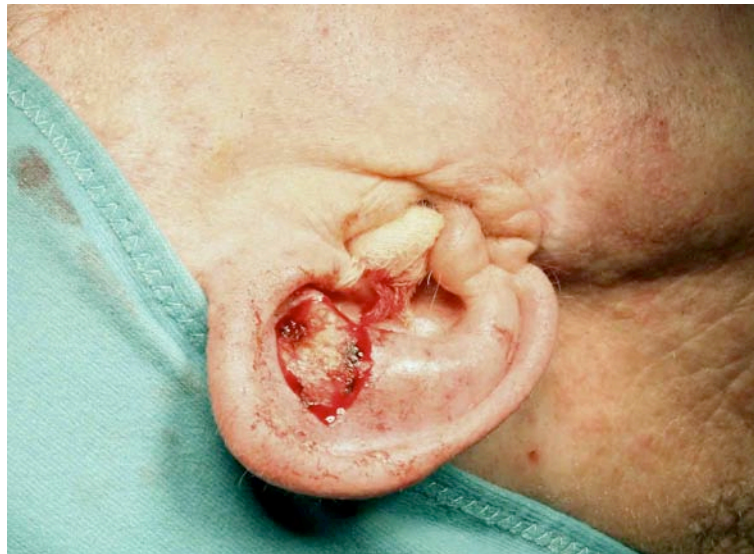

Fig. (3). Composite skin and perichondrium defect after malignancy resection.

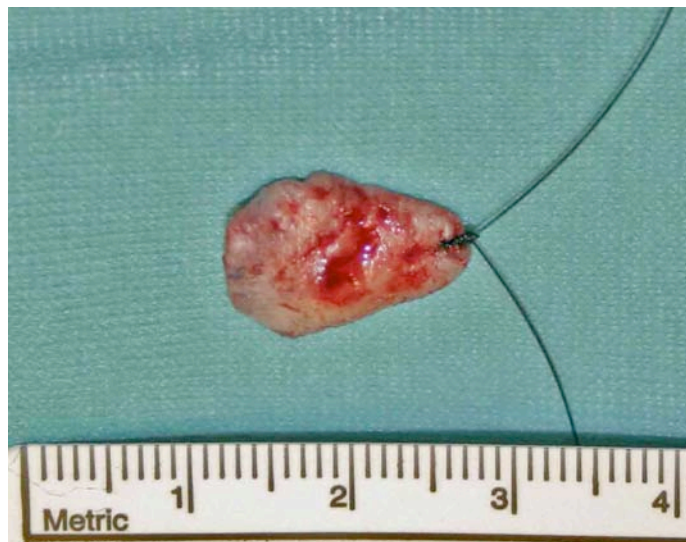

Fig. (4). Resected specimen (two cm diameter approximately).

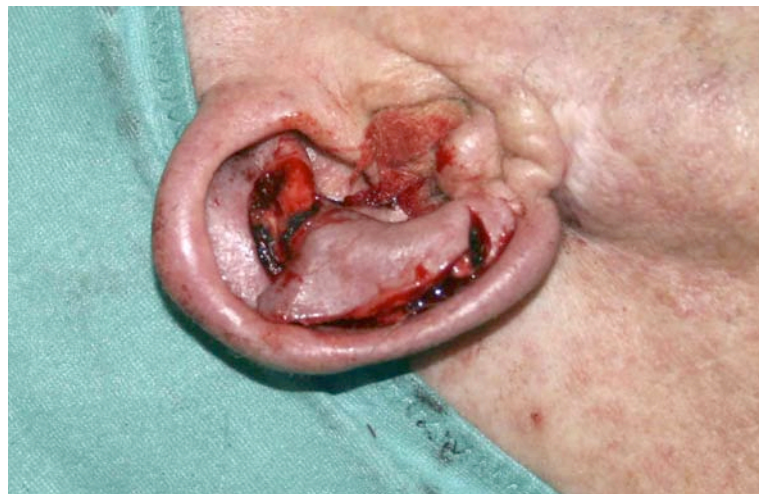

Fig. (5). Harvested PAAP flap.

2003 Dr. Ladocsi introduced the concept of a chondro-cutaneous rotation flap supplied by perforating branches of

the posterior auricular artery, which provide vasculature to the anterior surface of the ear [2].

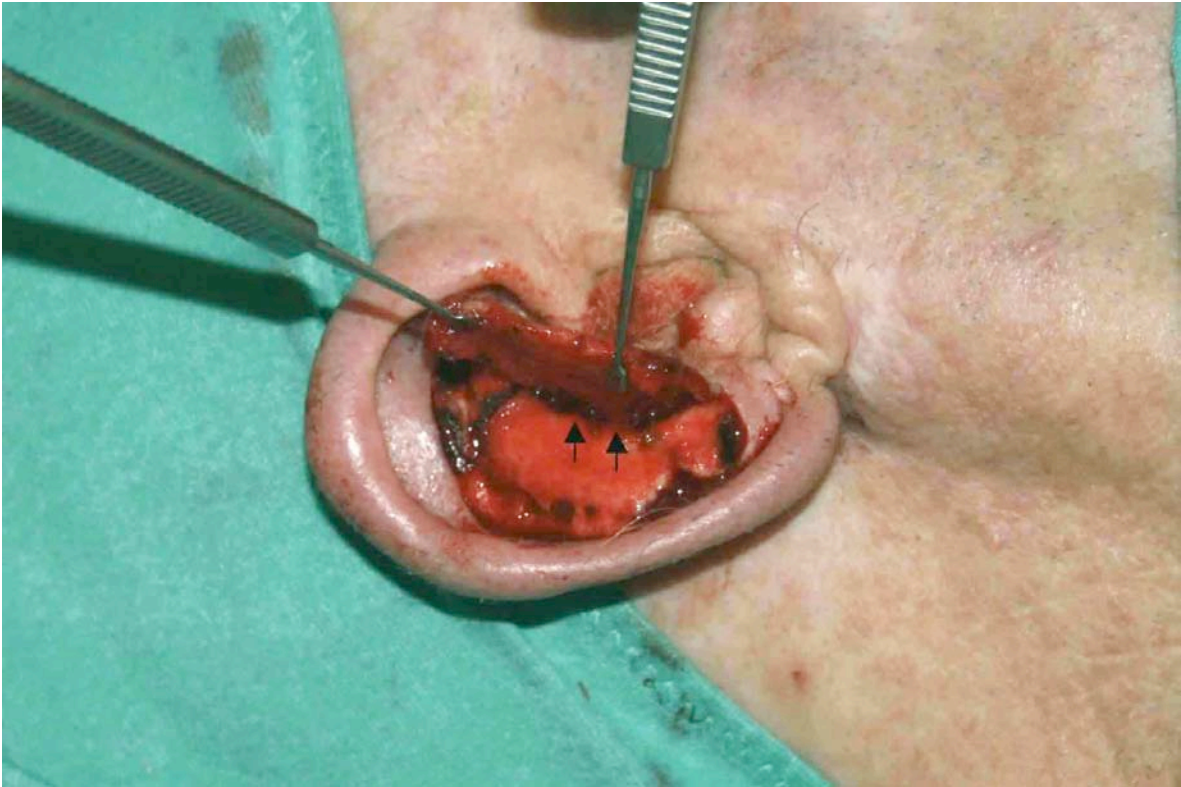


Fig. (6). Harvested PAAP flap anteriorly reflected. Arrows outline two posterior auricular artery perforator vessels.

A new flap, which represents a technical modification of that procedure is presented herein. Defects no larger than 3 cm in diameter represent the ideal target for this new approach. After malignancy resection being carried out in a triangular fashion (Figs. 1-4), a gentle curved incision is taken along the anthelix toward the lobe in the lower portion of the ear (Fig. 5). The dissection of the flap is carried out from lateral to medial on the anterior sub-perichondral plane. The flap is therefore raised without the cartilage component which is left unscarred and attached to the posterior auricular skin.

Few fine perforating vessels are visible medially (Fig. 6), piercing the cartilage and branching within the anterior perichondrium which has to be included in the flap.

The aforementioned careful blunt dissection on the sub-perichondral plane is thus performed paying attention not to injury the fine perforating vessels.

Microsurgical instruments, loops or other magnification devices are mandatory to approach this critical step. Microsurgical technical skills are required.

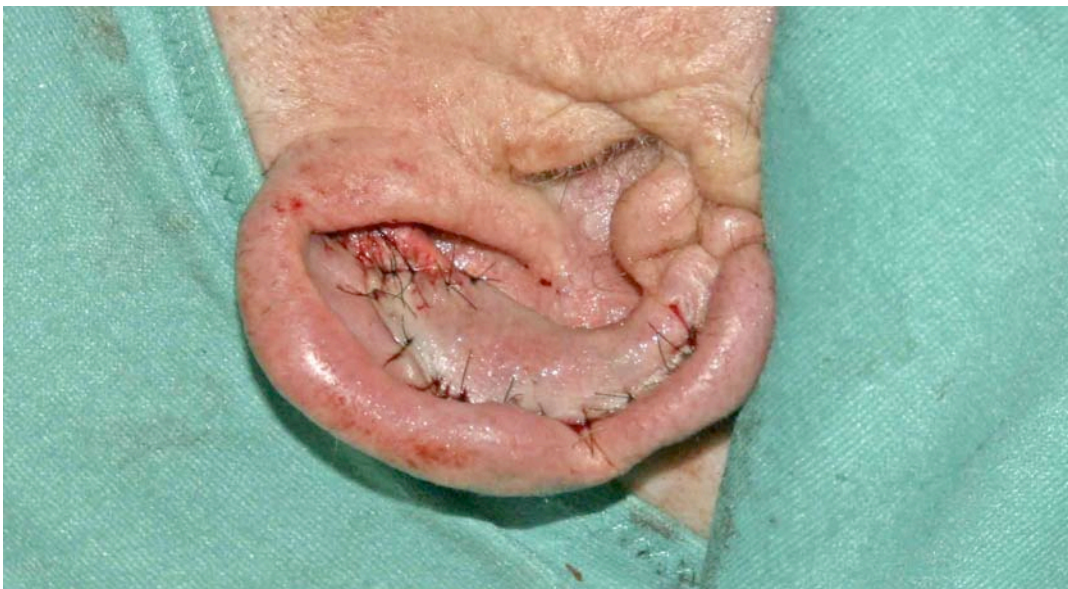

Fig. (7). Early post-op view showing adequate defect coverage.

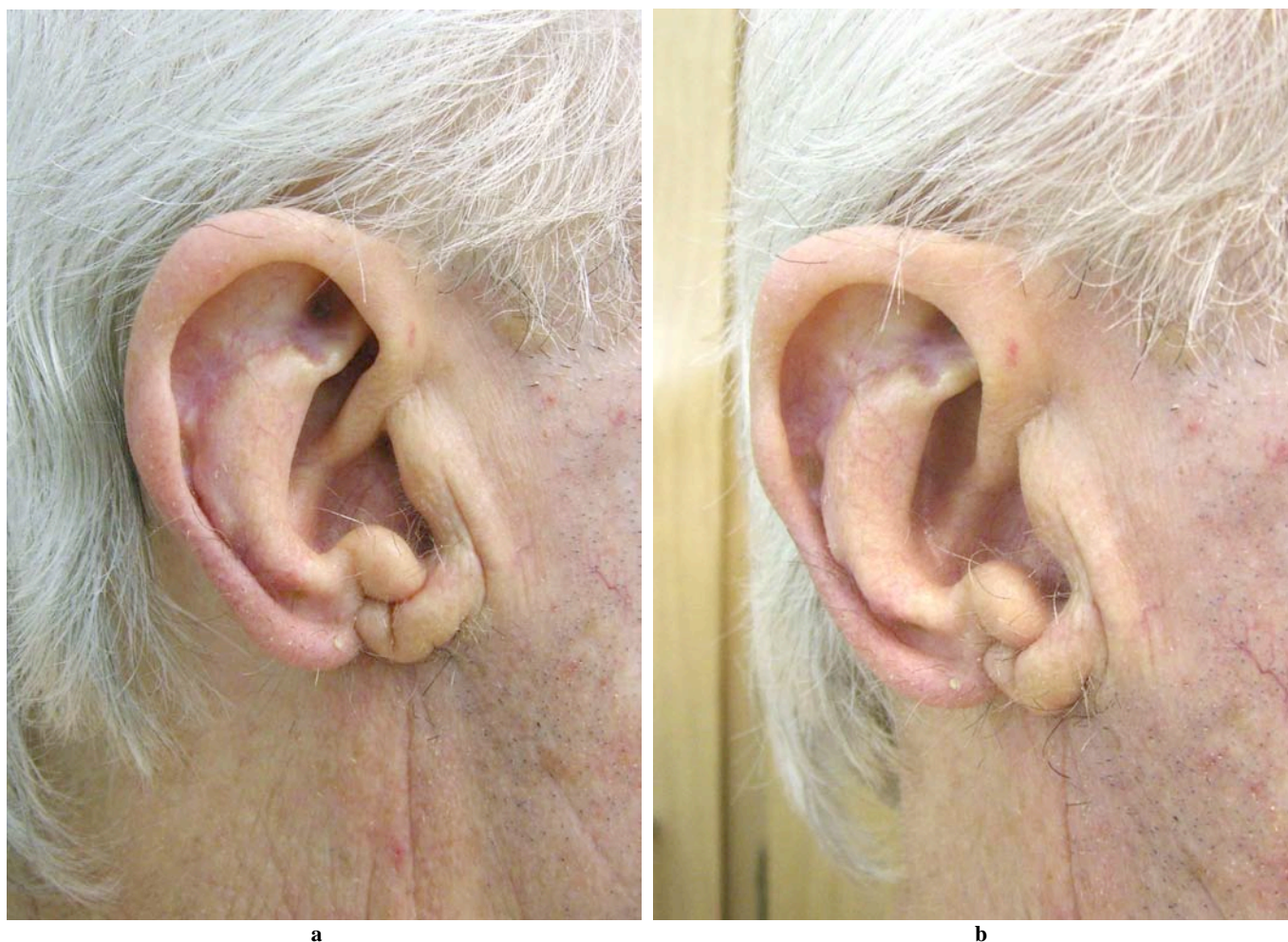


Fig. (8). (a, b). One year post-op follow-up.

In order to obtain a better rotation of the flap, a back cut is performed toward the root of the helix once the perforating vessels have been visualized and secured (Fig. 5).

A thin skin pedicle may or may not be left attached according to the reconstructive need for a comfortable rotation to the defect and a closure free from tension.

The advantages of the presented technique, if compared to the previously described chondrocutaneous rotation flaps, rely on the absence of cartilage resection, which may ultimately lead to distortion of the ear in shape and size.

On the other hand leaving the cartilage unscarred represents a limitation in terms of the size of the defect that may be reconstructed with the presented perichondrocutaneous flap. Moreover the presence of perichondrium in the flap further limits its capability to be stretched during rotation.

The flaps described by Dr. Elsahy and Dr. Ladocsi, being harvested as one single composite (cartilage and skin) unit,

allow for closure of a wider pattern of defects to the upper ear.

The presented technique has been successfully used in 10 cases in which the oncological resection to the triangular fossa did not include cartilage, but skin and perichondrium as shown in Figs. (3-8). However we think that the same procedure may also be qualified in managing composite full thickness anterior-skin and cartilage defects.

In conclusion the posterior auricular artery anthielix-conchal flap (PAAP flap) is to be considered a reliable option in managing well-selected defects to the upper ear.

REFERENCES

- [1] Elsahy NI. Ear reconstruction with rotation-advancement composite flap. *Plast Reconstr Surg* 1985; 75(4): 567-8.
- [2] Ladocsi L. Perforator-preserving chondrocutaneous rotation flap reconstruction of auricular defects. *Plast Reconstr Surg* 2003; 112(6): 1566-72.