

Choledochocele: Choledochal Cyst Ora Distinct Entity?

Francesca Pecchini^[a]; Barbara Catellani^[a]; Sara Acciuffi^[a]; Roberta Gelmini^{[a],*}

^[a]Surgery, University of Modena and Reggio Emilia, Modena, Italy.
*Corresponding author.

Received 15 November 2014; accepted 24 January 2014
Published online 24 February 2015

Abstract

Choledochocele represents a cystic dilatation of the distal common bile duct and it's included in Todani's classification as type III choledochal cysts. We report a case of a 66-years-old man who presented a suspected gallbladder lithiasis with colic abdominal pain, vomit, fever, jaundice and abnormal liver function tests. However the endoscopic retrograde cholangio-pancreatography revealed the absence of stones in the common bile duct and the presence of a 15mm-wide choledochocele that was successfully treated with an endoscopic sphincterotomy. Additionally a comprehensive review of the literature of the last 15 years was performed, collecting 105 cases of choledochocele. The available data were classified in 10 variables and subsequently analysed. Summarizing all data, we noticed that choledochocele presents different characteristics if compared with other types of choledochal cysts: The population affected is older, there isn't a strong female prevalence, the most frequent manifestation is pancreatitis instead of jaundice and cholangitis, the association with anomalous pancreato-biliary duct junction is rare and the risk of malignancy is lower. The standard for the diagnosis is endoscopic retrograde cholangio-pancreatography instead of magnetic resonance cholangio-pancreatography and the most accepted treatment is endoscopic sphincterotomy in order to allow the correct outflow of the biliary juice. In conclusion, even if choledochocele is commonly considered a type of cystic dilatation of the common biliary duct and it is usually included in the choledochal cysts classification, it has to be considered as a distinct entity with its own features.

Key words: Choledochocele; Type III; Choledochal cyst

Pecchini, F., Catellani, B., Acciuffi, D., & Gelmini, R. (2015). Choledochocele: Choledochal Cyst Ora Distinct Entity?. *Canadian Social Science*, 2(1), 1-8. Available from: <http://www.cscanada.net/index.php/css/article/view/5290>
DOI: <http://dx.doi.org/10.3968/5290>

INTRODUCTION

Choledochocele is a cystic dilatation of the intraduodenal portion of the common bile duct (CBD) and it protrudes into the duodenal lumen. It was first described by Wheeler et al¹ in 1940 and, according to the Alonso and Todani's classification (Figure 1)^[2-3], it is considered as a type III choledochal cyst (CC). Despite choledochocele is described as the rarest subtype of CC, representing less than 5% of all reported cysts^[4-5], recent studies observed an increasing incidence of choledochocele in the last years, probably due to the improvement of imaging techniques and to the growing experience with endoscopic procedure^[6-7].

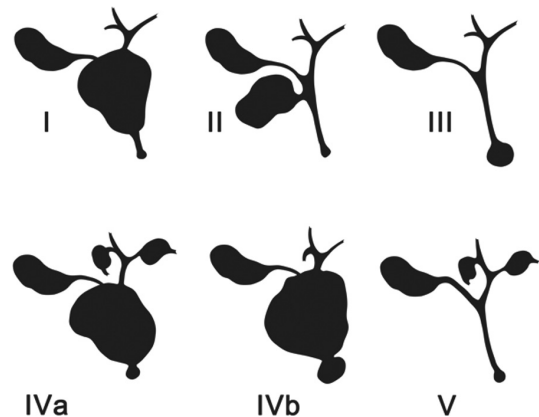


Figure 1
Biliary Cysts's Classification

Note. Type 1: solitary fusiform extrahepatic cyst. Type 2: extrahepatic supraduodenal diverticulum. Type 3: intraduodenal diverticulum (Choledochocele). Type 4a: fusiform extra and intrahepatic cyst. Type 4b: multiple extrahepatic cysts. Type 5: multiple intrahepatic cysts (Caroli's Disease)

On the basis of the observations of Scholz et al.,^[8] Sarris et al.^[9] proposed an anatomic classification by subdividing choledochoceles into type A and type B (Figure 2). In type A, that is the most frequent variety, the ampulla opens into the choledochocele which, in turn, communicates with the duodenum through an own small orifice. In type B the ampulla empties directly into the duodenum and the choledochocele represent a diverticulum of the distal common bile duct protruding into the duodenal lumen. In addition Antaki et al.^[10] recently differentiated choledochocele from duodenal duplication: the first one, lined with biliary mucosa, appears as a dilatation proximal to the papilla. In contrast, duodenal duplication is lined by duodenal mucosa and it protrudes distally to the papilla sharing a portion of its circumference with the duodenal wall. More variants of choledochocele were described by Kagiya et al.^[11] on the basis of endoscopic retrograde cholangio-pancreatography (ERCP) findings.

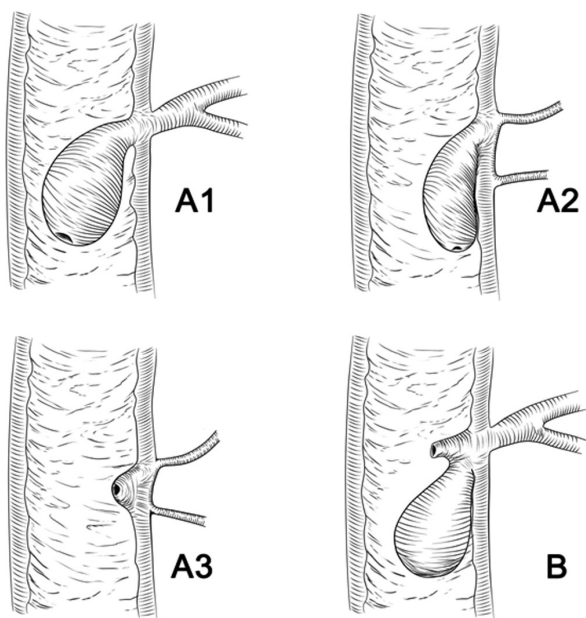


Figure 2
Classification of Choledochocel

Note. Type A₁: a common opening of pancreatic duct (PD) and CBD into the cyst. Type A₂: distinct opening of PD and CBD. Type A₃: small and intramural choledochocele. Type B: the ampulla empties into the duodenum and the choledochocele represents a diverticulum of the distal common bile duct.

The etiology is still debated: both congenital and acquired origins are proposed. Some authors describe choledochocele as an abnormal embryonic development^[8, 12-13], others consider dysfunction of the sphincter of Oddi, papillary stenosis or inflammation and reflux of pancreatic juices as the main cause of the common bile duct dilatation.^[1, 8, 14-15]

We present a case of choledochocele initially interpreted as a choledocholithiasis and then recognized by ERCP and treated with an endoscopic sphincterotomy

(ES). A systematic review of the literature referred to choledochocele cases was also performed, in order to highlight its clinical, diagnostic and therapeutic aspects. It's our aim to draw attention to the differences that occur between choledochocele and Todani types I, II, IV and V choledochal cysts, to demonstrate that choledochocele is a distinct entity.

CASE REPORT

A 66 years old man treated with antihypertensive drugs and affected by known gallbladder lithiasis, was admitted to our Emergency Room for colic abdominal pain associated with nausea, alimentary vomit and fever. At the physical examination his skin and sclera were yellow-stained and he had tenderness in the right hypochondrium and was positive for Murphy's sign. The blood tests showed abnormal liver function: aspartate transaminase 594 U/L [normal 2-37 U/L], alanine transaminase 551 U/L [normal 2-40 U/L], gamma-glutamyltranspeptidase 493 U/L [normal 11-50 U/L]. The patient had a mild jaundice with a total bilirubin of 2.54 mg/dL [normal 0.20-1.20 mg/dL] and direct bilirubin of 1.62 mg/dL [normal <0.3 mg/dL]. Alkaline phosphatase was normal such as pancreatic function tests; a moderate leucocytosis was present. An upper abdominal ultrasonography highlighted a thick-walled gallbladder with a 2 cm unique stone and a mild dilatation of intra and extra-hepatic bile ducts (common bile duct diameter was 9 mm). The observation of the gallstone associated with the presence of the jaundice and the biliary symptoms suggested an initial diagnosis of choledocholithiasis. Therefore an ERCP was performed and it showed a protruding mucosa fold covering the major papilla. The catheterization of the papilla and the filling with contrast medium didn't show any stones in the CBD but highlighted a saccular dilatation of the distal common bile duct of about 15 mm referring to choledochocele type A (Figures 3 and 4). An endoscopic sphincterotomy was carried out to unroof the superior part of the intramural segment of the choledochocele; in addition several biopsies of the mucosa were performed. The histopathological examination revealed normal tissue. Four days after ES the patient underwent a trans naso-biliary tube cholangiography that showed a reduction of the biliary ducts dilatation, the resolution of the choledochocele and it confirmed the gallstones. For this reason, after three days the patient underwent a laparoscopic cholecystectomy. The postoperative recovery was uneventful and two days after surgery the patient was discharged. Ten days and 13 months after surgery the patient underwent a magnetic resonance cholangio-pancreatography that showed the complete resolution of the choledochocele (Figure 5). At a four years follow-up the patient is clinically asymptomatic and in good health.

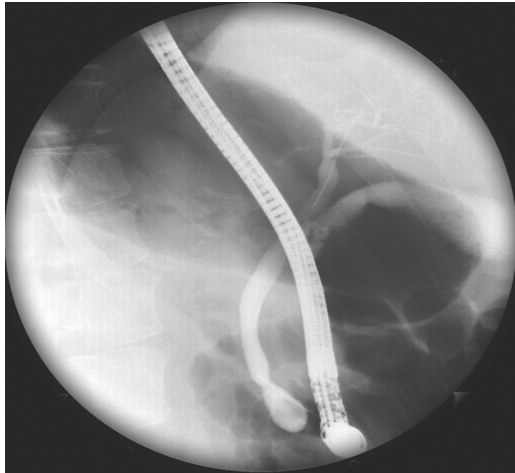


Figure 3
Endoscopic Retrograde Cholangio-Pancreatography and Opacification of the Biliary Tree With Contrast Medium That Shows the Dilatation of Terminal Common Bile Duct (Choledochoceles)

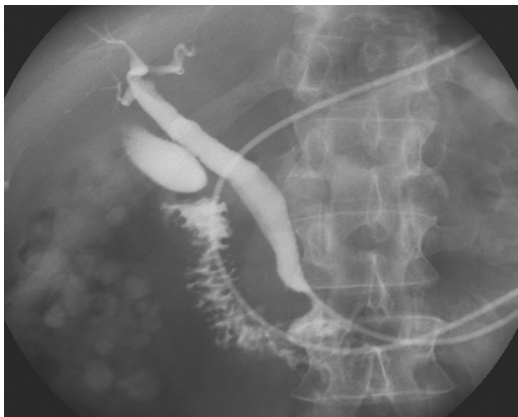


Figure 4
Endoscopic Retrograde Cholangio-Pancreatography and Opacification of the Biliary Tree With Contrast Medium That Shows the Dilatation of Terminal Common Bile Duct (Choledochoceles)

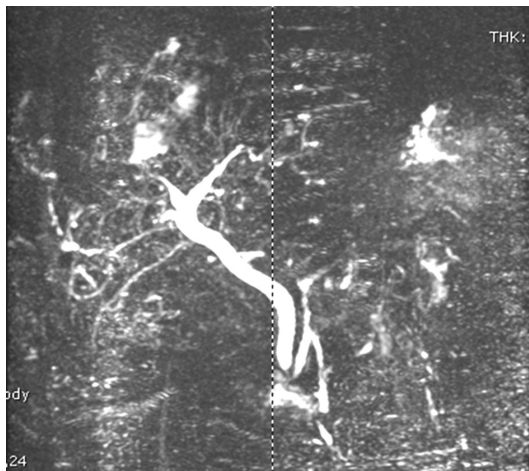


Figure 5
Magnetic Resonance Cholangio-Pancreatography That Shows the Complete Resolution of the Choledochocoeles 13 Months After Surgery

SYSTEMATIC REVIEW

Material and Methods

A systematic research of medical literature was performed on PubMed MEDLINE. We considered articles written in all languages other than Russian and Chinese, both case-reports and internal reviews, directly relevant to type III choledochal cysts. Moreover we excluded papers describing an exclusive or prevalent pediatric series and we limited our search starting from the year 2000, focusing on the newest series described in the last 15 years. In total, 28 publications resulted and 22 of these offered detailed data available for the review. Therefore we finally collected 105 cases of choledochocoele. For each case we considered 10 variables: Age, gender, clinical manifestation, comorbidities, diagnostic technique, treatment, size, complications, hospital stay and months of follow up. All the data were compared and analysed; when necessary we used the mean values and standard deviation.

RESULTS

Since year 2000, 105 cases of choledochocoele in adult patients were described in literature (Tables 1 and 2). In 19 cases (18%) the gender wasn't reported. Of the remaining cases 33 (38%) were male, 53 (62%) were female; the mean patient's age was 51 (\pm 20.2), with a range between 21-77 years.

Abdominal pain and pancreatitis were the main clinical manifestations, respectively in 54% and 28% of patients; five of these patients presented relapsing pancreatitis. Other common symptoms were nausea and vomit (12%), jaundice (10%) and cholangitis (6%). Three patients presented with cholecystitis, other two with recent weight loss, and an abdominal mass was found in one case. Different comorbidities were described in many patients: choledocholithiasis (24%), cholecystolithiasis (16%), anomalous pancreato-biliary duct junction (APBDJ, 16%), pancreas divisum (13%). Five cases presented with biliary or pancreatic stricture, and in two cases other types of CC were found. At the time of choledochocoele's diagnosis a total of nine patients (10%) resulted in a neoplastic affection, of which seven cases (7,8%) were malignant neoplasia: one pancreatic adenocarcinoma, two gallbladder cancers and four cholangiocarcinomas.

All patients underwent at first an Ultrasound examination (US) but it was always followed by further diagnostic techniques. ERCP was performed in 103 cases (98%) and it was always diagnostic. In addition to ERCP, magnetic resonance cholangio-pancreatography (MRCP) was performed in ten patients and computed tomography (CT) scan in six. In two patients the diagnosis was obtained only with MRCP. Endoscopic ultrasonography (EUS) was performed in one patient. The mean

choledochocele size of dilatation, described only in eight cases, was 36 mm (range 14-50).

As shown in Table 2, the treatment mainly performed for choledochocele was ES (92%): It failed in seven cases and a surgical approach was then required because of bleeding or for difficult visualization that didn't

permit the cannulation of Vater's papilla. In six cases (6%) an open surgery was chosen since the beginning: One patient underwent a pancreaticoduodenectomy (Whipple procedure), one patient underwent an excision of the cyst followed by cholecystectomy and Roux-en-Y choledochojunostomy and in one case a cholecysto-

Table 1
Review of literature: Patient population, Symptoms, Signs, Comorbidities, Diagnosis

Author	N°pts	Sex (f/m)	Median Age	Clinical manifestations	Comorbidities	Diagnostic technique
Zhu L et al, 2014 ⁴⁵	1	F	75	abdominal pain, nausea/vomiting, pancreatitis	choledocholithiasis, biliary stricture	CT, ERCP
Popova-Jovanovska R et al, 2012 ³⁹	1	F	60	abdominal pain, jaundice	biliary neoplasm	MRCP, ERCP
Garrido A et al, 2012 ⁴⁶	1	M	77	abdominal pain, nausea/vomiting, cholangitis	pancreas divisum	ERCP
Ulas M et al, 2012 ²⁸	3	n.a.	n.a.	abdominal pain, cholangitis	no	ERCP
Ziegler KM et al, 2010 ⁶	28*	16/12	50.7	abdominal pain (67%), pancreatitis (46%) nausea/vomiting (18%), jaundice (11%), weight loss (7%), abdominal mass (4%)	APBDJ (50%), pancreas divisum (39%), biliary stricture (11%), pancreatic stricture (4%), biliary neoplasm (7%), pancreatic neoplasm (7%)	ERCP
Martinez-Ordaz JL et al, 2010 ⁴⁷	3	n.a.	n.a.	abdominal pain	n.a.	ERCP
Wang QG et al, 2009 ⁴⁸	1	F	66	abdominal pain, pancreatitis, jaundice, cholecystitis	cyst type I	ERCP
Gordon SR et al, 2009 ⁴⁹	1	F	23	Pancreatitis	no	EUS, ERCP
Uribarrena Amezaga R et al, 2008 ⁵⁰	1	n.a.	44	abdominal pain, recurrent pancreatitis	no	CT, ERCP
Berger A et al, 2007 ³¹	1	M	70	abdominal pain, nausea/vomiting	cholecysto-choledochal lithiasis	ERCP
Can MF et al, 2006 ⁵¹	1	M	21	abdominal pain, nausea/vomiting	no	CT, MRCP, ERCP
Horaguchi J et al, 2005 ²⁵	21	14/7	68.5	abdominal pain (57%), pancreatitis (19%), jaundice (10%), cholecystitis (5%)	choledocholithiasis (43%), cholecystolithiasis (38%), gallbladder carcinoma (10%), cholangiocarcinoma(5%)	ERCP
Safioleas MC et al, 2005 ⁵²	1	F	n.a.	n.a.	cholecystolithiasis	ERCP
Garcia-Cano J et al, 2005 ⁵³	1	M	57	abdominal pain	no	ERCP
Park DH et al, 2005 ⁵⁴	11	n.a.	n.a.	n.a.	n.a.	ERCP(100%), MRCP (73%)
Naga MI et al, 2004 ⁴⁰	2	0/2	50.5	jaundice, cholangitis	no	ERCP
Jordan PH et al, 2004 ⁵⁵	1	n.a.	n.a.	no	n.a.	ERCP
Katsinelos P et al, 2003 ^[36]	2	2/0	59.5	abdominal pain, recurrent pancreatitis	no	CT, ERCP
Rabie ME et al, 2002 ^[56]	1	M	25	abdominal pain	biliary mud	CT, ERCP
Park KB et al, 2001 ^[24]	21	14/7	67	recurrent pancreatitis (10%)	choledocholithiasis (48%), colecystolithiasis (19%), Klatskin tumour (5%), cyst type I (5%)	ERCP
De Backer AI et al, 2000 ^[26]	1	F	22	abdominal pain, nausea/vomiting, pancreatitis, cholecystitis	no	MRI, MRCP
Adamek HE et al, 2000 ^[27]	1	F	25	abdominal pain, nausea/vomiting	no	MRCP

Note. N°pts number of patients; f female; m male; APBDJ anomalous pancreato-biliary duct junction; EUS endoscopic ultrasonography; n.a. not available, *including 3 pediatric cases.

duodenectomy with marsupialization of the cyst was carried out. In three patients the surgical procedure was not described. There were no post-operative complications in the available data and the mean hospital stay was 1 day for ES and 14 days for surgery. Two cases didn't undergo

any invasive procedures: One case was asymptomatic therefore was not treated with surgical neither with medical therapy and one patient received only medical therapy to resolve the pancreatitis and refused further invasive procedures.

Table 2
Review of literature: Treatment, Complications and Follow Up

Author	N°pts	Treatment	Size (mm)	Complications	Hospital stay (days)	FOLLOW UP (months)
Zhu L et al, 2014 ^[45]	1	ES	n.a.	no	n.a.	n.a
Popova-Jovanovska R et al, 2012 ^[39]	1	Pancreatico-duodenectomy	50	no	n.a.	60
Garrido A et al, 2012 ^[4]	1	ES	n.a.	no	n.a.	6
Ulas M et al, 2012 ^[28]	3	ES	<30	no	n.a.	n.a.
Ziegler KM et al, 2010 ^[6]	28*	ES (68%), ES+open surgery (21%), open surgery (11%)	n.a.	n.a.	7	41
Martinez-Ordaz JL et al, 2010 ^[47]	3	ES	n.a.	no	n.a.	48
Wang QG et al, 2009 ^[48]	1	Cystectomy + cholecystectomy with Roux-en-Y choledocho-jejunostomy	n.a.	no	20	n.a.
Gordon SR et al, 2009 ^[49]	1	ES	20	no	1	3
Uribarrena Amezaga R et al, 2008 ^[50]	1	ES	n.a.	no	n.a.	36
Berger A et al, 2007 ^[31]	1	ES	40	no	n.a.	6
Can MF et al., 2006 ^[51]	1	ES + duodenotomy	50	no	n.a.	2
Horaguchi J et al., 2005 ^[23]	21	ES	6	n.a.	n.a.	n.a.
Safioleas et al., 2005 ^[52]	1	ES	n.a.	no	n.a.	54
Garcia-Cano et al., 2005 ^[53]	1	ES	n.a.	no	n.a.	24
Park et al., 2005 ^[54]	11	ES	n.a.	n.a.	n.a.	36
Naga et al., 2004 ^[40]	2	ES	n.a.	no	n.a.	36
Jordan et al., 2004 ^[55]	1	Not treated	n.a.	n.a.	n.a.	n.a.
Katsinelos et al., 2003 ^[36]	2	ES	n.a.	no	11	18
Rabie et al., 2002 ^[56]	1	Duodenectomy + cyst marsupialization + cholecystectomy	50	no	n.a.	8
Park et al., 2001 ^[24]	21	ES	n.a.	n.a.	n.a.	n.a.
De Backer et al., 2000 ^[26]	1	Medical therapy for pancreatitis	n.a.	no	n.a.	n.a.
Adamek et al., 2000 ^[27]	1	ES	n.a.	no	n.a.	6

Note. N°pts number of patients; ES endoscopic sphincterotomy; mm millimeter; n.a. not available, *including 3 pediatric cases.

The mean follow-up time was 26 months (range 2-60). Among all studies, 14 reported long-term outcomes after treatment: 84% of these patients had a complete resolution of symptoms and didn't show clinical or endoscopic recurrence. Two patients (4.5%) developed biliary tumour (one cholangiocarcinoma and one ampullar carcinoma) at 36 and 53 months after the sphincterotomy. Both patients died 3 months after diagnosis. Five patients (11%) died for unknown reasons.

DISCUSSION

The present study is a review concerning the peculiar features of choledochocele obtained by the most recent international literature. Summarizing all data we first noticed that demographic characteristics of choledochocele differ from those of other types of cysts: We obtained a sex ratio of 1,6:1 that is notably lower than the one reported in the literature for all CC (4:1)^[5], in addition our mean age was 51 years according with Law et al.⁷ who reported the same mean age confirming that the population presenting choledochocele is substantially

older than the one affected by other type of CC (mean age 29 years^[7]).

Even the clinical manifestations are peculiar: whereas CDC is frequently associated with obstructive jaundice and cholangitis, the most frequent clinical manifestation of choledochocele, beside an aspecific abdominal pain, was pancreatitis that regarded 28% of patients with which the 19% presented relapsing pancreatitis. Previously Sarris et al.^[9] and Masetti et al.^[16] in two large reviews published respectively in 1988 and 1996, reported an incidence of pancreatitis associated with choledochocele that reached the value of 38%. The pathogenesis of this occurrence was first proposed in 1980 when Goldberg et al^[17]. suggested that the increased ductal pressure and the biliary reflux caused by the cystic dilatation could determine an obstruction of the pancreato-biliary outflow. Nowadays it still remains the most accepted hypothesis and some authors even identify choledochocele as a cause of recurrent pancreatitis^[18].

Anomalous pancreato-biliary duct junction (APBDJ) occurs in 50% to 80% of patients^[5] with choledochal cyst especially in type I and IV^[7]. APBDJ is defined as a

common channel greater than 15-20 mm or as a junction between the pancreatic and biliary ducts outside the duodenal wall^[19-20]. Ziegler et al.^[6] observed that APBDJ are significantly less frequent in choledochocoele than in other cysts. According to this finding APBDJ was detected in only 16% of all cases reviewed demonstrating that the association between choledochal cysts and APBDJ is well established for all types of CDC except for choledochocoele. This observation is important since one third of patients with APBDJ present a biliary neoplasia.^[20] APBDJ is considered as an independent risk factor for the onset of tumour in the biliary tract because the pancreato-biliary reflux causes a chronic inflammation of the tissue and the development of the sequence hyperplasia-dysplasia-carcinoma^[21-22]. Therefore it's not surprising that the incidence of cholangiocarcinoma in our series is lower than the one associated with other type of cysts reported in literature (4% versus 10%-30%^[5,21]).

Many different criteria for the diagnosis of choledochocoele are reported in literature^[23-25], but a lack of a univocal definition is still present. Moreover no minimum diameter of the cystic dilatation has been defined but the general assumption is that choledochocoele's size should be at least 1 cm, otherwise it is considered as a simple dilatation of the common biliary channel.

Since the majority of patients of our cohort initially presented upper abdominal pain, US was the first diagnostic tool used but it never allowed to reach the diagnosis because the cysts were too small to visualize. Nevertheless it offered important information about the presence of gallbladder stones, dilatation of the biliary tree and the presence of inflammation or neoplasia. Cross-sectional imaging like MRCP was scarcely used: It was successfully diagnostic in only two patients^[26-27] since in the other cases they were always followed by endoscopy. Even if MRCP is considered the gold standard for the investigation of all type of choledochal cysts^[22, 28], ERCP is the most accurate and accepted technique for the diagnosis of choledochocoele with a reported sensitivity of 97%^[16]. It is considered the most precise method showing the localization and extension of the cyst, and it can confirm the presence or absence of APBDJ.^[29-30] For these reasons, and because it permits the definitive management of the disease, endoscopy remains the most widely diagnostic and therapeutic tool used.

Historically surgical treatment was considered the standard management to excise potentially premalignant tissue from CDC^[7]. This therapeutic strategy is now rarely used in the treatment of choledochocoele and has been progressively replaced by endoscopic management. The lower risk of malignancy arising in choledochocoele justifies the use of this more conservative technique.^[31-32] Endoscopic sphincterotomy (ES) as a therapy for choledochocoele was first described by Dehyle and Meyer

in 1974^[33] followed by Siegel et al.^[34] and Nagasawa et al.^[35] and it consists in the incision of the mucosal tissue roofing the cyst with a sphincterotome^[36]. This procedure allows the drainage of the biliary stagnation, which is supposed to be partly responsible for the degeneration of the cyst^[37]. For this reason, given the possibility that pancreatic and biliary secretions can mix within the cystic dilatation and create a precancerous state, sphincterotomy is recommended even in asymptomatic patients^[38]. In our study, the 92% of patients underwent an endoscopic sphincterotomy with a failure in only 7% of cases, demonstrating that this approach is safe, feasible and it's accepted to be the treatment of choice for choledochocoele.

There are controversial opinions about the need for a long-term follow up considering that choledochocoele seldom co-exists with carcinoma. Even though the risk of malignant degeneration of the biliary tract demonstrated to be relatively low if compared with other type of cysts, at the time of diagnosis the total incidence of associated benign and malignant neoplasia of the biliary and pancreatic tissue reached the value of 10%. In addition 4.5% of the population presented a biliary tumour a long time after ES. Therefore, as several Authors previously suggested^[7, 39-42], we propose that a long-term surveillance may be done and it should include periodic endoscopy and mucosal biopsies to definitely exclude a possible malignancy.

Choledochocoele has been always included in Todani's classification as type III choledochal cyst but several authors^[6-7, 23-43], beginning from Wearn et al.^[44] in 1982, suggested to exclude it from the group of choledochal cysts. The aim of this review was to discuss this possibility and, on the basis of the peculiar demographics data and clinical presentation, the lower risk of malignancy and the different standard procedure for diagnosis and treatment, choledochocoele should be considered as a distinct pathological entity with its own features even if included in choledochal cysts classification.

REFERENCES

- [1] Wheeler, W. (1940). An unusual case of obstruction to the common bile duct (choledochocoele?). *Br J Surg*, 27, 446-448
- [2] Alonso, L. F., Rever, W. B., & Pessagno, D. J. (1959). Congenital choledochal cyst, with a report of two and an analysis of 94 cases. *Int Abstr Surg*, 108, 1-30.
- [3] Todani, T., Watanabe, Y., & Narusue, M., et al. (1977). Congenital bile ductcysts: Classification, operative procedures and review of thirtyseven cases including cancer arising from choledochal cyst. *Am J Surg*, 134, 263-269
- [4] Edil, B. H., Cameron, J. L., & Reddy, S., et al. (2008). Choledochal cyst disease in children and adults: A 30-year single-institution experience. *J Am Coll Surg*, 206, 1000-1008.

- [5] Singham, J., Yoshida, E. M., & Scudamore, C. H. (2009 October). Choledochal cysts. Part 1 of 3; classification and pathogenesis. *Can J Surg*, 52(5), 434-40.
- [6] Ziegler, K. M, Pitt, H. A. , & Zyromski, N. J., et al. (2010). Choledochoceles: Are they choledochal cysts? *Ann Surg*, 252, 683–690.
- [7] Law, R., & Topazian, M. (2014). Diagnosis and Treatment of Choledochoceles. *Clin Gastroenterol Hepatol*, 12(2), 196-203.
- [8] Scholz, F. J, Carrera, G. F., & Larsen, C. R. (1976 January). The choledochoceles: correlation of radiological, clinical and pathological findings. *Radiology*, 118(1), 25-8.
- [9] Sarris, G. E., & Tsang, D. (1989). Choledochoceles: Case report, literature review, and a proposed classification. *Surgery*, 105(3), 408-14.
- [10] Antaki, F., Tringali, A., & Deprez, P., et al. (2008). A case series of symptomatic intraluminal duodenal duplication cysts: Presentation, endoscopic therapy, and long-term outcome (with video). *Gastrointest Endosc*, 67, 163-168.
- [11] Kagiya, S., Okazaki, K., & Yamamoto, Y. (1987). Anatomic variants of choledochoceles and manometric measurements of pressure in the cecum and the orifice zone. *Am J Gastroenterol*, 82, 641-649.
- [12] Schwegler, R. A., & Boyden, E. (1937). The development of the pars intestinalis of the common bile duct in the human fetus, with special reference to the origin of the ampulla of Vater and the sphincter of Oddi. *Anat Rec*, 67, 441-467.
- [13] Tanaka, T. (1993). Pathogenesis of choledochoceles. *Am J Gastroenterol*, 88, 1140.
- [14] Kim, T. H., Park, J. S., & Lee, S. S., et al. (2002). Carcinoma arising in choledochoceles is choledochoceloma innocent by stander or culprit? *Endoscopy*, 34, 675–677.
- [15] Lipsett, P. A., & Pitt, H. A. (2003). Surgical treatment of choledochal cysts. *J Hepatobiliary Pancreat Surg.*, 10(5), 352.
- [16] Masetti, R., Antinori, A., & Coppola, R., et al. (1996). Choledochoceles: Changing trends in diagnosis and management. *Surg Today*, 26(4), 281-5.
- [17] Goldberg, P. B., Long, W. B., & Oleaga, J. A., et al. (1980). Choledochoceles as a cause of recurrent pancreatitis. *Gastroenterology*, 78, 1041–5.
- [18] Greene, F. L., Brown, J. J., Rubinstein, P., & Anderson, M. C. (1985). Choledochoceles and recurrent pancreatitis. *Am J Surg*, 149, 306-9.
- [19] Franko, J., Nussbaum, L., & Morris, J. B., et al. (2006 July-August). Choledochal cyst cholangiocarcinoma arising from adenoma: Case report and a review of the literature. *Curr Surg*, 63(4), 281-4.
- [20] Yu, Z. L., Zhang, L. J., & Fu, J. Z., et al. (2004). Anomalous pancreatico-biliary junction: Image analysis and treatment principles. *Hepatobiliary Pancreat Dis Int*, 3(1), 136-9.
- [21] Søreide, K., & Søreide, J. A. (2007 March). Bile duct cyst as precursor to biliary tract cancer. *Ann Surg Oncol*, 14(3), 1200-11.
- [22] Metcalfe, M. S., Wemyss-Holden, S. A., & Maddern, G. J. (2003). Management dilemmas with choledochal cysts. *Arch Surg*, 138, 333–339.
- [23] Horaguchi, J., Fujita, N., & Kobayashi, G., et al. (2005). Clinical study of choledochoceloma: Is it a risk factor for biliary malignancies? *J Gastroenterol*, 40(4), 396-401.
- [24] Park, K. B., Auh, Y. H., & Kim, J. H., et al. (2001). Diagnostic pitfalls in the cholangiographic diagnosis of choledochoceles: cholangiographic quality and its effect on visualization. *Abdom Imaging*, 26(1), 48-54.
- [25] Elton, E., Hanson, B. L., & Biber, B. P., et al. (1998). Dilated common channel syndrome: endoscopic diagnosis, treatment, and relationship to choledochoceloma formation. *Gastrointest Endosc*, 47(6), 471-8.
- [26] De Backer, A. I., Van den Abbeele, K., & De Schepper, A. M., et al. (2000). Choledochoceloma: diagnosis by magnetic resonance imaging. *Abdom Imaging*, 25(5), 508-10.
- [27] Adamek, H. E., Schilling, D., & Weitz, M., et al. (2000). Choledochoceloma imaged with magnetic resonance cholangiography. *Am J Gastroenterol*, 95(4), 1082-3.
- [28] Ulas, M., Polat, E., & Karaman, K., et al. (2012). Management of choledochal cysts in adults: A retrospective analysis of 23 patients. *Hepatogastroenterology*, 59(116), 1155-9.
- [29] Sato, M., Ishida, H., & Konno, K., et al. (2001). Choledochal cyst due to anomalous pancreaticobiliary junction in the adult: sonographic findings. *Abdom Imaging*, 26(4), 395-400.
- [30] Azzik, H., Colankoglu, S. O., & Ergun, Y., et al. (1997). Endoscopic retrograde cholangiopancreatography in the diagnosis and management of choledochal cysts. *HBP Surg*, 10(4), 211-8.
- [31] Berger, A., Doudard, R., & Landi, B., et al. (2007). Endoscopic management of a large choledochoceloma associated with choledocholithiasis. *Gastroenterol Clin Biol*, 31, 200-203.
- [32] Belli, G., Rotondano, G., & D'Agostino, A., et al. (1998). Cystic dilatation of extrahepatic bile ducts in adulthood: Diagnosis, surgical treatment and long-term results. *HPB Surg*, 10(6), 379-84.
- [33] Dehyle, S. P., & Meyer, H. J. (1974). Peroral endoskopische elektrophysiological Abtragung einer Choledochoceloma. *Dtsch Med Wochenschr*, 99,71-72.
- [34] Siegel, J. H., Harding, G. T., & Chateau, F. (1981). Endoscopic incision of choledochal cysts (choledochoceloma). *Endoscopy*, 13, 200-202.
- [35] Nagasawa, S., Tanaka, M., & Seki, H., et al. (1983). Choledochoceloma: 2 cases with endoscopic papillotomy. *Nihon Shokakibyō Gakkai Zasshi*, 80, 1490–1495.
- [36] Katsinelos, P., Dimiropoulos, S., & Galanis, I., et al. (2003 Jan). Needle-knife sphincterotomy. *Surg Endosc*, 17(1), 158.
- [37] Ohtsuka, T., Inoue, K., & Ohuchida, J., et al. (2001). Carcinoma arising in choledochoceloma. *Endoscopy*, 33, 614-9
- [38] Singham, J., Yoshida, E. M., & Scudamore, C. H. (2010 February). Choledochal cysts. Part 3 of 3; management. *Can J Surg*, 53(1), 51-6.

- [39] Popova-Jovanovska, R., Genadieva-Dimitrova, M., & Trajkovska, M. et al. (2012 Jul). Choledochal cysts: Diagnosis and treatment. *Prilozi*, 33(1), 49-33.
- [40] Naga, M. I., & Suleiman, D. N. (2004 Mar). Endoscopic management of choledochal cyst. *Gastrointest Endosc*, 59(3), 427-32.
- [41] Martin, R. F., Biber, B. P., & Bosco, J. J., et al. (1992 May). Symptomatic choledochocoeles in adults. Endoscopic retrograde cholangiopancreatography recognition and management. *Arch Surg*, 127(5), 536-8.
- [42] Kouraklis, G., Misiakos, E., & Glinavou, A., et al. (1996). Cystic dilatations of the common bile duct in adults. *HPB Surg*, 10(2), 91-4.
- [43] Spier, L. N., Crystal, K., & Kase, D. J., et al. (1995 April). Choledochocoele: newer concepts of origin and diagnosis. *Surgery*, 117(4), 476-8.
- [44] Wearn, F. G., & Wiot, J. F., et al. (1982). Choledochocoele: Not form of choledochal cyst. *J Can Assoc Radiol*, 33(2), 110-2.
- [45] Zhu, L., Zeng, H., & Chen, Y. X., et al. (2014). Endoscopic management of choledochocoele complicated with choledocholithiasis and pancreatitis in an old patient. *Agng Clin Exp Res* [Epub ahead of print]
- [46] Garrido, A., León, R., Lopez, J., & Marquez, J. L. (2012). An exceptional case of choledochocoele and pancreas divisum in an elderly man. *Gastroenterol Hepatol*, 35(1), 8-11.
- [47] Martínez-Ordaz, J. L., & Niño-Solis, J. (2010). Choledochal cysts in adults. *Cir Cir.*, 78(1), 61-6.
- [48] Wang, G. Q., & Zahng, S. T. (2009). A rare case of bile duct cyst. *World J Gastroenterol*, 28(20), 2550-1.
- [49] Gordon, S. R., Levenick, J. M., & Rath, D. L. (2009). Case of a closed choledochocoele with biliary and pancreatic drainage via the accessory duct causing acute pancreatitis. *Dig Endosc*, 21(2), 106-8.
- [50] Urribarrena, A. R., Raventós, N., & Fuentes, J., et al. (2008). Diagnosis and management of choledochal cysts. A review of 10 new cases. *Rev Esp Enferm Dig*, 100(2), 71-5.
- [51] Can, M. F., Kaymakçioğlu, N., & Yağci, G. (2006). An adult choledochocoele case presented with gastric outlet obstruction: a rare presentation. *Turk J Gastroenterol*, 17(1), 70-3.
- [52] Safioleas, M. C., Moulakakis, K. G., & Misiakos, E. P., et al. (2005). Surgical management of choledochal cysts in adults. *Hepatogastroenterology*, 52(64), 1030-3.
- [53] García-Cano, J., Nieto J., & Godoy, M. A., et al. (2005 December). Small size choledochocoele as a cause of chronic epigastric pain: diagnosis and treatment by means of ERCP. *An Med Interna*, 22(12), 591-3.
- [54] Park, D. H., Kim, M. H., & Lee, S. K., et al. (2005). Can MRCP replace the diagnostic role of ERCP for patients with choledochal cysts? *Gastrointest Endosc*, 62(3), 360-6.
- [55] Jordan, P. H. Jr, Goss, J. A. Jr, & Rosenberg, W. R., et al. (2004 Mar). Some considerations for management of choledochal cysts. *Am J Surg*, 187(3), 434-9.
- [56] Rabie, M. E., Al-Humayed, S. M., & Hosni, M. H., et al. (2002 October-December). Choledochocoele: The disputed origin. *Int Surg*, 87(4), 221-5.