

This is the peer reviewed version of the following article:

Bleeding jejunal varices and portal thrombosis in a splenectomized patient with hereditary spherocytosis / Bertolotti, Marco; Loria, P; Martella, P; Carulli, Lucia; De Santis, M; Carulli, N.. - In: DIGESTIVE DISEASES AND SCIENCES. - ISSN 0163-2116. - ELETTRONICO. - 45:(2000), pp. 373-377. [10.1023/A:1005481114220]

Terms of use:

The terms and conditions for the reuse of this version of the manuscript are specified in the publishing policy. For all terms of use and more information see the publisher's website.

24/04/2024 06:30

(Article begins on next page)

CASE REPORT

Bleeding Jejunal Varices and Portal Thrombosis in a Splenectomized Patient with Hereditary Spherocytosis

MARCO BERTOLOTTI, MD, PAOLA LORIA, MD, PIETRO MARTELLA, MD, LUCIA CARULLI, MD, MARIO DE SANTIS, MD, and NICOLA CARULLI, MD

KEY WORDS: hereditary spherocytosis; jejunal varices; portal thrombosis; splenectomy.

Bleeding from varices located in the small bowel is a very uncommon finding; nonetheless, such events accompany with a high mortality rate (1–4). Moreover, early diagnosis of jejunal or ileal varices cannot usually be accomplished with standard diagnostic tools (ie, esophagogastroduodenoscopy, colonoscopy).

Most reports in the literature relate to subjects with liver cirrhosis, often with hepatocarcinoma; in unusual anatomical situations, varices may develop beyond the ligament of Treitz in adjunct to the far more common location in the esophageal and gastric wall. Thrombosis of the portal vein is a common feature in such conditions. Portal thrombosis has also been described in association with overt or latent myeloproliferative diseases (5); its occurrence in nonneoplastic hematological conditions in subjects with normal liver function is quite uncommon.

This report describes the observation of jejunal varices, with repeated episodes of “melena of unknown origin,” some of which quite severe, as their clinical presentation in a patient with portal thrombosis and with otherwise absolutely normal liver function, who had undergone splenectomy for hereditary spherocytosis in early adolescence.

CASE REPORT

G.S., a Caucasian male 33 years of age, was admitted to our division nearly two weeks after an episode of melena. In the previous two and a half years he had presented two similar episodes, one of them leading to important blood

loss and anemia; investigation of the gastrointestinal tract by standard upper and lower endoscopy, performed at a local hospital, had always been negative and so had the other routine imaging exams. Therefore, no definite diagnosis had been made, and the patient, with a suspected diagnosis of erosive hemorrhagic gastritis, was put under treatment with antisecretive drugs (ranitidine or omeprazole cyclically). The clinical history of the patient was otherwise unremarkable with the exception of a diagnosis of hereditary spherocytosis in childhood, leading to splenectomy at the age of 13. At the present time he was not taking any drugs.

On physical examination the patient was slightly overweight, with no abdominal findings of clinical interest. The right leg had been moderately swollen, warm, and tender for the past five to six days; Doppler ultrasonography, performed upon admission, excluded the presence of deep venous thrombosis. Laboratory tests revealed mild hypochromic microcytic anemia, with blood cell morphology compatible with the diagnosis of hereditary spherocytosis, and marked thrombocytosis (800,000–900,000/ μ l). Antithrombin III was slightly lower than normal. Other values were within the normal range. A bone marrow biopsy was performed and allowed us to rule out a primary hematological disorder other than spherocytosis.

Melena had resolved spontaneously two to three days after onset and even occult blood was undetectable in the stool at the time of our observation. The patient felt subjectively well and the right leg pain and edema also subsided spontaneously in a few days.

Esophagogastroduodenoscopy had been performed the week before admission, after the clinical appearance of melena and was negative, as were the previous ones. To rule out a vascular anomaly of the small bowel, we performed a jejunoenteroscopy, which showed the presence of submucosal venous varices beyond the ligament of Treitz (Figure 1); apart from their more distal location, they had the same morphological appearance as esophageal varices, as the endoscopist pointed out. A selective angiography of the celiac and mesenteric arteries was subsequently performed; angiography of the superior mesenteric artery showed a normal arterial phase, whereas the venous phase (Figure 2)

Manuscript received February 26, 1999; accepted July 14, 1999.

From the Dipartimento di Medicina Interna and Dipartimento di Scienze Mediche, Oncologiche e Radiologiche, Università degli Studi di Modena e Reggio Emilia, Italy.

Address for reprint requests: Dr. Marco Bertolotti, Divisione di Medicina III, Policlinico, Via del Pozzo 71, 41100 Modena, Italy.

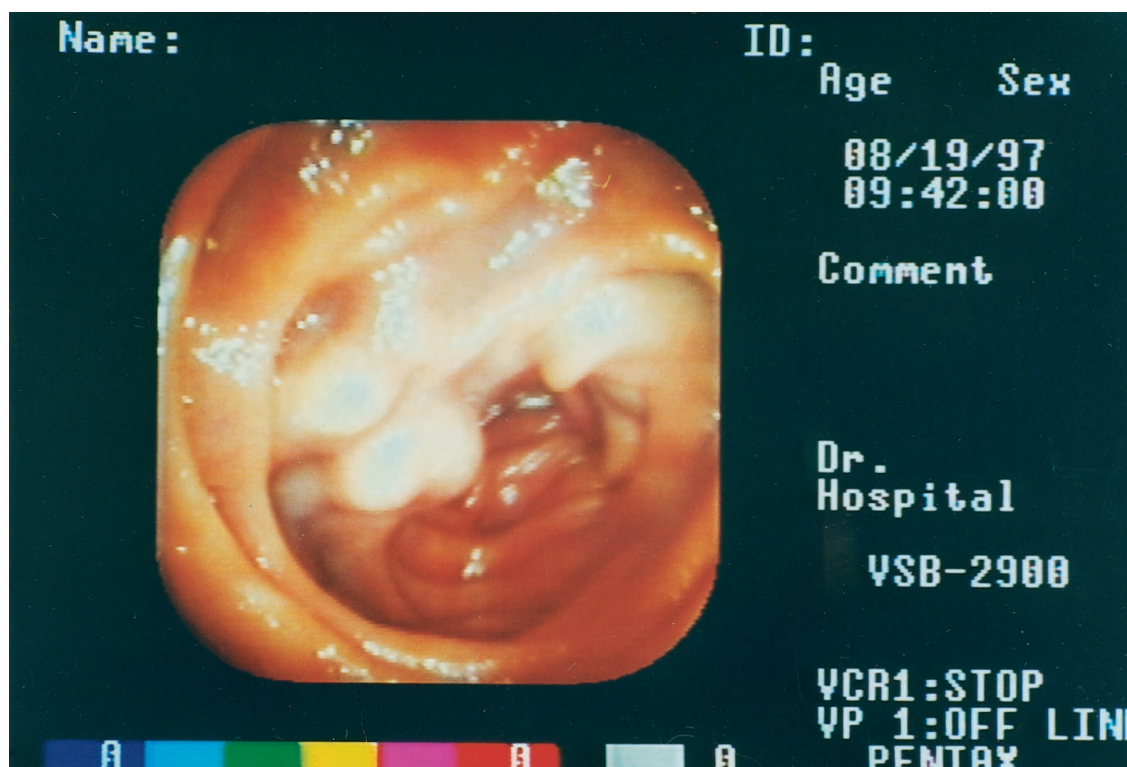


Fig 1. Enteroscopic imaging of submucosal varices in the proximal jejunum.

revealed several venous dilatations in the territory of the superior mesenteric vein. The vein itself was not opacified, whereas the portal vein was entirely thrombosed. The picture was confirmed at CT angiography (Figure 3).

A diagnosis of portal hypertension with jejunal varices, related to portal thrombosis, was made. Surgical devascularization was proposed to the patient, who refused.

DISCUSSION

Venous varices have been reported to occur at any site of the gastrointestinal tract, even if location beyond the duodenum is quite uncommon (1); their clinical presentation, though, may be quite serious and episodes of important intestinal hemorrhage have been described (2, 3). In the reports and reviews of the literature (1, 3, 4), the finding is mostly associated with chronic progressive liver disease, often complicated with hepatocarcinoma. In these clinical situations portal thrombosis is also relatively common and formation of submucosal varices in extraesophageal sites may follow, or be associated with, the appearance of esophageal and/or gastric varices. In some instances extraesophageal varices were detected after shunt operations to relieve portal hypertension (6).

Occurrence of portal thrombosis, portal hyperten-

sion and bleeding jejunal varices in subjects with normal liver function, is extremely rare; a few reports have described small bowel varices after abdominal surgery, usually at the site where an anastomosis was performed (7). Interestingly, portal thrombosis was also described to occur, independently of chronic liver disease, in subjects with hematological diseases, in particular with myeloproliferative conditions (5, 8, 9).

Hereditary spherocytosis is seldom associated with thrombotic risk (10). As far as we know, the only report in the literature describing the association of hereditary spherocytosis and portal thrombosis is a letter by McGrew and Avant (11); the patient described developed portal thrombosis eight years after splenectomy, which became clinically apparent after an episode of bleeding from esophagogastric varices.

We believe that in such patients more than one factor may contribute to the development of portal thrombosis. One such factor is thrombocytosis secondary to splenectomy; even if this condition is not usually associated with a hypercoagulable state, this might be favored by the association of hemolysis and spherocytosis *per se*. Secondly, removal of the spleen and of the splenic vein is likely to slow down portal

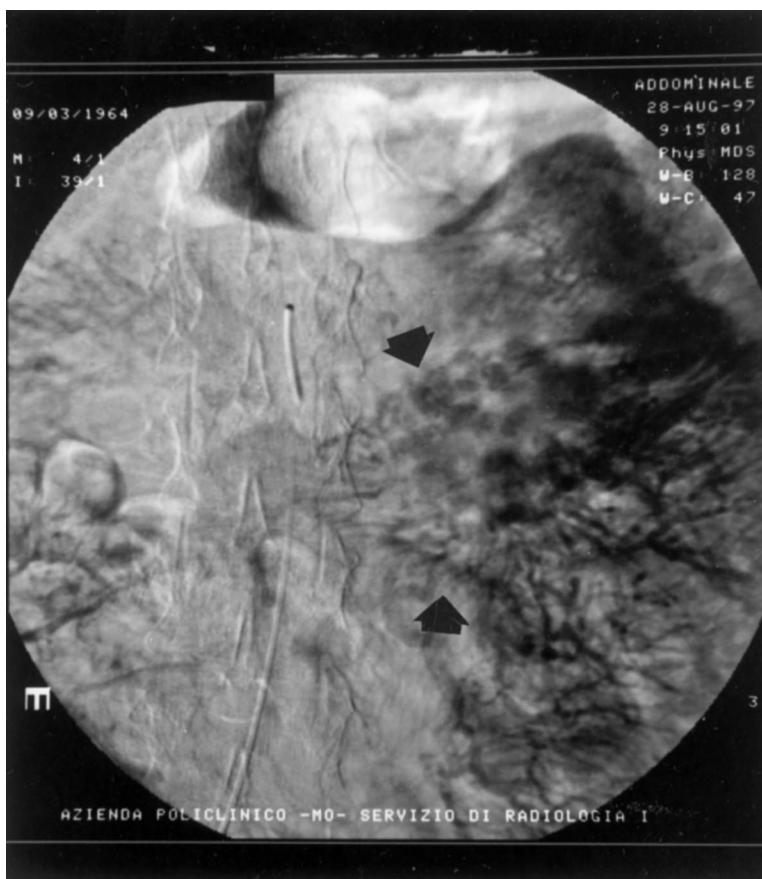

Fig 2. Selective angiography of the superior mesenteric artery: venous phase showing gross jejunal varices (arrows); the superior mesenteric and portal veins are not opacified.

flow and to facilitate the onset of a thrombotic process. Important hemodynamic changes take place after splenectomy or splenorenal shunt (12, 13). Portal thrombosis was indeed described after surgical splenectomy in subjects with idiopathic or cirrhotic portal hypertension (14) and shortly after laparoscopic splenectomy (15).

In our patient, bone marrow examination excluded a primary hematological disorder other than spherocytosis. Nonetheless, even in the absence of overt myeloproliferative disease, portal thrombosis has been described in association with the tendency to form “spontaneous” erythroid colonies in cultures of bone marrow taken from the subjects (5).

A prothrombotic state might be present in patients with hemolytic syndromes, or in subjects with “occult” myeloproliferative disorders. In our case, the mild defect in antithrombin III levels may also have contributed. The fact that this patient was in a thrombophilic state is also suggested by the clinical manifes-

tation at the right leg, which might have represented a minor episode of venous thrombosis, in spontaneous resolution when Doppler sonography was performed. Indeed venous thrombosis may be the cause of leg ulcers, a quite common finding in patients with spherocytosis.

The appearance of varices in the mesenteric small bowel probably reflects an uncommon anatomical situation where venous blood flow at relatively high pressure cannot drain through the coronary gastric and azygous veins due to the vascular deconnections of splenectomy or to extensive vascular involvement of the thrombotic process. A more limited extension of thrombosis was probably present in the only other case reported in the literature (11), with a different hemodynamic condition leading to the more usual clinical presentation as esophageal and gastric varices.

This case represents an unusual model of portal hypertension and suggests that the pathophysiological

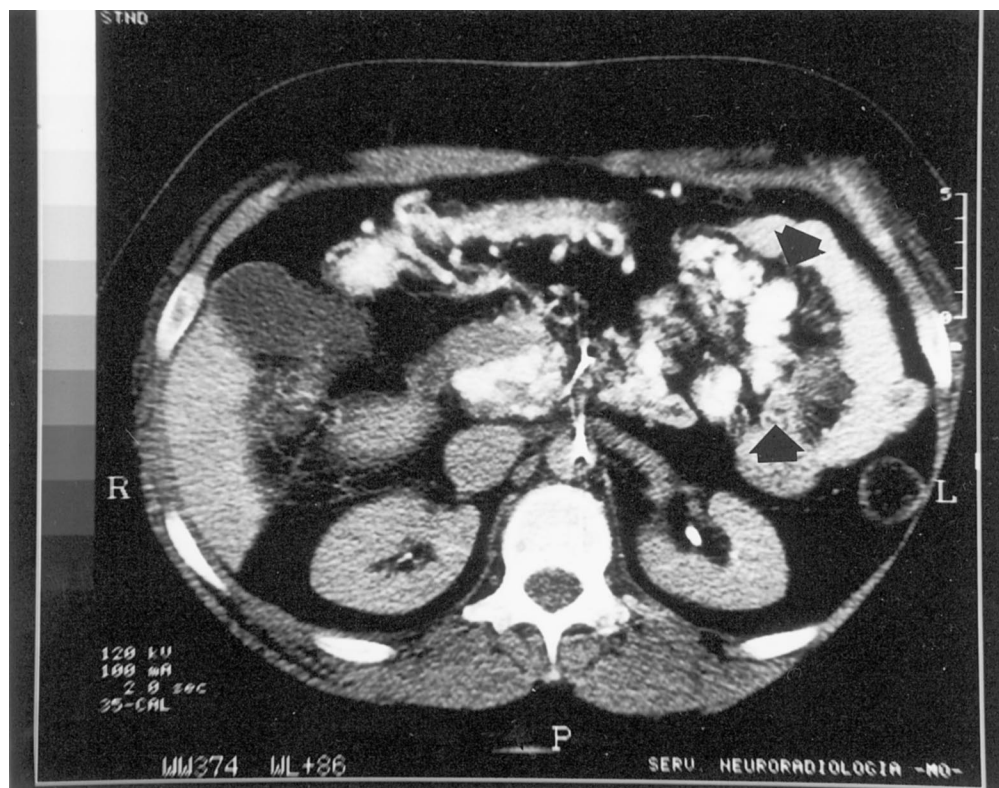


Fig 3. CT portography showing large jejunal varices (arrows).

processes and clinical manifestations of increased blood pressure in the portal system may be very similar even if the etiologies and the anatomical sites of manifestation are quite distinct. Our report encourages wider utilization of jejunoenteroscopy, a relatively noninvasive procedure (16, 17), as a diagnostic tool and the use of angiography even in the absence of concurrent bleeding, especially when the clinical history of the patient (ie, previous splenectomy or abdominal surgery in general; presence of a hematological disorder) may raise the suspicion of intestinal varices. We believe that such uncommon events may be increasingly diagnosed as the cause of gastrointestinal bleeding of, up to now, “unknown” origin.

REFERENCES

1. Cappell MS, Price JB: Characterization of the syndrome of small and large intestinal variceal bleeding. *Dig Dis Sci* 32:422–427, 1987
2. Philippakis M, Karkanias G, Sakorafas GH, Pontikis I, Gavalas M: Massive gastrointestinal bleeding secondary to intestinal varices. *Eur J Surg* 158:379–381, 1992
3. Yuki N, Kubo M, Noro Y, Kasahara A, Hayashi N, Fusamoto H, Ito T, Kamada T: Jejunal varices as a cause of massive gastrointestinal bleeding. *Am J Gastroenterol* 87:514–517, 1992
4. Kotfila R, Trudeau W: Extraesophageal varices. *Dig Dis* 16:232–241, 1998
5. Valla D, Casadevall N, Huisse MG, Tulliez M, Grange JD, Muller O, Binda T, Varet B, Rueff B, Benhamou JP: Etiology of portal vein thrombosis in adults. A prospective evaluation of primary myeloproliferative disorders. *Gastroenterology* 94:1063–1069, 1988
6. Attias E, Smadja C, Vons C, Traynor O, Franco D: Bleeding from intestinal varices after a Warren shunt. *J Clin Gastroenterol* 9:585–587, 1987
7. Paquet K-J, Lazar A, Bickhart J: Massive and recurrent gastrointestinal hemorrhage due to jejunal varices in an afferent loop—diagnosis and management. *Hepato-Gastroenterol* 41:276–277, 1994
8. Boughton BJ: Hepatic and portal vein thrombosis. Closely associated with chronic myeloproliferative disorders. *BMJ* 302:192–193, 1991
9. Muller EW, De Wolf JTM, Haagsma EB: Portal hypertension as presenting feature of a myeloproliferative disorder. Diagnosis and therapeutic dilemmas. *Scand J Gastroenterol* 28(suppl 200):74–79, 1993
10. Hayag-Barin JE, Smith RE, Tucker FC Jr: Hereditary spherocytosis, thrombocytosis, and chronic pulmonary emboli: A case report and review of the literature. *Am J Hematol* 57:82–84, 1998
11. McGrew W, Avant GR: Hereditary spherocytosis and portal vein thrombosis. *J Clin Gastroenterol* 6:381–382, 1984

PORTAL THROMBOSIS AND SPHEROCYTOSIS

12. Nakamura T, Moriyasu F, Ban N, Nishida O, Tamada T, Kawasaki T, Miura K, Sakai M, Miyake T, Uchino H, Kumada K, Ozawa K: Hemodynamic analysis of postsplenectomy portal thrombosis using ultrasonic Doppler duplex system. *Am J Gastroenterol* 82:1212–1216, 1987
13. Bolondi L, Gaiani S, Mazziotti A, Casanova P, Cavallari A, Gozzetti G, Barbara L: Morphological and hemodynamic changes in the portal venous system after distal splenorenal shunt: An ultrasound and pulsed Doppler study. *Hepatology* 8:652–657, 1988
14. Eguchi A, Hashizume M, Kitano S, Tanoue K, Wada H, Sugimachi K: High rate of portal thrombosis after splenectomy in patients with esophageal varices and idiopathic portal hypertension. *Arch Surg* 126:752–755, 1991
15. Valeri A, Venneri F, Presenti L, Nardi F, Grossi A, Borrelli D: Portal thrombosis. A rare complication of laparoscopic splenectomy. *Surg Endosc* 12:1173–1176, 1998
16. Lewis BS, Waye JD: Chronic gastrointestinal bleeding of obscure origin: role of small bowel enteroscopy. *Gastroenterology* 94:1117–1120, 1988
17. Bouhnik Y, Bitoun A, Coffin B, Moussaoui R, Oudghiri A, Rambaud JC: Two way push videoenteroscopy in investigation of small bowel disease. *Gut* 43:280–284, 1998