This is the peer reviewd version of the followng article:

Development and Validation of a Diagnostic Echocardiographic Mass Score in the Approach to Cardiac Masses / Paolisso, Pasquale; Foà, Alberto; Magnani, Ilenia; Bergamaschi, Luca; Graziosi, Maddalena; Angeli, Francesco; Chiti, Chiara; Fabrizio, Michele; Rinaldi, Andrea; Stefanizzi, Andrea; Armillotta, Matteo; Sansonetti, Angelo; Gallinoro, Emanuele; Maietti, Elisa; Rucci, Paola; Biagini, Elena; Mattioli, Anna Vittoria; Galiè, Nazzareno; Pizzi, Carmine. - In: JACC. CARDIOVASCULAR IMAGING. - ISSN 1936-878X. - 15:11(2022), pp. 2010-2012. [10.1016/j.jcmg.2022.06.005]

*Terms of use:*

The terms and conditions for the reuse of this version of the manuscript are specified in the publishing policy. For all terms of use and more information see the publisher's website.

12/10/2024 09:14

(Article begins on next page)

JACC: CARDIOVASCULAR IMAGING
VOL. ■, NO. ■, 2022
© 2022 BY THE AMERICAN COLLEGE OF CARDIOLOGY FOUNDATION
ISSN 1936-878X/$36.00
PUBLISHED BY ELSEVIER

iMAIL

iMAIL

## Development and Validation of a Diagnostic Echocardiographic Mass Score in the Approach to Cardiac Masses

Cardiac masses (CMs) are a diagnostic dilemma in clinical practice and require multiple imaging techniques to assess malignancy, which is essential to guide the proper treatment.[1-3] Echocardiography can provide precious information and represents the first-line imaging approach to CMs, as more advanced methods may not be available at all centers. This study was planned to investigate the echocardiographic features of CMs that may suggest malignancy and build a score, the diagnostic echocardiographic mass (DEM) score, that can increase diagnostic yield.

All consecutive patients undergoing complete echocardiographic evaluations from 2004 to 2020 were enrolled. On the basis of definitive diagnosis, achieved by histologic examination or, in the case of cardiac thrombi, with radiological evidence of thrombus resolution after appropriate anticoagulant treatment, CMs were distinguished as benign or malignant and classified according to the World Health Organization's 2015 classification of tumors of the heart and pericardium.[4] Echocardiograms were obtained using high-quality ultrasound machines (Philips iE33 or EPIQ) following the recommendations of the American Society of Echocardiography and the European Association of Cardiovascular Imaging. Images were analyzed off-line by 2 expert echocardiography cardiologists with more than 10 years' experience in cardiac imaging, blinded to clinical information and CM histology. Several echocardiographic characteristics were assessed to select those able to potentially identify malignant masses. Variables maintaining statistical significance in independently predicting malignancy after logistic regression analysis were used to build a multiparametric predictive score, which was developed in a derivation sample and tested in a validation cohort. All patients were managed according to the Declaration of Helsinki and provided informed consent for the anonymous publication of scientific data. The study protocol was approved by the local ethics committee (registration number 102/2017/0/Oss).

Our final study population included 249 patients, 181 (72%) with benign CMs and 68 (28%) with malignancies, and no significant differences in terms of clinical and demographic characteristics were observed between the derivation (178 subjects [70%]) and validation (71 subjects [30%]) cohorts. Within the derivation sample, several echocardiographic features were found to be strongly associated with malignancy, namely, nonleft localization, greater dimension (diameter >30 mm), inhomogeneity, irregular margins, immobility, sessile and polylobate masses, infiltration, and the coexistence of pericardial effusion ($P < 0.001$ for all). After multivariable logistic regression, only 6 features (infiltration, moderate to severe pericardial effusion, polylobate shape, sessile, inhomogeneity, and nonleft localization) were identified as independent predictors of malignant masses. On the basis of the weight assigned to regression coefficients, a DEM score ranging from 0 to 9 was developed and validated as follows: infiltration, polylobate shape, and moderate to severe pericardial effusion were assigned 2 points each, and inhomogeneity, sessile, nonleft localization were assigned 1 point each (**Figure 1**). The score showed the highest diagnostic performance to predict malignancy compared with the echocardiographic characteristics taken individually (AUC: 0.965 [95% CI: 0.938-0.993]; sensitivity, 84.0%; specificity, 96.0%; accuracy, 89.4%; Brier's score, 0.057). Furthermore, all 249 echocardiograms were randomly selected and reanalyzed by a cardiologist in training, blinded to patient clinical data and other echocardiographic results. Interobserver agreement, expressed as Cohen's κ, was adequate ($\kappa \geq 0.80$) with a percentage of agreement >90% for all the parameters selected for the score.

In the heterogeneous scenario of CMs, our study showed that several echocardiographic characteristics are actually related to malignancy, but the combination of some features into a multiparametric score (the DEM score) significantly increases diagnostic accuracy. The excellent result achieved by a training cardiologist supports our preliminary idea to select parameters easily and objectively measurable by all users. In conclusion, we believe that in patients with suspected CMs, our echocardiographic score could be a valuable and widely accessible tool for clinicians to quickly suggest the masses' nature,

**FIGURE 1** **Echocardiographic Features, Diagnostic Accuracy, and Clinical Implications of the DEM Score**

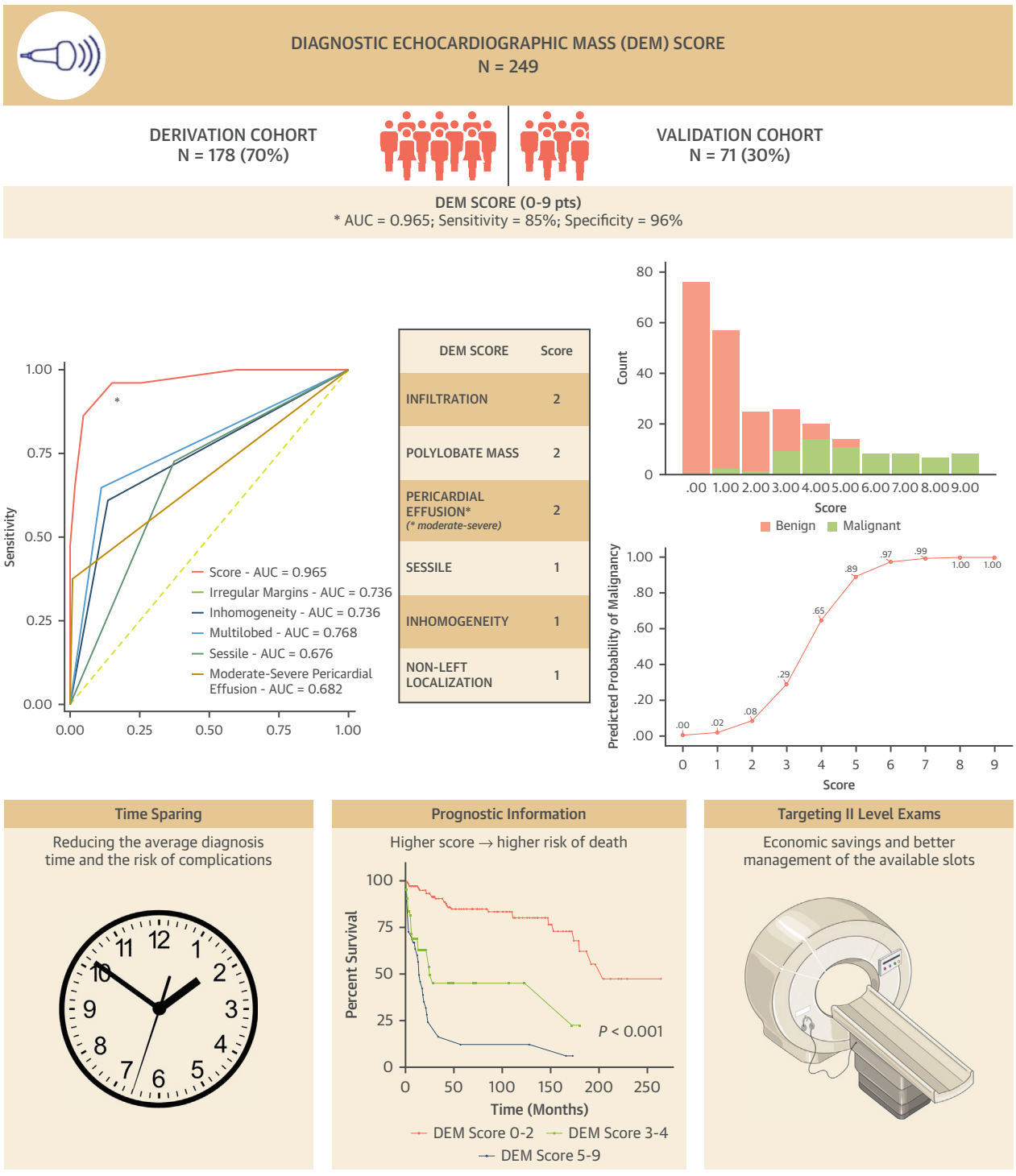


**Stacked bars** show the frequency distribution of patients with benign or malignant masses and the cumulative estimated probability of malignancy according to the diagnostic echocardiographic mass (DEM) score. Asterisk refers to the ROC curve **(red curve)** corresponding to the SCORE. AUC = area under the curve.

thereby minimizing the diagnostic pathway and the reliance on advanced radiological techniques, with the ultimate goal of delivering the proper treatment in the shortest time possible.

**Pasquale Paolisso, MD**†
**Alberto Foà, MD**†
**Ilenia Magnani, MD**
**Luca Bergamaschi, MD**
**Maddalena Graziosi, MD**
**Francesco Angeli, MD**
**Chiara Chiti, MD**
**Michele Fabrizio, MD**
**Andrea Rinaldi, MD**
**Andrea Stefanizzi, MD**
**Matteo Armillotta, MD**
**Angelo Sansonetti, MD**
**Emanuele Gallinoro, MD**
**Elisa Maietti, PhD**
**Paola Rucci, PhD**
**Elena Biagini, MD, PhD**
**Anna Vittoria Mattioli, MD, PhD**
**Nazzareno Galiè, MD, PhD**
**Carmine Pizzi, MD***

*Department of Experimental, Diagnostic and Specialty Medicine (Padiglione 23)
University of Bologna
Via Giuseppe Massarenti 9
Bologna 40138, Italy
E-mail: carmine.pizzi@unibo.it

https://doi.org/10.1016/j.jcmg.2022.06.005

†Drs Paolisso and Foà contributed equally to this work. The authors have reported that they have no relationships relevant to the contents of this paper to disclose.

The authors attest they are in compliance with human studies committees and animal welfare regulations of the authors' institutions and Food and Drug Administration guidelines, including patient consent where appropriate. For more information, visit the Author Center.

## REFERENCES

**1.** Foà A, Paolisso P, Bergamaschi L, et al. Clues and pitfalls in the diagnostic approach to cardiac masses: are pseudotumours truly benign? *Eur J Prev Cardiol*. 2022;29(3):e102–e104.

**2.** D'Angelo EC, Paolisso P, Vitale G, et al. Diagnostic accuracy of cardiac computed tomography and 18-F fluorodeoxyglucose positron emission tomography in cardiac masses. *J Am Coll Cardiol Img*. 2020;13:2400–2411.

**3.** Lopez-Mattei JC, Lu Y. Multimodality imaging in cardiac masses: to standardize recommendations, the time is now. *J Am Coll Cardiol Img*. 2020;13:2412–2414.

**4.** Burke A, Tavora F. The 2015 WHO classification of tumors of the heart and pericardium. *J Thorac Oncol*. 2016;11:441–452.