

## THYROID

# Aesthetic comparison between synthetic glue and subcuticular sutures in thyroid and parathyroid surgery: a single-blinded randomised clinical trial

*Confronto del risultato estetico tra colla sintetica e suture intradermiche nella chirurgia tiroidea e paratiroidea: una sperimentazione clinica in singolo cieco*

M. ALICANDRI-CIUFELLI<sup>1</sup>, A. PICCININI<sup>1</sup>, A. GRAMMATICA<sup>1</sup>, G. MOLTENI<sup>1</sup>, A. SPAGGIARI<sup>2</sup>, S. DI MATTEO<sup>3</sup>, S. TASSI<sup>1</sup>, A. GHIDINI<sup>1</sup>, L. IZZO<sup>4</sup>, F.M. GIOACCHINI<sup>1</sup>, D. MARCHIONI<sup>1</sup>, S. DI SAVERIO<sup>5</sup>, L. PRESUTTI<sup>1</sup>

Otolaryngology Department, University Hospital of Modena, Italy; <sup>2</sup>Plastic Surgery Department, University Hospital of Modena, Italy; <sup>3</sup>Medistat SAS, Milan, Italy; <sup>4</sup>Department of General Surgery, Policlinico Umberto I, "Sapienza" University of Rome, Rome, Italy; <sup>5</sup>Department of Emergency, Emergency Surgery and Trauma Surgery Unit, Maggiore Hospital, Bologna Local Health District, Bologna, Italy

## SUMMARY

The aim of our study was to compare, in terms of aesthetic results, the use of synthetic glue to intradermal absorbable sutures in post-thyroidectomy and parathyroidectomy wound closure in a single blinded, randomised, per protocol equivalence study. From September 2008 to May 2010, patients undergoing thyroid or parathyroid surgery (with an external approach) at the Otolaryngology Department of the University Hospital of Modena were assessed for eligibility. In total, 42 patients who had had synthetic glue application on surgical incisions (A) and 47 patients who had subcuticular sutures on their surgical incisions (B) were enrolled. The mean of the endpoint (based on the Wound Registry Scale) of group A at 10 days was 1.4, while that in group B (based on the Stony Brook Scar Evaluation Scale) was 2.9. Statistically significant ( $p = 0.002$ ) and clinically significant (difference of the means = 1.5) differences in the aesthetic results were found between groups A and B at 10 days, with better results in group B. On the other hand, at 3 months, the mean of the endpoint in group A was 3.1 while that in group B was 2.8; no statistically significant ( $p = 0.62$ ) or clinically significant (difference in means = 0.3) differences were found between groups A and B. In conclusion, synthetic glue differs from subcuticular suture in post-thyroidectomy or post-parathyroidectomy incision for early aesthetic results, with better outcomes for subcuticular sutures. At 3 months, there were no differences in aesthetic outcomes between groups. Moreover, sex, incision length, age, cold/hot blade and correspondence of the incision with a wrinkle in the skin did not seem to influence aesthetic outcomes with this type of incision.

**KEY WORDS:** Thyroid surgery • Parathyroid surgery • Neck surgery • Aesthetic outcomes • Synthetic glue • Intradermal absorbable sutures • Subcuticular sutures

## RIASSUNTO

*L'obiettivo del nostro lavoro è stato di confrontare, in termini di risultati estetici, l'uso di colla sintetica con l'uso di suture intradermiche riassorbibili nella chiusura delle ferite post tiroidectomia e post paratiroidectomia mediante uno studio in singolo cieco, randomizzato per protocollo di equivalenza. Da settembre 2008 a maggio 2010, i pazienti sottoposti a tiroidectomia o a paratiroidectomia (con approccio esterno) presso il Dipartimento di Otorinolaringoiatria del Policlinico di Modena sono stati valutati per l'ammissione nello studio. In totale 42 pazienti che avevano ricevuto l'applicazione di colla sintetica sulle loro incisioni chirurgiche (A) e 47 pazienti che avevano avuto suture intradermiche sulle loro incisioni chirurgiche (B) sono stati arruolati nello studio. La media dell'end point (in base alla Wound Registry Scale) del gruppo A a 10 giorni è stata di 1.4, mentre quella del gruppo B (in base alla Stony Brook Scar Evaluation Scale) è stata di 2.9. Una differenza statisticamente significativa ( $p = 0.002$ ) e clinicamente significativa (differenza delle medie = 1,5) nei risultati estetici è stata riscontrata tra i gruppi A e B a 10 giorni, con migliori risultati per il gruppo B. D'altra parte, a 3 mesi, la media dell'end point nel gruppo A è stata di 3.1 mentre quella nel gruppo B è stata di 2.8; nessuna differenza statisticamente significativa ( $p = 0,62$ ) o clinicamente significativa (differenza in medie = 0.3) è stata trovata tra i gruppi A e B. In conclusione la colla sintetica differisce dalla sutura intradermica nell'incisione post tiroidectomia o post paratiroidectomia per quanto riguarda i primi risultati estetici che risultano essere migliori con le suture intradermiche. A 3 mesi, non c'erano più differenze in termini di risultati estetici tra i due gruppi. Inoltre il sesso, la lunghezza dell'incisione, l'età, il tipo di lama (fredda o calda), e la corrispondenza dell'incisione con una piega cutanea non sembrano influenzare i risultati estetici con questo tipo di incisione.*

**PAROLE CHIAVE:** Chirurgia tiroidea • Chirurgia paratiroidea • Chirurgia cervicale • Risultati estetici • Colla sintetica • Suture intradermiche riassorbibili • Suture sottocutanee

## Introduction

The head-neck region is anatomically complex regarding the presence of different organs and tissues. Surgery in this region also raises significant aesthetic problems because the neck and face are among the areas most exposed to the vision of others, and thus are aesthetically important.

Several different materials and suturing techniques are used in head and neck surgery, depending on the region in which the suture is performed, although in head and neck surgery, the use of subcuticular absorbable sutures is very popular. This kind of suture has many benefits, for example, little tissue reaction, rapid reduction and absence of mark points<sup>1</sup>, and for all these reasons, our standard for all incision closures in regions particularly exposed is the subcuticular absorbable synthetic monofilament suture. On the other hand, in recent years, the use of tissue glue (e.g. octylcyanoacrylate) has gained favour in surgical practice for quicker and painless closure of lacerations, and the use of tissue adhesive is increasingly becoming an alternative to sutures.

In the literature, there are many comparative studies on different types of suture, but in general, have focused on the closure of excisional wounds or on suturing techniques not limited to one single region, but also including higher tension areas such as the extremities<sup>2</sup>. However, as is well known to every surgeon, each region in the human body has a different behaviour with regard to scar formation, both in rapidity of healing and in aesthetic results.

Thyroidectomy and parathyroidectomy classically require anterior neck incisions that are at risk of undesirable aesthetic results when scars do not form as expected. This type of incision is particularly important from an aesthetic point of view as its location is particularly exposed. Moreover, thyroid and parathyroid surgery is most often practiced in young women. In fact, the incidence of thyroid and parathyroid disease is three times higher in women than in men, and the incidence peaks in the third and fourth decades of life<sup>3</sup>. For all these reasons, the aesthetic outcomes of this kind of surgery are very important. For the above-mentioned reasons, we carried out a prospective, randomised, controlled trial to compare, in terms of aesthetic results, the use of synthetic glue to intradermal absorbable suture in post-thyroidectomy and parathyroidectomy wound closure.

The purpose was also to see whether other variables such as age, sex, size and type of incision (hot or cold), and correspondence of the incision with a skin wrinkle influenced the post-operative healing process in terms of aesthetic results.

## Methods

The IRB approval was requested and obtained (Comitato Etico Provinciale di Modena, 2454/C.E.). The present study was also registered on [www.clinicaltrials.gov](http://www.clinicaltrials.gov)

(NCT00754182). A CONSORT 2010 statement was used to report the present randomised controlled trial (RCT).

From September 2008 to May 2010, patients undergoing thyroid or parathyroid surgery (with an external approach) at the Otolaryngology Department of the University Hospital of Modena were assessed for eligibility for inclusion. Patients who had prior neck surgery and patients who required concomitant neck dissection were excluded from the study. During pre-operative clinical history collection, consent to participate in the study was obtained from the patient, after adequate information was given by the ENT surgeon. In the case of consent, the patient was included in the study, and consecutively randomised for treatment based on a block randomisation list, obtained by six permuting blocks (1 = AABB, 2 = ABAB, 3 = BBAA, 4 = BABA, 5 = ABBA, 6 = BAAB) randomly distributed to create the list. To the A patient group (study group), a glue suture (Dermabond; Ethicon Inc, Norwood, MA, USA) was assigned to close the skin, while to the B patient group (control group) a subcuticular suture (Caprosyn; Syneture, U.S. Surgical, Div. Tyco Healthcare, Norwalk, CT, USA) was utilised. In both cases, the skin was closed after strap muscle approximation and accurate subcutaneous suture placement. The primary outcome was aesthetic result based on an equivalence comparison of sutures at 10 days and at 3 months, while the secondary ad-hoc outcome was whether correspondence of the incision with a wrinkle of the skin, age < 45 years, incision length (higher versus lower than the mean) and sex could have played a role in the aesthetic results, independently of the type of suture used. Further post-hoc analyses included comparison of the results between the sutures for each variable considered in the scoring system, at 10 days and at 3 months, and whether they were able to identify in which subheading of the endpoint the aesthetics results differed. A 10 days (8-11 days was considered acceptable) and 3 months (10-14 weeks was considered acceptable), follow-up was performed. For controls, a picture of the surgical scar was obtained after suture removal and accurate cleaning of the scar to remove as much residual material from the suture as possible. All images were stored in a database. A plastic surgeon, blinded for the type of treatment, was then asked to review the images, assigning a score to each scar. Two different scoring systems were used as endpoints. To evaluate the 10-day aesthetic results, the 6-point (1, step-off of the borders; 2, contour irregularities; 3, margin separation; 4, edge inversion; 5, excessive distortion; 6, overall appearance) Wound Registry scale<sup>4</sup> was used, while to evaluate the 3-month aesthetic results, the 5-point Stony Brook Scar Evaluation Scale<sup>5</sup> (1, width < 2 mm; 2, height; 3, colour; 4, hatch or suture marks; 5, overall appearance) was used. For every category, one point was assigned (0 = bad; 1 = good), and the points in each category were then summed to obtain for every scar a score ranging from 0 (worst) to 6 (best) for 10-day

results, and a score ranging from 0 (worst) to 5 (best) for 3-month results. The aesthetic results were also collected in a database for further analyses.

*Statistical considerations*

A per protocol two-sided equivalence comparison was established with a statistical significance level of 95%. Patients who accomplished at least one rating were considered per protocol, and hence included in the final analyses. A power of 80% and a clinical difference of 1 point of the end point scale were considered significant. An ad-interim analyses was planned in November 2009 to determine patient numbers, based on preliminary differences found between the groups. Once an adequate patient number

had been obtained in the interim analyses, the study was stopped for final analysis of results. All patients who had at least one rating (either at 10 days or at 3 months) were analysed. The Mann-Whitney-Wilcoxon test was used to compare results (NCSS 2004, Kaysville, UT, USA).

**Results**

In total, 235 patients were assessed for eligibility (Fig. 1). Of these, 95 were excluded from the study because they did not meet inclusion criteria or declined to participate; 140 patients were randomised for treatment. Two patients were excluded from group A analyses because of postoperative bleeding, and one patient was excluded because

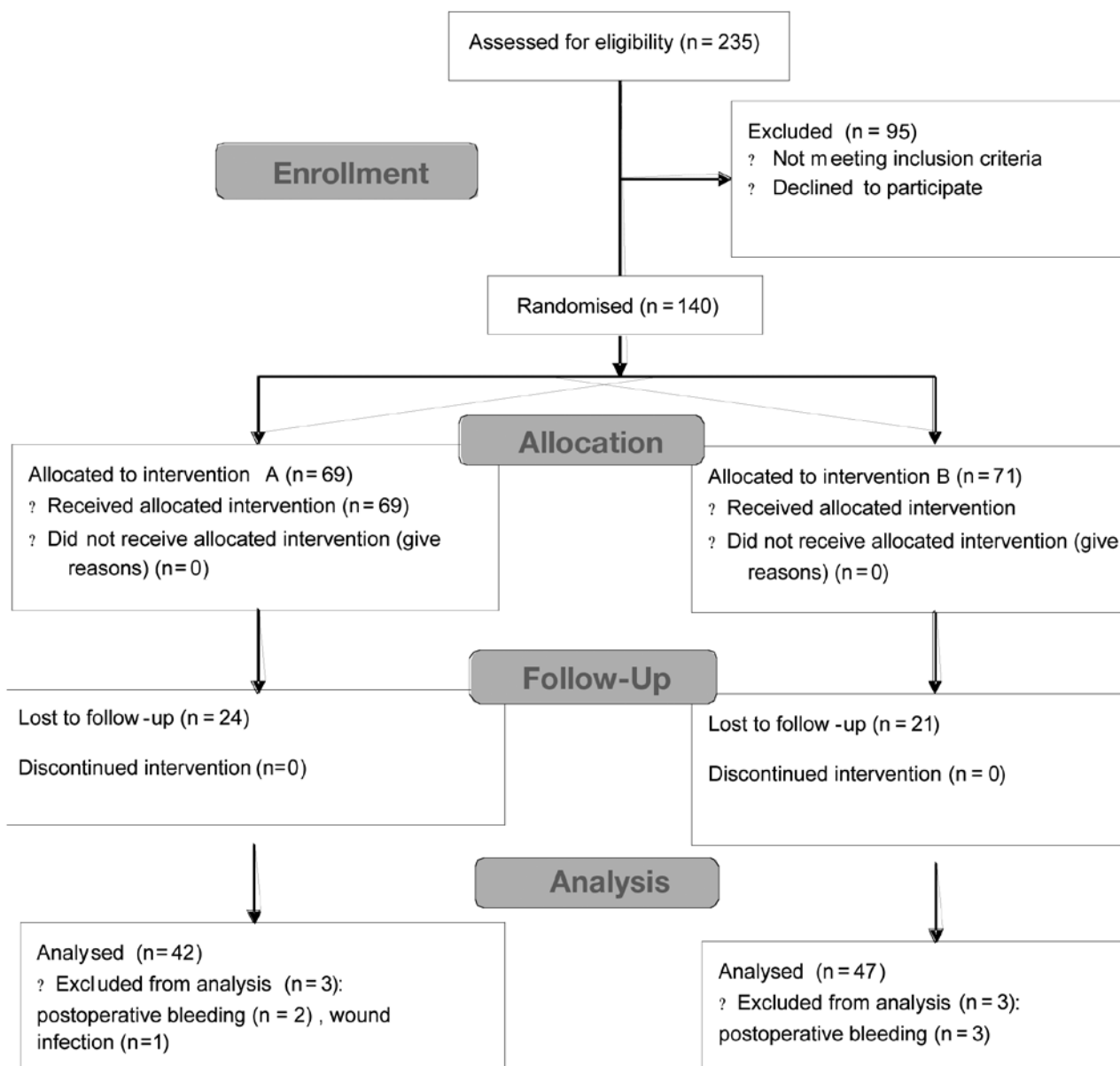


Fig 1. Flow-chart (according to CONSORT 2010).

**Table I.** Patient summary.

	A				B				Overall			
	N	%	Mean	SD	N	%	Mean	SD	N	%	Mean	SD
Patients (total)	42	47.19			47	52.81			89	100		
Sex												
<i>f</i>	32	76.19			37	78.72			69	77.53		
<i>m</i>	10	23.81			10	21.28			20	22.47		
Age	42	100	53.12	13.14	47	100	53.57	15.19	89	100	53.36	14.18

of wound infection. Three patients were excluded from group B analyses because of post-operative bleeding. In total, 42 patients from study group (A) and 47 patients from control group (B), in total 89 patients, were analysed per protocol (Tab. I). Aesthetic results are summarised in Table II.

#### Main outcome

The mean of the endpoint of group A at 10 days was 1.4, while that of group B was 2.9. A statistically significant ( $p = 0.002$ ) and clinically significant (difference of the means = 1.5) difference in the aesthetic results was found between groups A and B at 10 days, with better results in group B. On the other hand, at 3 months, the mean of the endpoint in group A was 3.1 while in group B it was 2.8. No statistically significant ( $p = 0.62$ ) or clinically significant (difference in means = 0.3) difference was found between groups A and B at 3 months.

#### Secondary outcomes

Concerning other ad-hoc analyses, none showed a statistically significant difference either at 10 days or at 3 months, apart from incision length at 3 months, which appeared to favour better aesthetic results at 3 months in the case of larger incisions (> 7 cm, mean length;  $p = 0.04$ ). However, it did not show a clinically significant difference (0.7). Mean incision length was 6.9 cm (range 4-11). Other post-hoc analyses

Statistically significant differences were found for the subheading 'step-off of the margins' ( $p = 0.007$ ), 'margin separation' ( $p = 0.01$ ), 'margin eversion' ( $p = 0.03$ ) and 'overall appearance' ( $p = 0.03$ ) in the 10-day endpoint scale, with better results for subcuticular sutures. None of the other single parameters analysed showed a statistically significant difference, either at 10 days or at 3 months.

## Discussion

In head and neck surgery, there is widespread use of skin-absorbable sutures performed with intradermic continuous suture. This kind of suture has many benefits: for example, little tissue reaction, rapid reduction and absence of mark points. On the other hand, one possible disadvantage is a rapid decrease in tensile strength<sup>6</sup>.

**Table II.** Aesthetic results.

	Mean aesthetic results (N)		Difference (in absolute value)	p
	A (42)	B (47)		
<b>A vs B</b>				
10 days	1.4	2.9	1.5	0.002
3 months	3.1	2.8	0.3	0.62
	Yes (55)	No (34)		
<b>Wrinkle correspondence</b>				
10 days	2.1	2.1	0	0.86
3 months	2.9	2.9	0	0.77
<b>Age</b>	≤ 45 (26)	> 45 (63)		
10 days	2.1	2.1	0	0.87
3 months	2.9	3	0.1	0.55
<b>Incision length</b>	≤ 7 cm (60)	> 7 cm (29)		
10 days	2.1	2.2	0.1	0.54
3 months	2.7	3.4	0.7	0.04
<b>Blade (cold/hot)</b>	Cold (81)	Hot (8)		
10 days	2.1	2.1	0	0.79
3 months	3	3	0	0.76
<b>Sex</b>	Male (20)	Female (69)		
10 days	2.1	2.1	0	0.24
3 months	3	2.9	0.1	0.2

The use of tissue glue (e.g. butylcyanoacrylate, octylcyanoacrylate) is currently popular for closure of superficial lacerations, especially in children. The cyanoacrylate group of tissue adhesives has been studied for use in surgical procedures for over 40 years<sup>7</sup>. These adhesives work by polymerising in an exothermic reaction when contacting a fluid or basic medium. For a number of years, the first widely used variety was *N*-butyl-2-cyanoacrylate<sup>8</sup>. This particular adhesive is significantly weaker than conventional monofilament sutures and is not particularly flexible<sup>9</sup>. More recently, a new tissue adhesive designed to address the limitations of the butyl-2-cyanoacrylate

group, 2-octyl cyanoacrylate (Dermabond; Ethicon Inc., Norwood, MA USA), has been approved by the US FDA. This cyanoacrylate has more flexibility and greater breaking strength, and may therefore be indicated for use in a wider variety of wound types<sup>10</sup>. In the literature, several practical advantages of cyanoacrylates have been noted. In particular, they are less time-consuming to apply than sutures, leading to shorter, more efficient patient encounters with less need for nursing, monitoring and sedation<sup>2</sup>. For all these reasons, cyanoacrylates are often used for the closure of excisional wounds in children. Moreover, since cyanoacrylates form an antibacterial barrier over the incision, sterility is maintained even without the application of topical antibiotics<sup>11</sup>. Regarding the aesthetic outcomes, there have been reports suggesting acceptable cosmetic outcome of wounds closed with tissue adhesive in the repair of simple lacerations and surgical incisions under lower tension<sup>12</sup>.

In a study carried out in 2002, the cosmetic results of the cyanoacrylate group were equal to or better than suture-closure with absence of suture marks, and possibly a lower degree of scar formation due to minimum handling of the tissue<sup>13</sup>. Another study showed that cyanoacrylate tissue adhesive is associated with a low rate of dehiscence, low infection rate and provides excellent cosmetic results for closure of both traumatic lacerations and surgical incision with results comparable to those obtained with standard wound closure techniques<sup>14</sup>. On the other hand, other studies<sup>2</sup> have shown that cosmetic outcome is significantly better in patients treated with conventional sutures.

In general, several publications have shown good cosmesis and faster times of skin closure using glue for laceration closure<sup>15</sup>. There are, however, only a few studies looking at tissue glue for surgical incisions. Moreover, these include different types of incisions with varying lengths and different locations<sup>16</sup>. Our study focused exclusively on post-thyroidectomy incisions. This type of incision is particularly important from an aesthetic point of view not only because of its exposed and visible location, but also because of the predominance of thyroidectomy in women. Furthermore, the incidence of this disease peaks in the third and fourth decades of life<sup>17</sup>.

Based on our results, and considering primary outcome, a difference in aesthetic results between sutures was found at 10 days. Statistically significant ( $p = 0.002$ ) and clinically significant (difference of the means = 1.5) differences in aesthetic results were found between groups A and B at 10 days, with better results in group B. These results were attributed to an increased step-off, eversion or separation of the margins, based on the results of post-hoc subheadings analyses. Thus it seems that the poorer results with glue may be attributed to a poorer juxtaposition of the margin, both in excessive, insufficient or irregular juxtaposition. On the other hand, at 3 months, no statistically significant ( $p = 0.62$ ) or clinically significant

(difference in means = 0.3) differences were found between groups A and B.

Regarding other ad-hoc analyses, none showed a statistically significant difference either at 10 days or at 3 months, apart from incision length at 3 months, which showed better aesthetic results at 3 months in the case of larger incisions ( $> 7$  cm, mean length;  $p = 0.04$ ), but this did not reach a clinically significant difference (0.7 of the end point scale), and the imbalanced number of patients ( $60 \leq 7$  cm vs  $29 > 7$  cm) between groups could have biased the results.

The results of our primary outcome are in accordance with some literature studies, where it has been found that the kind of suture employed did not have an important influence on aesthetic results at 3 months<sup>13</sup>.

In present study, two different scales were used at 10 days and three months<sup>4,5</sup>. As reported in the methods section, only one plastic surgeon rated the results, and multiple raters weren't used since the scales had already been validated by former studies, and thus did not require further investigations concerning interobserver or intraobserver variability and reliability. We would like also to emphasize that as the per protocol analyses was chosen in advance, since a considerable drop-out was expected due to the large proportion of patients coming to our institution from outside the region. Most of these patients completed their follow-up by referring to ENT specialists, endocrinologists or family doctors that sent them to us only for the operation. Nevertheless, a per protocol analysis was considered acceptable, since the drop-out was not considered to be related to a particular kind of suture, and moreover, the drop-out rate is balanced between groups (35% group A vs 30% group B). The exclusion of 5 (3.5%) patients out of 140 randomised, was motivated by post-operative bleeding: in these cases, the sutures were completely removed, without any significant difference in management of airway obstruction between group A and B, and then placed again after haemostasis.

The authors emphasise that aesthetic results are not the only important factors that must be considered when analysing suture materials and other factors may play a role in the final choice of material. First of all costs, but also operating times, which were not systematically measured in our study, although we can empirically confirm what had already been reported in the literature, i.e. the glue is faster to apply compared to traditional sutures<sup>14</sup>. We also recommend that adequate information be given to medical and nursing personnel when introducing new materials such as glue into clinical practice, since there may be some aspects that could significantly alter performance, and thus the results of the study. In particular, for glue it is very important to avoid contact of the wound with water or other dressing materials, and in general to avoid the adhesive part of the dressings coming into contact with the wound. Therefore, the medical and nursing staff



need proper information about the use of this new material, which should be provided before starting the study, in order to avoid systematic biases related to incorrect management of patients who received study treatment. The results of this study should be confirmed by similar experiences with other individual head and neck regions (such as the parotid region of the face).

## Conclusions

Synthetic glue differs from subcuticular sutures in post-thyroidectomy or post-parathyroidectomy incision, with better aesthetic results for subcuticular sutures in the early stages. However, at 3 months, there are no differences in aesthetic outcomes between synthetic glue and subcuticular sutures. Moreover sex, incision length, age, cold/hot blade and correspondence of the incision with a wrinkle of the skin did not seem to influence aesthetic outcomes in this type of incision.

## References

- <sup>1</sup> Swanson NA, Tromovitch TA. *Suture materials, 1980s: properties, uses, and abuses*. Int J Dermatol 1982;21:373-8.
- <sup>2</sup> Bernard L, Doyle J, Friedlander SF. *A prospective comparison of octyl cyanoacrylate tissue adhesive (Dermabond) and suture for the closure of excisional wounds in children and adolescent*. Arch Dermatol 2001;137:1177-80.
- <sup>3</sup> Nagataki S, Nyström E. *Epidemiology and primary prevention of thyroid cancer*. Thyroid 2002;12:889-996.
- <sup>4</sup> Hollander JE, Singer AJ, Valentine S, et al. *Wound registry: development and validation*. Ann Emerg Med 1995;25:675-85.
- <sup>5</sup> Singer AJ, Arora B, Dagum A, et al. *Development and validation of a novel scar evaluation scale*. Plast Reconstr Surg 2007;120:1892-97.
- <sup>6</sup> Brown JK, Campbell BT, Drongowski RA, et al. *A prospective, randomized comparison of skin adhesive and subcuticular suture for closure of pediatric hernia incisions: cost and cosmetic considerations*. J Pediatr Surg 2009;44:1418-22.
- <sup>7</sup> Coover HN, Joyner FB, Sheerer NH, et al. *Chemistry and performance of cyanoacrylate adhesive*. Special Tech Papers 1959;5:413-7.
- <sup>8</sup> Toriumi DM, Raslan WF, Friedman M, et al. *Histotoxicity of cyanoacrylate tissue adhesives*. Arch Otolaryngol Head Neck Surg 1990;115:546-50.
- <sup>9</sup> Noordzij JP, Foresman PA, Rodeheaver GT, et al. *Tissue adhesive wound repair revisited*. J Emerg Med 1994;12:645-9.
- <sup>10</sup> Perry LC. *An evaluation of acute incisional strength with traumaseal surgical tissue adhesive wound closure*. Leonia, NJ: Dimensional Analysis Systems Inc 1995.
- <sup>11</sup> Elmasalme FN, Matbouli SA, Zuberi MS. *Use of tissue adhesive in the closure of small incisions and lacerations*. J Pediatr Surg 1995;30:837-8.
- <sup>12</sup> Quinn JV, Wells GA, Sutcliffe T, et al. *Tissue adhesive versus suture wound repair at 1 year*. Ann Emerg Med 1998;32:645-9.
- <sup>13</sup> Ong CC, Jacobsen AS, Joseph VT. *Comparing wound closure using tissue glue versus subcuticular suture for pediatric surgical incisions: a prospective, randomised trial*. Pediatr Surg Int 2002;18:553-5.
- <sup>14</sup> Singer AJ, Quinn JV, Clark RE, et al. *Closure of lacerations and incisions with octylcyanoacrylate: a multicenter randomized controlled trial*. Surgery 2002;131:270-6.
- <sup>15</sup> Singer AJ, Quinn JV, Hollander JE. *Comparison of octylcyanoacrylate and standard wound closure methods for lacerations and incisions: a multi-center trial*. Acad Emerg Med 2001;18:538.
- <sup>16</sup> Toriumi DM, O'Grady K, Desai D, et al. *Use of octyl-2-cyanoacrylate for skin closure in facial plastic surgery*. Plast Reconstr Surg 1998;102:2209-19.
- <sup>17</sup> Nagataki S, Nyström E. *Epidemiology and primary prevention of thyroid cancer*. Thyroid 2002;12:889-96.

Received May 8, 2013 - Accepted: December 9, 2013

Address for correspondence: Federico Maria Gioacchini, Otolaryngology-Head and Neck Surgery Department, University Hospital of Modena, via del Pozzo 71, 41100 Modena, Italy. E-mail: giox83@hotmail.com