Cavoportal Hemitransposition: A Successful Way to Overcome the Problem of Total Portosplenomesenteric Thrombosis in Liver Transplantation

Giorgio E. Gerunda,[*] Roberto Merenda,[*] Daniele Neri,[*] Paolo Angeli,[†] Franco Barbazza,[*] Michele Valmasoni,[*] Paolo Feltracco,[‡] Fabio Zangrandi,[*] Antonio Gangemi,[*] Diego Miotto,[§] Alessandro Gagliesi,[*] and Alvise Maffei Faccioli[*]

Orthotopic liver transplantation (OLT) may be feasible even in the presence of diffuse portal vein thrombosis (PVT) in the recipient, providing hepatopetal portal flow to the graft can be ensured. Cavoportal hemitransposition was used in selected cases in which no other salvage solutions were technically possible. We report our experience of two patients with diffuse thrombosis of the entire portal system. One patient also had thrombosis of a previous portacaval shunt with a synthetic interposition graft. Portal pedicle dissection and native hepatectomy (with or without vena cava removal) appeared difficult. Bleeding from the exposed area was severe, and in one case, a new laparotomy was necessary to stop the abdominal hemorrhage. The postoperative course was complicated by severe ascites (with fluid infection and surgically drained suprahepatic abscess in one case), renal insufficiency (requiring dialysis in one case), esophagogastric variceal bleeding (needing several sessions of endoscopic treatment), and bronchopneumonic infections (in one case, superinfection with *Aspergillus fumigatus* despite amphotericin B lipid complex therapy led to the patient's death from multiorgan failure). Our experience was compared with 17 other cases in the literature. Etiologic factors, preoperative diagnostics, surgical problems, and postoperative complications are focused on and discussed. Diffuse PVT no longer appears to be an absolute contraindication to OLT, although cavoportal hemitransposition needs further experience and long-term follow-up. (*Liver Transpl 2002;8:72-75.*)

In the past, portal vein thrombosis (PVT) was considered an absolute contraindication to orthotopic liver transplantation (OLT) because of both the technical difficulties it entails[1] and the need for adequate hepatopetal portal flow to the liver graft, at least in the short term.[2] In recent years, innovative surgical techniques have been introduced (e.g., thrombectomy, the use of venous jump grafts or portal vein tributaries), and many obstacles have been overcome.[3,4] In particularly severe cases, potential salvage solutions have been used, such as combined liver and small-bowel transplantation, arterialization of the graft's portal vein,[5] or cavoportal hemitransposition.[6,7] We report our experience with cavoportal hemitransposition in two patients treated surgically for diffuse thrombosis of the portal system and discuss our experience in light of reports from six centers on another 17 cases.

Patients and Methods

In our series of more than 250 patients undergoing OLT, 2 patients had total thrombosis of the entire portal system, and the only feasible solution to overcome the problem and complete OLT successfully was to divert total caval flow into the portal vein.

Patient 1

A 57-year-old man who presented with alcoholic and hepatitis B virus–related cirrhosis, severe chronic encephalopathy, intractable ascites, and high risk for bleeding from large esophagogastric varices, classified as Child's grade C, underwent OLT. At laparotomy, no portal system vein was found to be patent. Severe bleeding occurred, particularly from the portal pedicle and diaphragmatic area. The native hepatectomy, technically demanding because of severe portal hypertension, was performed using the piggyback technique (sparing the vena cava), which enabled us to operate without extracorporeal venovenous bypass. Suprahepatic caval anastomosis was performed using the technique of Belghiti et al,[8] and arterial anastomosis was performed in an end-to-end fashion. Cavoportal anastomosis was end to side, and flow through the inferior vena cava (IVC) was uninterrupted until reperfusion, when the IVC was ligated flush with the anastomosis to avoid the thrombotic risk for a vein cul de sac. The right adrenal vein was ligated to prevent the development of collateral flow through that vein.[6] The hepatic artery and portal vein were unclamped simultaneously, as usual.[9] Biliary anastomosis was performed by means of a Roux-en-Y loop.

*From the *Department of Medical and Surgical Sciences, III Surgical Clinic; Departments of †Anesthesiology and ‡Clinical and Experimental Medicine, V Medical Clinic; and the §Department of Radiology, Padua University, Padua, Italy.*

Address reprint requests to Giorgio E. Gerunda, MD, Dipartimento di Scienze Mediche e Chirurgiche-Clinica Chirurgica III, Policlinico Universitario, Via Giustiniani, 2, 35128 Padova, Italy. Telephone: +39-049-821-2253; FAX: +39-049-821-2250; E-mail: giorgio.gerunda@unipd.it

1527-6465/02/0801-0017$35.00/0
doi:10.1053/jlts.2002.30404

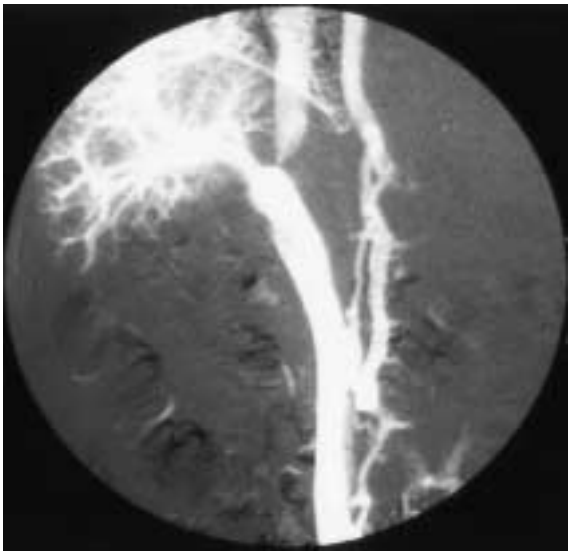

Figure 1. Side-to-end cavoportal anastomosis between the native vena cava and graft portal vein. Part of the caval flow is diverted away from the liver through the paravertebral plexus into the azygos vein despite ligature of the right adrenal vein.

Controlling hemorrhage, particularly from the portal pedicle and diaphragmatic area, was difficult and took a long time. Cold and warm ischemia times were 9½ hours and 70 minutes, respectively. Twelve units of blood were transfused.

In the postoperative period, the patient developed severe ascites (protein, 14 g/L), which favored spontaneous bacterial peritonitis and a subsequent suprahepatic abscess, which was drained surgically. The patient's clinical condition worsened, with the onset of renal failure and severe variceal bleeding controlled by endoscopic banding; however, Doppler ultrasonography confirmed the patency of all vessels (hepatic artery, portal vein, hepatic veins, renal veins, and vena cava). The patient was treated with FK506, mycophenolate mofetil, and low doses of steroids for immunosuppression.

After 2 months, the patient's general condition improved significantly, and he was discharged with mild ascites (treated with low doses of diuretics) and persistent esophageal varices undergoing serial endoscopic treatment. After 6 months, varices were eradicated, and cavography showed a patent side-to-end cavoportal anastomosis with normal portohepatic perfusion. Unfortunately, part of the caval flow was diverted away from the liver through the paravertebral plexus into the azygos vein despite ligature of right adrenal vein (Fig. 1). After follow-up of 12 months, the patient is alive and well.

Patient 2

A 55-year-old man presented with alcohol-related cirrhosis and a previous clotted portacaval shunt with an 8-mm ring-reinforced Gore-Tex prosthesis (Gore-Tex Medical Products, Flagstaff, AZ) interposition graft according to Sarfeh et al.[10] He was classified as Child's class C, with severe chronic encephalopathy and intractable ascites, and underwent OLT.

Preoperative angiography and Doppler ultrasound showed persistent portal and graft perfusion; however, at laparotomy, the vessels were found to be completely occluded. The operation was particularly difficult because of dense vascular hepatocolic adhesions secondary to severe and recurrent spontaneous bacterial peritonitis, which caused continuous blood loss during dissection. The native hepatectomy was performed using the conventional technique, using the inferior mesenteric vein for portal outflow from the venovenous bypass (flow was minimal; ~200 to 300 mL/min), with no significant benefit in reducing venous hypertension. The presence of hypertensive portal cavernoma made it impossible to dissect pedicle elements (portal vein, hepatic artery, and biliary conduit) and obliged us to ligate them all together. The right adrenal vein was ligated to prevent collateral flow developing through it, as reported elsewhere.[6] Suprahepatic caval anastomosis was performed using the conventional technique. The cavoportal anastomosis was performed in end-to-end fashion using the growth factor to adjust for the discrepancy between the veins. Arterial inflow was provided using the native hepatic artery in a side-to-end fashion without freeing it from the portal pedicle; it was impossible to use an interposition graft from the suprarenal aorta because of severe coloileomesenteric engorgement and high risk for bleeding. The portal vein was unclamped first, followed by reconstruction and unclamping of the hepatic artery. No biliary anastomosis was performed because the native choledochus was not free from the cavernoma; thus, the donor biliary tree was drained outside the abdomen by means of a Silastic tube (Rusch Hospital 20030-Varedo [Milano], Italy). Cold and warm ischemia times were 10 hours and 62 minutes, respectively. Fourteen units of blood were transfused.

When the OLT was over, bleeding persisted in the abdominal cavity and the patient underwent laparotomy again the next day. The bleeding was stopped, and biliary anastomosis was performed using a Roux-en-Y loop because the mesenteric engorgement appeared to have decreased significantly. Postoperatively, the patient developed severe ascites (protein, 12 g/L) and renal failure needing numerous dialysis sessions. Doppler ultrasonography confirmed patency of all vessels (hepatic artery, portal vein, hepatic veins, renal veins, and vena cava). The patient had large esophageal varices treated first with elective endoscopic banding, but unfortunately needing emergency endoscopic sclerotherapy to deal with severe successive esophagogastric bleeding. The patient was treated with FK506, mycophenolate mofetil, and low doses of steroids for immunosuppression.

Postoperative day 10, the patient developed an acute rejection episode (successfully responding to treatment with 2 g of steroids) and concomitant bronchopneumonic infection caused by *Candida* species and *Aspergillus fumigatus*, treated with 5 mg/kg/d of amphotericin B lipid complex (Abelcet; Wheth Lederle, Liposome Co, LTD, London, England). The patient's condition slowly worsened. Steroid therapy was dis-

continued, and FK506 levels were maintained at approximately 10 μg/L. Ascites required paracentesis almost once a week, and transaminase and cholestatic enzyme levels increased considerably when the abdomen was tense. After abdominal evacuation, enzyme levels promptly normalized. After 42 days, the patient experienced a severe rejection episode, treated with three 1-g steroid boluses. After an initially positive response, transaminase levels increased again to more than 2,000 IU, and the patient died of multiorgan failure.

Discussion

In the past, PVT has been considered an absolute contraindication to OLT.[1] In recent years, experience has been gained in various centers, and many reports have emerged indicating the feasibility of OLT even in the presence of PVT by using various techniques.[3-5,11,12]

Cavoportal hemitransposition has been proposed as a salvage procedure in diffuse portal vein thrombosis when no other solution is technically feasible.[6,7,13,14]

The incidence of PVT in patients with cirrhosis varies between 0.6% and 64.1%, depending on diagnostic methods used, patient selection, and considerations on the entity of thrombosis (partial or complete, with or without cavernoma).[15,16] Some factors seem to be associated with PVT, i.e., male sex, previous treatment for portal hypertension (sclerotherapy, transjugular intrahepatic portosystemic shunt, shunt surgery, splenectomy, gastric devascularization), Child's class C, alcoholic liver disease,[4,17] and autoimmune and cryptogenic cirrhosis.[18] Although there is no clear-cut explanation for this thrombotic tendency, it is probably related to increased intrahepatic resistance to portal flow caused by the atrophied cirrhotic liver in combination with coagulation abnormalities.

Only 17 cases are reported elsewhere in the literature of cavoportal hemitransposition in patients with total splanchnic thrombosis.[6,7,13,14] Considering these series with our own, we found that previous abdominal procedures (four extensive previous abdominal operations), particularly surgical treatment for bleeding esophageal varices (three splenectomies, three gastric devascularizations, two thrombosed shunts) represented the prevalent anamnestic element in 63% of cases (12 of 19 cases) in the clinical history of these patients. Moreover, they had from mild to severe encephalopathy in 58% of cases (11 of 19 cases) and (often refractory) ascites in 74% of cases (14 of 19 cases). In all but 2 cases, pre-OLT workups showed PVT, although in our second patient, Doppler study seemed to identify some flow in the portal vein and graft, probably misinterpreting some collaterals of portal cavernoma. In 42% of cases (8 of 19 cases), the vena cava was left in situ during the native hepatectomy, whereas in the other 11 cases, it was removed. In 3 patients in the group in which the vena cava was spared and 10 patients in the group in which the vena cava was removed, cavoportal anastomosis was performed in an end-to-end fashion, whereas in 2 cases, it was side to end (with a ligature flush to the anastomosis to prevent the thrombotic risk for a caval cul de sac). In one case, a cavocaval and left renal vein to portal vein anastomosis was performed.[7] In 32% of cases (6 of 19 cases), venovenous bypass was used, and in 42% (8 of 19 cases), suprahepatic anastomosis was performed using the piggyback technique. In 32% of patients (6 f 19 patients), arterial anastomosis was needed, using an interposition graft from the aorta or celiac axis. In one case, the right hepatic artery was completely inside the portal cavernoma; thus, only a side-to-end anastomosis could be performed.

None of the patients showed early hyperperfusion of the liver when normal portal and arterial flows to the parenchyma were restored or the late extensive systemic venous inflow steal reported elsewhere.[19] However, concern for this congestion prompted one of the investigators to constrict the preserved IVC with a Dacron sleeve (Intervascular Inc, London, England), but this solution favored early postoperative cavoportal thrombosis. In one of our patients, only a minimal portion of portal flow was diverted away from the liver, without unfavorable hemodynamic effects (Fig. 1). In one patient, biliary flow was diverted outside the abdomen through percutaneous drainage during surgery because of severe colomesenteric engorgement. The next day, this was successfully normalized by a Roux-en-Y choledochojejunostomy. Portal hypertension persisted and made hemostasis difficult during OLT; in the postoperative period, variceal bleeding occurred in 37% of cases (7 of 19 cases), overcome by splenectomy, gastric devascularization or splenic artery embolization (3 cases), or endoscopic treatments. In all patients, with the exception of 1 patient without complications, severe ascites developed and appeared to regress either with diuretics or spontaneously with time. Postoperative Doppler or angiographic follow-up showed cavoportal shunt patency in 63% of cases (12 of 19 cases) and a late diffuse thrombosis extending from the iliac vein to the level of the cavoportal anastomosis in 1 patient. With effective anticoagulation therapy, caval thrombosis recovered after 6 months. Four patients developed biopsy-proven mild rejection, which responded to treatment with steroids. One patient had two episodes of severe rejection, and only one episode responded to steroid treatment. In the postoperative phase, all patients had increasingly severe ascites and

renal insufficiency caused by increased hepatic resistance to cavoportal flow; this was particularly evident when rejection was documented.[11,14]

Only 6 of 19 patients (32%) have died to date; 1 patient died of enteric leakage and sepsis, 2 patients died of primary nonfunction and sepsis, 1 patient died of fatal pulmonary embolism, and 2 patients died of severe sepsis and multiorgan failure. In all other patients, liver function appears to be normal or near normal and tends to improve with time.

In conclusion, although isolated PVT is no longer a contraindication to OLT, the diffuse form represents a very difficult problem to overcome. In such cases, cavoportal hemitransposition[6,7,13,14] could provide an acceptable solution, bearing in mind that diffuse PVT unfortunately can be an unexpected finding during laparotomy for OLT. Intraoperative radiographic evaluation of the portal vessels is useful,[18] but fails to provide sufficient information on technical difficulties that may be encountered on dissecting the vessels and biliary conduit. Therefore, a donor aortoiliac hepatic interposition graft and biliary Roux-en-Y anastomosis must always be considered.

Postoperatively, life-threatening complications may develop because of severe ascites with spontaneous bacterial peritonitis and bleeding esophagogastric varices or hypertensive gastropathy. In our opinion, these complications can be prevented: (1) by preventing an increase in IVC pressure caused by fluid overload soon after OLT, particularly when liver rejection is documented (increased hepatic resistance may favor abdominal liquid retention and the likelihood of bacterial translocation)[14]; (2) by checking for the presence of varices very soon after surgery and, when necessary, treating them endoscopically without delay; and (3) bleeding caused by hypertensive gastropathy may be very difficult to cure, even with intravenous infusion of vasoconstrictors (somatostatin or glypressin), or prevent with β-blockers. Several investigators have proposed more aggressive treatments instead, such as splenectomy, gastric devascularization, and splenic artery embolization.[6]

Long-term effects of systemic venous flow to the liver graft through a cavoportal hemitransposition are not known at this time. Bearing in mind that this procedure should always be considered exclusively a salvage measure, after we have a better understanding of its hemodynamic and clinical effects, we may find that diffuse PVT is no longer an absolute contraindication to OLT.

References

1. Van Thiel DH, Schade RR, Starzl TE. Liver transplantation in adults. Hepatology 1982;2:637-641.
2. Starzl TE, Francavilla A, Halgromson CG. The origin, hormonal nature, and action of hepatotrophic substances in portal venous blood. Surg Gynecol Obstet 1973;137:179-199.
3. Stieber AC, Zetti G, Todo S, Tzakis AG, Fung JJ, Marino I, et al. The spectrum of portal vein thrombosis in liver transplantation. Ann Surg 1990;213:199-202.
4. Yerdel MA, Gunson B, Mirza D, Karayalcin K, Ollif S, Buckerls J, et al. Portal thrombosis in adults undergoing liver transplantation. Transplantation 2000;69:1873-1881.
5. Troisi R, Kerremans I, Mortier E. Arterialization of the portal vein in pediatric liver transplantation. Transpl Int 1998;11:147-151.
6. Tzakis AG, Kirkegaard P, Pinna AD, Jovine E, Misiakos EP, Maziotti A, et al. Liver transplantation with cavoportal hemitransposition in the presence of diffuse portal vein thrombosis. Transplantation 1998;65:619-624.
7. Azoulay D, Hargreaves GM, Castaing D, Bismuth H. Caval inflow to the graft: A successful way to overcome diffuse portal system thrombosis in liver transplantation. J Am Coll Surg 2000; 190:493-496.
8. Belghiti E, Companis Y, Sauvanet B, Gayet B, Fekete F. A new technique of side to side caval anastomosis during orthotopic hepatic transplantation without vena caval occlusion. Surg Gynecol Obstet 1992;175:271-272.
9. Gerunda GE, Merenda R, Neri D, Barbazza F, Dimarzio E, Zangrandi F, et al. Liver transplantation with vena cava in situ and selective use of temporary porta caval shunt or portal clamping. Hepatogastroenterology 2001;48:486-492.
10. Sarfeh U, Rypins EB, Conroy RM, Mason GR. Portacaval H-graft: Relationship of shunt diameter, portal flow patterns and encephalopathy. Ann Surg 1983;197:422-426.
11. Seu P, Shackleton CR, Schaked A, Imagawa DK, Olthoff KM, Rudich SR, et al. Improved results of liver transplantation in patients with portal vein thrombosis. Arch Surg 1996;131:840-843.
12. Todo S, Reyes J, Furukawa H, Abu-Elmagd K, Lee RG, Tzakis A, et al. Outcome analysis of 71 clinical intestinal transplantations. Ann Surg 1995;222:270-275.
13. Olausson M, Norrby J, Mjornstedt L, Liden H, Friman S. Liver transplantation using cavoportal hemitransposition—A life-saving procedure in the presence of extensive portal vein thrombosis. Transplant Proc 2001;33:1329-1330.
14. Pinna AD, Nery J, Kato T, Levi D, Nishida S, Tzakis AG. Liver transplantation with hemitransposition: Experience at the University of Miami. Transplant Proc 2001;33:1329-1330.
15. Belli L, Sansalone C, Aseni P, Romani F, Rondinara G. Partial thrombosis in cirrhotics: A retrospective analysis. Ann Surg 1986;203:286-290.
16. Sarfeh IJ. Portal vein thrombosis associated with cirrhosis. Arch Surg 1979;114:902-905.
17. Peron JM, Barange K, Otal P, Rousseau H, Payen JL, Pascal JP, Vinel JP. Transjugular intrahepatic portosystemic shunts in the treatment of refractory ascites: Results in 48 consecutive patients. J Vasc Interv Radiol 2000;11;1211-1216.
18. Manzanet G, Sanjuan F, Orbis P, Lopez R, Maya A, Juan M, et al. Liver transplantation in patients with portal vein thrombosis. Liver Transpl 2001;7:125-131.
19. Meyer WH, Starzl TE. The reverse portacaval shunt. Surgery 1959;45:531-536.