

Case Report

Livedoid skin reaction to 2nd dose of mRNA Covid-19 vaccine

Ilaria Girolami¹, Klaus Eisendle², Reinhard Walther Kluge¹, Esther Hanspeter¹, Albino Eccher³, Leonardo Vizziello², Pierfrancesco Zampieri⁴, Guido Mazzoleni¹

¹ Department of Pathology, Provincial Hospital of Bolzano (SABES-ASDAA), Bolzano-Bozen, Italy; *Lehrkrankenhaus der Paracelsus Medizinischen Privatuniversität*; ² Department of Dermatology, Provincial Hospital of Bolzano (SABES-ASDAA), Bolzano-Bozen, Italy; *Lehrkrankenhaus der Paracelsus Medizinischen Privatuniversität*; ³ Department of Pathology and Diagnostics, University and Hospital Trust of Verona, Verona, Italy; ⁴ Department of Dermatology, Hospital of Merano (SABES-ASDAA), Merano-Meran, Italy; *Lehrkrankenhaus der Paracelsus Medizinischen Privatuniversität*

Summary

Skin often represents a target organ for adverse drug reactions and this also applies to the mRNA vaccines against Sars-CoV-2. Here we present a case of extensive livedoid reaction after 2nd dose of BNT162b-2 vaccine with massive blood skin extravasation and no systemic symptoms apart from anemization. The 30-year-old woman developed progressively enlarging livedoid lesions on limbs and abdomen. Histology showed a near-normal epidermis and a very mild interstitial mixed inflammatory infiltrate with extensive blood extravasation in mid- and deep dermis. Diagnosis was adverse reaction to vaccine with skin capillary hyperpermeability and anaemization with lower than diagnostic features of cutaneous small vessel vasculitis. To date, no cases of a livedoid skin reaction associated to Covid-19 vaccine have been reported, and this case illustrates that massive livedoid reaction can be another kind of skin reaction to mRNA Covid-19 vaccine.

Key words: Covid-19 vaccine, drug eruption, skin, mRNA vaccine

Introduction

Skin often represents a target organ for adverse drug reactions and this also applies to the mRNA vaccines against Sars-CoV-2. Several skin reaction patterns have been reported, with apparent prevalence of injection-site reactions of delayed hypersensitivity type, the so-called COVID-arm^{1,2}, reactivation of herpes zoster virus, urticarial³ morbilliform⁴ and pityriasis rashes⁵⁻⁷. As highlighted in many studies, the clinico-pathological spectrum of cutaneous side effects with COVID-19 vaccines is wide^{8,9}. Less commonly reported are vasculitis^{9,10}, lichenoid/interface damage^{9,11} pattern reactions and purpuric rashes⁵⁻⁷. Here we present a case of extensive livedoid reaction after 2nd dose of BNT162b-2 vaccine with massive blood skin extravasation, little inflammation and sparse intraluminal material in small vessels as histopathological findings.

Case report

The patient was a 30-year-old woman with no family history of skin or autoimmune disease or vaccine reactions, who received priority vaccination with BNT162b-2 vaccine as a caregiver of an ill relative. She always

Received: January 9, 2022
Accepted: March 30, 2022

Correspondence

Ilaria Girolami
Department of Pathology, Provincial Hospital of Bolzano (SABES-ASDAA), Bolzano-Bozen, Italy; *Lehrkrankenhaus der Paracelsus Medizinischen Privatuniversität*, via L. Boehler 5, 39100 Bolzano, Italy
Tel.: 0471 43 81 53
Fax: 0471 43 81 75
E-mail: ilaria.girolami@sabes.it

How to cite this article: Girolami I, Eisendle K, Kluge RW, et al. Livedoid skin reaction to 2nd dose of mRNA Covid-19 vaccine. *Pathologica* 2022;114:322-325. <https://doi.org/10.32074/1591-951X-746>

© Copyright by Società Italiana di Anatomia Patologica e Citopatologia Diagnostica, Divisione Italiana della International Academy of Pathology



OPEN ACCESS

This is an open access journal distributed in accordance with the CC-BY-NC-ND (Creative Commons Attribution-NonCommercial-NoDerivatives 4.0 International) license: the work can be used by mentioning the author and the license, but only for non-commercial purposes and only in the original version. For further information: <https://creativecommons.org/licenses/by-nc-nd/4.0/deed.en>

tested negative for Covid-19 during the pandemic and also during the early period before and after vaccination. Her medical history was remarkable only for skin transplantation on the left underarm after a domestic accident with boiling oil in the period between the two doses of vaccine. Approximately two days after the second dose, she developed progressively enlarging livedoid lesions on the proximal and distal lower limbs, abdomen and partly proximal upper limbs, with no involvement of the injection site. Lesions were non-palpable, warm at touch, not itching, not relevantly painful and with general aspect of ecchymosis (Fig. 1A, B). The patient accessed the Emergency Department for concomitant vomiting and refractory epistaxis, with no fever or respiratory or cardiocirculatory symptoms. Diagnostic workup revealed anemia, but Coombs's test for hemolytic anemia and coagulation tests were negative. Leukocyte and platelets counts were in the range of normal. Skin biopsy was performed in right arm before administration of corticosteroid therapy. Histology showed a superficial biopsy with near-normal epidermis and a mild interstitial mixed inflammatory infiltrate with neutrophils and rare eosinophils with extensive blood extravasation in mid- and deep dermis

(Fig. 1C). No nuclear dust nor intraluminal fibrinoid material was apparent. The patient was investigated for autoimmune disease with broad autoantibody testing and found positive to lower-level anti-nuclear antibodies. Corticosteroid oral therapy was administered with partial benefit and in the following days ecchymotic lesions showed both enlargement and evolution towards resolution like normal bruises. Vasculitis was suspected with question on its nature as vaccine reaction or part of a pre-existent autoimmune disease, thus a larger and deeper skin biopsy was performed in right calf with additional punches for direct immunofluorescence (IF) examination. Histology showed disappear of eosinophils, persistence of inhomogeneous distribution of blood extravasation in dermis and subcutaneous adipose tissue, and isolated signs of intraluminal congestion of capillary vessels of adipose tissue and septal bundles with fibrinoid material and endothelial swelling (Fig. 1D, inset). IF examinations for immunocomplexes with IgG, IgM, IgA and C3 were negative. Clinical course improved slowly with gradual resolution of anemia and clearing of ecchymotic lesions, and repeated autoantibody testing was negative. The main differential diagnoses were a

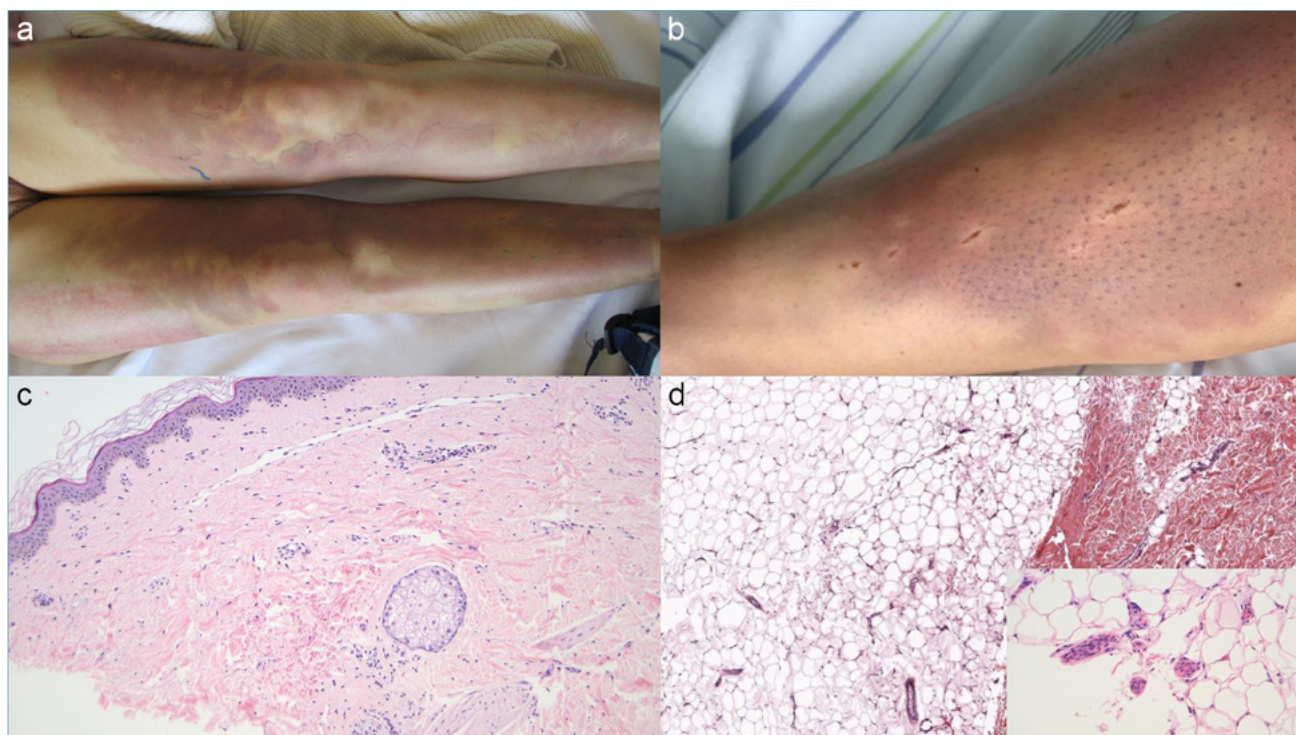


Figure 1. Livedoid reaction on lower limbs (A, B). Histology of first (C) and second (D) biopsy showing only mid and deep dermis blood extravasates, with isolate intraluminal material and endothelial swelling (D, inset). Hematoxylin-eosin, original magnification 100x (C, D), 400x (inset).

livedoid vasculopathy/atrophie blanche with the clinical appearance of livedo reticularis and a chronic lymphocytic vasculitis with only slight presence of intraluminal capillary congestion and endothelial swelling, triggered as an adverse reaction to the vaccine.

Discussion

Several skin reaction patterns have been reported against Sars-Cov-2 mRNA vaccines, with apparent prevalence of injection-site reactions of delayed hypersensitivity type, the so-called COVID-arm^{1,2}, reactivation of herpes zoster virus, urticarial³, morbilliform⁴ and pityriasis rashes⁵⁻⁷. Less commonly reported are vasculitis^{9,10}, lichenoid/interface damage^{9,11} pattern reactions and purpuric rashes⁵⁻⁷.

To date, no cases of a livedoid skin reaction associated to Covid-19 vaccine have been reported. However, it is reported that vaccination can mimic Sars-CoV-2 infection itself¹², with pernio/chilblains-like lesions, vesicular eruptions⁷, and, more recently, multisystem inflammatory syndrome¹³. Our case presented subtle features of difficult pathogenetic explanation, with imposing appearance of blood extravasation with anaemization, little morphological evidence of cellular inflammation but barely detectable intraluminal material and no detectable coagulative alterations nor evidence of immunocomplex disease. It could be speculated that vaccination triggered a reaction with both systemic and localized features, with the skin as the main organ involved in a patient that already had an activated inflammatory background in the skin compartment because of her recent medical history of burns. Even though hyperpermeability and epistaxis cannot be considered the direct cause of anemia in this patient, it is possible that the proinflammatory background might have emphasized a subclinical predisposition. This could be reasonable given the absence of other systemic symptoms such as fever or localized organ damage or skin lesions clearly attributable to a vasculitic or toxic process, if considering epistaxis as a limited mucosal counterpart of skin blood extravasation. The main differential diagnoses were a livedoid vasculopathy and a chronic lymphocytic vasculitis with slight presence of intraluminal capillary congestion and endothelial swelling. Both livedoid vasculopathy and vasculitides can show different and subtle morphology depending on the age of the lesion, with some authors considering livedoid vasculopathy/atrophie blanche (with clinical appearance of livedo reticularis) as lymphocytic vasculitis¹⁴, with definition of cutaneous lymphocytic vasculitis as requiring the presence of either acute or chronic damage to the walls of small vessels

(e.g., fibrin deposition, lamination by pericytes), and not necessarily all the features together¹⁵. Indeed, in our case the morphological features were very subtle and not clearly pointing towards an univocal diagnosis. However, the case may also be useful to dermatologists and general clinicians should be aware that massive livedoid reaction can be another kind of skin reaction to mRNA Covid-19 vaccine in patients with early previous skin surgical manipulation and despite evidence of immune damage requiring hospitalization. Thorough clinical and diagnostic workup with histological documentation and absence of clear-cut morphological damage in order to achieve diagnosis and enable correct management.

CONFLICT OF INTEREST

The authors declare no conflicts of interest.

FUNDING

None.

ETHICAL CONSIDERATION

The patient in this manuscript gave consent to publication of the case.

AUTHOR CONTRIBUTIONS

IG wrote the draft of the manuscript. KE, RWK, LV, PZ collected and analyzed data of the case. KE, RWK, EH, AE, GM contributed to the discussion of the case and the preparation of the manuscript. All the authors reviewed and approved the final manuscript.

References

- Kempf W, Kettelhack N, Kind F, et al. 'COVID arm' - histological features of a delayed-type hypersensitivity reaction to Moderna mRNA-1273 SARS-CoV2 vaccine. *J Eur Acad Dermatology Venereol Internet* 2021;35:e730-e732. <https://doi.org/10.1111/jdv.17506>
- Fernandez-Nieto D, Hammerle J, Fernandez-Escribano M, et al. Skin manifestations of the BNT162b2 mRNA COVID-19 vaccine in healthcare workers. 'COVID-arm': a clinical and histological characterization. *J Eur Acad Dermatology Venereol Internet* 2021;35:e425-427. <https://doi.org/10.1111/jdv.17250>
- Baraldi C, Boling LB, Patrizi A, et al. Unique case of urticarial skin eruptions after COVID-19 vaccination. *Am J Dermatopathol Internet* 2022;44:198-200. <https://doi.org/10.1097/DAD.0000000000002036>
- Ohsawa R, Sano H, Ikeda M, et al. Clinical and histopathological views of morbilliform rash after COVID-19 mRNA vaccination mimic those in SARS-CoV-2 virus infection-associated cutaneous manifestations. *J Dermatol Sci Internet* 2021;103:124-127. <https://doi.org/10.1016/j.jdermsci.2021.06.006>
- Catalö A, Muñoz-Santos C, Galván-Casas C, et al. Cutaneous reactions after SARS-COV-2 vaccination: a cross-sectional Spanish nationwide study of 405 cases. *Br J Dermatol Internet* 2022;186:142-152. <https://doi.org/10.1111/bjd.20639>
- Farinazzo E, Ponis G, Zelin E, et al. Cutaneous adverse reactions after m-RNA COVID-19 vaccine: early reports from Northeast Italy.

- J Eur Acad Dermatology Venereol Internet 2021;35:e548-e551. <https://doi.org/10.1111/jdv.17343>
- ⁷ McMahon DE, Amerson E, Rosenbach M, et al. Cutaneous reactions reported after Moderna and Pfizer COVID-19 vaccination: a registry-based study of 414 cases. *J Am Acad Dermatol Internet* 2021;85:46-55. <https://doi.org/10.1016/j.jaad.2021.03.092>
- ⁸ Niebel D, Wenzel J, Wilsmann-Theis D, et al. Single-center clinico-pathological case study of 19 patients with cutaneous adverse reactions following COVID-19 vaccines. *Dermatopathology Internet* 2021;8:463-476. <https://doi.org/10.3390/dermatopathology8040049>
- ⁹ Larson V, Seidenberg R, Caplan A, et al. Clinical and histopathological spectrum of delayed adverse cutaneous reactions following COVID-19 vaccination. *J Cutan Pathol Internet* 2022;49:34-41. <https://doi.org/10.1111/cup.14104>
- ¹⁰ Cohen SR, Prussick L, Kahn JS, et al. Leukocytoclastic vasculitis flare following the COVID-19 vaccine. *Int J Dermatol Internet* 2021;60:1032-1033. doi: 10.1111/ijd.15623
- ¹¹ Merhy R, Sarkis A, Kaikati J, et al. New-onset cutaneous lichen planus triggered by COVID-19 vaccination. *J Eur Acad Dermatology Venereol Internet* 2021;35:e729-e730. <https://doi.org/10.1111/jdv.17504>
- ¹² Satturwar S, Fowkes M, Farver C, et al. Postmortem Findings Associated With SARS-CoV-2. *Am J Surg Pathol Internet* 2021;45:587-603. <https://doi.org/10.1097/PAS.0000000000001650>
- ¹³ Salzman MB, Huang C-W, O'Brien CM, et al. Multisystem Inflammatory Syndrome after SARS-CoV-2 Infection and COVID-19 Vaccination. *Emerg Infect Dis Internet* 2021;27:1944-1948. <https://doi.org/10.3201/eid2707.210594>
- ¹⁴ Carlson JA, Mihm MC, LeBoit PE. Cutaneous lymphocytic vasculitis: a definition, a review, and a proposed classification. *Semin Diagn Pathol Internet* 1996;13:72-90.
- ¹⁵ LeBoit PE. Vasculitis: the true and the near-true. *Am J Dermatopathol Internet* 2002;24:267-269. <https://doi.org/10.1097/00000372-200206000-00015>