

*Original Research*

# Neuroanatomical Correlates of Cognitive Tests in Young-onset MCI

Chiara Carbone<sup>1,\*</sup>, Erica Balboni<sup>2,3</sup>, Daniela Beltrami<sup>4</sup>, Federico Gasparini<sup>4</sup>, Giulia Vinceti<sup>5</sup>, Chiara Galligani<sup>1,5</sup>, Davide Salvatori<sup>1,5</sup>, Simone Salemme<sup>1,5</sup>, Maria Angela Molinari<sup>5</sup>, Manuela Tondelli<sup>5</sup>, Alessandro Marti<sup>4</sup>, Annalisa Chiari<sup>5</sup>, Giovanna Zamboni<sup>1,5</sup>

<sup>1</sup>Department of Biomedical, Metabolic and Neural Sciences, University of Modena and Reggio Emilia, 41125 Modena, Italy

<sup>2</sup>Environmental, Genetic and Nutritional Epidemiology Research Center (CREAGEN), Department of Biomedical, Metabolic and Neural Sciences, University of Modena and Reggio Emilia, 41125 Modena, Italy

<sup>3</sup>Medical Physics Unit, Azienda Ospedaliero-Universitaria di Modena, 41125 Modena, Italy

<sup>4</sup>Clinical Neuropsychology Unit, Arcispedale S. Maria Nuova di Reggio Emilia, 42123 Reggio Emilia, Italy

<sup>5</sup>Neurology Unit, Azienda Ospedaliero-Universitaria di Modena, 41125 Modena, Italy

\*Correspondence: [chiara.carbone@unimore.it](mailto:chiara.carbone@unimore.it) (Chiara Carbone)

Academic Editor: Gernot Riedel

Submitted: 26 June 2023 Revised: 8 September 2023 Accepted: 26 September 2023 Published: 30 October 2023

## Abstract

**Background:** Mild Cognitive Impairment (MCI) is a heterogeneous condition characterised by cognitive changes that do not affect everyday functioning and may represent a pre-dementia phase. Research on the neuroanatomical correlates of cognitive tests used to diagnose MCI is heterogeneous and has mainly focused on elderly populations of patients with MCI, usually well above the age of 65. However, the effect of ageing on brain structure is known to be substantial and to affect brain-behaviour associations in older people. We explored the brain correlates of different cognitive tests in a group of young-onset MCI (i.e., with symptoms onset before the age of 65) to minimise the effect of ageing on brain-behaviour associations. **Methods:** Patients with a clinical diagnosis of young-onset MCI underwent extensive cognitive assessment and multimodal Magnetic Resonance Imaging (MRI) including high-resolution T1-weighted and Diffusion Tensor Imaging (DTI) sequences. Their scores on cognitive tests were related to measures of grey matter (GM) density and white matter (WM) integrity using, respectively, Voxel Based Morphometry (VBM) and Tract-Based Spatial Statistics (TBSS). **Results:** 104 young-onset MCI were recruited. VBM and TBSS whole-brain correlational analyses showed that between-subject variability in cognitive performance was significantly associated with regional variability in GM density and WM integrity. While associations between cognitive scores and focal GM density in our young-onset MCI group reflected the well-known lateralization of verbal and visuo-spatial abilities on the left and right hemispheres respectively, the associations between cognitive scores and WM microstructural integrity were widespread and diffusely involved most of the WM tracts in both hemispheres. **Conclusions:** We investigated the structural neuroanatomical correlates of cognitive tests in young-onset MCI in order to minimise the effect of ageing on brain-behaviour associations.

**Keywords:** neuroanatomical correlates; young-onset MCI; mild cognitive impairment; MRI; DTI; VBM; TBSS; cognitive tests; brain-behaviour associations; behavioural neurology

## 1. Introduction

Mild Cognitive Impairment (MCI), characterised by cognitive changes that do not affect everyday functioning, can be a transitional stage in the continuum from normal ageing to dementia, and it is frequently considered a pre-dementia phase of Alzheimer's Dementia (AD) [1]. People with MCI can have impairment in one or more cognitive domains [2]: they may have memory impairment (amnesic MCI – aMCI) in association or not with deficits in other cognitive domains (aMCI single or multi-domain), or they may have difficulties in one or more cognitive domains other than memory (non-amnesic MCI – nMCI single or multi-domain).

An extended cognitive assessment based on standardized tests is necessary to properly diagnose MCI, and it must explore all cognitive domains: language, verbal and visuo-

spatial short- and long-term memory, attentional-executive functions, visuo-constructional, and visuo-spatial abilities. A deficit in one or more of these domains, along with preserved independence in daily life, allows the clinician to diagnose MCI in patients who have a cognitive complaint (self-reported or noticed by others) [3]. Despite the fact that the neuropsychological evaluation is an objective, performance-based method to assess cognition, there is great variability both in literature and in clinical practice in defining MCI: some clinicians and researchers use a cut-off of 1.5/2 standard deviations (SD) below the age and education corrected normative data to identify MCI patients, while others employ a less stringent cut-off of 1.0 SD [4]. The clinical and cognitive characterization of MCI needs to be integrated with neuroimaging biomarkers to establish the underlying pathology and track disease progression over time.



Neuroimaging methods such as volumetric Magnetic Resonance Imaging (MRI) and Diffusion Tensor Imaging (DTI) have been widely used to investigate how performance in cognitive tests relates to brain structure, i.e., to study brain-behaviour associations. MRI volumetry allows to quantify brain volume, while DTI is used to estimate the structural integrity of brain connections by measuring diffusion of water molecules through tissues. This latter technique provides measures such as fractional anisotropy (FA), an index of microstructural integrity of cerebral white matter (WM), mean diffusivity (MD), related to the amount of water in the extracellular space, and radial diffusivity (RD), which indicates axonal damage [5].

Over the past years, several studies have attempted to explore the brain correlates of cognitive tests specifically in patients with MCI. In MCI population, global cognition, most frequently assessed with the Mini-Mental State Examination (MMSE) [6], has been positively associated with the grey matter (GM) density of the right inferior temporal gyrus and medial temporal structures (i.e., hippocampus) [7,8]. Performance in tests assessing language such as verbal fluency tasks positively correlated with the GM density of structures such as the right middle frontal gyrus and left putamen [7,9]. Neuroanatomical correlates of verbal long-term memory highlighted the role of medial temporal structures (hippocampus, parahippocampal gyrus, and entorhinal and perirhinal cortices) [8,10–12], as well as the role of the WM integrity of the medial temporal lobe, fornix, and uncinate fasciculus [13–15]. Performance in tests assessing visuo-spatial long-term memory positively correlated with GM density of the right hippocampus [11] and with WM integrity of the fornix (measured by reduced RD) [15]. Attentional-executive functions correlated with GM density and WM microstructural integrity of frontal (i.e., superior frontal gyrus, middle frontal gyrus, and lateral and medial orbital gyri) and parietal (i.e., anterior cingulum) areas [16].

Most of these previous studies have focused on late-onset MCI (i.e., on patients with symptoms onset after the age of 65). However, it is well known that the effect of ageing on brain anatomy is substantial and may challenge the identification of the neuroanatomical correlates of cognitive tests in older people. The aim of this study was to explore the neuroanatomical correlates of cognitive tests in a group of young-onset MCI, i.e., patients whose cognitive complaints commenced before the age of 65. We studied the neuroanatomical correlates of cognitive tests frequently used for the neuropsychological assessment of patients with MCI exploring the following cognitive domains: language, visuo-constructional ability, memory, relational reasoning, and attentional-executive functions.

## 2. Materials and Methods

### 2.1 Subjects

Adults with less than 70 years and a clinical diagnosis of MCI [2] whose cognitive complaints had com-

menced or had been noticed before the age of 65 (by the patients and/or by a relative/carer), consecutively seen in the cognitive neurology clinics of two hospitals in Emilia-Romagna, Northern Italy (Ospedale Civile di Baggiovara, Modena, Italy and Ospedale Santa Maria Nuova, Reggio Emilia, Italy), were included. After signing the informed consent, they underwent extended cognitive assessment and a multimodal MRI scan, and subsequently underwent clinical and MRI follow-up at 18-months. For the present study, only the baseline clinical and MRI data were considered. The study was approved by the Local Ethics committee (832/2018/SPER/AOUMO).

### 2.2 Cognitive Assessment

The cognitive battery included the following tests:

- Mini-Mental-State-Examination [6] as a measure of global functioning;
- Boston Naming Test (an 85-confrontation naming task with black and white figures [17]) and alternate fluency (which evaluates the production of letter-cued words, semantic-cued words, and the alternation of letter-cued words with semantic-cued words [18]) for language;
- Copy of Rey-Osterrieth Complex Figure (that consists in the copy of a complex geometric line drawing [19]) for visuo-constructional abilities;
- Judgment of Line Orientation Test (which evaluates the ability to find the orientation of lines in space [20]) and Clock Drawing Test (which requires the drawing of the clock numbers and the hands at ten past eleven [21]) for visuo-spatial abilities;
- Forward Digit and Corsi span for verbal and visuo-spatial short-term memory and their backward forms for verbal and visuo-spatial working memory (which implies that patients reproduce sequences of items – numbers and block positions – of increasing length in the presented and reverse order respectively [22]);
- Babcock Short Tale (that involves the ability to recall a short story 30 seconds after presentation and 20 minutes delayed [23]) and Free and Cued Selective Reminding Test (which evaluates the ability to recall 16 verbal items with and without semantic cues [24]) for verbal episodic memory;
- Delayed recall of Rey-Osterrieth Complex Figure (10-minutes delayed recall of the complex geometric line drawing [19]) and Corsi Supraspan (that is based on the Corsi span test and consists in a standard sequence of 8 blocks that the patients should learn, reproducing it correctly three consecutive times [25]) for visuo-spatial long-term memory;
- Raven’s Coloured Progressive Matrices (in which the patient is asked to select the missing element from 6 proposed below a matrix in order to complete its pattern [26]) for non-verbal relational reasoning;
- Stroop Test (that evaluates the ability to inhibit cognitive interference during the reading of words [27]), Trail Mak-

**Table 1. Descriptive statistics of demographic and behavioural data.**

	50th percentile (25th–75th percentile)	Min – Max
Age (years)	60 (56–65)	40 – 70
Education (years)	11 (8–13)	3 – 18
MMSE total score	28 (25–29)	16 – 30
BNT	73.5 (63.25–79)	10 – 85
Phonemic fluency	29 (18.75–35)	3 – 69
Semantic fluency	39 (32.75–45)	10 – 57
Alternate fluency	25 (15.75–34.5)	5 – 53
ROCF – copy	31 (26–33.5)	4 – 36
JLO	21 (16–24)	4 – 32
CDT	9 (6–10)	0 – 10
Digit span forward	5 (4–6)	3 – 7
Digit span backward	4 (3–4)	0 – 6
Corsi span forward	4 (4–5)	3 – 7
Corsi span backward	4 (3–5)	0 – 6
Babcock – IR	4.6 (3–5.5)	0 – 8
Babcock – DR	3.75 (1.1–5.2)	0 – 7.7
FCSRT – IFR	23 (16.5–28)	4 – 36
FCSRT – DFR	8 (5.75–11)	0 – 15
Corsi Supraspan	17.10 (8.64–22.98)	0 – 27.9
ROCF – DR	12.5 (7.25–16)	0 – 36
RCPM	26 (22–31)	8 – 36
Stroop – time	25.5 (18.75–35)	9.5 – 127
TMT – A	43.5 (33.75–63)	18 – 337
TMT – B	118 (81.5–181)	41 – 600
Cancellation Test	38.5 (30.75–45)	9 – 59
FAB	16 (14–18)	6 – 18
CET – A (errors)	8 (5–10.5)	0 – 19

MMSE, Mini-Mental State Examination; BNT, Boston Naming Test; CDT, Clock Drawing Test; CET, Cognitive Estimation Task; DFR, delayed free recall; DR, delayed recall; FAB, Frontal Assessment Battery; FCSRT, Free and Cued Selective Reminding Test; IFR, immediate free recall; IR, immediate recall; JLO, Judgment of Line Orientation; RCPM, Raven’s Coloured Progressive Matrices; ROCF, Rey-Osterrieth Complex Figure; TMT, Trail Making Test.

ing Test (in which the patient is asked to draw a line between 25 circles – only numbers, form A, or letters and numbers alternatively, form B [28]), Cancellation Test (which asks the patient to cancel digits from a list of numbers [29]), Frontal Assessment Battery (which comprises the evaluation of abstract reasoning, mental flexibility, motor programming, sensitivity to interference, inhibitory control, and environmental autonomy [30]) and Cognitive Estimation Task (a task that assesses patient’s ability to provide coherent answers to unanswered questions [31]) for attentional-executive functions.

### 2.3 Imaging Acquisition

A 3T GE Signa Architect scanner (software version: DV17.0\_R01\_1850.a) at Ospedale Civile di Baggiovara, Modena, Italy, equipped with a 48-channel-array head coil was used to acquire MRI sequences. The multimodal MRI protocol included, among others, high-resolution T1-weighted 3D BRAVO structural images (Repetition Time

(TR) 2.15 sec; Echo Time (TE) 3.1 msec; Field of View (FOV) 256 × 256 × 344 mm<sup>3</sup>; voxel dimension 1 mm isotropic) and DTI (TR 7 sec; TE 108.7 msec; slice thickness 2.5 mm; voxel dimension 2.5 mm isotropic; 64 diffusion directions; b 1000 sec/mm<sup>2</sup>) images.

#### 2.3.1 Preprocessing of Structural T1-Weighted Data

Structural T1-weighted data were analysed with FSL-Voxel Based Morphometry (VBM) [32], an optimized VBM protocol [33] carried out with FSL (FMRIB Software Library v6.0, <https://fsl.fmrib.ox.ac.uk/fsl>) tools [34]. Single-subject structural images were firstly brain-extracted (BET) and grey matter-segmented, and then registered to the Montreal Neurological Institute’s 152 (MNI 152) standard space using non-linear registration [35]. The resulting images were averaged and flipped along the x-axis to create a left-right symmetric, study-specific grey matter template. All native grey matter images were then non-linearly registered to this study-specific template and “mod-

**Table 2. Summary of imaging results.**

	VBM	TBSS
MMSE total score	↑ GM of bilateral posterior cortex and right putamen	↓ MD and RD of thalamic radiation, forceps minor and major, IFOF, SLF and UF, corpus callosum, and left cingulate
Phonemic fluency	↑ GM of left hippocampus, amygdala, striatum, lenticular nucleus, insula, and bilateral thalamus	↑ FA and ↓ MD and RD of bilateral cingulate, forceps minor and major, fornix, corpus callosum and anterior thalamic radiation, and left SLF, external capsule, and ILF
Semantic fluency	↑ GM of left thalamus, lenticular nucleus, and precentral gyrus	↑ FA of corpus callosum and forceps minor and major
Alternate fluency	↑ GM of bilateral hippocampus, amygdala, basal ganglia, and fronto-parietal regions	↑ FA and ↓ MD and RD of bilateral anterior thalamic radiation, corticospinal tract, forceps minor and major, IFOF, UF, and corpus callosum ↑ FA of left SLF, ILF, and cingulate, and right external capsule ↓ MD and RD of bilateral hippocampus, SLF, ILF, external capsule, and fornix ↓ RD of left cingulate
ROCF – copy	↑ GM of right angular gyrus and temporo-parietal-occipital junction	
Digit span backward	↑ GM of bilateral thalamus	↑ FA and ↓ MD and RD of bilateral external capsule, fornix, IFOF, SLF, ILF, UF, corticospinal tract, forceps minor and major, cingulate gyrus, anterior thalamic radiation, and corpus callosum
Corsi span backward		↑ FA and ↓ MD and RD of bilateral external capsule, fornix, IFOF, SLF, ILF, UF, corticospinal tract, forceps minor and major, cingulate, anterior thalamic radiation, and corpus callosum ↓ MD and RD of right hippocampus
FCSRT – IFR	↑ GM of left hippocampus	
Corsi Supraspan	↑ GM of bilateral medial temporal subcortical structures and lateral temporal cortices	↑ FA and ↓ MD and RD of bilateral fornix, IFOF, SLF, ILF, UF, forceps minor and major, hippocampus, anterior thalamic radiation, and corpus callosum
RCPM	↑ GM of right dorso-frontal and temporo-occipital cortex	↑ FA and ↓ MD and RD of bilateral fornix, forceps minor and major, external capsule, IFOF, ILF, anterior thalamic radiation, and corpus callosum ↓ MD and RD of right corticospinal tract and UF ↑ FA and ↓ MD of right SLF ↓ RD of right cingulate gyrus
Stroop – time		↓ FA and ↑ MD and RD of cingulate gyrus, IFOF, UF, external capsule, fornix, forceps minor and major, anterior thalamic radiation, corpus callosum, and hippocampus
TMT – B	↓ GM of bilateral occipito-temporo-parietal areas and subcortical structures	↑ MD and RD of corpus callosum, left SLF, and cingulate gyrus
Cancellation Test	↑ GM of bilateral thalamus	
FAB	↑ GM of bilateral fronto-temporo-parietal regions and subcortical structures	

↑, positive correlation; ↓, negative correlation; MMSE, Mini-Mental State Examination; FA, fractional anisotropy; FAB, Frontal Assessment Battery; FCSRT, Free and Cued Selective Reminding Test; GM, grey matter; IFOF, inferior fronto-occipital fasciculus; IFR, immediate free recall; ILF, inferior longitudinal fasciculus; MD, mean diffusivity; RCPM, Raven's Coloured Progressive Matrices; RD, radial diffusivity; ROCF, Rey-Osterrieth Complex Figure; SLF, superior longitudinal fasciculus; TBSS, Tract-Based Spatial Statistics; TMT, Trail Making Test; UF, uncinate fasciculus; VBM, Voxel-Based Morphometry.

**Table 3. Correlation coefficients between grey matter density/white matter microstructural integrity and cognitive tests.**

	Grey matter				Fractional anisotropy				Mean diffusivity				Radial diffusivity			
	x	y	z	<i>t</i> Statistic (corresponding <i>r</i> values)	x	y	z	<i>t</i> Statistic (corresponding <i>r</i> values)	x	y	z	<i>t</i> Statistic (corresponding <i>r</i> values)	x	y	z	<i>t</i> Statistic (corresponding <i>r</i> values)
MMSE total score	-30	-50	48	4.24 (0.39)					31	22	29	4.22 (0.39)	42	30	11	2.79 (0.27)
Phonemic fluency	-14	14	2	4.49 (0.41)	-20	38	9	3.95 (0.36)	-19	39	8	3.3 (0.31)	-20	40	7	3.20 (0.3)
Semantic fluency	-22	-22	14	4.67 (0.42)	-17	15	30	3.27 (0.31)								
Alternate fluency	-22	-22	14	5.27 (0.46)	-20	38	9	3.47 (0.32)	18	28	-13	2.16 (0.21)	20	35	-7	4.22 (0.39)
ROCF – copy	54	-64	-2	4.25 (0.39)												
Digit span backward	2	-22	6	5.16 (0.45)	-16	31	-14	1.89 (0.18)	31	45	-5	2.02 (0.2)	-10	30	-14	2.25 (0.22)
Corsi span backward					26	33	7	3.33 (0.31)								
FCSRT – IFR	-22	-38	-2	5.90 (0.5)												
Corsi Supraspan	64	-34	-26	3.23 (0.3)	31	32	9	4.59 (0.41)	26	17	-10	2.73 (0.26)	21	51	-9	2.38 (0.23)
RCPM	46	30	20	4.46 (0.4)	-4	21	16	2.72 (0.26)	17	-46	19	3.6 (0.34)	6	24	13	2.63 (0.25)
Stroop – time					-18	36	10	3.33 (0.31)	26	27	5	3.17 (0.3)	19	32	29	4.34 (0.39)
TMT – B	-66	-48	12	4.27 (0.39)					-16	-37	28	4.94 (0.44)	-15	-41	40	4.1 (0.38)
Cancellation Test	12	-20	4	4.62 (0.42)												
FAB	12	-20	2	4.75 (0.43)												

Location in MNI coordinates and maximum *t* Statistic value; MMSE, Mini-Mental State Examination; MNI, Montreal Neurological Institute; FAB, Frontal Assessment Battery; FCSRT, Free and Cued Selective Reminding; RCPM, Raven’s Coloured Progressive Matrices; ROCF, Rey-Osterrieth Complex Figure; TMT, Trail Making Test.

ulated” to correct for local expansion (or contraction) due to the non-linear component of the spatial transformation. These modulated grey matter images were finally smoothed with an isotropic Gaussian kernel with a sigma of 3 mm.

### 2.3.2 Preprocessing of DTI Data

DTI images were initially pre-processed with BET. Subsequently, the EDDY FSL algorithms allowed to correct for eddy currents and patient motion. Then, the FSL DTIFIT tool (<https://fsl.fmrib.ox.ac.uk/fsl>) was used for DTI parameters computation, i.e., FA, MD, and RD. Finally, DTI maps from different subjects were registered to  $1 \times 1 \times 1$  mm FMRIB58\_FA standard space, using Tract-Based Spatial Statistics (TBSS) [36]. The spatial analyses were conducted only on FA skeleton, obtained with a threshold of 0.2 on the map of mean FA across subjects.

### 2.4 Statistical Analysis

Descriptive statistics of demographic and cognitive variables were performed using Stata version 15 (Stata Statistical Software: Release 15. StataCorp LLC, College Station, TX, USA) and reported as median score (50th percentile) because all variables except five were skewed.

Pre-processed imaging data were analysed with whole-brain correlational analyses (i.e., VBM and TBSS). Correlations between cognitive scores and GM and whole brain FA, MD, and RD were analysed voxelwise, to identify voxels whose GM density or WM microstructural integrity had a significant correlation with performance. Values obtained from pre-processed images were used in regression analyses (General Linear Models – GLM) using *randomise* [37], a permutation-based non-parametric testing (5000 permutations), and including MMSE total score, sex, years of education, and age as covariates of no interest. This allowed us to test for the presence of significant correlations between cognitive scores and imaging parameters over and above the effect of global cognitive impairment, sex, and education, as well as the effect of age variability even within the young-onset sample. Threshold-Free Cluster Enhancement (TFCE) method with Family-wise error (FWE) rate for correction for multiple comparison was used for the analyses, and the statistical threshold was set at  $p < 0.05$ . For each neuropsychological test, we also added a multiple comparison correction considering the two imaging modalities (VBM and TBSS), setting the statistical threshold at  $p < 0.025$ . Harvard-Oxford cortical and sub-cortical structural atlases [38–41] for grey matter and Johns Hopkins University (JHU) white matter tractography atlas [42] for white matter were used as reference for localizing results.

## 3. Results

One hundred and four consecutive eligible subjects (43 male and 61 female) were recruited between 2019 and 2020; Table 1 provides the descriptive statistics of their demographic and cognitive data.

The imaging results showing the structural neuroanatomical correlates of cognitive tests are summarized in Table 2 and displayed in Fig. 1 and **Supplementary Fig. 1**. Table 3 shows the corresponding *t* Statistic values and correlation coefficients related to the voxels in which the *p* value was maximum, along with their coordinates in MNI space. For all the explored tests, the correlations survived multiple comparison correction considering that we had explored two different imaging modalities (VBM and TBSS), except for the one between GM and WM and semantic fluency.

### 3.1 Global Cognitive Status

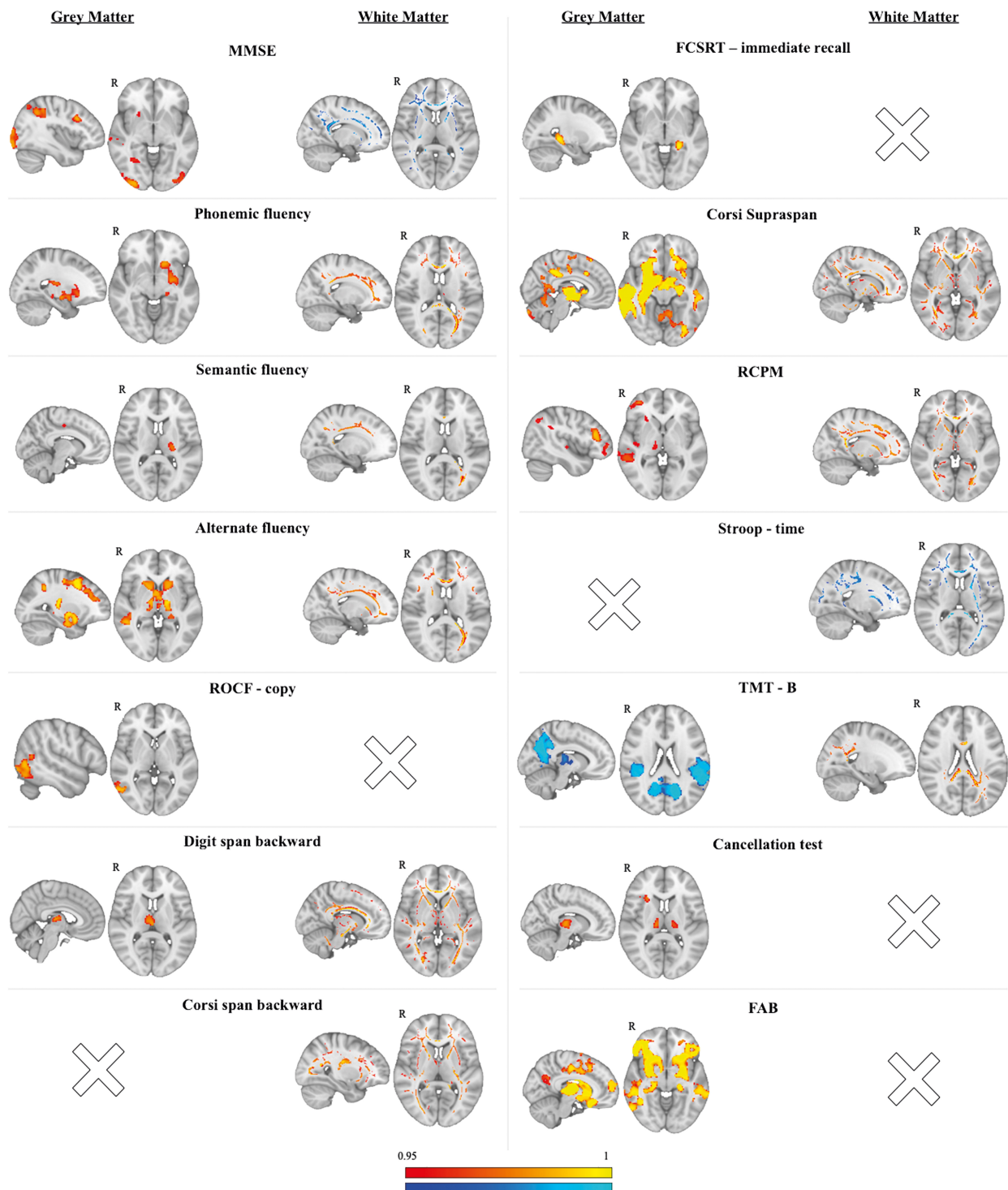
Global cognitive status scores measured with MMSE, assessing multiple cognitive domains such as orientation, verbal memory, visuo-construction ability, language, and attention, positively correlated with GM density in the posterior cortex bilaterally and in the right putamen.

It also correlated with measures of WM integrity, namely decreased MD and RD, in several white matter tracts such as the anterior thalamic radiation, forceps minor and major, inferior fronto-occipital fasciculus (IFOF), superior longitudinal fasciculus (SLF), inferior longitudinal fasciculus (ILF), uncinate fasciculus (UF), body and splenium of the corpus callosum, and the left cingulate gyrus.

### 3.2 Language

Performance in verbal fluency positively correlated with GM density of different subcortical structures: more precisely, the lower the score in phonemic fluency, the lower the GM density of left hippocampus and amygdala, striatum (accumbens and caudate), lenticular nucleus (putamen and pallidum), insula, and bilateral thalamus. The lower the score in semantic fluency, the lower the GM density in the left thalamus, lenticular nucleus, and precentral gyrus. The lower the score in alternate fluency, the lower the GM density in bilateral hippocampus and amygdala, basal ganglia, and fronto-parietal regions.

Performance in verbal fluency also related to measures of WM integrity: the lower the score in phonemic fluency, the lower the FA and the higher the MD and RD in the corpus callosum, anterior tracts such as cingulate gyrus, forceps minor and major, fornix, anterior thalamic radiation bilaterally, and posterior tract such as the SLF, external capsule, and ILF in the left hemisphere. The higher the score in semantic fluency, the higher the FA in the corpus callosum and forceps minor and major. Finally, impairment in alternate fluency was associated with lower FA and higher MD and RD in bilateral anterior thalamic radiation, corticospinal tract, forceps minor and major, IFOF, UF, and body and splenium of corpus callosum; it was also correlated to lower FA in the left SLF and ILF and in the right external capsule, to lower FA and higher RD in the left cingulate gyrus, and to higher MD and RD in bilateral hippocampus, SLF, ILF, external capsule, and fornix.



**Fig. 1. Correlations between imaging parameters and cognitive tests.** On the left side of each column are displayed significant correlations between cognitive tests and grey matter density (in red-yellow positive correlations, in blue-light blue negative correlations). On the right side of each column are displayed significant correlations between cognitive tests and parameters of white matter integrity (in red-yellow positive correlations with fractional anisotropy and in blue-light blue negative correlations with mean diffusivity, except for the Stroop test, where blue-light blue represents negative correlations with fractional anisotropy, and the TMT-B, where red-yellow represent positive correlations with mean diffusivity). Results are displayed at  $p < 0.05$ , FWE corrected for multiple comparisons using TFCE. MMSE, Mini-Mental State Examination; FAB, Frontal Assessment Battery; FCSRT, Free and Cued Selective Reminding Test; FWE, Family-wise error; RCPM, Raven's Coloured Progressive Matrices; ROCF, Rey-Osterrieth Complex Figure; TMT, Trail Making Test.

### 3.3 Visuo-Constructional Ability

As for visuo-constructional ability, the poorer the performance in the Rey-Osterrieth Complex Figure (ROCF) – copy, the lower the GM density in an area involving the right angular gyrus and the right temporo-parietal-occipital junction.

### 3.4 Working-Memory

Performance in tests of working-memory (i.e., Digit span backward and Corsi span backward) was related more to WM microstructural integrity than to GM density, except for a positive correlation between performance at Digit span backward and GM density in the thalamus bilaterally. Both verbal and visuo-spatial working-memory impairment was related to lower FA and higher MD and RD in several white matter tracts: bilateral external capsule, fornix, IFOF, SLF, ILF, UF, corticospinal tract, forceps minor and major, cingulate gyrus, anterior thalamic radiation, and body and splenium of corpus callosum. Performance in the Corsi span backward was also related to lower MD and RD in the right hippocampus.

### 3.5 Long-Term Memory

Regarding verbal long-term memory, the lower the performance in immediate recall of Free and Cued Selective Reminding Test (FCSRT), the lower the volume of the left hippocampus.

The neuroanatomical correlates of visuo-spatial long-term memory (i.e., Corsi Supraspan) extensively involved both GM density and WM microstructural integrity, with prevalence in the right hemisphere. More precisely, the lower the performance in visuo-spatial long-term memory, the lower the GM density of medial temporal subcortical structures (i.e., hippocampus, amygdala, accumbens) and lateral temporal cortices, bilaterally but more extensively in the right side. There was also a positive correlation between Corsi Supraspan impairment and WM integrity (lower FA and higher MD and RD) in bilateral fornix, IFOF, SLF, ILF, UF, forceps minor and major, hippocampus, anterior thalamic radiation, and body and splenium of the corpus callosum.

### 3.6 Non-Verbal Reasoning

Performance in non-verbal reasoning (i.e., Raven's Coloured Progressive Matrices (RCPM)) was related to GM density and WM integrity prevalently in the right hemisphere. The lower the performance in this test, the lower the GM density of two areas in the right dorso-frontal and right temporo-occipital cortex, and the lower the WM integrity in the right IFOF, ILF, forceps minor and major, fornix, anterior thalamic radiation, SLF, UF, hippocampus and corticospinal tract.

### 3.7 Attentional-Executive Functions

Among the tests for attentional-executive functions, Stroop test had WM correlates only, Trail Making Test (TMT)-B had both widespread GM and WM correlates, and Frontal Assessment Battery (FAB) GM correlates only. More precisely, the higher the time to complete the Stroop test (i.e., the worse the performance), the lower the WM integrity of the cingulate gyrus, IFOF, UF, external capsule, fornix, forceps minor and major, anterior thalamic radiation, body, and splenium of corpus callosum, and hippocampus. The higher the time to complete part B of TMT, the lower the GM density of posterior regions (i.e., occipito-temporo-parietal areas) and subcortical structures (amygdala, striatum, and thalamus) bilaterally, as well as the lower the WM integrity of body and splenium of corpus callosum, left SLF, and cingulate gyrus. The lower the score in the FAB, the lower the GM density in bilateral fronto-temporo-parietal regions and subcortical structures.

## 4. Discussion

We investigated the structural neuroanatomical correlates of cognitive tests in a group of young-onset MCI (i.e., onset of cognitive complaints before the age of 65) patients, to minimise the effect of ageing on the study of brain-behaviour associations.

The identified associations between cognitive scores and focal grey matter atrophy were in line with the lateralization of verbal and visuo-spatial abilities [43]. In fact, the grey matter correlates of tests such as verbal fluency (i.e., phonemic, semantic, and alternate fluency) and verbal long-term memory (i.e., FCSRT) were mostly located in structures of the left hemisphere, whereas the correlates of tests of visuo-constructional ability (i.e., ROCF – copy), visuo-spatial long-term memory (i.e., Corsi Supraspan), and non-verbal relational reasoning (i.e., RCPM) were more lateralized in the right hemisphere.

The neuroanatomical correlates of the MMSE were sparse in the brain's grey matter, highlighting the fact that this is a test meant to examine more than one cognitive domain. Interestingly, in our sample the variability in the MMSE mostly related to the atrophy of occipital and temporal areas, which had been shown before, albeit not exclusively [7]. The lack of correlates in frontal areas confirms that the MMSE has low sensibility in revealing frontal dysfunction [44], and this is especially evident in our group in which we controlled for the effect of aging by focusing on young-onset sample and including age among the covariates of no interest [45].

Grey matter neuroanatomical correlates of language ability tests especially involved subcortical structures, in line with previous literature [9], confirming the role of basal ganglia in language tasks [46].

Performance in the FCSRT, which measures verbal long-term memory ability, focally correlated with the integrity of the posterior part of the left hippocampus, in line



with previous studies exploring the correlates of other auditory verbal learning tests in older MCI subjects [8,10], as well as in healthy subjects [47]. The fact that in our young-onset MCI group the correlation between the immediate recall of the FCSRT and the grey matter density precisely delineated the posterior part of the left hippocampus is remarkable and novel. It confirms the role of the posterior part of hippocampus in the registration process [48,49], and provides further evidence for dissociable memory networks along the anterior–posterior axis of the hippocampus [50]. Notably, there were no white matter correlates of the FCSRT.

Another test that had focal grey matter correlates only was the ROCF, whose variability was significantly associated with grey matter density of the right temporo-parietal junction/angular gyrus, in line with the known involvement of this structure in visuo-spatial abilities.

In contrast to a previous study [11] which found few neuroanatomical structural correlates of visuo-spatial long-term memory limited to the right hippocampus, our study highlighted the involvement of several cortical and subcortical structures in addition to the right hippocampus in this cognitive domain, still mainly localized in the right hemisphere. This suggests that the test we used (i.e., Corsi Supraspan) is complex and involves processes related to movement monitoring and visual perception, and not only long-term memory abilities.

Finally, the associations that we found between grey matter density and attentional-executive functions confirmed a prominent role of fronto-temporo-parietal areas [16]. Of notice, the correlates of the TMT-B also emphasised the involvement of occipital regions given that this is a visual attention task. The correlates of the FAB, which tests verbal abstraction abilities, Luria sequence learning, Go/No-Go, and other non-visual tasks, were mainly located in bilateral dorso-lateral and peri-insular prefrontal cortex.

In our sample, the white matter neuroanatomical correlates were widespread rather than focal and involved both the hemispheres: for almost all cognitive domains, we found a relationship between the performance and several white matter tract fibers, including the superior longitudinal fasciculus, inferior longitudinal fasciculus, uncinate fasciculus, inferior fronto-occipital fasciculus, forceps minor and major, cingulum, corpus callosum, and anterior thalamic radiation. Interestingly, there were differences in the neuroanatomical correlates of selective and divided attention: selective attention investigated with the Cancellation Test was more related to grey matter atrophy, while divided attention examined by TMT-B was also related to white matter integrity. Working-memory too, both verbal and visuo-spatial, was more related to white matter integrity than to grey matter density, whereas visuo-constructional ability and verbal long-term memory were related to grey matter atrophy only.

The major limitation of this work is that we did not have a group of healthy controls, nor did we have a group of elderly MCIs to compare neuroanatomical correlates of our young-onset group. A further possible limitation of the study is that some of the included MCI subjects were older than 65 at the moment of recruitment, but the fact that they had developed symptoms before the age of 65 allowed us to still consider them as subjects with young-onset MCI. Despite of these limitations, this is the first study focused on young-onset MCI which investigates the neuroanatomical correlates of the different cognitive tests included in an extended neuropsychological battery simultaneously and could provide new information about such an early stage of cognitive impairment.

## 5. Conclusions

In our young-onset MCI group, we found that the neuroanatomical correlates of tests of verbal and visuo-spatial abilities reflected the well-known lateralization in the left and right hemispheres, respectively. These linear correlates were cleaner and more focal compared to previous studies in older MCI group, possibly reflecting the influence of ageing on these correlations. This is especially true for the FCSRT testing verbal memory, which was selectively associated with atrophy of the posterior left hippocampus, and for the copy of ROCF, testing visuo-constructional ability, which was selectively associated with atrophy of the right temporo-parietal junction. Most of the other tests were also linearly correlated with the variability of white matter microstructural integrity, and such associations involved several white matter tracts in both hemispheres. These correlations were more widespread and less focal than in previous studies conducted in older MCI subjects, suggesting that white matter integrity may have a role in the development of MCI especially in its young onset.

We showed that most of the cognitive tests (except the FCSRT and ROCF) involve several underlying processes that rely on the functioning of grey matter areas as well as on the integrity of several white matter tracts. This furthers a view of brain functioning based on networks and connections rather than on the functioning of focal cortical areas in isolation [5].

## Availability of Data and Materials

The data sets generated and/or analyzed during the current study are not publicly available due to regulatory requirements but are available from the corresponding author on reasonable request.

## Author Contributions

CC, FG, MAM, AM, AC and GZ designed the research study. CC, DB, GV, CG, DS, SS and MT performed the research. EB provided help with FSL software. CC and EB analyzed the data. CC, AC and GZ wrote the

manuscript. All authors contributed to editorial changes in the manuscript. All authors read and approved the final manuscript. All authors have participated sufficiently in the work and agreed to be accountable for all aspects of the work.

## Ethics Approval and Consent to Participate

The study was approved by the Local Ethics committee (832/2018/SPER/AOUMO) and all patients signed the informant consent.

## Acknowledgment

We are grateful to our patients and their families.

## Funding

The study was supported by the grant Dipartimenti di Eccellenza 2018-2022, MIUR, Italy, to the Department of Biomedical, Metabolic and Neural Sciences, University of Modena. The study was also funded by the European Union ERC, UnaWireD, project number 101042625. However, views and opinions expressed are those of the author(s) only and do not necessarily reflect those of the European Union or the European Research Council Executive Agency. Neither the European Union nor the granting authority can be held responsible for them.

## Conflict of Interest

The authors declare no conflict of interest. Giovanna Zamboni is the member of Editorial Board of this journal. Also, Giovanna Zamboni is serving as one of the Guest editors of this journal. We declare that Giovanna Zamboni had no involvement in the peer review of this article and has no access to information regarding its peer review. Full responsibility for the editorial process for this article was delegated to Gernot Riedel.

## Supplementary Material

Supplementary material associated with this article can be found, in the online version, at <https://doi.org/10.31083/j.jin2206152>.

## References

- [1] Ward A, Tardiff S, Dye C, Arrighi HM. Rate of conversion from prodromal Alzheimer's disease to Alzheimer's dementia: a systematic review of the literature. *Dementia and Geriatric Cognitive Disorders Extra*. 2013; 3: 320–332.
- [2] Petersen RC, Caracciolo B, Brayne C, Gauthier S, Jelic V, Fratiglioni L. Mild cognitive impairment: a concept in evolution. *Journal of Internal Medicine*. 2014; 275: 214–228.
- [3] Petersen RC. Mild cognitive impairment as a diagnostic entity. *Journal of Internal Medicine*. 2004; 256: 183–194.
- [4] Anderson ND. State of the science on mild cognitive impairment (MCI). *CNS Spectrums*. 2019; 24: 78–87.
- [5] Zamboni G. Functional specialization and network connectivity in brain function. In Husain M., Schott J. M. (ed.) *Oxford Textbook of Cognitive Neurology and Dementia* (pp. 32–41). 5th edn. Oxford University Press: Oxford. 2016.
- [6] Measso G, Cavazzeran F, Zappalà G, Lebowitz BD, Crook TH, Pirozzolo FJ, *et al.* The mini-mental state examination: Normative study of an Italian random sample. *Developmental Neuropsychology* 1993; 9: 77–85.
- [7] Cheng CPW, Cheng ST, Tam CWC, Chan WC, Chu WCW, Lam LCW. Relationship between Cortical Thickness and Neuropsychological Performance in Normal Older Adults and Those with Mild Cognitive Impairment. *Aging and Disease*. 2018; 9: 1020–1030.
- [8] Peng GP, Feng Z, He FP, Chen ZQ, Liu XY, Liu P, *et al.* Correlation of hippocampal volume and cognitive performances in patients with either mild cognitive impairment or Alzheimer's disease. *CNS Neuroscience & Therapeutics*. 2015; 21: 15–22.
- [9] Valdés Hernández MC, Clark R, Wang SH, Guazzo F, Calia C, Pattan V, *et al.* The striatum, the hippocampus, and short-term memory binding: Volumetric analysis of the subcortical grey matter's role in mild cognitive impairment. *NeuroImage. Clinical*. 2020; 25: 102158.
- [10] Fjell AM, Walhovd KB, Amlien I, Bjørnerud A, Reinvang I, Gjerstad L, *et al.* Morphometric changes in the episodic memory network and tau pathologic features correlate with memory performance in patients with mild cognitive impairment. *AJNR. American Journal of Neuroradiology*. 2008; 29: 1183–1189.
- [11] Philippi N, Noblet V, Duron E, Cretin B, Bouilly C, Wisniewski I, *et al.* Exploring anterograde memory: a volumetric MRI study in patients with mild cognitive impairment. *Alzheimer's Research & Therapy*. 2016; 8: 26.
- [12] Troyer AK, Murphy KJ, Anderson ND, Craik FIM, Moscovitch M, Maione A, *et al.* Associative recognition in mild cognitive impairment: relationship to hippocampal volume and apolipoprotein E. *Neuropsychologia*. 2012; 50: 3721–3728.
- [13] Goldstein FC, Mao H, Wang L, Ni C, Lah JJ, Levey AI. White Matter Integrity and Episodic Memory Performance in Mild Cognitive Impairment: A Diffusion Tensor Imaging Study. *Brain Imaging and Behavior*. 2009; 3: 132–141.
- [14] Rémy F, Vayssière N, Saint-Aubert L, Barbeau E, Pariente J. White matter disruption at the prodromal stage of Alzheimer's disease: relationships with hippocampal atrophy and episodic memory performance. *NeuroImage. Clinical*. 2015; 7: 482–492.
- [15] Zhuang L, Wen W, Trollor JN, Kochan NA, Reppermund S, Brodaty H, *et al.* Abnormalities of the fornix in mild cognitive impairment are related to episodic memory loss. *Journal of Alzheimer's Disease: JAD*. 2012; 29: 629–639.
- [16] Grambaite R, Selnes P, Reinvang I, Aarsland D, Hessen E, Gjerstad L, *et al.* Executive dysfunction in mild cognitive impairment is associated with changes in frontal and cingulate white matter tracts. *Journal of Alzheimer's Disease: JAD*. 2011; 27: 453–462.
- [17] D'Agostino L. Taratura su soggetti normali di prove di denominazione per l'afasia. Istituto di Clinica Neurologica, Università. 1985.
- [18] Costa A, Bagoj E, Monaco M, Zabberoni S, De Rosa S, Papan Antonio AM, *et al.* Standardization and normative data obtained in the Italian population for a new verbal fluency instrument, the phonemic/semantic alternate fluency test. *Neurological Sciences: Official Journal of the Italian Neurological Society and of the Italian Society of Clinical Neurophysiology*. 2014; 35: 365–372.
- [19] Caffarra P, Vezzadini G, Dieci F, Zonato F, Venneri A. Rey-Osterrieth complex figure: normative values in an Italian population sample. *Neurological Sciences: Official Journal of the Italian Neurological Society and of the Italian Society of Clinical Neurophysiology*. 2002; 22: 443–447.
- [20] Benton AL, Varney NR, Hamsher K de S, Ferracuti F, Ferracuti S. Test di giudizio di orientamento di linee: manuale. *Organizzazioni Speciali: Firenze*. 1992.

- [21] Mondini S, Mapelli D, Vestri A, Arcara G, Bisiacchi P. ENB esame neuropsicologico breve. Raffaello Cortina Editore: Milano. 2003.
- [22] Monaco M, Costa A, Caltagirone C, Carlesimo GA. Forward and backward span for verbal and visuo-spatial data: standardization and normative data from an Italian adult population. *Neurological Sciences: Official Journal of the Italian Neurological Society and of the Italian Society of Clinical Neurophysiology*. 2013; 34: 749–754.
- [23] Carlesimo G, Buccione I, Fadda L, Graceffa A, Mauri M, Lorusso S, *et al.* Normative data of two memory tasks: Short-Story recall and Rey’s Figure. *Nuova Rivista di Neurologia*. 2002; 12: 1–13.
- [24] Girtler N, De Carli F, Amore M, Arnaldi D, Bosia LE, Bruzzaniti C, *et al.* A normative study of the Italian printed word version of the free and cued selective reminding test. *Neurological Sciences: Official Journal of the Italian Neurological Society and of the Italian Society of Clinical Neurophysiology*. 2015; 36: 1127–1134.
- [25] Capitani E, Laiacona M, Ciceri E. Sex differences in spatial memory: a reanalysis of block tapping long-term memory according to the short-term memory level. *Italian Journal of Neurological Sciences*. 1991; 12: 461–466.
- [26] Carlesimo GA, Caltagirone C, Gainotti G. The Mental Deterioration Battery: normative data, diagnostic reliability and qualitative analyses of cognitive impairment. The Group for the Standardization of the Mental Deterioration Battery. *European Neurology*. 1996; 36: 378–384.
- [27] Caffarra P, Vezzadini G, Dieci F, Zonato F, Venneri A. Una versione abbreviata del test di Stroop: Dati normativi nella popolazione Italiana. *Nuova Rivista di Neurologia*. 2002; 12: 111–115.
- [28] Giovagnoli AR, Del Pesce M, Mascheroni S, Simoncelli M, Laiacona M, Capitani E. Trail making test: normative values from 287 normal adult controls. *Italian Journal of Neurological Sciences*. 1996; 17: 305–309.
- [29] Della Sala S, Laiacona M, Spinnler H, Ubezio C. A cancellation test: its reliability in assessing attentional deficits in Alzheimer’s disease. *Psychological Medicine*. 1992; 22: 885–901.
- [30] Appollonio I, Leone M, Isella V, Piamarta F, Consoli T, Villa ML, *et al.* The Frontal Assessment Battery (FAB): normative values in an Italian population sample. *Neurological Sciences: Official Journal of the Italian Neurological Society and of the Italian Society of Clinical Neurophysiology*. 2005; 26: 108–116.
- [31] Scarpina F, D’Aniello GE, Mauro A, Castelnuovo G, MacPherson SE. How many segments are there in an orange: normative data for the new Cognitive Estimation Task in an Italian population. *Neurological Sciences: Official Journal of the Italian Neurological Society and of the Italian Society of Clinical Neurophysiology*. 2015; 36: 1889–1895.
- [32] Douaud G, Smith S, Jenkinson M, Behrens T, Johansen-Berg H, Vickers J, *et al.* Anatomically related grey and white matter abnormalities in adolescent-onset schizophrenia. *Brain: a Journal of Neurology*. 2007; 130: 2375–2386.
- [33] Good CD, Johnsrude IS, Ashburner J, Henson RN, Friston KJ, Frackowiak RS. A voxel-based morphometric study of ageing in 465 normal adult human brains. *NeuroImage*. 2001; 14: 21–36.
- [34] Smith SM, Jenkinson M, Woolrich MW, Beckmann CF, Behrens TEJ, Johansen-Berg H, *et al.* Advances in functional and structural MR image analysis and implementation as FSL. *NeuroImage*. 2004; 23: S208–S219.
- [35] Andersson JL, Jenkinson M, Smith S. Non-linear registration, aka Spatial normalisation FMRIB technical report TR07JA2. FMRIB Analysis Group of the University of Oxford. 2007; 2: e21.
- [36] Smith SM, Jenkinson M, Johansen-Berg H, Rueckert D, Nichols TE, Mackay CE, *et al.* Tract-based spatial statistics: voxelwise analysis of multi-subject diffusion data. *NeuroImage*. 2006; 31: 1487–1505.
- [37] Winkler AM, Ridgway GR, Webster MA, Smith SM, Nichols TE. Permutation inference for the general linear model. *NeuroImage*. 2014; 92: 381–397.
- [38] Makris N, Goldstein JM, Kennedy D, Hodge SM, Caviness VS, Faraone SV, *et al.* Decreased volume of left and total anterior insular lobule in schizophrenia. *Schizophrenia Research*. 2006; 83: 155–171.
- [39] Frazier JA, Chiu S, Breeze JL, Makris N, Lange N, Kennedy DN, *et al.* Structural brain magnetic resonance imaging of limbic and thalamic volumes in pediatric bipolar disorder. *The American Journal of Psychiatry*. 2005; 162: 1256–1265.
- [40] Desikan RS, Ségonne F, Fischl B, Quinn BT, Dickerson BC, Blacker D, *et al.* An automated labeling system for subdividing the human cerebral cortex on MRI scans into gyral based regions of interest. *NeuroImage*. 2006; 31: 968–980.
- [41] Goldstein JM, Seidman LJ, Makris N, Ahern T, O’Brien LM, Caviness VS Jr, *et al.* Hypothalamic abnormalities in schizophrenia: sex effects and genetic vulnerability. *Biological Psychiatry*. 2007; 61: 935–945.
- [42] Hua K, Zhang J, Wakana S, Jiang H, Li X, Reich DS, *et al.* Tract probability maps in stereotaxic spaces: analyses of white matter anatomy and tract-specific quantification. *NeuroImage*. 2008; 39: 336–347.
- [43] Hugdahl K. Lateralization of cognitive processes in the brain. *Acta Psychologica*. 2000; 105: 211–235.
- [44] Han M, Kim DY, Leigh JH, Kim MW. Value of the Frontal Assessment Battery Tool for Assessing the Frontal Lobe Function in Stroke Patients. *Annals of Rehabilitation Medicine*. 2020; 44: 261–272.
- [45] Zamboni G, Griffanti L, Jenkinson M, Mazzucco S, Li L, Küker W, *et al.* White Matter Imaging Correlates of Early Cognitive Impairment Detected by the Montreal Cognitive Assessment After Transient Ischemic Attack and Minor Stroke. *Stroke*. 2017; 48: 1539–1547.
- [46] Booth JR, Wood L, Lu D, Houk JC, Bitan T. The role of the basal ganglia and cerebellum in language processing. *Brain Research*. 2007; 1133: 136–144.
- [47] Ezzati A, Katz MJ, Zammit AR, Lipton ML, Zimmerman ME, Sliwinski MJ, *et al.* Differential association of left and right hippocampal volumes with verbal episodic and spatial memory in older adults. *Neuropsychologia*. 2016; 93: 380–385.
- [48] Ludwig E, Trautner P, Kurthen M, Schaller C, Bien CG, Elger CE, *et al.* Intracranially recorded memory-related potentials reveal higher posterior than anterior hippocampal involvement in verbal encoding and retrieval. *Journal of Cognitive Neuroscience*. 2008; 20: 841–851.
- [49] Epelbaum S, Bouteloup V, Mangin JF, La Corte V, Migliaccio R, Bertin H, *et al.* Neural correlates of episodic memory in the Memento cohort. *Alzheimer’s & Dementia (New York, N. Y.)*. 2018; 4: 224–233.
- [50] Voets NL, Zamboni G, Stokes MG, Carpenter K, Stacey R, Adcock JE. Aberrant functional connectivity in dissociable hippocampal networks is associated with deficits in memory. *The Journal of Neuroscience: the Official Journal of the Society for Neuroscience*. 2014; 34: 4920–4928.