

## Optimizing long-term joint health in the treatment of hemophilia

Roberta Gualtierotti, Andrea Giachi, Chiara Suffritti, Luca Bedogni, Francesco Franco, Francesco Poggi, Sergio Mascetti, Marco Colussi, Dragan Ahmetovic, Valentina Begnozzi, Elena Anna Boccalandro, Luigi Piero Solimeno & Flora Peyvandi

To cite this article: Roberta Gualtierotti, Andrea Giachi, Chiara Suffritti, Luca Bedogni, Francesco Franco, Francesco Poggi, Sergio Mascetti, Marco Colussi, Dragan Ahmetovic, Valentina Begnozzi, Elena Anna Boccalandro, Luigi Piero Solimeno & Flora Peyvandi (2024) Optimizing long-term joint health in the treatment of hemophilia, Expert Review of Hematology, 17:10, 713-721, DOI: [10.1080/17474086.2024.2396617](https://doi.org/10.1080/17474086.2024.2396617)

To link to this article: <https://doi.org/10.1080/17474086.2024.2396617>



© 2024 The Author(s). Published by Informa UK Limited, trading as Taylor & Francis Group.



Published online: 08 Sep 2024.



Submit your article to this journal [↗](#)



Article views: 399



View related articles [↗](#)



View Crossmark data [↗](#)

## Optimizing long-term joint health in the treatment of hemophilia

Roberta Gualtierotti<sup>a,b</sup>, Andrea Giachi<sup>b</sup>, Chiara Suffritti<sup>a</sup>, Luca Bedogni<sup>c</sup>, Francesco Franco<sup>c</sup>, Francesco Poggi<sup>d</sup>, Sergio Mascetti<sup>e</sup>, Marco Colussi<sup>e</sup>, Dragan Ahmetovic<sup>e</sup>, Valentina Begnozzi<sup>a</sup>, Elena Anna Boccalandro<sup>a</sup>, Luigi Piero Solimeno<sup>f</sup> and Flora Peyvandi<sup>a,b</sup>

<sup>a</sup>Fondazione IRCCS Ca' Granda Ospedale Maggiore Policlinico, Angelo Bianchi Bonomi Hemophilia and Thrombosis Center, Milan, Italy; <sup>b</sup>Department of Pathophysiology and Transplantation, Università degli Studi di Milano, Milan, Italy; <sup>c</sup>Dipartimento di Scienze Fisiche, Informatiche e Matematiche, Università degli Studi di Modena e Reggio Emilia, Modena, Italy; <sup>d</sup>Institute for Cognitive Sciences and Technologies (ISTC), National Research Council (CNR), Bologna, Italy; <sup>e</sup>Department of Computer Science, Università degli Studi di Milano, Milan, Italy; <sup>f</sup>Fondazione IRCCS Ca' Granda Ospedale Maggiore Policlinico, Division of Orthopaedic Surgery and Traumatology, Milan, Italy

### ABSTRACT

**Introduction:** The improved quality of care and increased drug availability have shifted the goal of treating people with hemophilia from life-threatening bleeding prevention to joint health preservation and quality of life amelioration. Many tools are now available to the clinician in order to optimize the management of hemophilic arthropathy.

**Areas covered:** This paper reviews the pivotal role of ultrasound evaluation in early detection of joint bleeding and differential diagnosis of joint pain, with a focus on the feasibility of a long-term monitoring of joint health through the use of artificial intelligence and telemedicine. The literature search methodology included using keywords to search in PubMed and Google Scholar, and articles used were screened by the coauthors of this review.

**Expert opinion:** Joint ultrasound is a practical point-of-care tool with many advantages, including immediate correlation between imaging and clinical presentation, and dynamic evaluation of multiple joints. The potential of telemedicine care, coupled with a point-of-care detection device assisted by artificial intelligence, holds promises for even earlier diagnosis and treatment of joint bleeding. A multidisciplinary approach including early intervention by physical medicine and rehabilitation (PMR) physicians and physiotherapists is crucial to ensure the best possible quality of life for the patient.

### ARTICLE HISTORY

Received 13 April 2024  
Accepted 21 August 2024

### KEYWORDS

Ultrasonography;  
hemophilia; synovitis;  
cartilage; joint diseases

## 1. Introduction

Hemophilia A and B are rare bleeding disorders caused by a complete or partial deficiency in coagulation factors VIII (FVIII) or IX (FIX). Individuals with severe hemophilia, characterized by FVIII or FIX levels below 1 U/dL, if untreated with adequate prophylaxis may experience spontaneous musculoskeletal bleeding, which represent around 80% of overall bleeding events. Recurrent joint bleeding, more frequent in the ankles, elbows, and knees, can lead to hemophilic arthropathy, characterized by irreversible joint damage [1].

Over the last decade, we have witnessed significant progress in hemophilia treatment, with a dramatic progress in the pharmacological armamentarium [2,3]. Despite these strides, challenges and unmet needs persist.

In the past, a FVIII trough level of 1% was considered enough to protect patients with hemophilia from spontaneous bleeding, but Manco-Johnson et al. demonstrated that arthropathy progressed despite adequate prophylaxis even in the absence of overt intra-articular bleeding [4]. Therefore, current international recommendations suggest aiming for a FVIII trough level of 3–5% [5,6]. More recently, several research groups have demonstrated that higher FVIII trough levels, up to 15%, may not be

enough to prevent arthropathy [7,8], possibly also due to different patient features such as baseline joint health and lifestyle, leading to the need for a personalized approach. Our group has also recently confirmed this data in a cohort of mild hemophilia patients, demonstrating that a minimum FVIII trough level of around 17% was needed to prevent spontaneous bleeding [9].

The improvement in the quality of health care and the greater availability of replacement and non-replacement drugs have facilitated a change in the objectives of prophylactic treatment. From solely focusing on preventing life-threatening bleeding, the aim of prophylaxis has now shifted toward preserving joint health and enhancing overall quality of life [10]. Nowadays, in the era of modern treatment for hemophilia, including also non-replacement and gene therapy [2], in order to optimize long-term joint health, efforts should be directed toward the early detection of subclinical bleeding, as there is evidence that even a single bleeding episode can lead to cartilage damage and synovitis [11]. However, it is now clear that the annual bleeding rate is not a reliable and accurate outcome in hemophilia, as patients may not report their treatments and bleeding events regularly in a diary; in addition, it has been demonstrated that patients and

### Article highlights

- Thanks to the improved quality of life care and novel drugs, long-term joint health preservation has become the main target of treatment for people with hemophilia.
- Differential diagnosis of joint pain and early detection of joint bleeding can be made by means of ultrasonography, which has demonstrated to be a reliable point-of-care tool.
- A standardization of the definitions used for ultrasound evaluation of hemophilic joints is still lacking.
- A multidisciplinary management for joint bleeding which involves clinicians, PMR physicians, and physiotherapists is the optimal approach for people with hemophilia.
- Telemedicine, dedicated apps, and artificial intelligence-assisted devices can facilitate the early recognition of joint bleeding ensuring better follow-up and recovery.

physicians may not be able to correctly identify joint bleeding by self-report or physical examination [12]. While many hemophilia comprehensive centers currently confirm joint bleeding through point-of-care ultrasound examination, not all centers have access to specialists proficient in musculoskeletal ultrasound. In a survey on 109 hemophilia treatment centers worldwide, only half of the Centers declared its use as a point-of-care tool, barriers to implementations being mainly the lack of trained health-care professionals and the overall time commitment required [13].

We here discuss the available tools to early detect joint bleeding and damage, to monitor joint damage in the long term and

remotely, and the multidisciplinary management needed to optimize long-term joint health in hemophilia (Figure 1).

## 2. Materials and methods

The following keywords were used in different combinations to identify relevant studies published in PubMed and Google Scholar before March 2024: 'hemophilia,' 'hemophilic arthropathy,' 'physiotherapy,' 'ultrasound,' 'ultrasonography,' 'joint,' 'joint bleeding,' 'cartilage,' 'synovitis,' 'osteocondral,' 'quality of life,' 'telemedicine,' 'app,' 'application.' The search was limited to English-language publications only. We included articles regarding patients with hemophilia. The selected articles were identified by specialists in hematology, rheumatology, computer science, and internal medicine based on their expertise. Any articles for which no full text was available were excluded.

## 3. Early detection of intra-articular bleeding and hemophilic arthropathy

Ultrasound imaging is a simple and reliable tool for evaluating joint health in patients with hemophilia. It is accurate as a point-of-care tool, enabling the differential diagnosis of joint pain due to intra-articular bleeding from pain due to acute synovitis and pain caused by osteochondral damage. Ultrasound imaging can identify joint bleeding even in the absence of overt signs or symptoms, facilitating early

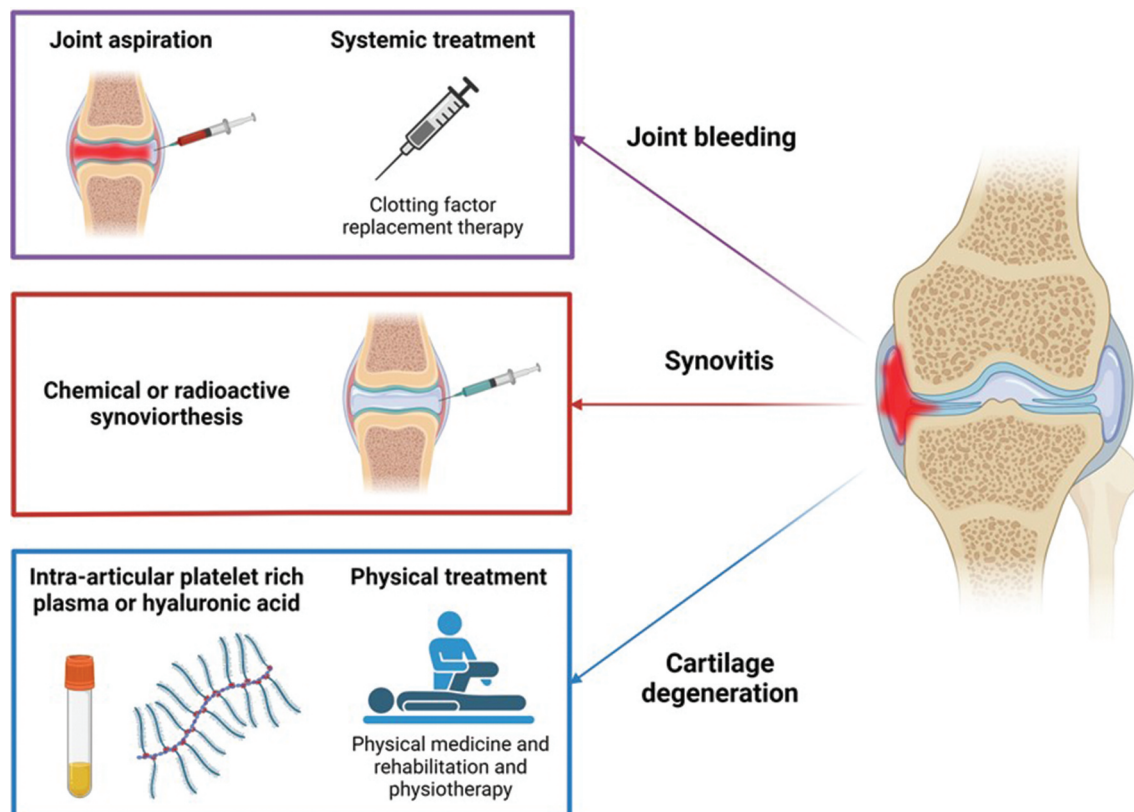


Figure 1. Multidisciplinary approach to joint bleeding, synovitis and cartilage degeneration in patients with hemophilia. Created using Biorender.com.

intervention and prevention of joint damage. Indeed, subclinical joint bleeding is not uncommon due to the availability of both replacement and non-replacement treatments, which mitigate clinical manifestations in patients with hemophilia. In comparison with magnetic resonance imaging (MRI), musculoskeletal ultrasound is much more sensitive in detecting bloody (complex) effusion and distinguishing it from synovial (simple) effusion. However, its diagnostic sensitivity in differentiating blood clots and synovial hyperplasia may vary depending on factors such as the operator's expertise and the quality of the equipment used, potentially resulting in a not completely satisfactory outcome [14–19].

Recurrent and spontaneous joint bleeding stands as the most prevalent manifestation of hemophilia, with the ankles, knees, and elbows, typically affected and termed 'index joints' [1]. The recurrence of intra-articular bleeding fosters the development of synovitis, rendering these joints more susceptible to further bleeds, and progressive joint damage. Historically, the term 'target joint' denoted a joint experiencing recurrent bleed, and the International Society of Thrombosis and Hemostasis (ISTH) definition envisages three or more spontaneous bleeds into a single joint within a consecutive 6-month period [20]. A joint ceases to be a target joint if there have been fewer than two bleeds within 12 consecutive months [20,21]. Recently, the term 'problem joint' has been proposed to identify joints affected by chronic pain and/or with a limited range of motion due to compromised joint integrity, encompassing chronic synovitis with or without osteochondral damage even in the absence of recurrent bleeding [22]. The United Kingdom Haemophilia Centre Doctors' Organisation (UKHCDO) guidelines suggest that, in patients on prophylaxis, any joint experiencing more than two bleeds over a 6-month period should be deemed an 'at-risk joint,' necessitating thorough examination and investigations [23].

### 3.1. Early recognition of joint bleeding (hemarthrosis)

The term hemarthrosis refers to the presence of blood within the joint, originating from the ancient Greek words haimo- (blood) and arthro- (joint). Some clinicians interchangeably use the term hemarthrosis with hemophilic arthropathy, possibly due to its resemblance to the term osteoarthritis (which in turn has become osteoarthritis in the Anglo-Saxon language). To mitigate confusion, we advise to use the term joint or intra-articular bleeding.

Normal synovial fluid is a transudate of plasma enriched with hyaluronans and lubricin, produced by type B synoviocytes. It should not contain red blood cells, except in very low numbers [24]. It has been hypothesized that iron from the degradation of these cells is the primary cause of blood-induced joint damage in hemophilia [25].

Historically, joint bleeding was suspected in patients based on a suggestive history, such as spontaneous or trauma-induced painful swelling, an 'aura,' i.e. a tingling sensation preceding visible swelling or limping, particularly in small children, who rarely complain about pain [20]. However, this definition was applicable when patients were treated more often with episodic replacement therapy and experienced frequent intra-articular bleeding episodes. With the

improvement of prophylaxis using both replacement and non-replacement drugs and a higher level of protection, the severity of joint bleeding has markedly diminished [26], but it is now evident that arthropathy progresses despite adequate treatment even in the absence of overt joint bleeding. In addition, patients and physicians may not be able to recognize intra-articular bleeding, which may occur even without overt joint swelling, as shown by point-of-care ultrasound [27]. This poses a significant challenge for future early diagnosis and prompt treatment.

Ultrasound, conducted by a suitably trained physician, is valuable in assessing simple effusion, complex effusion (indicative of joint bleeding), or synovial hypertrophy, manifested as isoechoic thickening of the capsule [19,28].

Among the different proposed ultrasound scores, the hemophilia early arthropathy detection with ultrasound (HEAD-US) [29] and the Joint tissue Activity and Damage Examination (JADE) [30] are applied worldwide. Both aim at the evaluation and scoring of the presence and degree of synovitis and osteochondral damage, although with different definitions of the ultrasound features, but none of them defines the characteristics of joint bleeding. Our group has recently identified unmet needs in the description of ultrasound features of hemophilic arthropathy and joint bleeding and proposed a set of definitions as a starting point for their standardization and validation. This process has been proposed and planned as a project in the context of the Factor VIII/IX Standardization Subcommittee of the ISTH Scientific and Standardization Committee [19].

### 3.2. Hemophilic synovitis

The term synovitis indicates a reaction of the synovial membrane to a noxious stimulus [31,32]. Normally, the synovial membrane is 2–3 cell-thick, whereas inflammation leads to synovial hyperplasia, characterized by 10–12 cell-thick synovial lining, formation of villi and angiogenesis, partly due to fibroblast-like synoviocyte proliferation or interstitial innate and adaptive cellular infiltrate, depending on the underlying disease [33–35]. Synovial hypertrophy is characterized by the formation of villi and proliferation of vascularization in the sub-synovial layer, which is greater in hemophilic patients than in those with rheumatoid arthritis [36,37]. In the instance of hemophilic arthropathy, as a consequence of the repeated bleeding and the overwhelmed synovial clearing capacity, hemosiderin, the product of blood breakdown, is evident at histopathology [1]. Hemosiderin deposits have been found both in the synovial lining and the supporting layer in the majority of patients affected by hemophilic synovitis, while in patients affected by rheumatoid arthritis or osteoarthritis, they were found in less than 25% [38]. Vascularization of the synovial membrane in hemophilic arthropathy is prominent although, compared to rheumatoid arthritis, a lower degree of inflammation is observed [39,40].

An accurate differential diagnosis of acute joint pain is important because intra-articular bleeding, even though subclinical, needs to be immediately treated with factor replacement [11,12], whereas acute synovitis may require treatment with selective COX-2 inhibitors [27,41]. Synovial hyperplasia can be identified

by ultrasound imaging as an abnormal capsule thickening that appears as a non-displaceable and poorly compressible hypochoic tissue that may exhibit a power-Doppler (PD) signal [42]. Indeed, differently from rheumatoid arthritis or other inflammatory arthritides, the presence of a PD signal is not sensitive to hemophilic arthropathy. When present, the PD signal denotes the presence of inflammation in the course of acute synovitis and is useful to distinguish it from complex (bloody) effusion, which shows no PD signal [43,44]. A synovitis scoring system is available to describe the intensity of the PD signal [45–50]. The importance and significance of the PD signal in hemophilic synovitis are still debated.

The finding of synovitis in the early stage of the disease may be the sign of an inadequate prophylaxis regimen or compliance issues, thus prompting pharmacokinetic studies and finally leading to switching to a different drug with the goal of personalized treatment, if necessary. In addition, the presence of synovial hyperplasia and angiogenesis in this stage of synovitis further predisposes patients to recurrent intra-articular bleeding, whereas late-stage synovitis is mainly characterized by fibrosis and is often not associated with recurrent bleeding [51].

### 3.3. Detecting early osteochondral damage

The presence of blood into the joint cavity due to repeated intra-articular bleeding is considered responsible for the synovial and cartilage damage, eventually leading to hemophilic arthropathy [1]. Although synovial changes are thought to precede cartilage damage, iron may induce modifications in both from the first bleeding episode [25]. As iron deposition diffuses inside the joint cavity, damage develops throughout the joint before, and possibly independent of, the synovial mechanisms of cartilage destruction. To detect osteochondral damage in patients with hemophilia, it is recommended to perform ultrasonography at least at the typical sites corresponding to the main index joints: the anterior portion of the distal humerus (elbow), the femoral trochlea (knee), and the anterior portion of the talar dome (ankle) [29]. Indeed, the ability of ultrasound to evaluate deeper sites of osteochondral damage is limited, although it has been proposed that the osteochondral damage found in one surface can be considered representative of the overall status of the joint, due to the diffuse deposition of iron in hemophilic patients [29]. Finally, all these distinctions may be helpful to detect early osteochondral damage and follow its progression, but they are irreversible, whereas in the early stages, synovitis could still be reversible and should be the focus of prophylaxis fine-tuning and treatment personalization.

## 4. The multidisciplinary management of people with hemophilic arthropathy

With the increased availability of effective prophylaxis and the establishment of a novel recommended protective trough level of at least 3–5% for joint health [5,6], recurrent joint bleeding in patients with hemophilia is a less frequent event.

Currently, the optimal approach to managing joint health is to prevent or reduce the occurrence of joint bleeding in order

to prevent the onset or slow the progression of hemophilic arthropathy. This envisages ensuring an adequate trough level of the replacement treatment, performing periodical joint imaging to assess for synovitis and osteochondral damage and ruling out mechanical causes of bleeding.

### 4.1. Preserving joint health

The cornerstone of hemophilia treatment remains the replacement of the deficient coagulation factor or a non-replacement treatment ensuring adequate hemostasis, aiming at preventing recurring bleeding episodes such as joint bleeding and the onset of arthropathy. However, current pharmacological interventions do not specifically address synovitis, a recognized source of recurrent bleeding, and the primary driver behind hemophilic arthropathy. Given the importance of iron in inducing osteochondral damage, it is reasonable to think that removing blood from the joint in the case of clinically evident intra-articular bleeding, after adequate coverage with replacement treatment, is beneficial not only for pain relief but also for preserving long-term joint health. However, this point remains to be clarified due to the absence of randomized controlled trials [52,53]. Similar uncertainties surround intra-articular corticosteroid therapy, potentially beneficial in specific cases, particularly in patients showing synovitis with PD signal at the ultrasound examination [54].

It is clear that once synovitis has formed, an approach based solely on factor replacement is inadequate. Currently, there is no evidence that synthetic or biological disease-modifying anti-rheumatic drugs may be effective in controlling synovitis, partly due to the lack of sensitive outcome measures, the disease's heterogeneity and the extensive follow-up required. Anti-cytokine treatment with monoclonal antibodies has been proposed as a mean to manage synovitis and potentially reduce joint bleeding recurrence, although this option remains speculative pending elucidation of the pathophysiological mechanisms driving hemophilic arthropathy and the precise involvement of proinflammatory cytokines [55].

The intra-articular administration of corticosteroids, hyaluronic acid, and intra-articular platelet-rich plasma has been proposed as conservative treatments for joint pain relief together with COX-2 antagonists, when a surgical indication is not present yet [56–60]. However, very limited evidence regarding the long-term efficacy of these interventions in pain reduction and prevention of arthropathy progression is available for hemophilic arthropathy and other conditions such as osteoarthritis [61].

Patients with target joints refractory to prophylaxis and local treatments may benefit from chemical synoviorthesis with rifampicin or tetracyclines and radioisotopic synovectomy – the latter being more effective in large joints –, as well as joint embolization in selected cases [62–64].

### 4.2. The role of physical medicine and rehabilitation (PMR) and physiotherapy in hemophilia

Together with pharmacological options, non-pharmacological management plays an important role in preserving or improving joint health and physical function

in patients with hemophilia, as well as in encouraging regular physical activity [65].

PMR and physiotherapy after acute bleeding is strongly recommended to restore joint function and prevent complications due to immobilization [66]. The best option is a program of isometric muscle exercises and stretching [67]. PMR and physiotherapy also play an important role in the prevention of joint and musculoskeletal bleeds and are a crucial part of the comprehensive care for patients with hemophilia [6,68]. The optimal approach should include resistance exercises, isometric exercises, bicycle ergometry, treadmill walking, and hydrotherapy, with a personalized approach [69]. Moreover, gait analysis performed by physiotherapists is able to detect early changes in the walking pattern with a noninvasive and well-tolerated procedure, especially in the pediatric population [70–73]. Therefore, to date, the role of the PMR physician and physiotherapist, in synergy with the other specialists of the multidisciplinary team such as rheumatologists, orthopedic surgeons, and hematologists, is to provide a personalized intervention aimed at maximizing the physical potential and ability of the individual, to support and encourage physical activity, as well as to evaluate and treat dysfunctions not necessarily related to acute bleeding episodes or surgery [74]. Although personalized prophylaxis using factor replacement therapies or non-replacement drugs notably reduces musculoskeletal bleeding episodes, mitigating joint stress requires a combined approach of pharmacological intervention and the meticulous observation of motion patterns, beginning from infancy, with prompt intervention for any dysfunctions identified. Thus, the role of the PMR physician and physiotherapist extends to optimizing biomechanics, preventing bleeding episodes, and facilitating sustained physical activity [75].

## 5. Long-term monitoring of joint health in the era of telemedicine

Based on the evidence of the importance of immediately identifying and treating joint bleeding to prevent irreversible damage, tools that allow a very early diagnosis of intra-articular bleeding are receiving growing interest.

Telemedicine is defined as the distant supply of health-care services and clinical assistance using information and communication technologies, such as the internet, wireless systems, and mobile phones. Telemedicine brings several advantages, such as the possibility of treating patients at home instead of at the hospital, as well as an increased quality of life [76]. However, telemedicine comprises several technologies that still need to be addressed, validated, and deployed before being offered as services to patients. Thanks to the technological development and the introduction of telemedicine, patients can now use electronic diaries (e-diaries) to record bleeds and treatments (Table 1). E-diaries, commonly available as smartphone apps, enable patients to input information about their treatment and bleeding events more quickly and easily than paper diaries. With varying degrees of detail, patients can document bleeds, treatments, and patterns of physical activity.

Several proof-of-concept studies have demonstrated the feasibility of at-home ultrasound imaging for the early diagnosis of joint bleeding, and the research group of Von Drygalski reported that after a 3-month training, patients were comfortable with home-based mobile ultrasonography and could acquire the correct images with good quality [77,78]. More recently, a clinical trial (NCT04131920) has assessed the feasibility and utility of a patient hand-held home ultrasound to determine if joint pain is caused by bleeding, but data analysis is still ongoing. Another solution supports self-acquisition by guiding the patient in the correct positioning of the ultrasound probe thanks to a machine learning model that detects anatomical markers in real time, hence computing how the probe should be moved [79].

To facilitate early detection of subclinical bleeding, artificial intelligence has been tested as well. Artificial intelligence consists of techniques that can be trained on existing data to identify patterns, enabling it to assist clinicians in diagnosing by recognizing these patterns in imaging data.

An expert group in data science, ultrasonography, and hemophilia care (University of Toronto, software company SofTx Innovations Inc., and Novo Nordisk) developed an AI-enabled software prototype using a portable ultrasound device. The algorithm was trained by viewing over 50,000 images of the knee from community controls and over 1,000 images of the knee from patients with hemophilia and showed a good diagnostic accuracy [80].

**Table 1.** Main available applications (apps) for health monitoring in hemophilia.

App	Platforms	Main features	Addressability
MicroHealth Hemophilia Microhealth Inc.	Android, iOS	Logging infusion and bleeding, set reminders for infusion, share data via e-mail, manage multiple users, communicate with hemophilia treatment center via chat, educational resources.	Patients, Caregivers, Doctor
myWAPPS, McMaster University	Android, iOS	Logging infusion and bleeding, set reminders for infusion, share data via e-mail.	Patients, Doctors
HemMobile, Pfizer Inc.	Android, iOS	Logging infusion and bleeding, set reminders for infusion, share data with physician, integration with Google Fit and Apple Health.	Patients, Doctors
Florio HAEMO	Android, iOS	Logging infusion, logging bleeding, set reminders for infusion, share data with physicians, integration with Google Fit and Apple Health.	Patients, Doctors

In a study by Ai et al., the authors studied the possibility of predicting the risk of bleeding for a series of children ( $N=98$ ) with hemophilia A, using three machine learning models to discriminate between bleeding and non-bleeding events [81]. The main suggestion of their study is to use these models to guide children in their physical activities. The analysis has been done on clinical parameters, focusing on the treatment and physical characteristics of the patients. Our group has proposed a solution to detect joint recess distention as a proxy of joint bleeding through the use of a multi-task model that achieves a balanced accuracy value of 0.78 in distinguishing the distended and non-distended sub-quadriceps recess of the knee [82].

Ahmetovic et al. proposed Play4Physio, a telerehabilitation mobile application designed for patients with hemophilia [83]. Through a short setup phase, the system is trained to recognize personalized movements during exercise performance, based on the specific rehabilitation needs of each patient. These movements are then mapped as controls for existing and popular mobile video games, selected based on the patient's interest and on the compatibility with the exercise intensity and pace. The patient can then exercise independently at home, while PMR physicians and physiotherapists can remotely monitor whether the rehabilitation schedule is properly followed [83].

## 6. Conclusion

In an era characterized by the widespread availability of advanced treatments offering increased effectiveness and safety for individuals with hemophilia, our focus naturally shifts toward preventing disability and enhancing health-related quality of life. Incorporating ultrasound and telemedicine for the timely detection of even the slightest joint bleeding provides an opportunity for accurate diagnosis and optimal management, contributing to the preservation of joint health. The involvement of a multidisciplinary team is crucial, ensuring comprehensive and personalized treatment to address the unique needs of each patient with hemophilia.

## 7. Expert opinion

Given the well-established knowledge that a single joint bleed can cause irreversible damage, we advocate for a target of zero joint bleeds across all hemophilia treatments and for improved systems for early joint bleeding detection in the foreseeable future.

Indeed, ultrasound emerges as an easily accessible point-of-care tool for early joint bleeding detection and differential diagnosis of painful joints, offering a number of advantages over MRI. These advantages include applicability in infants and elimination of sedation requirements due to its tolerability, absence of ionizing radiation, the ability to assess multiple joints at each session, immediate correlation between imaging and clinical presentation, and a dynamic evaluation that is not feasible with MRI. The suggested equipment for musculoskeletal ultrasound is usually a high-end device with a 5–12 MHz linear probe to accommodate different depth and width of the joints [84]. In addition, it has been demonstrated that the

combined use of ultrasound and physical examination is superior to using either method alone, providing comprehensive information regarding anatomical and biomechanical changes in hemophilic arthropathy. Ultrasound can detect synovitis even in the early stages of hemophilic arthropathy, while a physical examination assesses mechanical aspects such as strength, pain, and gait that cannot be measured by ultrasound [41,84].

The use of ultrasound in detecting joint bleeding keeps evolving; however, its utilization remains somewhat restricted to several hemophilia care centers, likely due to the need for a more widespread specific training program for health-care providers dealing with hemophilia. An important consideration lies in the special attention that pediatric joints require. The complexity arises from the significant variability in the growth processes of individuals and challenges in detecting joint capsule distension in cartilage-rich joints, where distinguishing it from intra-articular fluid can sometimes be difficult. Specific training on musculoskeletal ultrasound is suggested to better understand the ultrasound anatomy and pathophysiology of the joints, and we advocate this will be part of the hematology residency.

Another obstacle is the absence of standardized ultrasound definitions for different aspects of hemophilic arthropathy and its severity. In the future, efforts should focus on technologies supporting physicians in distinguishing synovial from bloody effusion and detecting even minimal amounts of bloody effusion in patients' joints. This could also lead to the simplification of the current ultrasound acquisition protocols and scoring systems.

Looking ahead to the potential of telemedicine care, the availability of clear standardized definitions and criteria, coupled with point-of-care detection devices, holds promise for earlier treatment initiation in the patient's home. This approach not only ensures swift intervention but also contributes to the emerging objective of personalized, participative, and patient-centered contemporary hemophilia management, aiming to further postpone joint damage. Moreover, home-based early differential diagnosis of joint pain, can avoid any possible overtreatment due to the misinterpretation of the symptoms, thus reducing the direct costs of drugs for hemophilia treatment; on the other hand, it allows prompt treatment even in those cases of subclinical bleeding that are often overlooked and undertreated by the patients, decreasing the number of days of convalescence thanks to an early adequate intervention and monitoring the rehabilitation period after a joint bleed. One of the possible scenarios in the differential diagnosis of painful joints is the finding of synovitis with PD signal at ultrasound in the absence of signs of joint bleeding, indicating active synovitis [41]. Although the treatment of this complication is still debated due to the absence of randomized clinical trials, COX-2 inhibitors could be beneficial for inflammation [6,85]. On the other hand, considering recent evidence showing that synovitis is associated with a higher risk of spontaneous joint bleeding, reevaluation, and, if needed, intensification of the prophylactic regimen is advisable based on individual factors (pharmacokinetics of the administered drug, lifestyle, sport activity, physical exercise), with a strict follow-up of the patients at 72 h from the painful event to ensure that joint bleeding is not missed [41,86].

Given the heterogeneity of clinical manifestations in patients with hemophilia, personalization will be crucial for accurate multidisciplinary management. This approach will rely not only on genetic and molecular data but also on lifestyle, activity, and joint health information that telemedicine systems can more easily provide. Physical activity and sports, once deemed off-limits for hemophilia patients, are now viable and strongly recommended, provided the patient receives adequate protection through personalized treatment tailored to the intensity and frequency of their activities. Lastly, reducing the number of unnecessary visits to medical centers will improve patients' quality of life and decrease social costs related to absences from work or school.

## Funding

This paper was partially supported by the Italian Ministry of Health – Bando Ricerca Corrente. Part of this research was supported by Fondazione di Comunità Milano, Bando 57; the Multilayered Urban Sustainability Action (MUSA) project, funded by the European Union – NextGenerationEU, under the National Recovery and Resilience Plan (PNRR) Mission 4 Component 2 Investment Line 1.5: Strengthening of research structures and creation of R&D “innovation ecosystems”, setup of “territorial leaders in R&D” and by the TEMPO – Tight control of treatment efficacy with tEmedicine for an improved Management of Patients with hemOphilia project, funded by the Italian Ministry of University and Research, Progetti di Ricerca di Rilevante Interesse Nazionale (PRIN) Bando 2022 - grant [2022PKTW2B].

## Declaration of interest

R Gualtierotti is on the advisory boards of Bayer, Roche, Sanofi, SOBI, and Novo Nordisk, and has participated in speaker bureau/educational meetings for Pfizer, SOBI, Takeda, and Novo Nordisk. F Peyvandi is on the advisory boards of CSL Behring, BioMarin, Roche, Sanofi, Sobi, and Novo Nordisk, and has participated in speaker bureau/educational meetings for Takeda/Spark. The authors have no other relevant affiliations or financial involvement with any organization or entity with a financial interest in or financial conflict with the subject matter or materials discussed in the manuscript apart from those disclosed.

## Reviewer disclosures

Peer reviewers on this manuscript have no relevant financial or other relationships to disclose.

## Acknowledgments

The authors gratefully acknowledge Prof. PM Mannucci for their assistance in critically revising this paper.

## References

**Papers of special note have been highlighted as either of interest (•) or of considerable interest (••) to readers.**

- Gualtierotti R, Solimeno LP, Peyvandi F. Hemophilic arthropathy: current knowledge and future perspectives. *J Thromb Haemost.* 2021;19(9):2112–2121. doi: [10.1111/jth.15444](https://doi.org/10.1111/jth.15444)
- Mannucci PM. Hemophilia treatment innovation: 50 years of progress and more to come. *J Thromb Haemost.* 2023;21(3):403–412. doi: [10.1016/j.jtha.2022.12.029](https://doi.org/10.1016/j.jtha.2022.12.029)
- Franchini M, Mannucci PM. The more recent history of hemophilia treatment. *Seminars thrombosis hemostasis.* 2022;48(8):904–910. doi: [10.1055/s-0042-1756188](https://doi.org/10.1055/s-0042-1756188)
- Manco-Johnson MJ, Abshire TC, Shapiro AD, et al. Prophylaxis versus episodic treatment to prevent joint disease in boys with severe hemophilia. *N Engl J Med.* 2007;357(6):535–544. doi: [10.1056/NEJMoa067659](https://doi.org/10.1056/NEJMoa067659) PubMed PMID: 17687129; eng.
- **This study demonstrates that prophylaxis with replacement treatment can prevent joint damage and decrease the frequency of joint bleeding. However, MRI revealed a degree of arthropathy even in joints where no evident bleeding occurred.**
- Peyvandi F, Berger K, Seitz R, et al. Kreuth V initiative: European consensus proposals for treatment of haemophilia using standard products, extended half-life coagulation factor concentrates and non-replacement therapies. *Haematologica.* 2020;105(8):2038–2043. doi: [10.3324/haematol.2019.242735](https://doi.org/10.3324/haematol.2019.242735)
- Srivastava A, Santagostino E, Dougall A, et al. WFH guidelines for the management of hemophilia, 3rd edition. *Haemophilia.* 2020; Suppl 26(S6):1–158. doi: [10.1111/hae.14046](https://doi.org/10.1111/hae.14046)
- Den Uijl IEM, Fischer K, van der Bom JG, et al. Analysis of low frequency bleeding data: the association of joint bleeds according to baseline FVIII activity levels. *Haemophilia.* 2011;17(1):41–44. doi: [10.1111/j.1365-2516.2010.02383.x](https://doi.org/10.1111/j.1365-2516.2010.02383.x)
- Soucie JM, Monahan PE, Kulkarni R, et al. The frequency of joint hemorrhages and procedures in nonsevere hemophilia a vs B. *Blood Adv.* 2018;2(16):2136–2144. doi: [10.1182/bloodadvances.2018020552](https://doi.org/10.1182/bloodadvances.2018020552)
- Agosti P, Siboni SM, Scardo S, et al. Minimum factor VIII levels to prevent joint bleeding in mild hemophilia a. *Blood Adv.* 2023;7(23):7209–7215. doi: [10.1182/bloodadvances.2023011366](https://doi.org/10.1182/bloodadvances.2023011366)
- Lewandowska M, Nasr S, Shapiro AD. Therapeutic and technological advancements in haemophilia care: quantum leaps forward. *Haemophilia.* 2022;28(Suppl S4):77–92. doi: [10.1111/hae.14531](https://doi.org/10.1111/hae.14531)
- **Updated overview of novel and emerging drugs and digital applications informing hemophilia management with a personalised medicine approach.**
- Roosendaal G, Lafeber FP. Blood-induced joint damage in hemophilia. *Semin Thromb Hemost.* 2003;29(1):037–042. doi: [10.1055/s-2003-37938](https://doi.org/10.1055/s-2003-37938)
- **A comprehensive review on the available experimental evidence of the mechanisms linking intra-articular bleeding with synovial and osteochondral damage in hemophilia.**
- Bakeer N, Dover S, Babyn P, et al. Musculoskeletal ultrasound in hemophilia: results and recommendations from a global survey and consensus meeting. *Res Pract Thromb Haemost.* 2021;5(5):e12531. doi: [10.1002/rth2.12531](https://doi.org/10.1002/rth2.12531)
- Ignas DM, Doria AS, von Drygalski A, et al. Use of ultrasound for assessment of musculoskeletal disease in persons with haemophilia: results of an international prophylaxis study group global survey. *Haemophilia.* 2020;26(4):685–693. doi: [10.1111/hae.14006](https://doi.org/10.1111/hae.14006)
- Di Minno MN, Ambrosino P, Quintavalle G, et al. Assessment of hemophilic arthropathy by ultrasound: where do we stand? *Seminars thrombosis hemostasis.* 2016;42(5):541–549. doi: [10.1055/s-0036-1579640](https://doi.org/10.1055/s-0036-1579640)
- Di Minno MN, Iervolino S, Soscia E, et al. Magnetic resonance imaging and ultrasound evaluation of “healthy” joints in young subjects with severe haemophilia A. *Haemophilia.* 2013;19(3):e167–73. doi: [10.1111/hae.12107](https://doi.org/10.1111/hae.12107)
- Keshava SN, Gibikote S, Doria AS. Imaging evaluation of hemophilia: musculoskeletal approach. *Seminars thrombosis hemostasis.* 2015;41(8):880–893. doi: [10.1055/s-0035-1564798](https://doi.org/10.1055/s-0035-1564798)
- Nguyen S, Lu X, Ma Y, et al. Musculoskeletal ultrasound for intra-articular bleed detection: a highly sensitive imaging modality compared with conventional magnetic resonance imaging. *J Thromb Haemost.* 2018;16(3):490–499. doi: [10.1111/jth.13930](https://doi.org/10.1111/jth.13930)
- **A study demonstrating the advantages of musculoskeletal ultrasound over MRI in detecting intra-articular blood, supporting its use in the clinic for rapid bleed detection.**
- von Drygalski A, Moore RE, Nguyen S, et al. Advanced hemophilic arthropathy: sensitivity of soft tissue discrimination with



- musculoskeletal ultrasound. *J Ultrasound Med.* 2018;37(8):1945–1956. doi: [10.1002/jum.14541](https://doi.org/10.1002/jum.14541)
19. Gualtierotti R, Solimeno LP, Peyvandi F. Ultrasound evaluation of hemophilic arthropathy: a proposal of definitions in a changing landscape. *Res Pract Thromb Haemost.* 2024;8(1):102314. doi: [10.1016/j.rpth.2023.102314](https://doi.org/10.1016/j.rpth.2023.102314)
  20. Blanchette VS, Key NS, Ljung LR, et al. Definitions in hemophilia: communication from the SSC of the ISTH. *J Thromb Haemost.* 2014;12(11):1935–1939. doi: [10.1111/jth.12672](https://doi.org/10.1111/jth.12672)
  21. Donadel-Claeyssens S. Current co-ordinated activities of the PEDNET (European paediatric network for haemophilia management). *Haemophilia.* 2006;12(2):124–127. doi: [10.1111/j.1365-2516.2006.01202.x](https://doi.org/10.1111/j.1365-2516.2006.01202.x)
  22. O'Hara J, Khair K, McLaughlin P, et al. "Problem joint" a more patient relevant definition for joint morbidity in haemophilia. *Haemophilia.* 2019;25(S1):35–188. Poster Presentations. doi: [10.1111/hae.13666](https://doi.org/10.1111/hae.13666)
  23. Kidder W, Nguyen S, Larios J, et al. Point-of-care musculoskeletal ultrasound is critical for the diagnosis of hemarthroses, inflammation and soft tissue abnormalities in adult patients with painful hemophilic arthropathy. *Haemophilia.* 2015;21(4):530–537. doi: [10.1111/hae.12637](https://doi.org/10.1111/hae.12637)
  24. Freemont AJ, Denton J. CHAPTER 30 - synovial fluid. In: Gray W Kocjan G, editors. *Diagnostic cytopathology*. 3rd ed. Edinburgh: Churchill Livingstone; 2010. p. 809–817.
  25. Valentino LA, Hakobyan N, Enockson C. Blood-induced joint disease: the confluence of dysregulated oncogenes, inflammatory signals, and angiogenic cues. *Semin Hematol.* 2008;45(2 Suppl 1):S50–7. doi: [10.1053/j.seminhematol.2008.03.017](https://doi.org/10.1053/j.seminhematol.2008.03.017)
  26. Manco-Johnson MJ, Soucie JM, Gill JC. Prophylaxis usage, bleeding rates, and joint outcomes of hemophilia, 1999 to 2010: a surveillance project. *Blood.* 2017;129(17):2368–2374. doi: [10.1182/blood-2016-02-683169](https://doi.org/10.1182/blood-2016-02-683169)
  27. Ceponis A, Wong-Sefidan I, Glass CS, et al. Rapid musculoskeletal ultrasound for painful episodes in adult haemophilia patients. *Haemophilia.* 2013;19(5):790–798. doi: [10.1111/hae.12175](https://doi.org/10.1111/hae.12175)
  28. De la Corte-Rodriguez H, Rodriguez-Merchan EC, Alvarez-Roman MT, et al. The value of HEAD-US system in detecting subclinical abnormalities in joints of patients with hemophilia. *Exp Rev Hematol.* 2018;11(3):253–261. doi: [10.1080/17474086.2018.1435269](https://doi.org/10.1080/17474086.2018.1435269)
  29. Martinoli C, Della Casa Alberighi O, Di Minno G, et al. Development and definition of a simplified scanning procedure and scoring method for haemophilia early arthropathy detection with ultrasound (HEAD-US). *Thromb Haemost.* 2013;109(6):1170–1179. doi: [10.1160/th12-11-0874](https://doi.org/10.1160/th12-11-0874)
  - **Musculoskeletal ultrasound scoring system for assessing damage related to hemophilic arthropathy.**
  30. Volland LM, Zhou JY, Barnes RFW, et al. Development and reliability of the joint tissue activity and damage examination for quantitation of structural abnormalities by musculoskeletal ultrasound in hemophilic joints. *J Ultrasound Med.* 2019;38(6):1569–1581. doi: [10.1002/jum.14846](https://doi.org/10.1002/jum.14846)
  - **Musculoskeletal ultrasound scoring system for patients with hemophilic arthropathy that also takes into account power-Doppler signal**
  31. Hayashi D, Roemer FW, Katur A, et al. Imaging of synovitis in osteoarthritis: current status and outlook. *Semin Arthritis Rheum.* 2011;41(2):116–130. doi: [10.1016/j.semarthrit.2010.12.003](https://doi.org/10.1016/j.semarthrit.2010.12.003)
  32. Sokolove J, Lepus CM. Role of inflammation in the pathogenesis of osteoarthritis: latest findings and interpretations. *Ther Adv Musculoskelet Dis.* 2013;5(2):77–94. doi: [10.1177/1759720x12467868](https://doi.org/10.1177/1759720x12467868)
  33. McInnes IB, Schett G. The pathogenesis of rheumatoid arthritis. *N Engl J Med.* 2011 Dec 8;365(23):2205–2219. doi: [10.1056/NEJMra1004965](https://doi.org/10.1056/NEJMra1004965)
  34. Smith MD. The normal synovium. *Open Rheumatol J.* 2011;5:100–106. doi: [10.2174/1874312901105010100](https://doi.org/10.2174/1874312901105010100)
  35. Firestein GS, McInnes IB. Immunopathogenesis of rheumatoid arthritis. *Immunity.* 2017;46(2):183–196. doi: [10.1016/j.immuni.2017.02.006](https://doi.org/10.1016/j.immuni.2017.02.006)
  36. Jiang J, Leong NL, Khaliq U, et al. Connective tissue growth factor (CTGF/CCN2) in hemophilic arthropathy and arthrofibrosis: a histological analysis. *Haemophilia.* 2016;22(6):e527–e536. doi: [10.1111/hae.13049](https://doi.org/10.1111/hae.13049)
  37. Cooke EJ, Zhou JY, Wyseure T, et al. Vascular permeability and remodelling coincide with inflammatory and reparative processes after joint bleeding in factor VIII-deficient mice. *Thromb Haemost.* 2018;118(6):1036–1047. doi: [10.1055/s-0038-1641755](https://doi.org/10.1055/s-0038-1641755)
  38. Morris CJ, Blake DR, Wainwright AC, et al. Relationship between iron deposits and tissue damage in the synovium: an ultrastructural study. *Ann Rheum Dis.* 1986;45(1):21–26. doi: [10.1136/ard.45.1.21](https://doi.org/10.1136/ard.45.1.21)
  39. Koski JM, Saarakkala S, Helle M, et al. Power Doppler ultrasonography and synovitis: correlating ultrasound imaging with histopathological findings and evaluating the performance of ultrasound equipments. *Ann Rheum Dis.* 2006;65(12):1590–1595. doi: [10.1136/ard.2005.051235](https://doi.org/10.1136/ard.2005.051235)
  40. Naredo E, Collado P, Cruz A, et al. Longitudinal power Doppler ultrasonographic assessment of joint inflammatory activity in early rheumatoid arthritis: predictive value in disease activity and radiologic progression. *Arthritis Rheum.* 2007;57(1):116–124. doi: [10.1002/art.22461](https://doi.org/10.1002/art.22461)
  41. van Bergen EDP, van Leeuwen FHP, Foppen W, et al. Subclinical synovial proliferation in patients with severe haemophilia A: the value of ultrasound screening and biochemical markers. *Haemophilia.* 2023;29(6):1580–1588. doi: [10.1111/hae.14861](https://doi.org/10.1111/hae.14861)
  42. De la Corte-Rodriguez H, Rodriguez-Merchan EC, Alvarez-Roman MT, et al. Clinical assessment and point of care ultrasonography: how to diagnose hemophilic synovitis. *Haemophilia.* 2022;28(1):138–144. doi: [10.1111/hae.14441](https://doi.org/10.1111/hae.14441)
  43. Zhang N, Yang S, Zwagemaker AF, et al. A semiquantitative color Doppler ultrasound scoring system for evaluation of synovitis in joints of patients with blood-induced arthropathy. *Insights Imaging.* 2021;12(1):132. doi: [10.1186/s13244-021-01043-0](https://doi.org/10.1186/s13244-021-01043-0)
  44. Acharya SS, Schloss R, Dyke JP, et al. Power Doppler sonography in the diagnosis of hemophilic synovitis—a promising tool. *J Thromb Haemost.* 2008;6(12):2055–2061. doi: [10.1111/j.1538-7836.2008.03160.x](https://doi.org/10.1111/j.1538-7836.2008.03160.x)
  45. Padovano I, Costantino F, Breban M, et al. Prevalence of ultrasound synovial inflammatory findings in healthy subjects. *Ann Rheum Dis.* 2016;75(10):1819–1823. doi: [10.1136/annrheumdis-2015-208103](https://doi.org/10.1136/annrheumdis-2015-208103)
  46. Bruyn GA, Iagnocco A, Naredo E, et al. OMERACT definitions for ultrasonographic pathologies and elementary lesions of rheumatic disorders 15 years on. *J Rheumatol.* 2019;46(10):1388–1393. doi: [10.3899/jrheum.181095](https://doi.org/10.3899/jrheum.181095)
  47. Plagou A, Teh J, Grainger AJ, et al. Recommendations of the ESSR arthritis subcommittee on ultrasonography in inflammatory joint disease. *Semin Musculoskelet Radiol.* 2016;20(5):496–506. doi: [10.1055/s-0036-1593533](https://doi.org/10.1055/s-0036-1593533)
  48. Szkudlarek M, Court-Payen M, Jacobsen S, et al. Interobserver agreement in ultrasonography of the finger and toe joints in rheumatoid arthritis. *Arthritis Rheum.* 2003;48(4):955–962. doi: [10.1002/art.10877](https://doi.org/10.1002/art.10877)
  49. Backhaus M, Burmester GR, Gerber T, et al. Guidelines for musculoskeletal ultrasound in rheumatology. *Ann Rheum Dis.* 2001 Jul;60(7):641–649. doi: [10.1136/ard.60.7.641](https://doi.org/10.1136/ard.60.7.641)
  50. Terslev L, Naredo E, Aegerter P, et al. Scoring ultrasound synovitis in rheumatoid arthritis: a EULAR-OMERACT ultrasound taskforce-part 2: reliability and application to multiple joints of a standardised consensus-based scoring system. *RMD Open.* 2017;3(1):e000427. doi: [10.1136/rmdopen-2016-000427](https://doi.org/10.1136/rmdopen-2016-000427)
  51. Solimeno L, Goddard N, Pasta G, et al. Management of arthrofibrosis in hemophilic arthropathy. *Haemophilia.* 2010;16(5):115–120. doi: [10.1111/j.1365-2516.2010.02308.x](https://doi.org/10.1111/j.1365-2516.2010.02308.x)
  52. De la Corte-Rodriguez H, Rodriguez-Merchan EC, Alvarez-Roman MT, et al. Accelerating recovery from acute hemarthrosis in patients with hemophilia: the role of joint aspiration. *Blood Coagulation Fibrinolysis.* 2019;30(3):111–119. doi: [10.1097/MBC.0000000000000803](https://doi.org/10.1097/MBC.0000000000000803)
  53. Manners PJ, Price P, Buurman D, et al. Joint aspiration for acute hemarthrosis in children receiving factor VIII prophylaxis for severe hemophilia: 11-year safety data. *J Rheumatol.* 2015;42(5):885–890. doi: [10.3899/jrheum.141236](https://doi.org/10.3899/jrheum.141236)
  54. Martin EJ, Cooke EJ, Ceponis A, et al. Efficacy and safety of point-of-care ultrasound-guided intra-articular corticosteroid joint injections in patients with hemophilic arthropathy. *Haemophilia.* 2017;23(1):135–143. doi: [10.1111/hae.13057](https://doi.org/10.1111/hae.13057)

55. Melchiorre D, Morfini M, Linari S, et al. Anti-tnf- $\alpha$  therapy prevents the recurrence of joint bleeding in haemophilia and arthritis. *Rheumatology (Oxford)*. 2014;53(3):576–578. doi: [10.1093/rheumatology/ket280](https://doi.org/10.1093/rheumatology/ket280)
56. Li TY, Wu YT, Chen LC, et al. An exploratory comparison of single intra-articular injection of platelet-rich plasma vs hyaluronic acid in treatment of haemophilic arthropathy of the knee. *Haemophilia*. 2019;25(3):484–492. doi: [10.1111/hae.13711](https://doi.org/10.1111/hae.13711)
57. Rezende MU, Andrusaitis FR, Silva RT, et al. Joint lavage followed by viscosupplementation and triamcinolone in patients with severe haemophilic arthropathy: objective functional results. *Haemophilia*. 2017;23(2):e105–e115. doi: [10.1111/hae.13115](https://doi.org/10.1111/hae.13115)
58. Carulli C, Rizzo AR, Innocenti M, et al. Viscosupplementation in symptomatic haemophilic arthropathy of the knee and ankle: experience with a high molecular weight hyaluronic acid. *Haemophilia*. 2020;26(4):e198–e200. doi: [10.1111/hae.13979](https://doi.org/10.1111/hae.13979)
59. Liou IH, Lu LY, Lin KY, et al. Combined intra-articular injections of hyaluronic acid and platelet-rich plasma for the treatment of haemophilic arthropathy: a case series study. *Haemophilia*. 2021;27(2):e291–e294. doi: [10.1111/hae.14182](https://doi.org/10.1111/hae.14182)
60. Rodriguez-Merchan EC. Intra-articular injections of hyaluronic acid (viscosupplementation) in the haemophilic knee. *Blood Coagul Fibrinolysis*. 2012;23(7):580–583. doi: [10.1097/MBC.0b013e328357b36a](https://doi.org/10.1097/MBC.0b013e328357b36a)
61. Pavelka K, Uebelhart D. Efficacy evaluation of highly purified intra-articular hyaluronic acid (Sinovial<sup>®</sup>) vs hylan G-F20 (Synvisc<sup>®</sup>) in the treatment of symptomatic knee osteoarthritis. A double-blind, controlled, randomized, parallel-group non-inferiority study. *Osteoarthritis Cartilage*. 2011;19(11):1294–1300. doi: [10.1016/j.joca.2011.07.016](https://doi.org/10.1016/j.joca.2011.07.016)
62. Rodriguez-Merchan EC, De la Corte-Rodriguez H, Jimenez-Yuste V. Radiosynovectomy in haemophilia: long-term results of 500 procedures performed in a 38-year period. *Thromb Res*. 2014;134(5):985–990. doi: [10.1016/j.thromres.2014.08.023](https://doi.org/10.1016/j.thromres.2014.08.023)
63. Ali T, Abou Fakher FH, Schved JF. Chemical vs. radioactive synoviorrhesis for treatment of chronic haemophilic synovitis: Syrian experience. *Haemophilia*. 2016;22(6):e573–e575. doi: [10.1111/hae.13129](https://doi.org/10.1111/hae.13129)
64. Obaji S, Jones C, Yates A, et al. Selective angiographic embolization for recurrent elbow and knee haemarthroses in haemophilia: a retrospective case series. *Haemophilia*. 2015;21(3):e226–e228. doi: [10.1111/hae.12629](https://doi.org/10.1111/hae.12629)
65. Atilla B, Güney-Deniz H. Musculoskeletal treatment in haemophilia. *EFORT Open Rev*. 2019;4(6):230–239. doi: [10.1302/2058-5241.4.180068](https://doi.org/10.1302/2058-5241.4.180068)
66. Mejia-Carvajal C, Hakobyan N, Enockson C, et al. The impact of joint bleeding and synovitis on physical ability and joint function in a murine model of haemophilic synovitis. *Haemophilia*. 2008;14(1):119–126. doi: [10.1111/j.1365-2516.2007.01527.x](https://doi.org/10.1111/j.1365-2516.2007.01527.x)
67. Boccacandro E, Mancuso ME, Riva S, et al. Ageing successfully with haemophilia: a multidisciplinary programme. *Haemophilia*. 2018;24(1):57–62. doi: [10.1111/hae.13308](https://doi.org/10.1111/hae.13308)
68. Blamey G, Forsyth A, Zourikian N, et al. Comprehensive elements of a physiotherapy exercise programme in haemophilia: a global perspective. *Haemophilia*. 2010;16(Suppl 5):136–145. doi: [10.1111/j.1365-2516.2010.02312.x](https://doi.org/10.1111/j.1365-2516.2010.02312.x)
69. de Kleijn P, Dupont G, Jansone K, et al. European principles of care for physiotherapy provision for persons with inherited bleeding disorders: perspectives of physiotherapists and patients. *Haemophilia*. 2022;28(4):649–655. doi: [10.1111/hae.14566](https://doi.org/10.1111/hae.14566)
- **Principles of care by the European Association for Haemophilia and Allied Disorders (EAHAD) and the European Haemophilia Consortium (EHC) outlining standards for optimal personalised, patient-centered care. These standards emphasize physical health, shared decision-making, and supported self-management.**
70. Fouasson-Chailloux A, Maugars Y, Vinatier C, et al. Clinical relevance of 3D gait analysis in patients with haemophilia. *Haemophilia*. 2018;24(5):703–710. doi: [10.1111/hae.13563](https://doi.org/10.1111/hae.13563)
71. Fouasson-Chailloux A, Leboeuf F, Maugars Y, et al. Gait alteration due to haemophilic arthropathies in patients with moderate haemophilia. *Int J Environ Res Public Health*. 2022;19(12):7527. doi: [10.3390/ijerph19127527](https://doi.org/10.3390/ijerph19127527)
72. Putz P, Durstberger S, Kaufmann C, et al. 3D gait analysis, haemophilia joint health score, leg muscle laterality and biomarkers of joint damage: a cross-sectional comparative assessment of haemophilic arthropathy. *Haemophilia*. 2020;26(6):e323–e333. doi: [10.1111/hae.14154](https://doi.org/10.1111/hae.14154)
73. Forneris E, Andreacchio A, Pollio B, et al. Gait analysis in children with haemophilia: first Italian experience at the Turin haemophilia Centre. *Haemophilia*. 2016;22(3):e184–91. doi: [10.1111/hae.12920](https://doi.org/10.1111/hae.12920)
74. Lobet S, Hermans C, Stephensen D. The emerging clinical and scientific role of the physiotherapist in haemophilia care. *Haemophilia*. 2020;26(4):560–562. doi: [10.1111/hae.14096](https://doi.org/10.1111/hae.14096)
75. Boccacandro EA, Pasca S, Begnozzi V, et al. Joint dysfunction as a cause of spontaneous subclinical bleeding in infants with hemophilia. *J Clin Med*. 2023;12(20):6672. doi: [10.3390/jcm12206672](https://doi.org/10.3390/jcm12206672)
76. Kulkarni R. Use of telehealth in the delivery of comprehensive care for patients with haemophilia and other inherited bleeding disorders. *Haemophilia*. 2018;24(1):33–42. doi: [10.1111/hae.13364](https://doi.org/10.1111/hae.13364)
77. Aznar JA, Pérez-Alenda S, Jaca M, et al. Home-delivered ultrasound monitoring for home treatment of haemarthrosis in haemophilia A. *Haemophilia*. 2015;21(2):e147–50. doi: [10.1111/hae.12622](https://doi.org/10.1111/hae.12622)
78. Agüero P, Barnes RF, Flores A, et al. Teleguidance for patient self-imaging of hemophilic joints using Mobile ultrasound devices: a Pilot study. *J Ultrasound Med*. 2023;42(3):701–712. doi: [10.1002/jum.16084](https://doi.org/10.1002/jum.16084)
79. Colussi M, Mascetti S, Ahmetovic D, et al. GAJA - Guided self-acquisition of joint ultrasound images. In: Kainz B, Noble A, Schnabel J, Khanal B, Müller JP Day T, editors. *Simplifying medical ultrasound*. ASMUS 2023. Lecture notes in computer science. Vol. 14337. Cham: Springer; 2023. doi: [10.1007/978-3-031-44521-7\\_13](https://doi.org/10.1007/978-3-031-44521-7_13)
80. Tyrrell P, Blanchette V, Mendez M, et al. Detection of joint effusions in pediatric patients with hemophilia using artificial intelligence-assisted ultrasound Scanning: early insights from the development of a self-management tool [abstract]. *Res Pract Thromb Haemost*. 2021;5(Suppl 2). doi: [10.1002/rth2.12531](https://doi.org/10.1002/rth2.12531)
81. Ai D, Cui C, Tang Y, et al. Machine learning model for predicting physical activity related bleeding risk in Chinese boys with haemophilia A. *Thromb Res*. 2023;232:43–53. doi: [10.1016/j.thromres.2023.10.012](https://doi.org/10.1016/j.thromres.2023.10.012)
82. Colussi M, Civitarese G, Ahmetovic D, et al. Ultrasound detection of subquadriceps recess distension. *Intell Syst With Appl*. 2023;17:200183. doi: [10.1016/j.iswa.2023.200183](https://doi.org/10.1016/j.iswa.2023.200183)
83. Ahmetovic D, Bagnato D, Frangiamone A, et al. Play4Physio: supporting physical therapy of children with hemophilia. In: *The 15th International Conference on Pervasive Technologies Related to Assistive Environments (PETRA '22)*; 2022 Jun 29–Jul 1; Corfu, Greece; 2022. p. 319–320.
84. Gualtierotti R, Giachi A, Truma A, et al. Assessing joint health in haemophilia patients: the combined value of physical examination and ultrasound imaging. *Haemophilia*. 2024;30(4):1018–1024. doi: [10.1111/hae.15030](https://doi.org/10.1111/hae.15030)
85. Gualtierotti R, Tafuri F, Arcudi S, et al. Current and emerging approaches for pain management in hemophilic arthropathy. *Pain Ther*. 2022;11(1):1–15. doi: [10.1007/s40122-021-00345-x](https://doi.org/10.1007/s40122-021-00345-x)
86. Arcudi S, Gualtierotti R, Scalabrino E, et al. Predictive parameters for spontaneous joint bleeding during emicizumab prophylaxis. *Blood Adv*. 2024;8(11):2901–2907. doi: [10.1182/bloodadvances.2023012285](https://doi.org/10.1182/bloodadvances.2023012285)