







# Paraglottic Space Invasion in Glottic Laryngeal Cancer: A Clinical-Pathological Study

Matteo Fermi, MD ; Alfredo Lo Manto, MD ; Gianluca Di Massa, MD; Graziana Gallo, MD;  
 Massimo Lupi, MD; Vincenzo Maiolo, MD ; Grazia Montrone, MD ; Luigi Lovato, MD;  
 Livio Presutti, MD ; Francesco Mattioli, MD 

**Objective:** This study aims to prospectively compare endoscopic, radiological, and pathological features of a cohort of patients with glottic laryngeal squamous cell carcinoma (LSCC) undergoing open partial horizontal laryngectomy (OPHL) type II/III or total laryngectomy to better understand the reliability of preoperative endoscopy and computed tomography (CT) to predict the inferior paraglottic space (iPGS) involvement.

**Methods:** We prospectively compared the endoscopic, radiological, and pathological findings in patients with glottic LSCC who underwent OPHL II/III, or total laryngectomy.

**Results:** Endoscopy achieved a diagnostic accuracy of 87.2% for the anterior iPGS (iPGSa) and 86.1% for the posterior iPGS (iPGSp). There was no statistically significant difference in terms of histopathologic iPGSa involvement between reduced (85%—17/20 pts) and absent (92%—24/26 pts) vocal cord mobility ( $p = 0.39$ ). CT alone did not improve the diagnostic performance of the endoscopy, reaching a diagnostic accuracy of 62.9% and 73.7% for the iPGSa and iPGSp, respectively. When endoscopy and CT were combined, the diagnostic performance improved for the iPGSp, achieving a sensitivity (Se), specificity (Spe), positive predictive value (PPV), and negative predictive value (NPV) of 100%, 89.8%, 68.7%, and 100%, respectively. On the contrary, the combination of CT and endoscopy improved only the Se and NPV for the iPGSa with respect to the sole endoscopic assessment.

**Conclusions:** Whenever motility impairment is present, a histopathologic invasion of the iPGS should be suspected. Endoscopic assessment of laryngeal motility achieved a satisfactory value of Se, Spe, PPV, and NPV in predicting the involvement of the iPGS. CT scan is still the mainstay imaging technique in the clinical staging of patients with LSCC.

**Key Words:** CT scan, endoscopy, glottis, head and neck neoplasms, imaging, laryngeal neoplasms, laryngectomy, laryngoscopy, squamous cell carcinoma of head and neck, x-ray.

**Level of Evidence:** IV

*Laryngoscope*, 00:1–7, 2022

## INTRODUCTION

The paraglottic space is a submucosal laryngeal space containing loose connective tissue, adipose tissue, glands, and vessels. It is bounded anterolaterally by the

thyroid cartilage, dorsally by the piriform sinus, and by the quadrangular membrane superomedially and the elastic cone inferomedially.<sup>1</sup>

It can be divided in a craniocaudal direction into the superior and inferior paraglottic space (iPGS) by a horizontal line passing through the upper free edge of the true vocal fold. The iPGS is a submucosal compartment bound laterally by the laryngeal cartilaginous framework and medially by the thyroarytenoid muscle. It can also be divided into an anterior and posterior iPGS (iPGSa and iPGSp) in the axial plane by a line passing through the anterior border of the vocal process of the arytenoid cartilages.<sup>2,3</sup> The iPGS involvement by glottic tumors may become clinically evident through a reduction of the vocal fold and arytenoid mobility and may serve as a route of tumor spreading.

The iPGS infiltration determines a staging modification from cT2 to cT3 in the actual TNM ed.VIII.<sup>4</sup> Moreover, the iPGS involvement has several therapeutic and prognostic implications. When iPGSp is invaded by laryngeal squamous cell carcinoma (LSCC), transoral laryngeal microsurgery (TLM) is contraindicated, and so is open partial horizontal laryngectomy (OPHL) type II, if the iPGSp is massively infiltrated.<sup>5–7</sup> Thus, in the latter case, OPHL type III extended to cricoarytenoid unit

This is an open access article under the terms of the [Creative Commons Attribution-NonCommercial-NoDerivs](https://creativecommons.org/licenses/by-nc-nd/4.0/) License, which permits use and distribution in any medium, provided the original work is properly cited, the use is non-commercial and no modifications or adaptations are made.

From the Department of Otorhinolaryngology, Head and Neck Surgery (M.F., L.P.), IRCCS Azienda Ospedaliero-Universitaria di Bologna, Policlinico S.Orsola-Malpighi, Bologna, Italy; Department of Specialist, Diagnostic and Experimental Medicine (DIMES), Alma Mater Studiorum (M.F., L.P.), Università di Bologna, Bologna, Italy; Department of Otorhinolaryngology, Head and Neck Surgery (A.L.M., F.M.), University Hospital of Modena, Modena, Italy; Department of Pathology (G.D.M., G.G., M.L.), University Hospital of Modena, Modena, Italy; and the Department of Radiology (V.M., G.M., L.L.), IRCCS Azienda Ospedaliero-Universitaria di Bologna, Policlinico S.Orsola-Malpighi, Bologna, Italy.

Editor's Note: This Manuscript was accepted for publication on July 25, 2022.

M.F. and A.L.M. contributed equally to the study.

The authors have no funding, financial relationships, or conflicts of interest to disclose.

Send correspondence to Alfredo Lo Manto, MD, Department of Otorhinolaryngology, Head and Neck Surgery, University Hospital of Modena, Largo del Pozzo, 71, Modena, MO 41124, Italy. E-mail: [alfredolomanto93@gmail.com](mailto:alfredolomanto93@gmail.com)

DOI: 10.1002/lary.30335

(CAU) or total laryngectomy (TL) should be considered as a therapeutic option. On the other hand, when iPGSa is involved, a type IV TLM can be considered in referral centers without significant reduction in local control, disease-free survival, or organ preservation rates, maintaining the possibility to perform open surgery in case of early detection of recurrence.<sup>6</sup>

Moreover, due to its composition, the iPGS may serve as a route of spread to other parts of the larynx and regional lymph nodes, determining a significant impact on local control, laryngeal preservation rates, and survival.<sup>8,9</sup>

Endoscopy is an essential tool for the assessment of LSCC and guides treatment planning. Unfortunately, both vocal fold and arytenoid mobility can be affected by several factors, such as intrinsic laryngeal muscle or iPGS infiltration, tumor “weight-effect” and also inflammatory changes.<sup>3,10</sup> Imaging is fundamental to better specifying the submucosal extension of the LSCC and defining the cause of hypomobility/fixation of the vocal cords. In this context, magnetic resonance imaging (MRI) with superficial coils has been shown to have better resolution power and allows for differentiating tumor infiltration from peritumoral inflammation, but there is a difficulty in clinical practice to constantly use it because they are much more sophisticated and complex to be properly used, less well-known than computed tomography (CT) machine, requiring longer examination time and more compliant patients.<sup>11</sup>

The CT scan remains the mainstay in the assessment of submucosal tumor spread in the work-up of laryngeal cancer.

This study aims to prospectively compare endoscopic, radiologic, and pathologic features of a cohort of patients with LSCC undergoing OPHL type II/III or TL at a tertiary-care academic center to better understand the reliability of preoperative endoscopy and CT to predict the iPGS involvement.

## METHODS

This is a prospective study performed in a tertiary academic center. The study was conducted in accordance with the Declaration of Helsinki and approved by the Local Ethics Committee (CER Emilia-Romagna: 0026904/21). It includes patients with LSCCs involving the glottis who underwent OPHL II, III, or TL between January 2019 and March 2021.

Patients who previously underwent TLM (cordectomy type I-III according to the European Laryngological Society Classification<sup>7</sup>) were included if they did not experience a postoperative impairment of the vocal fold mobility during the postoperative course.

Patients who had previously undergone chemoradiation therapy were excluded due to the different clinical and diagnostic scenarios. Recurrent tumors after radiation failures are often understaged by imaging studies and endoscopy. This is due to a different histologic growth pattern of recurrent laryngeal carcinomas, which is characterized by multifocal tumor nests instead of the central growth pattern in “de novo” carcinomas.<sup>12</sup>

All patients underwent preoperative transnasal flexible video-endoscopy with high-definition white light and PIET filter fibroscopy (XION MATRIX PL Spectar endoscopy system, Berlin, Germany).

The preoperative endoscopic assessment was recorded and stored for further evaluation by two experienced laryngologists (M.F., F.M.) blinded to the CT scan images, type of surgery performed, and histopathological reports. They were asked to assess the vocal fold and arytenoid mobility.<sup>13</sup>

The two raters expressed the degree of mobility of the vocal cords as normal, impaired, or absent for each side affected by the tumor. For statistical purposes, cases of impaired or absent mobility were pooled and considered as “reduced mobility.” Bulky tumors impairing vocal fold mobility assessment were not included.

## Radiologic Assessment

All the patients underwent contrast-enhanced neck CT preoperatively at our Radiology Unit within 3 weeks before surgery.

Multi-detector CT scans were performed with a 64-channel helical CT system (Lightspeed VCT LS Advantage 64 slices, General Electric Medical System) according to neck laryngeal protocol parameters: 120 kV, 225 mA, pitch 0.5, rotation time 0.8 s, table speed 40 mm/rotation, 1.25 mm slice thickness, 0.6 mm collimation, matrix size 512 512, and FOV of 20 cm.

All examinations were performed with patients in the supine position and previously instructed to avoid swallowing and coughing while continuing quiet breathing during the scan.

A non-ionic contrast medium was injected with an automated power injector at a maximal flow rate of 2 ml/s into an antecubital vein.

Axial slices were obtained from the base of the skull to the sternoclavicular joints, with a delay time of 80 s; in post-processing, slices were reconstructed on a plane parallel to the true vocal cords, using bone and soft-tissue algorithms, and then reconstructed in the coronal and/or sagittal plane.

All scans were blindly examined by the same experienced head and neck radiologist (V.M.).

Low-quality scans were sorted out if an adequate diagnostic evaluation could not be provided.

The radiologic goal was to examine iPGSa and iPGSp to assess their infiltration.

## Pathologic Assessment

All laryngectomy specimens were examined postoperatively and analyzed for tumor site and extent according to ICCR guidelines<sup>14</sup> by the same experienced pathologist (M.L.). All laryngectomy specimens were macroscopically analyzed. Slides were stained with hematoxylin and eosin and assessed in terms of iPGS involvement. Histopathologic involvement of the iPGS was defined as the neoplastic microscopic infiltration of the loose connective and adipose tissue of the iPGS. Sections of both glottic areas were always submitted to assess both iPGS, even when they were not macroscopically involved (Figs. 1–3).

## Statistical Analysis

The IBM SPSS software for statistics (version 26, IBM Corp, Armonk, NY) was used to perform statistical analysis. The normality of data distribution was assessed with the Kolmogorov–Smirnov test. Continuous variables were presented as mean ( $\pm$ SD) or median (interquartile range), as appropriate, while categorical variables were presented as percentages.

Inter-rater reliability was assessed via the Cohen’s *K* coefficient and rated as 0–0.20 as slight, 0.21–0.40 as fair, 0.41–0.60 as moderate, 0.61–0.80 as substantial, and 0.81–1 as almost perfect agreement.<sup>15</sup>

The Chi-square test (or Fisher’s exact test) and the Mann–Whitney *U* test were used to compare and analyze the

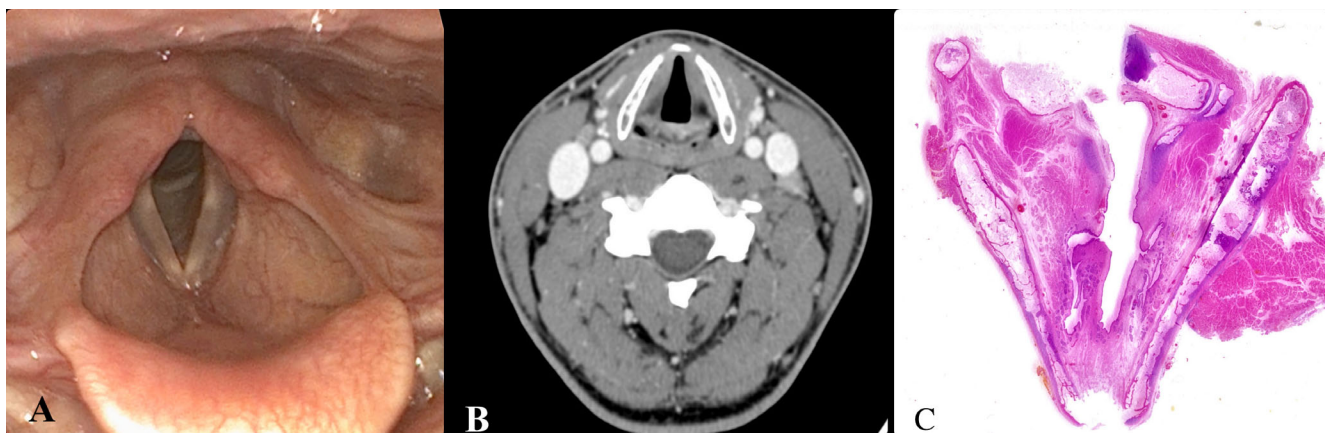


Fig. 1. A 34-year-old-female with a normal glottic plane. (A) Laryngeal endoscopy. (B) Axial contrast-enhanced computed tomography-scan section. (C) Histological section stained with hematoxylin and eosin. [Color figure can be viewed in the online issue, which is available at [www.laryngoscope.com](http://www.laryngoscope.com).]

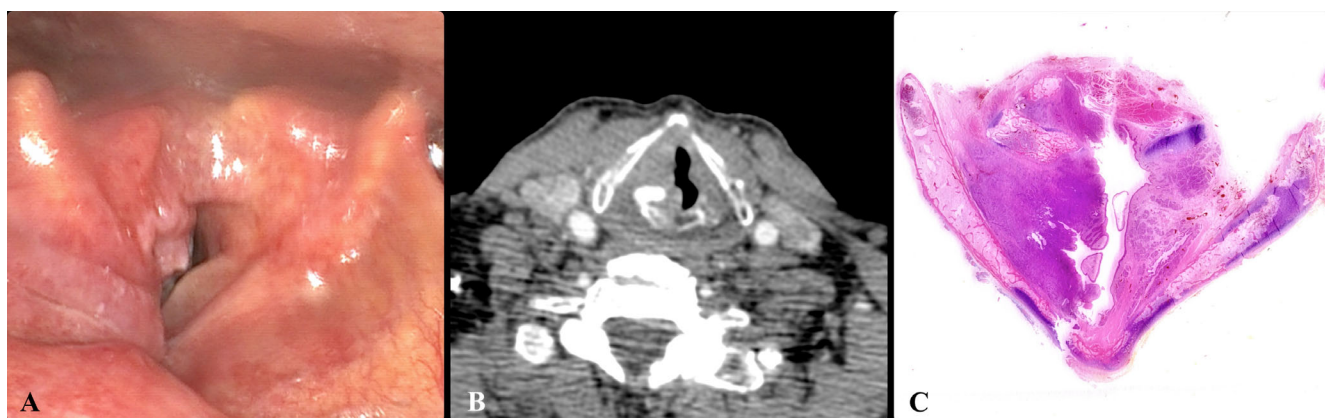

Fig. 2. A 67-year-old-man with a right glottic squamous cell carcinoma. (A) Preoperative endoscopy. Absent arytenoid and vocal fold mobility. (B) Preoperative axial contrast-enhanced computed tomography-scan section showing involvement of the anterior and posterior paraglottic space and sclerosis of the arytenoid cartilage. (C) Histological section stained with hematoxylin and eosin showing anterior and posterior paraglottic space involvement and arytenoid cartilage infiltration. [Color figure can be viewed in the online issue, which is available at [www.laryngoscope.com](http://www.laryngoscope.com).]

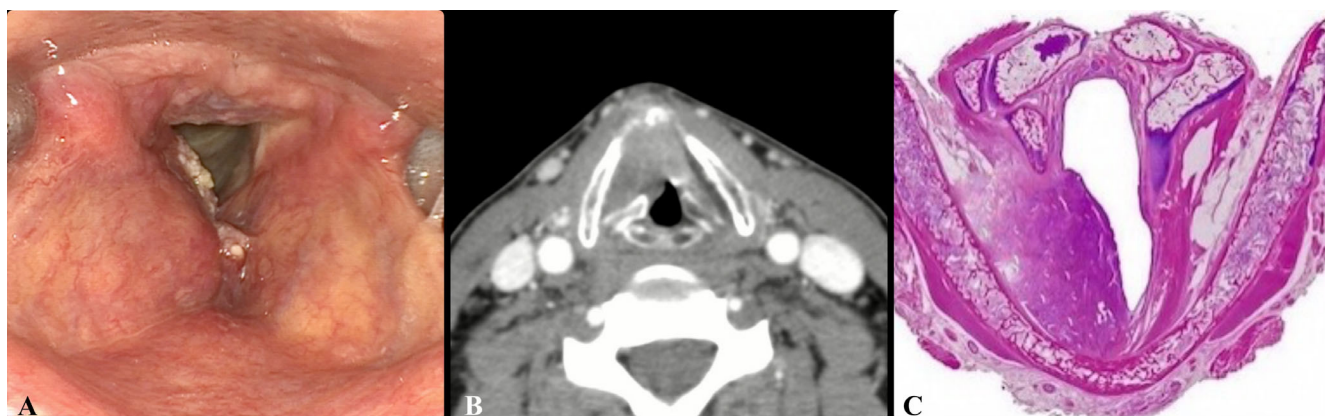

Fig. 3. A 73-year-old-man with right glottic squamous cell carcinoma. (A) Preoperative endoscopy: Normal arytenoid mobility and reduced vocal cord mobility. (B) Preoperative axial contrast-enhanced computed tomography-scan section showing probable involvement of the anterior paraglottic space. (C) Histological section stained with hematoxylin and eosin showing anterior paraglottic space involvement. [Color figure can be viewed in the online issue, which is available at [www.laryngoscope.com](http://www.laryngoscope.com).]

clinical, radiological, and pathological findings. Odds ratios (OR) were calculated for significant values.

The specificity (Spe), sensitivity (Se), positive predictive value (PPV), and negative predictive value (NPV) of the clinical and radiological findings were calculated with respect to the pathological result.

A *p*-value <0.05 was considered statistically significant.

## RESULTS

### Patients

This study concerned a cohort of 67 patients (91.5% male, mean age 67 years  $\pm$  10.2 SD).

Eight patients were excluded due to the presence of a bulky tumor.

The final study population consisted of 59 patients affected by LSCC and treated with open laryngeal surgery (i.e., OPHL types II and III or TL).

The distribution of the patients by clinical and pathological T stage is shown in Table I.

Thirteen patients (15.1%) previously underwent TLM and were treated with open laryngeal surgery for recurrent LSCC, 7 patients had previously undergone cordectomy type I, 5 had patients cordectomy type II, and only 1 patient cordectomy type III, according to the European Laryngological Society Classification.<sup>7</sup> Twenty-seven (45.7%) patients underwent TL, 3 (5.1%) underwent OPHL type III and the remaining 30 (49.2%) patients underwent OPHL type II. Eleven patients (18.6%) who underwent OPHL had either the arytenoid (13.6%) or the CAU (5.1%) sacrificed.

TABLE I.  
Demographic, Clinical and Histopathological Features of the Study Population.

| Variables                  | No. of Patients     |
|----------------------------|---------------------|
| Age, years (mean $\pm$ SD) | 67 years $\pm$ 10.2 |
| Sex                        |                     |
| Male                       | 61                  |
| Female                     | 8                   |
| Vocal fold mobility        |                     |
| Normal                     | 40                  |
| Impaired                   | 20                  |
| Fixed                      | 26                  |
| Arytenoid mobility         |                     |
| Normal                     | 63                  |
| Impaired                   | 23                  |
| pT1b                       | 1                   |
| pT2                        | 17                  |
| pT3                        | 23                  |
| pT4a                       | 18                  |
| pN0                        | 49                  |
| pN1                        | 4                   |
| pN2b                       | 2                   |
| pN2c                       | 2                   |
| pN3b                       | 2                   |

### Endoscopic Findings

The raters, independently, assessed the vocal cord and arytenoid mobility on each side macroscopically involved by the tumor (*n* = 86).

The inter-rater reliability was tested for vocal cord and arytenoid mobility, achieving an almost perfect agreement in both cases (Cohen's *K* = 0.859 and 0.941, respectively).

After the raters' agreement, the vocal cord mobility was considered normal in 40 (46.5%) cases, impaired in 20 (23.3%), and absent in 26 (30.2%). The arytenoid mobility was rated as normal in 63 (73.3%) cases and abnormal in 23 (26.7%).

There was no statistically significant difference in terms of histopathologic iPGSa involvement between reduced (85%—17/20 pts) and absent (92%—24/26 pts) vocal cord mobility (*p* = 0.39).

In the 20 and 26 patients who had impaired or absent vocal cord mobility, histological examination showed paraglottic space (PGS) infiltration in 41 cases out of 46 (Chi-square test, *p* < 0.01, OR 57.4, confidence interval [CI] 15.3–214.6).

The endoscopic finding of a reduced (impaired or absent) vocal fold mobility showed a Se, Spe, PPV, and NPV of 89.1%, 87.5%, 89.1%, and 87.5%, respectively, in identifying a histopathologic involvement of the iPGSa, achieving a diagnostic accuracy of 87.2%.

In the 23 patients who had reduced arytenoid mobility, histological examination showed posterior PGS infiltration in 15 (78.9%) cases (Chi-square test, *p* < 0.01, OR 27.6, CI 7.3–104.2).

The endoscopic finding of reduced arytenoid mobility showed a Se, Spe, PPV, and NPV of 78.9%, 88.1%, 65.2%, and 93.7%, respectively, in identifying a histopathologic involvement of the iPGSp, achieving a diagnostic accuracy of 86.1% (Table II).

### Radiological Findings

The radiologist was asked to assess the radiological PGS involvement on each side macroscopically involved by the tumor (*n* = 86). Ten (8.6%) cases were excluded from the analysis due to the low-quality images determining an inadequate evaluation.

CT identified PGS involvement in 55 (63.9%) cases. The anterior PGS was radiologically involved in all of them, while the posterior PGS was involved only in 27 (32.6%).

TABLE II.  
Diagnostic Accuracy of Preoperative Endoscopy According to Pathological Results.

| Compartment | Sensitivity (%) | Specificity (%) | PPV (%) | NPV (%) | Accuracy (%) |
|-------------|-----------------|-----------------|---------|---------|--------------|
| iPGsA       | 89.1            | 87.5            | 89.1    | 87.5    | 87.2         |
| iPGsP       | 78.9            | 88.1            | 65.2    | 93.7    | 86.1         |

iPGsA = anterior compartment of inferior paraglottic space; iPGsP = posterior compartment of inferior paraglottic space; NPV = negative predictive value; PPV = positive predictive value.

TABLE III.

Diagnostic Accuracy of Computed Tomography-Scan According to Pathological Results.

| Compartment | Sensitivity (%) | Specificity (%) | PPV (%) | NPV (%) | Accuracy (%) |
|-------------|-----------------|-----------------|---------|---------|--------------|
| iPGsA       | 92.5            | 50.0            | 67.3    | 85.7    | 62.9         |
| iPGsP       | 70.6            | 74.6            | 44.4    | 89.8    | 73.7         |

iPGsA = anterior compartment of inferior paraglottic space;  
 iPGsP = posterior compartment of inferior paraglottic space;  
 NPV = negative predictive value; PPV = positive predictive value.

TABLE IV.

Diagnostic Accuracy of Combined Preoperative Endoscopy and Computed Tomography-Scan According to Pathological Results.

| Compartment | Sensitivity (%) | Specificity (%) | PPV (%) | NPV (%) | Accuracy (%) |
|-------------|-----------------|-----------------|---------|---------|--------------|
| iPGsA       | 100             | 58.3            | 72.2    | 100     | 80           |
| iPGsP       | 100             | 89.8            | 68.7    | 100     | 91.7         |

iPGsA = anterior compartment of inferior paraglottic space;  
 iPGsP = posterior compartment of inferior paraglottic space;  
 NPV = negative predictive value; PPV = positive predictive value.

The radiological findings of the involvement of iPGS showed a Se, Spe, PPV, and NPV of 92.5%, 50.0%, 67.3%, and 85.7%, respectively, in identifying a histopathologic involvement of the iPGS.

The same analysis was performed by dividing the iPGSa and iPGSp to examine the radiologic accuracy to diagnose their histopathologic infiltration.

The radiological finding of involvement of iPGSa showed a Se, Spe, PPV, and NPV of 94.9%, 51.4%, 67.3%, and 90.5%, respectively, in identifying a histopathologic involvement of the iPGSa, achieving a diagnostic accuracy of 62.9%.

The radiological findings of involvement of iPGSp showed a Se, Spe, PPV, and NPV of 70.6%, 74.6%, 44.4%, and 89.8%, respectively, in identifying a histopathologic involvement of the iPGSp, achieving a diagnostic accuracy of 73.7% (Table III).

When the preoperative endoscopy and CT scan findings were combined a significantly higher prediction of iPGS invasion was reached, achieving a Se, Spe, PPV, NPV, and accuracy of 100%, 58.3%, 72.2%, 100%, and 80% for the iPGSa and Se, Spe, PPV, NPV, and accuracy of 100%, 89.8%, 68.7%, 100%, and 91.7% for the iPGSp (Table IV).

## DISCUSSION

Assessing iPGS infiltration using endoscopy and radiology allows us to plan an adequate therapeutic strategy.

iPGS involvement may cause impaired vocal cord and/or arytenoid mobility or fixation. Other factors can cause the same endoscopic findings, such as bulky tumors, inflammatory edema, and inferior laryngeal nerve infiltration. To date, there is no method for

objectively evaluating the vocal fold mobility, and this leads to erroneous estimates of clinical staging.

Thus, a preoperative radiologic assessment is mandatory to understand the localization of the tumor and its possible spreading routes, especially those that are unpredictable with sole clinical evaluation (e.g., cartilage invasion, extra laryngeal extension).

CT is considered the workhorse in the evaluation of LSCC, providing a fast and reliable anatomic picture that can be reconstructed in different planes.

MRI with contrast, especially with surface coils, has the potential for better discrimination and definition of submucosal tissue changes and cartilage abnormalities.<sup>16,17</sup> However, it requires longer acquisition time and patient cooperation throughout the procedure.

To our knowledge, there are a few studies in the literature that focused on the endoscopic evaluation of vocal fold mobility as a factor predicting iPGS infiltration.<sup>8,18</sup>

In this study, the endoscopic evaluation was shown to be reliable in identifying a histopathologic involvement of the iPGSa, reaching values of Se, Spe, PPV, and NPV of 89.1%, 87.5%, 89.1%, and 87.5%, respectively.

In those patients who had a reduced or fixed arytenoid mobility, these values were 78.9%, 88.1%, 65.2%, and 93.7%, respectively, in identifying a histopathologic involvement of the iPGSp. These findings are slightly different from those reported by Lucioni et al., who studied the association between the evidence of reduced vocal fold mobility with histopathologic infiltration of the CAU and iPGSp, reporting values of Se, Spe, PPV, and NPV of 93%, 58%, 30%, and 98%, respectively.<sup>18</sup>

Even if the current TNM staging system does not differentiate between impairments of vocal fold and arytenoid mobility, we recommend assessing this endoscopic finding during preoperative diagnostic work-up. It was demonstrated that there is a significant association of both vocal fold and arytenoid mobility impairment with iPGS infiltration (iPGSa—OR 57.4, CI 15.3–214.6; iPGSp—OR 27.6, CI 7.3–104.2). Surprisingly, in this case series, there was no statistically significant difference between endoscopic findings of reduced and absent vocal fold mobility with respect to histopathologic iPGS neoplastic infiltration. This result is even more important if we consider that in this selected cohort of patients, those with bulky tumor-provoking mass-effect related mobility impairment were excluded. Thus, whenever vocal fold mobility is impaired, iPGS infiltration should be suspected and further assessed through radiologic studies.

The CT scan showed values of Se, Spe, PPV, and NPV of 92.5%, 50.0%, 67.3%, and 85.7%, respectively, in predicting a histopathologic involvement of the iPGSa and of 70.6%, 74.6%, 44.4%, and 89.8% in predicting the involvement of the iPGSp.

The CT scan overestimation in predicting the iPGSa involvement could be attributed to several causes, such as the difficulty to discriminate between tumoral tissue and adjacent peritumoral inflammation, the overlap between the tumor and the adjacent structures' contrast-enhanced density; the paucity of adipose tissue that results in a lack of hypodensity front which discriminates the iPGS invasion harder.<sup>19</sup>

The low specificity of the CT scan in predicting the iPGSa involvement has been remarked in a few studies in the literature.<sup>16,19,20</sup>

Benazzo et al. described high sensitivity and low specificity for deep intralaryngeal invasion by LSCC (90.3% and 19.1%, respectively).<sup>19</sup> In a previously published article, Jaipuria et al. compared CT staging with histopathology in T3–T4 laryngeal cancers, reporting 85.7% sensitivity, 77.8% specificity, and 82.6% accuracy for the assessment of iPGSa.<sup>20</sup> Despite differences in percentage specificity of CT scan in predicting iPGSa involvement, it is always reported to be low, and this could be considered an intrinsic limit of the CT scan for the reasons previously described.

Concerning the iPGSp infiltration, Benazzo et al. showed that the CT scan predicted its histopathologic invasion with values of Se, Spe, PPV, and NPV of 58.8%, 82.6%, 62.5%, and 80.0%, respectively.<sup>19</sup>

These data slightly differ from those reported in this study. Even in this case, a change in specificity trend that is higher than the data corresponding to the iPGSa is observed. This finding could be explained by the fact that the volume of adipose tissue, and the hypodense signal on the CT scan increase in the iPGSp, allowing to achieve a lower number of false positives.

Surprisingly, there are studies where the MRI performances in predicting iPGS involvement are not better than CT scans. For instance, Banko et al. reported values of Se and Spe of 67% and 50%, respectively, in predicting iPGS involvement.

Ravanelli et al. studied the diagnostic accuracy of the MRI with diffusion-weighted imaging (DWI), superficial coils directly applied to the larynx, and a state-of-the-art technique (including spatial resolution and special sequences with motion-compensation for uncooperative patients), achieving satisfactory values of Se and Spe, being 100% and 78%, respectively.<sup>3</sup> Unfortunately, such an institutional protocol is not widely applied in other centers, and these MRI findings are hardly achievable.

The tumor invasion of iPGS upstages the LSCC into T3 and is related to a higher probability of lymph node metastasis, worsening the prognosis.<sup>9</sup> For such reasons, its involvement might justify open laryngeal surgery rather than TLM or primary radiotherapy.<sup>21</sup> Unfortunately, large multicentric prospective studies showing the oncological and functional outcomes of different therapeutic strategies (e.g., TLM, OPHLs, TL, and organ preservation protocols) are still lacking.

However, if the iPGS is involved, the therapeutic strategy significantly changes, especially when conservative surgery is considered. If iPGSa invasion is suspected, either a type IV–V cordectomy or an OPHL type II should be contemplated.<sup>7</sup> On the other hand, if iPGSp invasion is suspected, TLM is contraindicated and OPHL type III A + CAU might be considered as an alternative to TL or chemoradiation therapy, especially if a massive infiltration of iPGSp is recognized.<sup>22</sup> Considering the very high diagnostic Se of the combination of endoscopy and CT, herein reported, when there are no radiological signs of iPGS infiltration and a normal vocal fold/arytenoid mobility is assessed, a histopathologic infiltration of the iPGS

can be confidently excluded and therefore the patient can be addressed to a conservative approach.

Regarding those cases in which the arytenoid mobility is compromised and there is a radiological suspicion of infiltration of the iPGSp, given the high levels of Spe on the combined data, the patient can be referred to OPHL III + CAU (for selected patients) or TL.

The Spe values for iPGSa prediction obtained by combining CT-scan and preoperative endoscopy data were found to be lower (58.3%) than the only preoperative endoscopic evaluation (87.5%). Moreover, the diagnostic accuracy of preoperative endoscopy for iPGSa infiltration is high in terms of Se, PPV, and NPV.

Therefore, it can be postulated that whenever there is vocal fold mobility impairment, histopathologic involvement of iPGSa can be reliably suspected. Thus, due to the low diagnostic accuracy of the CT on iPGSa, an MRI with contrast and DWI sequences with superficial coils should be performed, especially whenever considering TLM.

This study has several weaknesses. First, the sample is limited, and further studies are required to confirm our data, preferably in a multicentric setting involving different endoscopy and radiology raters.

This study has several weaknesses. First, the sample is limited, and further studies are required to confirm our data, preferably in a multicentric setting involving different endoscopy and radiology raters. Moreover, a study on recurrent glottic SCCs would be useful to ascertain the diagnostic accuracy of endoscopy and radiology in this different scenario. In this study, a small population of patients who previously underwent TLM type I–III was included due to the integrity of the PGS after surgery. However, this population could be a confounding factor when considering the reliability of vocal fold mobility assessment and CT-scan.

Lastly, the endoscopic finding of an impaired/fixed vocal fold or arytenoid is not univocal and prone to subjectivity.

The endoscopic finding of an impaired/fixed vocal fold or arytenoid is not univocal and prone to subjectivity. However, in this study, two raters independently assessed every single case and satisfactory inter-rater reliability (Cohen's  $K = 0.859$  vocal cord mobility and Cohen's  $K = 0.941$  arytenoid mobility) was achieved. In the future, it would be desirable to develop an objective assessment tool able to quantify the degree of mobility impairment to let the scientific community find an association with iPGS infiltration.<sup>23</sup>

## CONCLUSIONS

Endoscopic assessment of laryngeal mobility achieved satisfactory values of Se, Spe, PPV, and NPV in predicting iPGS involvement, especially considering the iPGSa. No differences between reduced and absent mobility were found in this analysis, demonstrating that whenever mobility impairment is present, no matter what degree, a histopathologic invasion of the iPGS should be strongly suspected. CT-scan, despite its limitations, is still the mainstay imaging technique in the clinical staging of patients with LSCC and will remain so at least

until MRI, with specific acquisition protocols for the larynx, will become more accessible. Especially when considering TLM surgery, present data suggest that when vocal fold mobility is impaired, a careful radiologic assessment of the iPGS should be performed to plan an adequate resection, reducing the risk of LSCC persistence or recurrence.

## ACKNOWLEDGMENT

Open Access Funding provided by Università degli Studi di Modena e Reggio Emilia within the CRUI-CARE Agreement.

## BIBLIOGRAPHY

1. Tucker GF, Smith HR. A histological demonstration of the development of laryngeal connective tissue compartments. *Trans Am Acad Ophthalmol Otolaryngol.* 1962;66:308-318.
2. Succo G, Crosetti E, Bertolin A, et al. Treatment for T3 to T4a laryngeal cancer by open partial horizontal laryngectomies: prognostic impact of different pathologic tumor subcategories. *Head Neck.* 2018;40(9):1897-1908. <https://doi.org/10.1002/hed.25176>.
3. Ravanelli M, Paderno A, Del Bon F, et al. Prediction of posterior paraglottic space and cricoarytenoid unit involvement in endoscopically T3 glottic cancer with arytenoid fixation by magnetic resonance with surface coils. *Cancer.* 2019;111(1):67. <https://doi.org/10.3390/cancers111010067>.
4. Amin MB, Edge SB, Greene FL, et al. *AJCC Cancer Staging Manual.* 8th ed. Springer-Verlag; 2017.
5. Succo G, Peretti G, Piazza C, et al. Open partial horizontal laryngectomies: a proposal for classification by the working committee on nomenclature of the European Laryngological Society. *Eur Arch Otorhinolaryngol.* 2014; 271(9):2489-2496.
6. Peretti G, Piazza C, Cocco D, et al. Transoral CO<sub>2</sub> laser treatment for Tis-T3 glottic cancer: the University of Brescia experience on 595 patients. *Head Neck.* 2009;32(8):977-983. <https://doi.org/10.1002/hed.21278>.
7. Remacle M, Eckel HE, Antonelli A, et al. Endoscopic cordectomy. A proposal for a classification by the Working Committee, European Laryngological Society. *Eur Arch Otorhinolaryngol.* 2000;257(4):227-231. <https://doi.org/10.1007/s004050050228>.
8. Dagan R, Morris CG, Bennett JA, et al. Prognostic significance of paraglottic space invasion in T2N0 glottic carcinoma. *Am J Clin Oncol.* 2007; 30(2):186-190. <https://doi.org/10.1097/01.coc.0000251403.54180.df>.
9. Murakami R, Nishimura R, Baba Y, et al. Prognostic factors of glottic carcinomas treated with radiation therapy: value of the adjacent sign on radiological examinations in the sixth edition of the UICC TNM staging system. *Int J Radiat Oncol Biol Phys.* 2005;61(2):471-475. <https://doi.org/10.1016/j.ijrobp.2004.05.024>.
10. Katilmiş H, Öztürkcan S, Özdemir I, et al. A clinico-pathological study of laryngeal and hypopharyngeal carcinoma: correlation of cord-arytenoid mobility with histopathologic involvement. *Otolaryngol Head Neck Surg.* 2007;136(2):291-295. <https://doi.org/10.1016/j.otohns.2006.08.022>.
11. Becker M, Monnier Y, de Vito C. MR imaging of laryngeal and hypopharyngeal cancer. *Magn Reson Imaging Clin N Am.* 2022;30(1):53-72. <https://doi.org/10.1016/j.mric.2021.08.002>.
12. Zbären P, Nuyens M, Curschmann J, Stauffer E. Histologic characteristics and tumor spread of recurrent glottic carcinoma: analysis on whole-organ sections and comparison with tumor spread of primary glottic carcinomas. *Head Neck.* 2007;29(1):26-32. <https://doi.org/10.1002/hed.20502>.
13. Rosen CA, Mau T, Remacle M, et al. Nomenclature proposal to describe vocal fold motion impairment. *Eur Arch Otorhinolaryngol.* 2016;273(8): 1995-1999. <https://doi.org/10.1007/s00405-015-3663-0>.
14. Helliwell T, Chernock R, Dahlstrom JE, et al. Data set for the reporting of carcinomas of the hypopharynx, larynx, and trachea: explanations and recommendations of the guidelines from the international collaboration on cancer reporting. *Arch Pathol Lab Med.* 2019;143(4):432-438. <https://doi.org/10.5858/arpa.2018-0419-SA>.
15. Landis JR, Koch GG. The measurement of observer agreement for categorical data. *Biometrics.* 1977;33(1):159-174. <https://doi.org/10.2307/2529310>.
16. Bertrand M, Tollard E, François A, et al. CT scan, MR imaging and anatomopathologic correlation in the glottic carcinoma T1-T2. *Rev Laryngol Otol Rhinol.* 2010;131(1):51-57.
17. Maroldi R, Ravanelli M, Farina D. Magnetic resonance for laryngeal cancer. *Curr Opin Otolaryngol Head Neck Surg.* 2014;22(2):131-139. <https://doi.org/10.1097/MOO.0000000000000036>.
18. Lucioni M, Lionello M, Machin P, et al. Sclerosis of the arytenoid cartilage and glottic carcinoma: a clinical-pathological study. *Head Neck.* 2018; 41(1):72-78. <https://doi.org/10.1002/hed.25372>.
19. Benazzo M, Sovardi F, Preda L, et al. Imaging accuracy in preoperative staging of T3-T4 laryngeal cancers. *Cancer.* 2020;125(5):1074. <https://doi.org/10.3390/cancers12051074>.
20. Jaipuria B, Dosemane D, Kamath PM, Sreedharan SS, Shenoy VS. Staging of laryngeal and hypopharyngeal cancer: computed tomography versus histopathology. *Iran J Otorhinolaryngol.* 2018;30(99):189-194.
21. Mattioli F, Fermi M, Molinari G, et al. pT3 N0 laryngeal squamous cell carcinoma: oncologic outcomes and prognostic factors of surgically treated patients. *Laryngoscope.* 2021;131(10):2262-2268. <https://doi.org/10.1002/lary.29528>.
22. Peretti G, Piazza C, Mora F, Garofolo S, Guastini L. Reasonable limits for transoral laser microsurgery in laryngeal cancer. *Curr Opin Otolaryngol Head Neck Surg.* 2016;24(2):135-139. <https://doi.org/10.1097/MOO.0000000000000240>.
23. Adamian N, Naunheim MR, Jowett N. An open-source computer vision tool for automated vocal fold tracking from videoendoscopy. *Laryngoscope.* 2021;131(1):E219-E225. <https://doi.org/10.1002/lary.28669>.