

Polypoidal choroidal vasculopathy invading the optic disc

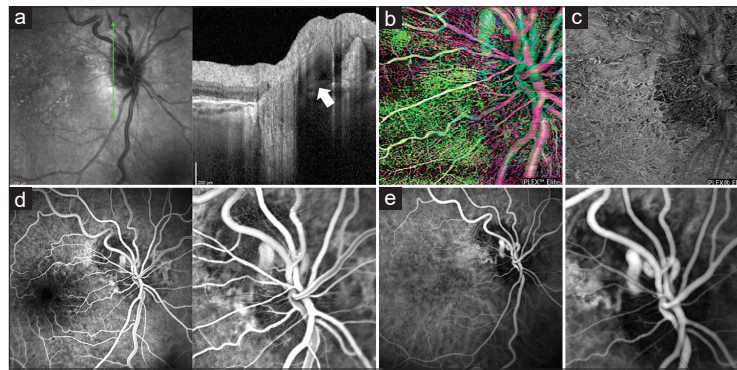


Figure 1: Multimodal imaging of polypoidal choroidal vasculopathy invading the optic disc. Structural cross-sectional optical coherence tomography (OCT) illustrates a subretinal aneurysmal lesion at the temporal edge of the optic disc (a, arrow). Full retinal thickness OCT angiography (b), shows vascular flow and a polypoidal appearance. OCT angiography segmented at the level of the retinal pigment epithelium (c) excluded the coexistence of other evident choroidal neovascularization. Fluorescein angiography (d) and indocyanine green angiography (e) confirms the vascularization of the polypoidal lesion (e)

A 90-year-old lady with advanced age-related macular degeneration showed on structural optical coherence tomography (OCT) of the right eye a subretinal aneurysmal lesion at the temporal edge of the optic disc, not associated with exudation [Fig. 1a]. On full retinal thickness OCT angiography [Fig. 1b], this structure demonstrated vascular flow and a polypoidal appearance. OCT angiography segmented at the level of the retinal pigment epithelium [Fig. 1c] excluded other new vessels, as confirmed by fluorescein angiography [Fig. 1d] and indocyanine green angiography (ICGA; Fig. 1e). ICGA also disclosed a choroidal feeder vessel going through the Bruch's membrane-free optic disc surface.^[1-3]

Financial support and sponsorship

PLEX Elite 9000 have been made available through the Advanced Retina Imaging Network for which Giuseppe Querques is a steering Committee Member.

Conflict of interest

Alessandro Marchese has no disclosures. Giuseppe Querques has the following disclosures: Allergan (S), Alimera (S), Amgen (S), Bayer (S), Khb (S), Novartis (S), Roche (S), Sandoz (S), Zeiss (S); Allergan (C), Alimera (C), Bausch And Lomb (C), Bayer (C), Heidelberg (C), Novartis (C), Zeiss (C). Francesco Bandello has the following disclosures: Allergan (S), Alimera (S), Bayer (S), Farmila-Thea (S), Schering Pharma (S), Sanofi-Aventis (S), Novagali (S), Pharma (S), Hoffmann-lar Roche (S), Genetech (S), Novartis (s).

Declaration of patient consent

The authors certify that they have obtained all appropriate patient consent forms. In the form the patient(s) has/have given his/her/their consent for his/her/their images and other clinical information to be reported in the journal. The patients understand that their names and initials will not be published and due efforts will be made to conceal their identity, but anonymity cannot be guaranteed.

*Alessandro Marchese, Francesco Bandello,
Giuseppe Querques*

Department of Ophthalmology, San Raffaele Scientific Institute,
University Vita-Salute San Raffaele, Milan, Italy

Correspondence to: Dr. Giuseppe Querques,
Department of Ophthalmology, San Raffaele Scientific Institute,
University Vita-Salute San Raffaele, Via Olgettina 60,
Milan 20132, Italy.
E-mail: giuseppe.querques@hotmail.it

References

1. Yannuzzi LA, Sorenson J, Spaide RF, Lipson B. Idiopathic polypoidal choroidal vasculopathy (IPC). *Retina* 1990;10:1-8.
2. Srour M, Querques G, Semoun O, El Ameen A, Miere A, Sikorav A, *et al.* Optical coherence tomography angiography characteristics of polypoidal choroidal vasculopathy. *Br J Ophthalmol* 2016;100:1489-93.
3. Dansingani KK, Gal-Or O, Sadda SR, Yannuzzi LA, Freund KB. Understanding aneurysmal type 1 neovascularization (polypoidal choroidal vasculopathy): A lesson in the taxonomy of 'expanded spectra' – A review. *Clin Exp Ophthalmol* 2018;46:189-200.

This is an open access journal, and articles are distributed under the terms of the Creative Commons Attribution-NonCommercial-ShareAlike 4.0 License, which allows others to remix, tweak, and build upon the work non-commercially, as long as appropriate credit is given and the new creations are licensed under the identical terms.

Access this article online	
Quick Response Code:	Website: www.ijo.in
	DOI: 10.4103/ijo.IJO_937_19

Cite this article as: Marchese A, Bandello F, Querques G. Polypoidal choroidal vasculopathy invading the optic disc. *Indian J Ophthalmol* 2020;68:2532.