



---

# Venous Congestion in Acute Mechanical Intestinal Obstruction: A Computed Tomography Guided Study

**Corresponding Author:**

Dr. Antonio Manenti,  
Associate Professor, University of Modena - Italy

**Submitting Author:**

Dr. Antonio Manenti,  
Associate Professor, Department Surgery - Italy

**Article ID:** WMC003411

**Article Type:** Original Articles

**Submitted on:** 25-May-2012, 09:23:04 AM GMT **Published on:** 26-May-2012, 01:56:41 PM GMT

**Article URL:** [http://www.webmedcentral.com/article\\_view/3411](http://www.webmedcentral.com/article_view/3411)

**Subject Categories:** SURGERY

**Keywords:** Intestinal Occlusion, Mesenteric Circulation, Computed Tomography

**How to cite the article:** Manenti A , Amorico M, Manco G, Vezzelli E, Donatiello S. Venous Congestion in Acute Mechanical Intestinal Obstruction: A Computed Tomography Guided Study . WebmedCentral SURGERY 2012;3(5):WMC003411

**Copyright:** This is an open-access article distributed under the terms of the [Creative Commons Attribution License](#), which permits unrestricted use, distribution, and reproduction in any medium, provided the original author and source are credited.

**Source(s) of Funding:**

None

**Competing Interests:**

None

# Venous Congestion in Acute Mechanical Intestinal Obstruction: A Computed Tomography Guided Study

**Author(s):** Manenti A , Amorico M, Manco G, Vezzelli E, Donatiello S

## Abstract

Intestinal mechanical obstruction is often joined with a diffuse venous congestion. Computed Tomography (CT) is helpful in demonstrating this condition, important from a general-clinical, diagnostic and therapeutic point of view.

## Introduction

The important role of imaging techniques in the diagnosis of mechanical intestinal obstruction is universally accepted. TC is considered one of the most important mean, often permitting to detect type and site of the occlusion of small bowels and colon (1-9). The modern methods of multidetector row CT, with intravenous contrast enhancement and the possibility of coronal and sagittal formatted reconstruction, allow to accurately study the vascular pathology of the mesentery and of the intestinal loops. Some aspects of a secondary vascular pathology have been just described, as diagnostic of intestinal mechanical obstruction: mucosal hyperenhancement, edematous thickening of the intestinal wall, central crowding and "whirling" of the mesenteric vessels in case strangulation or volvulus of an intestinal loop (10). Here we underline the importance of diffuse mesenteric venous congestion, that confirm the clinico-radiological diagnosis of mechanical obstruction, influence the general haemodynamics, and address towards the choice of an adequate therapy.

## Methods

We have re-examined 30 cases of intestinal mechanical obstruction: 20 cases interesting the small bowel and the colon, secondary to malignant colonic neoplasms, and 10 of small bowel occlusion, due to peritoneal adhesions or fibrous bands. No case of peritoneal carcinomatosis or intestinal volvulus was considered. A concomitant hepatic pathology could be excluded in all the cases and the clinico-radiological diagnosis was always confirmed at the subsequent

laparotomy. This series was compared with other 10 cases of paralytic ileus, secondary to a localized peritonitis or to a retroperitoneal pathology.

## Results

Reevaluating our cases, we confirmed the value of the aforementioned classical radiological signs of intestinal mechanical occlusion, but particular attention was given to the following, not always adequately considered:

- dilatation and engorgement of the peripheral mesenteric vessels (Illustrations 1,2);
- dilatation of the major affluents to the porto-mesenteric trunk and to the inferior mesenteric vein (Illustrations 3,4).

The CT contrast-enhanced study permitted us to clearly identify the dilated venous network: mesenteric venous dilatation was evident in 17 (80.5%) cases of concomitant ileal and colonic obstruction, and in 7 (70.0%) of simple small bowel occlusion. No case of thrombosis of mesenteric vessels was observed. On the contrary, no evident vascular pathology was present in any case of paralytic ileus.

## Discussion

Vascular mesenteric congestion must be considered not an early but an important radiological sign, demonstrating a haemodynamic complication of the intestinal occlusion. The splanchnic venous congestion influences the general hemodynamic balance, with the mechanism of the "third-space" fluid loss. In this condition, an eventual laparotomy, followed by a sudden abdominal decompression, can induce a further brisk sequestration of blood in the mesenteric system, with negative influence on the systemic circulation. The sequence: intestinal bowels dilatation with contractile hyperactivity, augmented metabolic requests, increased arterial supply and venous congestion, appears logic. Congestion of the mesenteric veins appears the final morphological result of this vascular pathological sequence; it must be considered an important, but not an early sign of

mechanical intestinal occlusion (Illustration 5). These considerations are based only on morphological data, but, necessarily, not on direct hemodynamic measures, too difficult to be performed in case of "acute abdomen".

## Conclusion(s)

Vascular mesenteric congestion must be considered not an early but an important radiological sign, demonstrating a haemodynamic complication of the intestinal occlusion. The splanchnic venous congestion influences the general hemodynamic balance, with the mechanism of the "third-space" fluid loss. In this condition, an eventual laparotomy, followed by a sudden abdominal decompression, can induce a further brisk sequestration of blood in the mesenteric system, with negative influence on the systemic circulation. The sequence: intestinal bowels dilatation with contractile hyperactivity, augmented metabolic requests, increased arterial supply and venous congestion, appears logic. Congestion of the mesenteric veins appears the final morphological result of this vascular pathological sequence; it must be considered an important, but not an early sign of mechanical intestinal occlusion (Illustration 5). These considerations are based only on morphological data, but, necessarily, not on direct hemodynamic measures, too difficult to be performed in case of "acute abdomen". Mesenteric venous congestion is a consequence of the mechanical intestinal occlusion; it can be clearly demonstrated by CT and directly correlated to the severity of this condition. An equivalent situation, but limited to a segment of mesentery and interesting only a few ileal loops, can give evidence of "closed loop obstruction" or of "strangulated bowel". Our aim has been to recall attention to the CT signs of diffuse mesenteric congestion, following the condition of intestinal mechanical obstruction, and to its general consequences. According to these considerations, in case of colonic obstruction, surgeon can preferentially proceed, as first step, to a simple diverting colostomy or intraluminal stenting, rather than to a direct laparotomy (11). Besides, it must be underlined, once again, the diagnostic value of contrast enhanced CT, that gives precise morpho-functional information about the entire splanchnic circulation, with subsequent useful clinical correlations.

## Reference(s)

Vascular mesenteric congestion must be considered not an early but an important radiological sign, demonstrating a haemodynamic complication of the intestinal occlusion. The splanchnic venous congestion influences the general hemodynamic balance, with the mechanism of the "third-space" fluid loss. In this condition, an eventual laparotomy, followed by a sudden abdominal decompression, can induce a further brisk sequestration of blood in the mesenteric system, with negative influence on the systemic circulation. The sequence: intestinal bowels dilatation with contractile hyperactivity, augmented metabolic requests, increased arterial supply and venous congestion, appears logic. Congestion of the mesenteric veins appears the final morphological result of this vascular pathological sequence; it must be considered an important, but not an early sign of mechanical intestinal occlusion (Illustration 5). These considerations are based only on morphological data, but, necessarily, not on direct hemodynamic measures, too difficult to be performed in case of "acute abdomen". Mesenteric venous congestion is a consequence of the mechanical intestinal occlusion; it can be clearly demonstrated by CT and directly correlated to the severity of this condition. An equivalent situation, but limited to a segment of mesentery and interesting only a few ileal loops, can give evidence of "closed loop obstruction" or of "strangulated bowel". Our aim has been to recall attention to the CT signs of diffuse mesenteric congestion, following the condition of intestinal mechanical obstruction, and to its general consequences. According to these considerations, in case of colonic obstruction, surgeon can preferentially proceed, as first step, to a simple diverting colostomy or intraluminal stenting, rather than to a direct laparotomy (11). Besides, it must be underlined, once again, the diagnostic value of contrast enhanced CT, that gives precise morpho-functional information about the entire splanchnic circulation, with subsequent

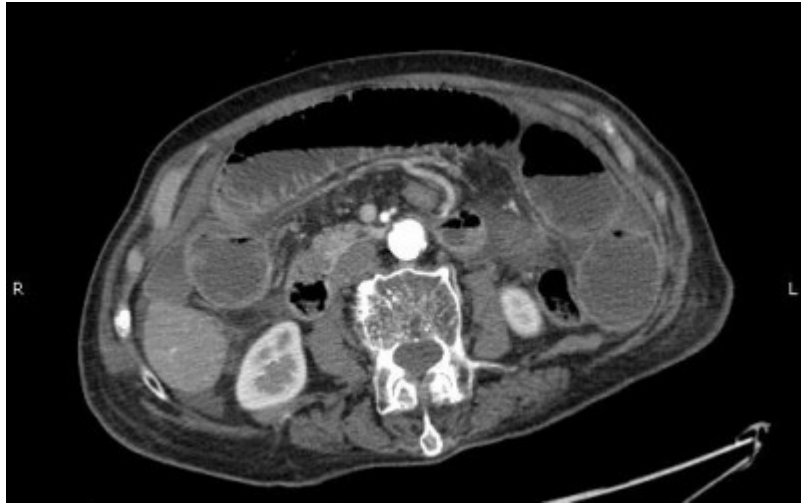- Galbani A., Paushter D., Dachman A.H. Multidetector row CT of small bowel obstruction. *Radiol.Clin:North Am.* 2007;45:499-512.
- Maglinte D.D., Heitkamp D.E., Howard T.J. et al. Current concepts in imaging of small bowel obstruction. *Radiol.Clin.North Am.* 2003;41:263-283.
- Furukawa A., Yamasaki M., Furuichi K. et al. Helical CT in the diagnosis of small bowel obstruction. *Radiographics* 2001;21:341-355.
- Hwang J., Lee J.K., Lee J.E., Baek S.Y. Value of multidetector CT in decision making regarding surgery in patients with small bowel obstruction due to adhesion. *Eur.Radiol.* 2009;19:2425-2431
- Maglinte D.D.T., Kelvin F.M., Sandrasegaran K.A. et

- al. Radiology of small bowel obstruction: contemporary approach and controversies. *Abdom. Imaging* 2005;30:160-178.
5. Desser T.S., Gross M. Multidetector row Computed Tomography of small bowel obstruction. *Semin. Ultrasound CT MRI* 2008; 29: 308-321.
6. Qalbani A., Paushter, Dauchman A.H. Multidetector row CT of small bowel obstruction. *Radiol. Clin. North Am.* 2007;45: 499-412.
7. Shina R., Verma R. Multidetector row computed tomography in bowel obstruction. Part 10. Large bowel obstruction. *Clin. Radiol.* 2005;60:1068-1075.
8. Taourel P., Kessler N., Lesnik A. et al. Helical CT of large bowel obstruction. *Abdom. Imaging* 2003; 28:267-275.
9. Mallo R.D., Salem L., Lalani T. et al. Computed Tomography diagnosis of ischemia and complete obstruction in small bowel obstruction: a systematic review. *J. Gastroint. Surg.* 2005;9:60-694.
10. Sjo O.H., Larsen S., Lunde O.C., Nesbakken A. Short term outcome after emergency and elective surgery for colon cancer. *Colorectal Dis.* 2009;11:733-739. *seful clinical correlations.*

## Illustrations

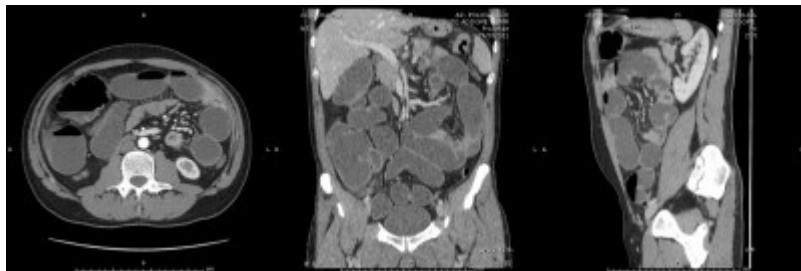### Illustration 1

Ileal occlusion due to fibrous band. A dilated loop with corresponding congested venous branches.



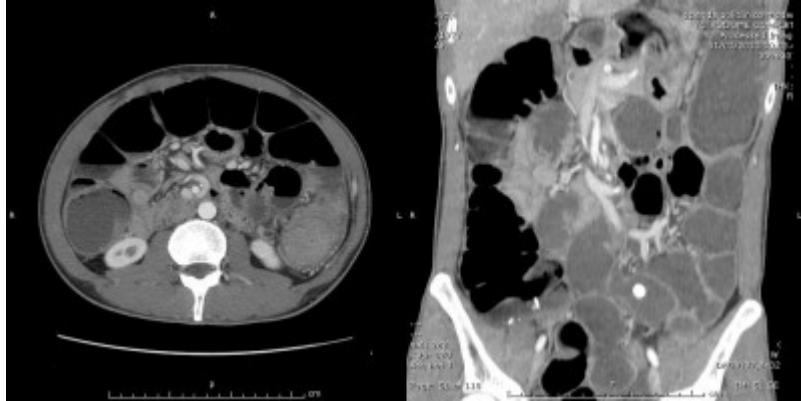
### Illustration 2

Ileo-colon occlusion secondary to a sigmoid cancer. Congestion of the jejunal venous mesenteric branches.



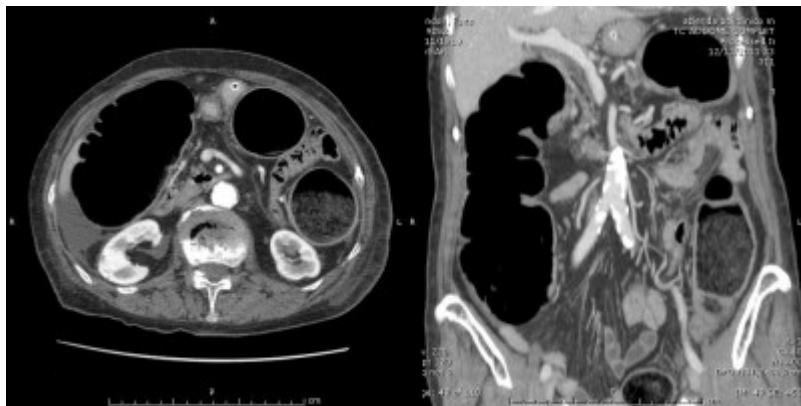
### Illustration 3

Ileo-colon occlusion secondary to a cancer of the left flexure. Dilatation in the jejuno-ileal venous mesenteric branches, with concomitant arterial hyper-enhancement of the walls of the distal transverse colon.



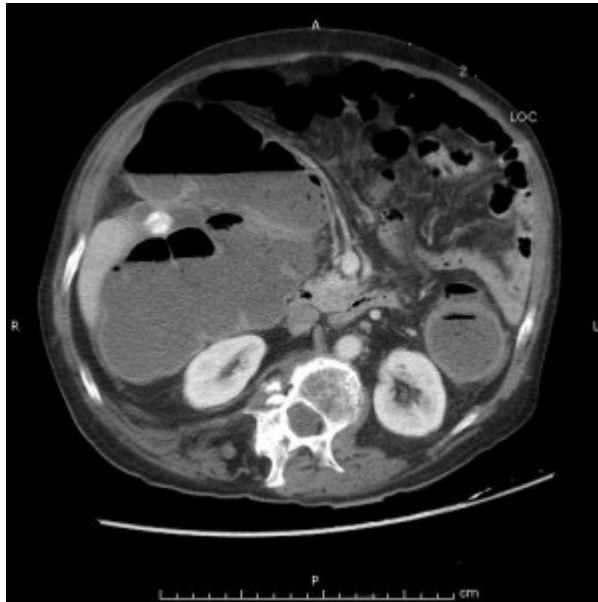### Illustration 4

Colon obstruction secondary to sigmoid cancer. Evident venous congestion of the veins of the left colon flexure.



## Illustration 5

Colon obstruction secondary to sigmoid cancer. Vascular arterial hyperenhancement and venous congestion of the dilated right colon.



## Disclaimer

This article has been downloaded from WebmedCentral. With our unique author driven post publication peer review, contents posted on this web portal do not undergo any prepublication peer or editorial review. It is completely the responsibility of the authors to ensure not only scientific and ethical standards of the manuscript but also its grammatical accuracy. Authors must ensure that they obtain all the necessary permissions before submitting any information that requires obtaining a consent or approval from a third party. Authors should also ensure not to submit any information which they do not have the copyright of or of which they have transferred the copyrights to a third party.

Contents on WebmedCentral are purely for biomedical researchers and scientists. They are not meant to cater to the needs of an individual patient. The web portal or any content(s) therein is neither designed to support, nor replace, the relationship that exists between a patient/site visitor and his/her physician. Your use of the WebmedCentral site and its contents is entirely at your own risk. We do not take any responsibility for any harm that you may suffer or inflict on a third person by following the contents of this website.