

Received: 2017.12.16  
Accepted: 2018.02.13  
Published: 2018.06.25

# Pulmonary Fat Embolism and Coronary Amyloidosis

Authors' Contribution:  
Study Design A  
Data Collection B  
Statistical Analysis C  
Data Interpretation D  
Manuscript Preparation E  
Literature Search F  
Funds Collection G

BEF 1 **Veronica Lever**  
AB 1 **Francesco Erdini**  
AB 1 **Claudio Ghimenton**  
AB 2 **Luca Novelli**  
AB 1 **Matteo Brunelli**  
AB 3 **Mattia Barbareschi**  
ABD 4 **Guido Mazzoleni**  
C 5 **Elisa Vermiglio**  
CD 6 **Alessandro Mantovani**  
E 1 **Luca Cima**  
BEF 1 **Giovanni Valotto**  
AEG 1 **Albino Eccher**

1 Pathology Unit, Department of Diagnostics and Public Health, University and Hospital Trust of Verona, Verona, Italy  
2 Pathology Unit, Careggi University Hospital, Firenze, Italy  
3 Pathology Unit, Santa Chiara Hospital, Trento, Italy  
4 Pathology Unit, San Maurizio Hospital, Bolzano, Italy  
5 Forensic Pathology Unit, Department of Diagnostics and Public Health, University and Hospital Trust of Verona, Verona, Italy  
6 Division of Endocrinology, University and Hospital Trust of Verona, Verona, Italy

**Corresponding Author:** Giovanni Valotto, e-mail: [giovanni.valotto@me.com](mailto:giovanni.valotto@me.com)  
**Conflict of interest:** None declared  
**Source of support:** Funding for this work was provided by internal University Funds for Research (FUR MB)

**Patient:** **Male, 72**  
**Final Diagnosis:** **Fat lung embolism**  
**Symptoms:** **Dyspnea**  
**Medication:** —  
**Clinical Procedure:** —  
**Specialty:** **Orthopedics and Traumatology**

**Objective:** **Diagnostic/therapeutic accidents**

**Background:** Fat embolism syndrome is a well-known complication in orthopedic and trauma surgery, caused by a massive release of fat into the circulation that can lead to cardiopulmonary insufficiency and multiorgan failure.

**Case Report:** We present the case of a 72-year-old man with osteoarthritis who underwent an elective right cementless total hip arthroplasty. Two hours after surgery, the patient lost consciousness and was found hypotensive and with reduced oxygen saturation, with a severe right heart dilatation at echocardiographic evaluation. Death occurred after cardiopulmonary resuscitation attempts. Post-mortem microscopic examination revealed that the final cause of death was pulmonary fat embolism associated with coronary amyloidosis and atherosclerosis.

**Conclusions:** This case called our attention on the sudden onset of fat embolism syndrome after arthroplasty and the insidious nature of amyloidosis infiltrative disease. The autopsy findings substantially aided understanding the immediate cause of death.

**MeSH Keywords:** **Amyloidosis • Embolism, Fat • Orthopedics • Pulmonary Embolism**

**Full-text PDF:** <https://www.amjcaserep.com/abstract/index/idArt/908561>

 1088  1  1  21



## Background

Fat embolism syndrome (FES), a well-known complication of orthopedic and trauma surgery [1–4], describes a characteristic and clinically recognizable systemic reaction following a massive release of fat into the circulation that can lead to cardiorespiratory insufficiency and multiorgan failure. The traditional triad of FES, which can be subclassified as subclinical, non-fulminant, and fulminant [5], consists of respiratory failure, altered mental status, and skin petechiae [6,7]. Gurd and Wilson and, later on, Schonfeld, proposed a series of criteria to help the clinician recognize FES [8,9]. The high incidence of fat embolization during cemented arthroplasty is consistent with a substantial increase of intramedullary pressures after cement pressurization, forcing fat and bone marrow into the circulation. However, several cases of FES have been reported following cementless arthroplasty [2,10–12]. The incidence rate seems to be less than 1% in retrospective reviews, while it ranges from 10% to 30% in prospective studies [13,14]. The incidence rate of fat embolism at post-mortem appears to be as high as 20%, exceeding by several times the clinically suspected rate. This disparity has given rise to the concept of an “iceberg effect”, confirmed by the use of transesophageal echocardiography, suggesting a very high incidence of fat embolism during orthopedic surgery, even though the symptomatic forms remains relatively rare [13,15]. Mortality rates in the 1970s ranged from 10% to 20%, whereas more recent studies report mortality rates of 10% or less, mainly because of earlier diagnosis and advances in supportive care [16]. However, there is still little information regarding the occurrence of the fulminant FES in orthopedic surgery, especially in patients with no apparent cardiovascular risk factors. We believe that this topic is clinically relevant, and that greater effort should be made in recognizing this serious and fatal condition in order to improve the survival in these patients.

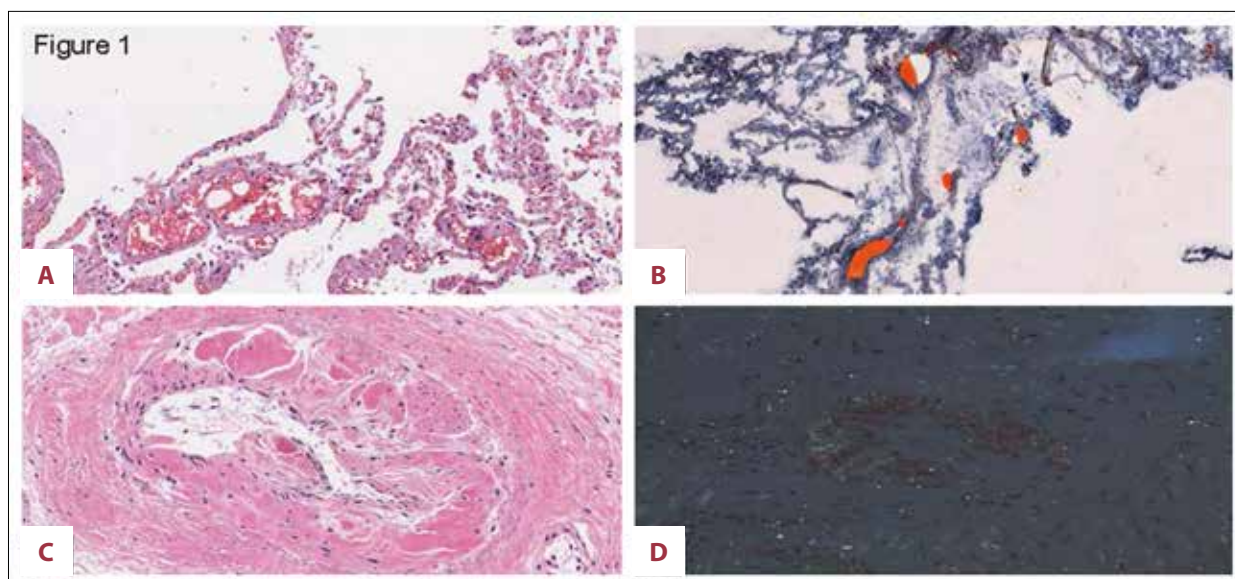
## Case Report

We present the case of a 72-year-old man with osteoarthritis who underwent an elective right cementless total hip arthroplasty. His past medical history included mild emphysema and hypertension. Preoperative evaluation was consistent with an American Society of Anesthesiologists (ASA) score of II, of the complementary evaluation, only a right bundle branch block. Preoperative chest X-ray findings were unremarkable. The patient was put under general anaesthesia. The intra-operative course was uncomplicated. Two hours after the intervention, the patient lost consciousness and was found to be hypotensive, with reduced oxygen saturation. Urgent echocardiographic evaluation demonstrated a severe right heart dilatation. The patient died after numerous resuscitation attempts.

Post-mortem examination revealed a severe cardiomegaly (with a cardiac mass of 640 g) as well as the presence of substenotic coronary vascular lumina with multifocal areas of mild to severe atherosclerosis. Cardiac valves were unremarkable. The abdominal aorta showed a localized dilatation, consistent with chronic aneurysm. The pulmonary arteries and major bronchi were unremarkable. The lungs were slightly edematous and congested. Brain examination findings were unremarkable. Microscopic examination of the lungs showed red blood cells marginalization and optically empty vacuolation within capillaries and arterioles (Figure 1A). Sudan III staining confirmed the presence of fat emboli, appearing as orange intravascular globules (Figure 1B). Microscopic examination of the heart revealed thickened wall of intramyocardial arterioles with subsequent bulging in the lumen (Figure 1C). Congo red staining and typical apple-green birefringence under polarized light confirmed the presence of amyloid deposits within the vessel wall (Figure 1D). Amyloid deposits consisted of TTR (transthyretin) protein. There was no sign of amyloid deposits within the myocardium or in other organs evaluated. The final cause of death was pulmonary fat embolism associated with vascular heart amyloidosis and coronary atherosclerosis.

## Discussion

Although FES is relatively rare, it is a potentially life-threatening condition and its diagnosis should be considered in all patients with a postoperative change in respiratory or neurologic status after either cemented or cementless arthroplasty. FES cannot always be accurately diagnosed on clinical grounds only, because of elusive symptoms in milder forms and sudden onset with fulminant clinical course in the most severe ones. Lack of universal criteria for diagnosis and limited studies can also make the post-mortem diagnosis difficult to ascertain [17]. A widely used histological classification (introduced by Falzi and modified by Janssen) provides a four-grade scoring system for pulmonary fat embolism (Table 1). Falzi-grade III can usually be stated as a direct cause of death without concomitant factors; however, it is also accepted that less pronounced fat embolism can lead to acute right heart failure in patients with pre-existing cardiac disease [17]. Engorgement of lung microcirculation by fat globules results in increased pulmonary vascular resistance, which in turn causes an increased workload of the right heart. If there is previous heart damage (such as that caused by an infiltrative disease), the ability to overcome this resistance is compromised and heart failure is more likely to occur, even in case of minor embolism. In the case described above, the fatal outcome was due to a moderate fat pulmonary embolism (grade II sec. Falzi) and to cardiac vascular disease, which strongly contributed to making the heart incapable of supporting the sudden increase in vascular resistance due to the fat embolism. Particularly, heart involvement



**Figure 1.** (A) Hematoxylin and eosin (H&E) stain at 25× magnification: marginalization of the erythrocytes associated with an optically empty vacuolation within lung vessels. (B) Sudan III stain at 25× magnification: frozen lung tissue with fat emboli that appear as orange intravascular globules. (C) H&E stain at 25× magnification: myocardial arterioles with thickened walls and amorphous deposits. (D) Congo Red stain at 10× magnification: amorphous pink deposits at light microscopy showing apple-green birefringence under polarized microscopy, consistent with amyloidosis.

**Table 1.** Grading of pulmonary fat embolism (PFE) sec. Falzi.

Grade	Emboli shape	Emboli frequency*
I – light PFE	Drop	Sporadic
II – moderate PFE	Sausage	Multiple, disseminated
III – massive PFE	Antler	Numerous, everywhere
0 – no PFE		Very rare

\* Per field of view at 25× magnification.

by amyloid deposition is a common feature of systemic amyloidosis, but can also occur as a localized phenomenon [18], and involvement of the intramyocardial vessels has been associated with clinically significant cardiac disease [19]. However, because of its rarity, its insidious onset, and the vague nature of symptoms, cardiac amyloidosis is hard to recognize and the diagnosis may not be made in a patient undergoing anaesthesia and surgery for an apparently straightforward problem. It is important to point out that, in the presence of cardiac amyloidosis, several unexpected complications (including heart failure) may arise, either before the operation or in the

postoperative period, especially if a surgical complication (such as the fat embolism in our patient) occurs [20]. A variety of diagnostic modalities (e.g., endomyocardial biopsy, echocardiography, electrocardiography (ECG), cardiovascular magnetic resonance imaging, radionuclide imaging) are available, but no single test is sufficient by itself; hence, early and accurate diagnosis remains difficult [21]. ECG findings associated with amyloidosis include low-voltage QRS complexes, conduction defects, and pseudoinfarction patterns. Despite the presence of right bundle branch block on the ECGs of our patient, given the absence of other symptoms, preoperative cardiovascular risk was impossible to accurately assess with the standard preoperative evaluation.

## Conclusions

Severe complications of pulmonary fat embolism depend on multiple risk factors, and comorbidities may play a paramount role in the overall clinical picture. Greater effort should be made to identify in advance any relevant, although insidious, preoperative risk factor such as amyloidosis.

## References:

- de Froidmont S, Bonetti LR, Villaverde RV et al: Postmortem findings in bone cement implantation syndrome-related deaths. *Am J Forensic Med Pathol*, 2014; 35(3): 206–11
- Arroyo JS, Garvin KL, McGuire MH: Fatal marrow embolization following a porous-coated bipolar hip endoprosthesis. *J Arthroplasty*, 1994; 9(4): 449–52
- Koessler MJ, Pitto RP: Fat and bone marrow embolism in total hip arthroplasty. *Acta Orthop Belg*, 2001; 67(2): 97–109
- Fallon KM, Fuller JG, Morley-Forster P: Fat embolization and fatal cardiac arrest during hip arthroplasty with methylmethacrylate. *Can J Anaesth*, 2001; 48(7): 626–29

5. Sevitt S: The significance and classification of fat embolism. *Lancet* (London, England), 1960; 2(7155): 825–28
6. Akhtar S: Fat embolism. *Anesthesiol Clin*, 2009; 27(3): 533–50
7. Hofmann S, Huemer G, Salzer M: Pathophysiology and management of the fat embolism syndrome. *Anaesthesia*, 1998; 53(Suppl .2): 35–37
8. Gurd AR, Wilson RI: The fat embolism syndrome. *J Bone Joint Surg Br*, 1974; 56B(3): 408–16
9. Schonfeld SA, Ploysongsang Y, DiLisio R et al: Fat embolism prophylaxis with corticosteroids. A prospective study in high-risk patients. *Ann Intern Med*, 1983; 99(4): 438–43
10. Gelinas JJ, Cherry R, MacDonald SJ: Fat embolism syndrome after cementless total hip arthroplasty. *J Arthroplasty*, 2000; 15(6): 809–13
11. Kim Y-H, Kook H-K, Kim J-S: Total hip replacement with a cementless acetabular component and a cemented femoral component in patients younger than fifty years of age. *J Bone Joint Surg Am*, 2002; 84-A(5): 770–74
12. Orsini EC, Byrick RJ, Mullen JB et al: Cardiopulmonary function and pulmonary microemboli during arthroplasty using cemented or non-cemented components. The role of intramedullary pressure. *J Bone Joint Surg Am*, 1987; 69(6): 822–32
13. Mellor A, Soni N: Fat embolism. *Anaesthesia*, 2001; 56(2): 145–54
14. Taviloglu K, Yanar H: Fat embolism syndrome. *Surg Today*, 2007; 37(1): 5–8
15. Georgopoulos D, Bouros D: Fat embolism syndrome: Clinical examination is still the preferable diagnostic method. *Chest*, 2003; 123(4): 982–83
16. Talbot M, Schemitsch EH: Fat embolism syndrome: History, definition, epidemiology. *Injury*, 2006; 37(4): S3–S7
17. Miller P, Prahlow JA: Autopsy diagnosis of fat embolism syndrome. *Am J Forensic Med Pathol*, 2011; 32(3): 291–99
18. Selvanayagam JB, Hawkins PN, Paul B et al: Evaluation and management of the cardiac amyloidosis. *J Am Coll Cardiol*, 2007; 50(22): 2101–10
19. Smith TJ, Kyle RA, Lie JT: Clinical significance of histopathologic patterns of cardiac amyloidosis. *Mayo Clin Proc*, 1984; 59(8): 547–55
20. Wani Z, Harkawat D, Sharma M: Amyloidosis and anesthesia. *Anesth Essays Res*, 2017; 11(1): 233–37
21. Desai H V, Aronow WS, Peterson SJ, Frishman WH: Cardiac amyloidosis approaches to diagnosis and management. *Cardiol Rev*, 2010; 18: 1–11