


















CLINICAL COMMENTARY

Neurocysticercosis and epilepsy: Imaging and clinical characteristics

Ildelfonso Rodríguez-Leyva¹  | Karla Cantú-Flores¹  | Arturo Domínguez-Frausto²  |
 Anna Elisabetta Vaudano³  | John Archer^{4,5,6,7}  | Boris Bernhardt⁸  |
 Lorenzo Caciagli^{9,10}  | Fernando Cendes¹¹  | Yotin Chinvarun¹²  | Paolo Federico¹³  |
 William D. Gaillard¹⁴  | Eliane Kobayashi^{15,16}  | Godwin Ogbale¹⁷  |
 Stefan Rampp^{18,19}  | Irene Wang²⁰  | Shuang Wang²¹  | Luis Concha² 

¹School of Medicine, Universidad Autónoma de San Luis Potosí, San Luis Potosí, Mexico

²Institute of Neurobiology, Universidad Nacional Autónoma de México, Querétaro, Mexico

³Neurology Unit, Department of Biomedical, Metabolic and Neural Sciences, University of Modena and Reggio Emilia, Modena, Italy

⁴Department of Medicine (Austin Health), University of Melbourne, Heidelberg, Victoria, Australia

⁵Murdoch Children's Research Institute, Parkville, Victoria, Australia

⁶Florey Institute of Neuroscience and Mental Health, Heidelberg, Victoria, Australia

⁷Department of Neurology, Austin Health, Heidelberg, Victoria, Australia

⁸Multimodal Imaging and Connectome Analysis Lab, McConnell Brain Imaging Centre and Montreal Neurological Institute, McGill University, Montreal, Canada

⁹Department of Bioengineering, University of Pennsylvania, Philadelphia, Pennsylvania, USA

¹⁰Department of Clinical and Experimental Epilepsy, UCL Queen Square Institute of Neurology, London, UK

¹¹Department of Neurology, University of Campinas – UNICAMP, Campinas, Brazil

¹²Phramongkutklao Hospital, Bangkok, Thailand

¹³Hotchkiss Brain Institute, Cumming School of Medicine, University of Calgary, Calgary, Alberta, Canada

¹⁴Children's National Hospital, Washington, District of Columbia, USA

¹⁵Montreal Neurological Institute and Hospital, Montreal, Quebec, Canada

¹⁶Neurology and Neurosurgery Department, McGill University, Montreal, Québec, Canada

¹⁷Department of Radiology, University College Hospital/College of Medicine, University of Ibadan, Ibadan, Nigeria

¹⁸Department of Neurosurgery, University Hospital Erlangen, Erlangen, Germany

¹⁹Department of Neurosurgery, University Hospital Halle (Saale), Halle (Saale), Germany

²⁰Epilepsy Center, Neurological Institute, Cleveland Clinic, Cleveland, Ohio, USA

²¹Department of Neurology, Second Affiliated Hospital, School of Medicine, Zhejiang University, Hangzhou, China

Correspondence

Luis Concha, Instituto de Neurobiología; UNAM, Campus Juriquilla. Blvd. Juriquilla 3001; Juriquilla, Querétaro, 76230, Mexico.
Email: lconcha@unam.mx

Abstract

The ILAE Neuroimaging Task Force aimed to publish educational case reports highlighting basic aspects related to neuroimaging in epilepsy consistent with the educational mission of the ILAE. Neurocysticercosis (NCC) is highly endemic in resource-limited countries and increasingly more often seen in non-endemic regions due to migration. Cysts with larva of the tapeworm *Taenia solium* lodge in

This is an open access article under the terms of the [Creative Commons Attribution-NonCommercial](https://creativecommons.org/licenses/by-nc/4.0/) License, which permits use, distribution and reproduction in any medium, provided the original work is properly cited and is not used for commercial purposes.

© 2023 The Authors. *Epileptic Disorders* published by Wiley Periodicals LLC on behalf of International League Against Epilepsy.

the brain and cause several neurological conditions, of which seizures are the most common. There is great heterogeneity in the clinical presentation of neurocysticercosis because cysts vary in number, larval stage, and location among patients. We here present two illustrative cases with different clinical features to highlight the varying severity of symptoms secondary to this parasitic infestation. We also present several examples of imaging characteristics of the disease at various stages, which emphasize the central role of neuroimaging in the diagnosis of neurocysticercosis.

KEYWORDS

CT, epilepsy, MRI, neurocysticercosis, neuroimaging

1 | INTRODUCTION

Neurocysticercosis (NCC) is a parasitic neurologic disease caused by the encysted larva of the tapeworm *Taenia solium*. It is the most common parasitic disease affecting the human central nervous system (CNS) in the world¹ and significantly contributes to the global burden of epilepsy.² There is a great disparity in the geographical distribution of NCC. Historically, NCC has remained relatively rare in resource-rich countries,³ but is rather a common cause of acquired epilepsy in endemic areas of Latin America, Asia, and Africa. Healthcare professionals in industrialized nations with a high rate of immigration from endemic areas should be aware of the disease.^{1,4,5} In Latin America, there are an estimated 75 million people at risk for NCC, 400 000 of whom present neurological symptoms.⁶ NCC is, therefore, clearly a public health challenge globally¹ with symptomatic patients representing only the tip of the iceberg.⁷

Neurocysticercosis encompasses a variety of clinical presentations, depending on the number, location, size, evolutionary stage of lesions, and the host's inflammatory response. Despite great heterogeneity in clinical presentation, seizures occur in up to 90% of patients with NCC.⁸ Consequently, imaging plays a crucial role in the diagnosis, staging, and prognosis of NCC. The main objectives here are to present illustrative cases and neuroimaging vignettes of patients with epilepsy secondary to NCC and to provide a concise summary of its pathophysiology, clinical presentations, diagnostic approach, and staging of lesions by neuroimaging.

2 | CASE 1

A 51-year-old woman was admitted to the emergency department after suffering a bilateral tonic-clonic seizure, followed by post-ictal confusion. She had been diagnosed with abdominal lymphoma (not specified) 3 months before this event, and she had finished her first chemotherapy cycle 3 days earlier, which caused nausea, vomiting,

and progressive weight loss. Prior to that, her medical history was relatively unremarkable, with no previous history of seizures. At the time of admission, she was conscious and oriented. Physical examination was mostly normal, revealing only a Babinski sign on the right side. Laboratory results showed hyperglycemia, hyponatremia, and hypokalemia. The remainder of the laboratory tests were within the reference ranges, including a complete blood count, basic metabolic panel, coagulation parameters, and liver function test. X-ray computed tomography (CT) was performed, which revealed findings indicative of different stages of neurocysticercosis (Figure 1). The patient was treated with albendazole and prednisone, and hydrocephalus was managed with the implantation of a ventriculoperitoneal shunt. There was a favorable evolution with the combination of pharmacological and surgical treatments.

3 | CASE 2

A 33-year-old man was admitted to the emergency department due to status epilepticus, with focal to bilateral tonic-clonic seizures lasting more than 40 min. He had two prior hospitalizations for status epilepticus in the last 2 years. He had been diagnosed with epilepsy during childhood, with focal motor seizures with impaired awareness, left ocular version, left arm clonus, progressing to bilateral tonic-clonic convulsions. Relatives reported that seizures were preceded by agitation and speech disturbance, referred to as the patient being “unable to pronounce words correctly, and suddenly he starts running.” A month and a half earlier, he suffered a mild traumatic brain injury after a bicycle accident secondary to a seizure. Neurologic examination revealed symmetric miotic pupils, preserved cough, oculocephalic, corneal, and pupillary light reflexes. CT revealed a granulomatous lesion with a calcified scolex in the mesial temporal lobe (Figure 2). Treatment for status epilepticus included phenytoin load and sedation with midazolam and propofol,

FIGURE 1 Cranial CT shows various stages of NCC. A scolex is visible as a small hyperdensity within a large cyst next to the dilated right temporal horn of the lateral ventricle (inset). Colloidal-vesicular NCC with perilesional edema (curved arrows) and calcified granulomatous lesions (straight arrows) are seen in the parieto-occipital region and right frontal lobe. Sulcal effacement is consistent with raised intracranial pressure.

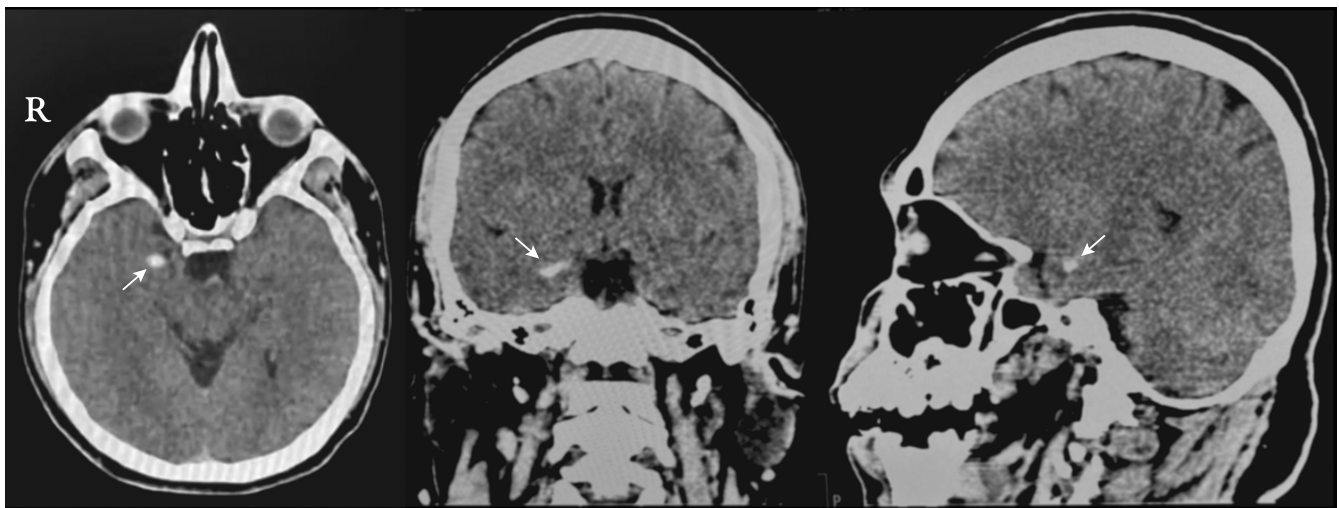
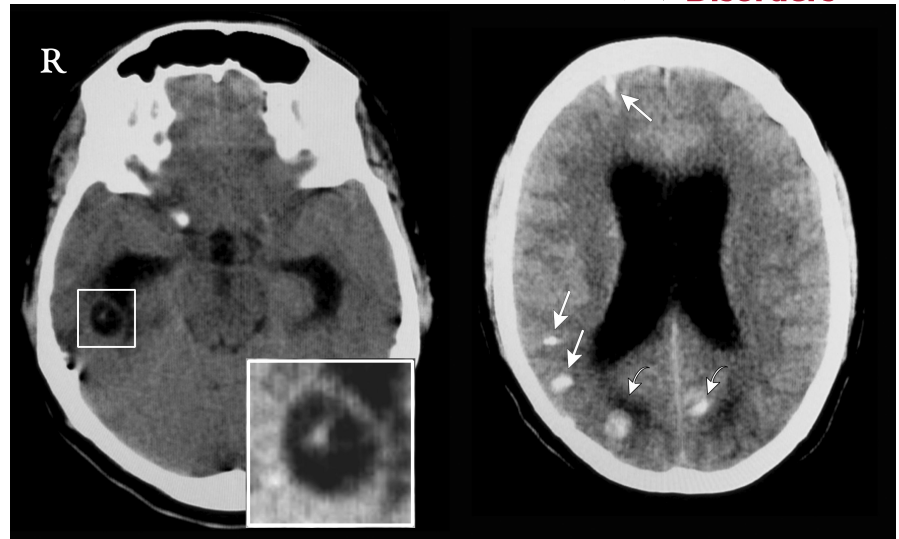


FIGURE 2 CT without contrast displays parenchymal cysticercosis with a calcified granuloma in the right mesial temporal region (arrows in axial, coronal, and sagittal views).

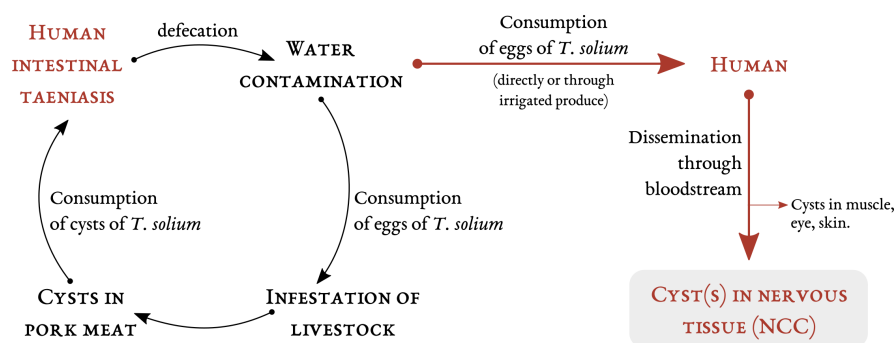


FIGURE 3 Lifecycle of the parasite. A cycle of human intestinal taeniasis and cyst formation in pigs sustained by contamination of water with human feces and the consumption of pork meat. Human consumption of eggs of *T. solium* occurs through contaminated water, or its use to irrigate produce intended for raw consumption. Embryos of the tapeworm break through the intestinal mucosa and enter the bloodstream and reach skeletal muscle, eye, skin, or nervous tissue, where they evolve into cysts.

vasopressor support with norepinephrine, and ventilatory assistance in volume-controlled mode. After successful control of seizures, sedatives and phenytoin were tapered. Anti-seizure medication treatment continued with levetiracetam and magnesium valproate with excellent long-term control of seizures.

4 | LIFE CYCLE OF THE PARASITE

The life cycle of *Taenia solium* has three phases: egg, larvae, and adult (Figure 3).¹ It holds a two-host life cycle between humans and pigs; both serve as intermediate hosts for the larval form, yet humans are the only definitive host for the adult tapeworm.⁹ *T. solium* forms cystic, fluid-filled membranous vesicles with the tapeworm's head (scolex) inside that lodge in skeletal muscle and CNS. When humans consume contaminated pork, the scolex unsheathes, adheres to the intestinal wall, and matures into a 2–4 m long ribbon-like tapeworm.¹⁰ Gravid proglottids and small fertile eggs that contain an infective embryo (oncosphere) are released into feces.¹¹ Unsanitary conditions lead to contaminated water and livestock feed, reinforcing the cycle in pigs, where embryos break through their intestinal mucosa to their bloodstream, evolving into cysticerci in muscle and CNS.¹² It is important to note that the route through which cysts can lodge into the human CNS is hematogenic after ingestion of produce irrigated with water contaminated with fecal matter and tapeworm eggs, rather than consumption of cysts present in pork meat.^{13,14}

5 | CLINICAL PRESENTATION

Clinical manifestations can range from entirely asymptomatic infection to severe illness and death. Infestation outside the CNS occurs in humans but is generally under-recognized. Contrastingly, patients most often seek attention for neurological symptoms.¹⁵ The severity of the disease and the clinical manifestations are associated with the characteristics of the infestation (number, size, and location of the cysts, along with the intensity of the host's immune response). NCC is considered a great imitator in endemic areas because it can mimic almost any neurological disorder.^{16,17} Clinical presentation differs between parenchymal disease (within the brain tissue) and extra parenchymal involvement, most commonly in the subarachnoid spaces, ventricles, and spine. However, it is not uncommon to find patients with several co-occurring NCC lesions of various forms, locations, and stages.¹⁸ Seizures caused by NCC likely result from the

TABLE 1 Diagnostic criteria for NCC¹.

1. Parenchymal neurocysticercosis
Definitive parenchymal neurocysticercosis ^(a) , one of the following:
1. Parenchymal cyst with pathological diagnosis
2. Single or multiple active parenchymal cysts, with at least one cyst with scolex on CT or MRI
3. Multiple parenchymal vesicles without scolex associated with at least one of the following:
a. Seizures: focal or generalized tonic-clonic
b. Positive serum or CSF immunological test
4. Any combination of the parenchymal cysticercus in different evolutive stages: vesicular with or without scolex, degenerative (colloidal or nodular), and calcified
Probable parenchymal neurocysticercosis, one of the following:
1. Single parenchymal calcification or vesicle (without scolex) or degenerating cyst(s), establishing differential diagnoses with other etiologies, associated with at least two of the following:
a. Seizures: focal or generalized tonic-clonic
b. Subcutaneous or muscle cysts location confirmed by biopsy
c. Positive serum or CSF immunological test
d. Plain X-ray films showing “cigar-shaped” calcifications
e. Individual who lives or has lived in or has traveled frequently to endemic countries
2. Multiple parenchymal calcifications in an individual who lives or has lived in or has traveled frequently to endemic countries and in whom clinical state excludes other etiologies of calcifications
2. Extraparenchymal neurocysticercosis (intraventricular/basal subarachnoid)
Definitive extraparenchymal neurocysticercosis, one of the following:
1. Extraparenchymal cyst with pathological diagnosis
2. One or more extraparenchymal cysts on MRI special sequences with scolex in at least one of them
3. One or more extraparenchymal cysts on MRI special sequences without scolex associated with at least two of the following:
a. Hydrocephalus
b. Inflammatory CSF
c. Positive CSF immunological test
d. Presence of single or multiple calcifications or parenchymal vesicular or degenerative cyst
3. Definitive parenchymal and extraparenchymal neurocysticercosis
Combination of the above definitive parenchymal and definitive extraparenchymal criteria

^(a) Parasite located in the subarachnoid space of the convexity are included with parenchymal parasites.

⁽¹⁾ From Ref.,²¹ with permission.

space-occupying effect and a reactive inflammatory response within the brain parenchyma.¹⁹ Diagnostic criteria for NCC were first published in 2001²⁰ and then revised in 2016 by a group of experts from endemic countries.²¹ The latter is reproduced in [Table 1](#).

Adult-onset seizures (in particular of focal onset) are highly suggestive of NCC in patients living in geographical areas with a high prevalence of the disease.²² Seizures are more likely to occur in the presence of multiple lesions in the acute or chronic phases of the infestation.²³ First-time seizures are often related to an active cyst, whereas chronic epilepsy is associated with calcified granulomas, with cysts undergoing degeneration being the most epileptogenic.²⁴ Recurrent seizures occur in about 40%–80% of symptomatic cases of NCC,^{3,8} with active lesions being predictive of recurrence. Seizures are often of focal origin, typically with corresponding clinical semiology and EEG findings.²⁵ However, seizure characteristics may not be

congruent with the location and stage of NCC lesions, as **Case 2** illustrates, with some (but not all) features being compatible with alteration of mesial temporal structures. This is further complicated in patients with multiple NCC lesions, and the co-occurrence of other pathologies, such as hippocampal sclerosis.^{31–34} Other presentations include focal neurological deficits (16%), increased intracranial pressure (12%), and cognitive impairment (5%). Disappearance of calcified lesions in CT is predictive of good outcome, but subsequent development of hippocampal atrophy has been described in patients who presented with status epilepticus.²⁶

Treatment should be individualized based on the lesions' extent, location, and clinical manifestations. Cysticidal drugs such as albendazole, imidazole, or praziquantel are effective at killing the parasite. However, this is often associated with an extensive inflammatory response that could pose an even greater risk to the patient than the infestation

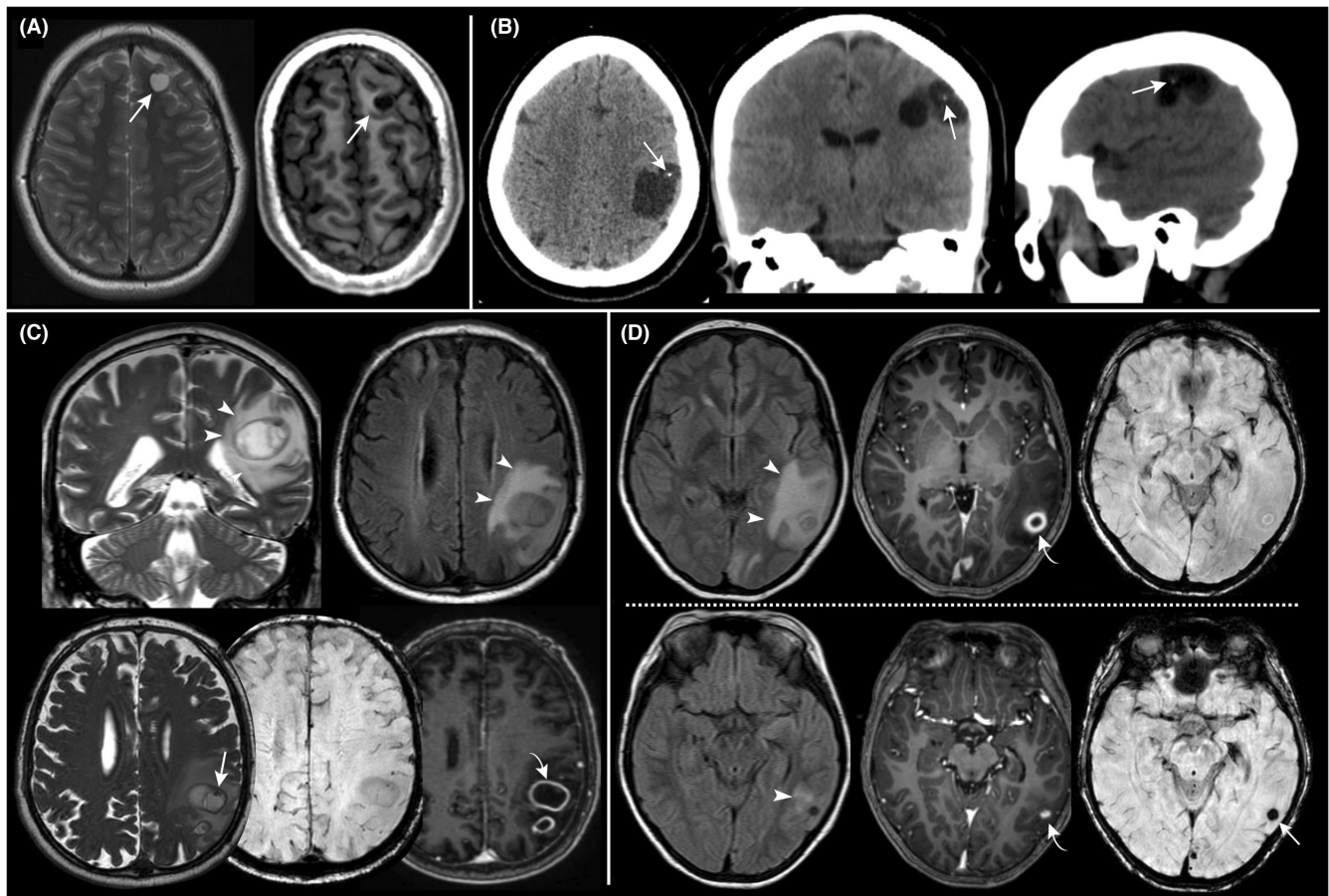


FIGURE 4 Examples of early-stage NCC lesions. (A) Vesicular lesions in the left frontal lobe (arrows). The interior of the lesion shows intensities similar to CSF in T2-(left) and T1-(right) weighted images. (B) The scolex can be identified on CT as a hyperdense spot within a large hypodense cyst (“hole-with-dot”; arrows). (C) Large temporo-parietal vesiculo-colloidal lesions with visible scolex (arrow), considerable perilesional edema (arrowheads), and signal enhancement of the capsule (curved arrow). (D) Temporal evolution in a patient showing a large vesiculo-colloidal lesion (top) that is greatly reduced after treatment (bottom), with near-complete resolution of edema on FLAIR (left; arrowheads), subtle post-contrast enhancement (middle; curved arrows), and visible calcification on SWI (hypointense, right; arrow).

itself.²⁷ Prior or upon initiation of antiparasitic drugs, systemic steroids can be used to prevent an exacerbated inflammatory response,^{10,28} but rebound inflammation can occur upon their discontinuation²⁹; methotrexate has been suggested as an alternative treatment to, or during tapering of steroids.³⁰ Cysticidal drugs are not necessary if only calcified cysts are identified, as the parasite is already dead. Patients with epilepsy related to NCC often respond well to conventional anti-seizure medications.^{16,17,22} However, even after 2 years of seizure freedom, their discontinuation may result in a relapse in some patients.¹⁸ As **Case 1** shows, ventriculoperitoneal shunting may be required to alleviate hydrocephalus. Surgical treatment can be an effective option for select refractory cases of NCC-related epilepsy, particularly when calcified cysts or dual pathology with hippocampal sclerosis are present.^{31–34} Lesionectomy and

lobectomy are viable surgical approaches, but careful monitoring for potential complications such as infection or hemorrhage is necessary.^{31,35,36} Surgical removal of cysts and shunt insertion for fluid drainage may be necessary in cases of extensive infection, such as racemose NCC and severe extraparenchymal NCC.²⁷ Development of new techniques such as lamina terminalis endoscopic third ventriculostomy (LT-ETV) may offer additional options for surgical intervention.³⁷ Careful patient selection and thorough preoperative evaluation are necessary to ensure optimal outcomes.

6 | NEUROIMAGING FINDINGS

Neuroimaging has become a cornerstone in the diagnosis of NCC as histological confirmation is generally not

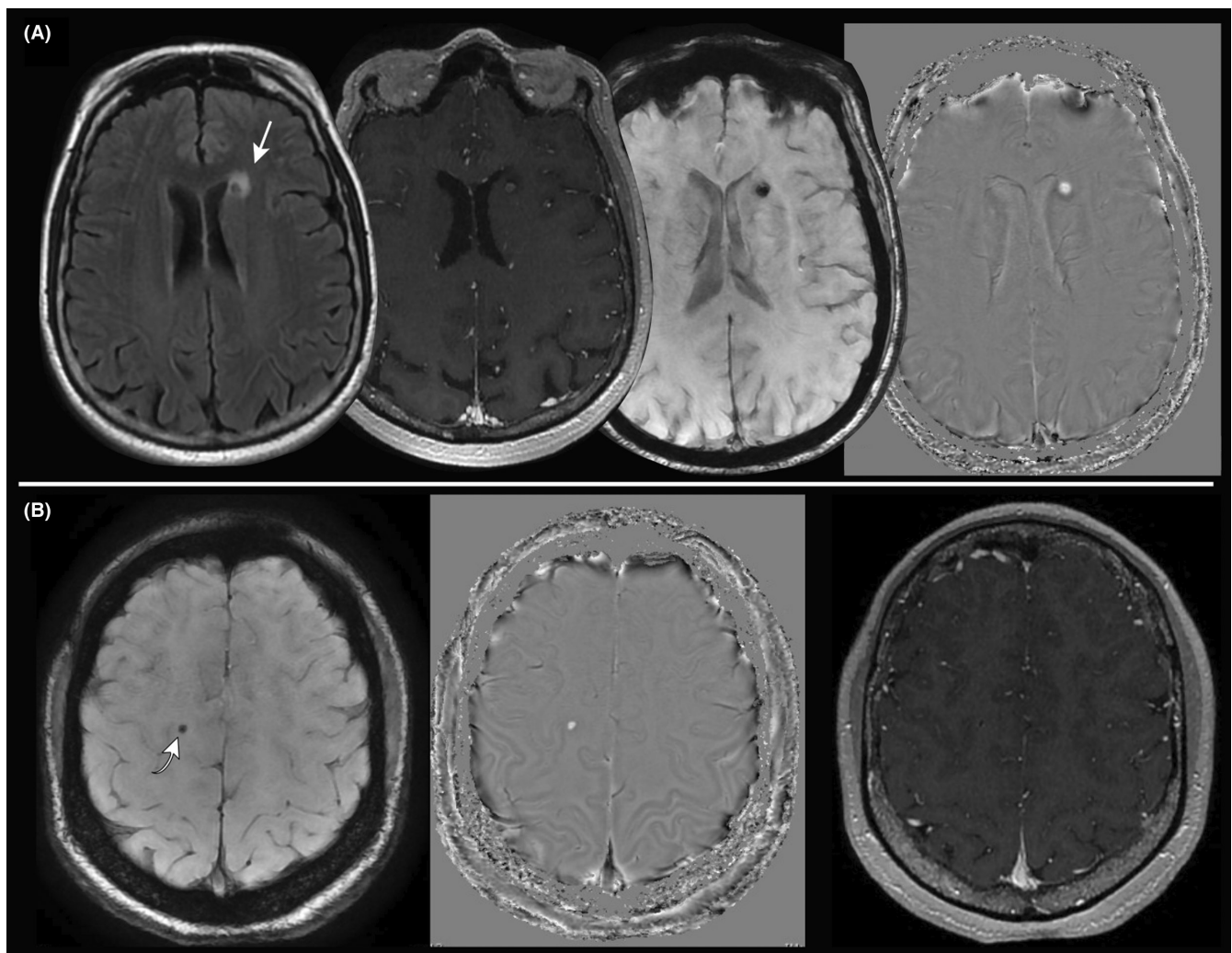


FIGURE 5 Examples of late-stage NCC lesions. (A) Granulomatous lesion adjacent to the lateral ventricle with some perilesional edema on FLAIR (leftmost image; arrow), no signal enhancement after contrast administration (second image from the left), and signs of calcifications on SWI (hypointensity, third image from the left) and the corresponding phase map (hyperintensity, rightmost image). (B) Calcified lesion seen as hypointense on SWI (left; curved arrow) and hyperintense on the corresponding phase map (middle), without contrast enhancement (right).

needed.³⁸ In general, CT is more widely available and, in most cases, sufficient for the demonstration of NCC. If available, however, MRI should be preferred due to its higher diagnostic yield, ideally following the HARNES MRI protocol for neuroimaging of adults with epilepsy^{39,40} with the addition of optional contrasts sensitive to calcifications (see below). The demonstration of a scolex within a cystic lesion through neuroimaging is considered as an absolute criterion for the diagnosis of NCC (figure 1). These round lesions are generally 10–20 mm in diameter, with their content isointense to cerebrospinal fluid (CSF), but with a notable object (the scolex) encapsulated within, thus receiving the term “hole-with-dot” imaging sign (figure 4). Differential diagnosis includes cystic primary tumors (e.g., epidermoid cysts, and teratoma) and metastases, arachnoid cysts, hydatidosis, toxoplasmosis, and abscesses—their distinction relies on careful examination through different MRI contrast mechanisms. Other imaging signs are highly suggestive of NCC: (1) cystic lesions without scolex; (2) ring-like lesions that enhance after gadolinium administration and may be accompanied by perilesional edema; (3) multilobulated cystic lesions in subarachnoid space (racemose NCC)⁴¹; and (4) parenchymal brain calcifications. Calcifications signal non-viable cysticerci, are typically less than 1 cm in diameter with well-defined borders, and are easily visualized through CT and with MRI with the use of additional contrasts such as T2* (gradient echo) and susceptibility-weighted imaging (SWI, Figure 5). Diagnostic support for NCC is provided by the spontaneous resolution of small enhancing lesions, or their disappearance or transformation into calcifications after treatment with antiparasitic medications (albendazole or praziquantel).⁴² Immunodiagnostic tests of CSF and serum samples (ELISA, immunoblot, and NOVALISA) provide ancillary support for the diagnosis of NCC, with sensitivity and specificity as high as 81% and 97% respectively.^{43,44}

Lesion appearance in CT and MRI varies as a function of the cyst's lifetime evolution (Figures 3 and 4). As the parasite invades the tissue, there is focal edema and some degree of contrast enhancement. Cyst formation occurs next, with signal being isointense to CSF, and the scolex becomes apparent (vesicular stage). After the parasite dies within the cyst, a capsule forms around the cyst with considerable contrast enhancement, the fluid becomes turbid, and the associated inflammatory response induces further perilesional edema (colloidal-vesicular stage). The cyst then retracts, the capsule is thickened, and the lesion appears hypointense on T2-weighted images, with very little surrounding edema and persisting post-contrast enhancement (granular nodular stage). Lesions finally become calcified, usually without contrast enhancement or perilesional edema (calcified nodular

stage).¹ However, edema and MRI contrast enhancement around NCC calcifications have been described, which may be intermittent and associated with seizures.^{45,46} It is not uncommon for a single patient to host several NCC lesions in various stages.

7 | CONCLUSIONS

Epilepsy secondary to NCC is, sadly, still highly prevalent around the world, yet NCC remains in the World Health Organization's list of neglected tropical diseases. Imaging must be performed in all patients with adult-onset focal seizures, and NCC should rank high in the list of differential diagnoses in highly endemic countries. Head CT is widely available and can easily identify calcified granulomas and viable or degenerating cysts, allowing for fast diagnosis even in countries with limited resources. Brain MRI can provide additional information about surrounding inflammatory response and cyst staging. NCC is much less frequently found in well-resourced countries, where other lesions such as tumors, vascular lesions, or malformations of cortical development may be more frequent. However, the long temporal evolution of the parasite, combined with worldwide migratory fluxes brought by social, political, and climate-related unrest, have brought patients with NCC (and other infectious and parasitic causes of seizures⁴⁷) to non-endemic regions. Despite the effectiveness of antiparasitic drugs and the usual control of seizures with standard anti-seizure medications, patients with NCC can suffer a long-lasting and debilitating disease. Recurrent infestation can also occur, and thus, sanitary conditions should be a public health priority, with preventative measures to abate orofecal disease transmission implemented in all countries.

ACKNOWLEDGMENTS

LC and A.D-F thank Dr. Erick Pasaye and the personnel at the National Laboratory of MRI, Mexico, for technical assistance during the acquisition and processing of images presented in Figures 4 and 5. LC was partially funded by UNAM-DGAPA (IN204720).

ORCID


Ildefonso Rodríguez-Leyva  <https://orcid.org/0000-0002-3316-1471>

Karla Cantú-Flores  <https://orcid.org/0000-0002-9092-106X>

Anna Elisabetta Vaudano  <https://orcid.org/0000-0002-6280-7526>

John Archer  <https://orcid.org/0000-0002-3939-3847>

Boris Bernhardt  <https://orcid.org/0000-0001-9256-6041>

Lorenzo Caciagli  <https://orcid.org/0000-0001-7189-9699>
 Fernando Cendes  <https://orcid.org/0000-0001-9336-9568>
 Paolo Federico  <https://orcid.org/0000-0002-9555-3569>
 William D. Gaillard  <https://orcid.org/0000-0001-5709-0033>
 Eliane Kobayashi  <https://orcid.org/0000-0002-1713-1563>
 Godwin Ogbolo  <https://orcid.org/0000-0003-0431-7198>
 Stefan Rampp  <https://orcid.org/0000-0002-4826-1520>
 Irene Wang  <https://orcid.org/0000-0002-3829-5217>
 Shuang Wang  <https://orcid.org/0000-0001-5211-9036>
 Luis Concha  <https://orcid.org/0000-0002-7842-3869>

REFERENCES

- Kimura-Hayama ET, Higuera JA, Corona-Cedillo R, Chávez-Macias L, Perochena A, Quiroz-Rojas LY, et al. Neurocysticercosis: radiologic-pathologic correlation. *Radiographics*. 2010;30:1705–19. <https://doi.org/10.1148/rg.306105522>
- García HH. Neurocysticercosis. *Neurol Clin*. 2018;36:851–64. <https://doi.org/10.1016/j.ncl.2018.07.003>
- Mazumder R, Lee JK. Epileptogenesis in common parasitic infections. *Curr Neurol Neurosci Rep*. 2022;22:285–91. <https://doi.org/10.1007/s11910-022-01187-6>
- Del Brutto OH. Neurocysticercosis: actualización en diagnóstico y tratamiento. *Neurología (Barc ed Impr)*. 2005;4:12–8.
- Giménez-Roldán S, Díaz F, Esquivel A. Neurocysticercosis e inmigración. *Neurología*. 2003;18:385–8.
- Bern C, García HH, Evans C, Gonzalez AE, Verastegui M, Tsang VC, et al. Magnitude of the disease burden from neurocysticercosis in a developing country. *Clin Infect Dis off Publ Infect Dis Soc Am*. 1999;29:1203–9. <https://doi.org/10.1086/313470>
- García HH, Gonzalez AE, Tsang VCW, Gilman RH. Neurocysticercosis: some of the essentials. *Pract Neurol*. 2006;6:288–97. <https://doi.org/10.1136/jnnp.2006.101253>
- Carabin H, Ndimubanzi PC, Budke CM, Nguyen H, Qian Y, Cowan LD, et al. Clinical manifestations associated with neurocysticercosis: a systematic review. *PLoS Negl Trop Dis*. 2011;5:e1152. <https://doi.org/10.1371/journal.pntd.0001152>
- García HH, Gonzalez AE, Evans CAW, Gilman RH. Cysticercosis working Group in Peru. *Taenia Solium Cysticercosis Lancet Lond Engl*. 2003;362:547–56. [https://doi.org/10.1016/S0140-6736\(03\)14117-7](https://doi.org/10.1016/S0140-6736(03)14117-7)
- García HH, Nash TE, Del Brutto OH. Clinical symptoms, diagnosis, and treatment of neurocysticercosis. *Lancet Neurol*. 2014;13:1202–15. [https://doi.org/10.1016/S1474-4422\(14\)70094-8](https://doi.org/10.1016/S1474-4422(14)70094-8)
- Del Brutto OH. Neurocysticercosis. *Handb Clin Neurol*. 2014;121:1445–59. <https://doi.org/10.1016/B978-0-7020-4088-7.00097-3>
- Flisser A. Taeniasis and cysticercosis due to taenia solium. *Prog Clin Parasitol*. 1994;4:77–116.
- Lescano AG, García HH, Gilman RH, Gavidia CM, Tsang VCW, Rodríguez S, et al. Taenia solium cysticercosis hotspots surrounding tapeworm carriers: clustering on human seroprevalence but not on seizures. *PLoS Negl Trop Dis*. 2009;3:e371. <https://doi.org/10.1371/journal.pntd.0000371>
- O'Neal SE, Moyano LM, Ayvar V, Gonzalez G, Diaz A, Rodriguez S, et al. Geographic correlation between tapeworm carriers and heavily infected cysticercotic pigs. *PLoS Negl Trop Dis*. 2012;6:e1953. <https://doi.org/10.1371/journal.pntd.0001953>
- Guzman C, Garcia HH. Current diagnostic criteria for neurocysticercosis. *Res Rep Trop Med*. 2021;12:197–203. <https://doi.org/10.2147/RRTM.S285393>
- García HH, Del Brutto OH, Cysticercosis Working Group in Peru. Neurocysticercosis: updated concepts about an old disease. *Lancet Neurol*. 2005;4:653–61. [https://doi.org/10.1016/S1474-4422\(05\)70194-0](https://doi.org/10.1016/S1474-4422(05)70194-0)
- Takayanagui OM, Odashima NS. Clinical aspects of neurocysticercosis. *Parasitol Int*. 2006;55:S111–5. <https://doi.org/10.1016/j.parint.2005.11.016>
- Nash TE, García HH. Diagnosis and treatment of neurocysticercosis. *Nat Rev Neurol*. 2011;7:584–94. <https://doi.org/10.1038/nrneurol.2011.135>
- Vezzani A, Fujinami RS, White HS, Preux P-M, Blümcke I, Sander JW, et al. Infections, inflammation and epilepsy. *Acta Neuropathol (Berl)*. 2016;131:211–34. <https://doi.org/10.1007/s00401-015-1481-5>
- Del Brutto OR, Rajshekhar V, White AC, Tsang VCW, Nash TE, Takayanagui OM, et al. Proposed diagnostic criteria for neurocysticercosis. *Neurology*. 2001;57:177–83.
- Carpio A, Fleury A, Romo ML, Abraham R, Fandiño J, Durán JC, et al. New diagnostic criteria for neurocysticercosis: reliability and validity. *Ann Neurol*. 2016;80:434–42. <https://doi.org/10.1002/ana.24732>
- Del Brutto OH, Santibañez R, Noboa CA, Aguirre R, Díaz E, Alarcón TA. Epilepsy due to neurocysticercosis: analysis of 203 patients. *Neurology*. 1992;42:389–9. <https://doi.org/10.1212/WNL.42.2.389>
- Kelvin EA, Carpio A, Bagiella E, Leslie D, Leon P, Andrews H, et al. Seizure in people with newly diagnosed active or transitional neurocysticercosis. *Seizure*. 2011;20:119–25. <https://doi.org/10.1016/j.seizure.2010.10.036>
- DeGiorgio CM, Medina MT, Durón R, Zee C, Escueta SP. Neurocysticercosis. *Epilepsy Curr*. 2004;4:107–11. <https://doi.org/10.1111/j.1535-7597.2004.43008.x>
- Duque KR, Burneo JG. Clinical presentation of neurocysticercosis-related epilepsy. *Epilepsy Behav EB*. 2017;76:151–7. <https://doi.org/10.1016/j.yebeh.2017.08.008>
- Kobayashi E, Guerreiro CA, Cendes F. Late onset temporal lobe epilepsy with MRI evidence of mesial temporal sclerosis following acute neurocysticercosis: case report. *Arq Neuropsiquiatr*. 2001;59:255–8. <https://doi.org/10.1590/s0004-282x2001000200021>
- Gripper LB, Welburn SC. Neurocysticercosis infection and disease—a review. *Acta Trop*. 2017;166:218–24. <https://doi.org/10.1016/j.actatropica.2016.11.015>
- Baird RA, Wiebe S, Zunt JR, Halperin JJ, Gronseth G, Roos KL. Evidence-based guideline: treatment of parenchymal neurocysticercosis. *Neurology*. 2013;80:1424–9. <https://doi.org/10.1212/WNL.0b013e31828c2f3e>
- Mejia R, Nash TE. Corticosteroid withdrawal precipitates perilesional edema around calcified taenia solium cysts. *Am J Trop Med Hyg*. 2013;89:919–23. <https://doi.org/10.4269/ajtmh.13-0350>

30. Mitre E, Talaat KR, Sperling MR, Nash TE. Methotrexate as a corticosteroid-sparing agent in complicated neurocysticercosis. *Clin Infect Dis*. 2007;44:549–53. <https://doi.org/10.1086/511040>
31. White AC Jr, Coyle CM, Rajshekhar V, Singh G, Hauser WA, Mohanty A, et al. Diagnosis and treatment of neurocysticercosis: 2017 clinical practice guidelines by the Infectious Diseases Society of America (IDSA) and the American Society of Tropical Medicine and Hygiene (ASTMH). *Clin Infect Dis*. 2018;66:e49–75. <https://doi.org/10.1093/cid/cix1084>
32. Espino PH, Couper RG, Burneo JG. An update on neurocysticercosis-related epilepsy. *Clin Neurol Neurosurg*. 2022;213:107139. <https://doi.org/10.1016/j.clineuro.2022.107139>
33. Velasco TR, Zanello PA, Dalmagro CL, Araújo D, Santos AC, Bianchin MM, et al. Calcified cysticercotic lesions and intractable epilepsy: a cross sectional study of 512 patients. *J Neurol Neurosurg Psychiatry*. 2006;77:485–8. <https://doi.org/10.1136/jnnp.2005.078675>
34. da Gama CN, Kobayashi E, Li LM, Cendes F. Hippocampal atrophy and neurocysticercosis calcifications. *Seizure*. 2005;14:85–8. <https://doi.org/10.1016/j.seizure.2004.10.005>
35. Singh G, Chowdhary AK. Epilepsy surgery in context of neurocysticercosis. *Ann Indian Acad Neurol*. 2014;17:S65–8. <https://doi.org/10.4103/0972-2327.128660>
36. Escalaya AL, Burneo JG. Epilepsy surgery and neurocysticercosis: assessing the role of the cysticercotic lesion in medically-refractory epilepsy. *Epilepsy Behav EB*. 2017;76:178–81. <https://doi.org/10.1016/j.yebeh.2017.01.029>
37. Giussani C, Guida L, Trezza A, Sganzerla EP. Effectiveness of intraventricular endoscopic lamina terminalis fenestration in comparison with standard ETV: systematic review of literature. *World Neurosurg*. 2017;103:257–64. <https://doi.org/10.1016/j.wneu.2017.03.143>
38. Del Brutto OH, Nash TE, White AC, Rajshekhar V, Wilkins PP, Singh G, et al. Revised diagnostic criteria for neurocysticercosis. *J Neurol Sci*. 2017;372:202–10. <https://doi.org/10.1016/j.jns.2016.11.045>
39. Bernasconi A, Cendes F, Theodore WH, Gill RS, Koeppe MJ, Hogan RE, et al. Recommendations for the use of structural magnetic resonance imaging in the care of patients with epilepsy: a consensus report from the international league against epilepsy neuroimaging task force. *Epilepsia*. 2019;60:1054–68. <https://doi.org/10.1111/epi.15612>
40. Wang I, Bernasconi A, Bernhardt B, Blumenfeld H, Cendes F, Chinvarun Y, et al. MRI essentials in epileptology: a review from the ILAE imaging taskforce. *Epileptic Disord Int Epilepsy J Videotape*. 2020;22:421–37. <https://doi.org/10.1684/epd.2020.1174>
41. Bickerstaff ER, Cloake PCP, Hughes B, Smith WT. The race-mose form of cerebral cysticercosis. *Brain J Neurol*. 1952;75:1–18. <https://doi.org/10.1093/brain/75.1.1>
42. Garcia HH, Gonzales I, Lescano AG, Bustos JA, Zimic M, Escalante D, et al. Efficacy of combined antiparasitic therapy with praziquantel and albendazole for neurocysticercosis: a double-blind, randomised controlled trial. *Lancet Infect Dis*. 2014;14:687–95. [https://doi.org/10.1016/S1473-3099\(14\)70779-0](https://doi.org/10.1016/S1473-3099(14)70779-0)
43. Michelet L, Fleury A, Sciutto E, Kendjo E, Fragoso G, Paris L, et al. Human neurocysticercosis: comparison of different diagnostic tests using cerebrospinal fluid. *J Clin Microbiol*. 2011;49:195–200. <https://doi.org/10.1128/JCM.01554-10>
44. Hernández M, Astudillo O-G, Diego G, de-la-Rosa-Arana J-L, Meza-Lucas A, García-Rodea R, et al. Immunodiagnosis of human neurocysticercosis: comparative performance of serum diagnostic tests in Mexico. *Parasitol Res*. 2019;118:2891–9. <https://doi.org/10.1007/s00436-019-06425-4>
45. Nash TE, Pretell EJ, Lescano AG, Bustos JA, Gilman RH, Gonzalez AE, et al. Perilesional brain oedema and seizure activity in patients with calcified neurocysticercosis: a prospective cohort and nested case-control study. *Lancet Neurol*. 2008;7:1099–105. [https://doi.org/10.1016/S1474-4422\(08\)70243-6](https://doi.org/10.1016/S1474-4422(08)70243-6)
46. Jama-António JMC, Yasuda CL, Cendes F. Intermittent perilesional edema and contrast enhancement in epilepsy with calcified neurocysticercosis may help to identify the seizure focus. *Epilepsia Open*. 2019;4:351–4. <https://doi.org/10.1002/epi4.12324>
47. Yacubian EMT, Kakooza-Mwesige A, Singh G, Carpio A, de Figueiredo NV, Lutzky Saute R, et al. Common infectious and parasitic diseases as a cause of seizures: geographic distribution and contribution to the burden of epilepsy. *Epileptic Disord Int Epilepsy J Videotape*. 2022;24:994–1019. <https://doi.org/10.1684/epd.2022.1491>

SUPPORTING INFORMATION

Additional supporting information can be found online in the Supporting Information section at the end of this article.

How to cite this article: Rodríguez-Leyva I, Cantú-Flores K, Domínguez-Frausto A, Vaudano AE, Archer J, Bernhardt B, et al. Neurocysticercosis and epilepsy: Imaging and clinical characteristics. *Epileptic Disord*. 2023;00:1–10. <https://doi.org/10.1002/epd2.20060>

Test yourself

1. A 22-year-old man with new-onset seizures that begin with clonic movements of the left arm followed by loss of consciousness and secondarily generalized tonic–clonic seizures. The differential diagnosis does NOT include one of the following:
 - A. Arterio-venous malformation
 - B. Neurocysticercosis
 - C. Primary brain tumor or metastasis
 - D. Malformation of cortical development
 - E. Metabolic encephalitis
2. MRI scan is performed. T2-weighted images show a large collection of inhomogeneous fluid, with a small solid mass within it. Considerable edema, seen as hyperintense on T2-weighted images, surrounds the lesion. After contrast injection, T1-weighted images show a very bright ring-like structure surrounding the fluid. This type of lesion is:
 - A. Calcified NCC
 - B. Granulomatous NCC
 - C. Vesicular NCC
 - D. Racemose NCC
3. A calcified NCC is (select the only correct one):
 - A. A live larva surrounded by a calcified capsule
 - B. Amenable to treatment with antiparasitic drugs
 - C. A degenerated dead larva
 - D. Invisible on CT scan
 - E. Often surrounded by edema

Answers may be found in the [Supporting Information](#).