



## Central serous chorioretinopathy: Towards an evidence-based treatment guideline



Thomas J. van Rijssen<sup>a,1</sup>, Elon H.C. van Dijk<sup>a,1</sup>, Suzanne Yzer<sup>b,1</sup>, Kyoko Ohno-Matsui<sup>c,1</sup>, Jan E.E. Keunen<sup>d,1</sup>, Reinier O. Schlingemann<sup>e,f,1</sup>, Sobha Sivaprasad<sup>g,1</sup>, Giuseppe Querques<sup>h,1</sup>, Susan M. Downes<sup>i,1</sup>, Sascha Fauser<sup>j,k,1</sup>, Carel B. Hoyng<sup>d,1</sup>, Felice Cardillo Piccolino<sup>l,1</sup>, Jay K. Chhablani<sup>m,1</sup>, Timothy Y.Y. Lai<sup>n,o,1</sup>, Andrew J. Lotery<sup>p,1</sup>, Michael Larsen<sup>q,r,1</sup>, Frank G. Holz<sup>s,1</sup>, K. Bailey Freund<sup>t,u,v,1</sup>, Lawrence A. Yannuzzi<sup>t,u,v,1</sup>, Camiel J.F. Boon<sup>a,e,\*,1</sup>

<sup>a</sup> Department of Ophthalmology, Leiden University Medical Center, Leiden, the Netherlands

<sup>b</sup> Department of Ophthalmology, Rotterdam Eye Hospital, Rotterdam, the Netherlands

<sup>c</sup> Department of Ophthalmology and Visual Science, Tokyo Medical and Dental University, Graduate School, Tokyo, Japan

<sup>d</sup> Department of Ophthalmology, Radboud University Medical Center, Nijmegen, the Netherlands

<sup>e</sup> Department of Ophthalmology, Amsterdam University Medical Center, University of Amsterdam, the Netherlands

<sup>f</sup> Department of Ophthalmology, University of Lausanne, Jules Gonin Eye Hospital, Fondation Asile des Aveugles, Lausanne, Switzerland

<sup>g</sup> NIHR Moorfields Biomedical Research Centre 162, London, United Kingdom

<sup>h</sup> Department of Ophthalmology, IRCCS Ospedale San Raffaele, Vita-Salute University, Milan, Italy

<sup>i</sup> Oxford Eye Hospital, John Radcliffe Hospital, Oxford University Hospitals NHS Foundation Trust, West Wing, Oxford, United Kingdom

<sup>j</sup> Department of Ophthalmology, University Hospital of Cologne, Cologne, Germany

<sup>k</sup> F. Hoffmann-La Roche, Basel, Switzerland

<sup>l</sup> Fondazione per la Macula Onlus, Di.N.O.G.Mi, University Eye Clinic, University of Genova, Italy

<sup>m</sup> Smt. Kanuri Santhamma Retina Vitreous Centre, L.V. Prasad Eye Institute, Kallam Anji Reddy Campus, Banjara Hills, Hyderabad, India

<sup>n</sup> Department of Ophthalmology & Visual Sciences, The Chinese University of Hong Kong, Hong Kong

<sup>o</sup> 2010 Retina & Macula Centre, Tsim Sha Tsui, Kowloon, Hong Kong

<sup>p</sup> Faculty of Medicine, University of Southampton, Southampton, United Kingdom

<sup>q</sup> Department of Ophthalmology, Rigshospitalet, Glostrup, Denmark

<sup>r</sup> Faculty of Health Sciences, University of Copenhagen, Copenhagen, Denmark

<sup>s</sup> Department of Ophthalmology, University of Bonn, Bonn, Germany

<sup>t</sup> Vitreous Retina Macula Consultants of New York, New York, NY, USA

<sup>u</sup> LuEsther T. Mertz Retinal Research Center, Manhattan Eye, Ear, and Throat Hospital, New York, NY, USA

<sup>v</sup> Department of Ophthalmology, New York University School of Medicine, New York, NY, USA

### ARTICLE INFO

#### Keywords:

Central serous chorioretinopathy  
Treatment  
Guideline  
Photodynamic therapy  
Micropulse laser  
Mineralocorticoid antagonist  
Retina

### ABSTRACT

Central serous chorioretinopathy (CSC) is a common cause of central vision loss, primarily affecting men 20–60 years of age. To date, no consensus has been reached regarding the classification of CSC, and a wide variety of interventions have been proposed, reflecting the controversy associated with treating this disease. The recent publication of appropriately powered randomised controlled trials such as the PLACE trial, as well as large retrospective, non-randomised treatment studies regarding the treatment of CSC suggest the feasibility of a more evidence-based approach when considering treatment options. The aim of this review is to provide a comprehensive overview of the current rationale and evidence with respect to the variety of interventions available for treating CSC, including pharmacology, laser treatment, and photodynamic therapy. In addition, we describe the complexity of CSC, the challenges associated with treating CSC, and currently ongoing studies. Many treatment strategies such as photodynamic therapy using verteporfin, oral mineralocorticoid antagonists, and micropulse laser treatment have been reported as being effective. Currently, however, the available evidence suggests that half-dose (or half-fluence) photodynamic therapy should be the treatment of choice in chronic CSC, whereas

\* Corresponding author. Leiden University Medical Center, Department of Ophthalmology, P.O. Box 9600 2300, RC, Leiden, the Netherlands.

E-mail address: [c.j.f.boon@lumc.nl](mailto:c.j.f.boon@lumc.nl) (C.J.F. Boon).

<sup>1</sup> Percentage of work contributed by each author in the production of the manuscript is as follows: T.J. van Rijssen: 25%; E.H.C. van Dijk: 7%; S. Yzer: 3%; K. Ohno-Matsui: 3%; J.E.E. Keunen: 3%; R.O. Schlingemann: 3%; S. Sivaprasad: 3%; G. Querques: 3%; S.M. Downes: 3%; S. Fauser: 3%; C.B. Hoyng: 3%; F. Cardillo Piccolino: 3%; J. Chhablani: 3%; T.Y.Y. Lai: 3%; A.J. Lotery: 3%; M. Larsen: 3%; F.G. Holz: 3%; K.B. Freund: 3%; L.A. Yannuzzi: 3%; C.J.F. Boon: 17%.

<https://doi.org/10.1016/j.preteyeres.2019.07.003>

Received 30 March 2019; Received in revised form 11 July 2019; Accepted 14 July 2019

Available online 15 July 2019

1350-9462/© 2019 The Authors. Published by Elsevier Ltd. This is an open access article under the CC BY license

(<http://creativecommons.org/licenses/by/4.0/>).

observation may be the preferred approach in acute CSC. Nevertheless, exceptions can be considered based upon patient-specific characteristics.

## 1. Introduction

Central serous chorioretinopathy (CSC) is a chorioretinal disease that causes idiopathic serous detachment of the retina, which is associated with one or more areas of leakage from the choroid through a defect in the retinal pigment epithelium (RPE) outer blood-retina barrier. The majority of patients are men who have decreased and/or distorted vision together with altered colour appreciation, and CSC is generally associated with a decrease in the patient's quality of life (Breukink et al., 2017; Sahin et al., 2014). The age at onset for CSC can be as early as 7 years and as late as 83 years, with a peak at 40–50 years (Castro-Correia et al., 1992; Fine and Owens, 1980; Gilbert et al., 1984; Spaide et al., 1996a). CSC is relatively common, considered the fourth most common non-surgical retinopathy associated with fluid leakage (after neovascular age-related macular degeneration (AMD), diabetic macular oedema, and retinal vein occlusion). Although the subretinal fluid (SRF) can resolve spontaneously, many patients have significant clinical sequelae, including atrophy of the RPE or retina, and patients can also develop subretinal neovascularisation. The pathogenesis of CSC remains poorly understood; however, choroidal abnormalities are believed to be the primary underlying pathophysiology (Cardillo Piccolino et al., 1995; Daruich et al., 2015; Guyer et al., 1994; Prunte and Flammer, 1996; Spaide et al., 1996b). These abnormalities can include choroidal thickening and hyperpermeability, together with increased hydrostatic pressure, which has been hypothesised to induce detachment of the RPE. These points of RPE detachment can remain isolated, but breakdown of the outer blood-retina barrier can also cause leakage of fluid into the subretinal space, resulting in active CSC. The chronic presence of SRF can ultimately damage the RPE, although in some cases the underlying multifocal choroidal vascular dysfunction can directly affect the RPE without the presence of SRF (Gass, 1967; Hayashi et al., 1986).

Central serous chorioretinopathy was first described as ‘relapsing central luetic retinitis’ by Albrecht von Graefe more than 150 years ago (von Graefe, 1866). In the 1930s, Kitahara changed the name to central serous chorioretinitis, describing many of the clinical features associated with the disease and hypothesising that the disease occurs secondary to tuberculosis (Kitahara, 1936). At around the same time, Horniker called the condition ‘capillaro-spastic central retinitis’ and postulated that the disease has a vascular origin (Horniker, 1927, 1937). In the 1940s, the condition was renamed ‘central serous retinopathy’ by Duke-Elder (1940). At the time, the disease was believed to occur secondary to spasms of the retinal vessels, which was believed to cause a subretinal leakage of fluid. The majority of cases reported at that time were military recruits in World War II; therefore, most of the cases were young men.

Even back then, there was a focus on the autonomic nervous system. For example, in 1955 Bennett noted from his review of the literature and his personal analysis of patients with CSC that ‘... while admitting that certain individuals – call them allergic, neurotic, endocrinopathic, vasculospastic, or what you will – are peculiarly susceptible to an attack, we should not rule out an immediate essential cause, possibly infective.’ (Bennett, 1955). Bennett also reported a high incidence of ‘stress diseases’ and history of stress-producing life situations, as well as a ‘tense obsessional mental make-up’ among affected patients. Maumenee used fluorescein angiography to obtain fundamental information regarding the pathophysiology of disease (Maumenee, 1965), finding that the condition is associated with leakage at the level of the RPE, not from the retinal vessels. The same group later suggested that a recently invented device – the laser – might be used to treat this leak (Patz et al.,

1971). In a landmark paper, Gass outlined many of the modern ideas of what he called idiopathic CSC (Gass, 1967), proposing that increased permeability of the choriocapillaris causes increased hydrostatic pressure in the choroid. This increased hydrostatic pressure in the choroid and hyperpermeability of the choriocapillaris gives rise to pigment epithelial detachments (PEDs) and defects in the RPE monolayer, allowing fluid to leak under the neuroretina. This differs from neovascularisation, in which PEDs occur due to leakage from newly formed vessels. Although many alternate theories were proposed, the concept of choroidal hyperpermeability was confirmed decades later with the introduction of indocyanine green angiography (ICGA) and optical coherence tomography (OCT) (Spaide et al., 1996b).

A population-based study in Olmsted County, MN, USA found that the annual age-adjusted incidence of CSC from 1980 through 2002 was 9.9 and 1.7 per 100,000 in men and women, respectively, in a predominantly Caucasian population (Kitzmann et al., 2008). A more balanced sex-based distribution was found in a population-base study from Taiwan, with an annual incidence of 54.5 men and 34.2 women per 100,000 corticosteroid users (Tsai et al., 2014). A South Korean cohort study of corticosteroid users and non-users found that the total incidence of CSC was 5.4 men and 1.6 women per 10,000 person-years (Rim et al., 2018). These discrepancies in the reported incidence of CSC may be due to methodological and/or ethnic differences. Nevertheless, the reported incidences may have been underestimated, as Kitzmann et al. excluded patients without fluorescein angiography (FA) data, and Tsai et al. and Rim et al. based their studies on insurance claims data from nearly all nationwide claims submitted by healthcare providers in Taiwan and South Korea, respectively. No significant differences in incidence rates and disease spectrum have been reported in a retrospective analysis between 15 African American and 59 Caucasians CSC patients (Desai et al., 2003). In Asians, however, pachychoroid disease such as polypoidal choroidal vasculopathy may be more prevalent than in Caucasians (Cheung et al., 2018).

Multimodal imaging is essential in order to accurately diagnose CSC. Using a combination of FA, ICGA, OCT, and fundus autofluorescence (FAF) allows the practitioner to distinguish between CSC and other conditions with overlapping clinical features. Using OCT, the presence of SRF can be both assessed and quantified, which is generally considered useful for estimating the episode duration and for determining the subsequent treatment strategy (Song et al., 2012). Moreover, FAF imaging can help estimate the duration of the CSC episode and the damage induced by CSC, and can also help determine the appropriate treatment strategy (Lee et al., 2016; Spaide and Klancnik, 2005). The combination of OCT, FA, ICGA, and OCT angiography can be used to detect subretinal neovascularisation, which may be challenging to conclusively confirm (Borrelli et al., 2018).

### 1.1. Clinical characteristics of CSC

Several subtypes of CSC have been proposed, but these are still subject to debate, and there is currently no universally accepted classification system for CSC (Daruich et al., 2015; Nicholson et al., 2013; Singh et al., 2018). This debate is based largely on the variable course of the disease and discrepancies with respect to the classification of CSC among ophthalmologists (Singh et al., 2018). Many authors use a basic distinction between acute CSC (aCSC) and chronic CSC (cCSC) based on the duration of SRF and the structural changes visible on multimodal imaging (Cardillo Piccolino et al., 2005; Guyer et al., 1994).

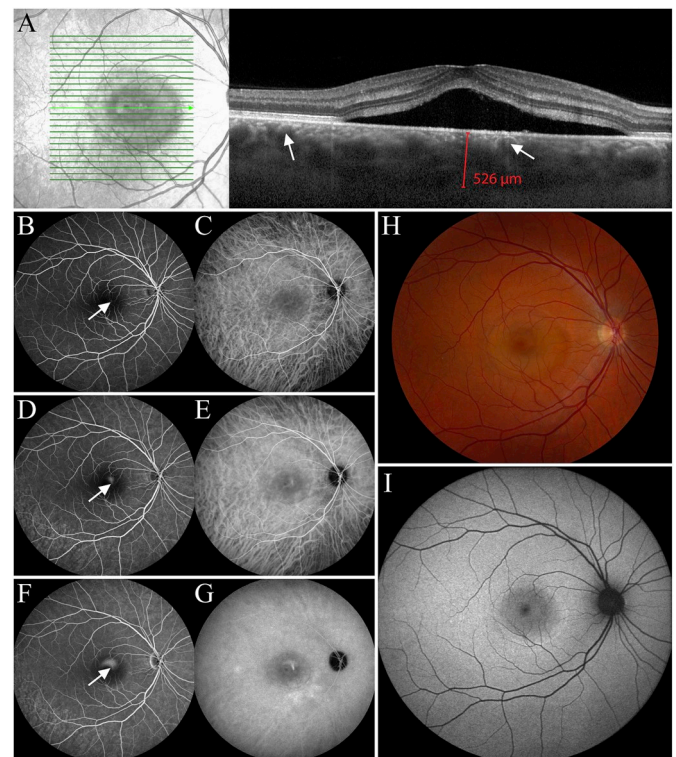
Although the serous detachment in aCSC usually resolves within 3–4 months without the need for treatment, the detachment tends to persist

in cCSC, and the chronic presence of SRF commonly leads to permanent structural damage in the neuroretina and RPE, with irreversible long-term vision loss (Laatikainen, 1994; Loo et al., 2002; Mrejen et al., 2019; von Wining et al., 1982). In the aCSC/cCSC classification system, aCSC usually presents with one – or just a few – focal leaks and produces an isolated dome-shaped neuroretinal elevation (not to be confused with a dome-shaped RPE-detachment), with few atrophic changes in the RPE. In contrast, patients with cCSC can present with a large number of leaks, and the chronic leakage of SRF tends to produce a larger, less elevated neuroretinal detachment. However, some patients with CSC present with one or several leaks that last more than 4 months but are not associated with widespread RPE changes, a shallow detachment, or decreased visual acuity. It is therefore debatable whether this clinical subgroup should be classified as aCSC or cCSC. Given this wide clinical variability and overlap, progress towards a new classification system has been slow; however, reaching a consensus regarding the classification of CSC is an important first step towards better defining the disease subgroups and treatment endpoints. The subcategories that have been proposed include non-resolving CSC, recurrent CSC, and inactive CSC (Daruich et al., 2015), as well as severe CSC based on multimodal imaging (Mohabati et al., 2018b, 2018c). Patients with a single point of leakage are considered to have focal leakage, whereas patients with several focal leakage points or ill-defined areas of dye leakage on FA can be categorised as having diffuse leakage (Gass, 1967). A focal leakage point on early FA typically increases in size with indistinct borders in the late phase of FA due to the leakage of fluorescein through the focal defect in the RPE. This focal area often co-localises with a dome-shaped RPE detachment and is presumed to be the point of least resistance at the RPE outer blood-retina barrier due to damage by increased wall stress induced by an increase in the vascular pressure gradient from the choriocapillaris. As a result of this small tear in the RPE or focal outer blood-retina barrier defect, fluid can flow from below the RPE into the subretinal space.

It is important to create at least a basic distinction between the various clinical subtypes of CSC in order to define treatments, which can be used in study designs. In this review, we use the basic distinction between aCSC and cCSC, as this clinical distinction is the most widely used in the context of the natural history and treatment of CSC.

### 1.1.1. Acute CSC

Acute CSC is defined as an acute-onset, dome-shaped serous detachment of the neuroretina, with spontaneous complete resolution of the resulting SRF in 3–6 months together with a good visual prognosis (Daruich et al., 2015; Klein et al., 1974; Nicholson et al., 2013). Patients with aCSC often present with altered vision and hypermetropisation (Daruich et al., 2017). In a study involving 27 patients with CSC with an average follow-up of 23 months, SRF spontaneously resolved in all 27 patients within an average duration of follow-up of 3 months (Klein et al., 1974). In another study of 31 patients with aCSC, SRF completely resolved by 6 months of follow-up in 84% of patients (Daruich et al., 2017). However, SRF has been reported to recur in up to 52% of patients (Ficker et al., 1988; Fok et al., 2011; Yap and Robertson, 1996). More importantly, even in patients who had SRF for only a short period of time, CSC can lead to irreversible damage to photoreceptors; thus, treatment may also be indicated in aCSC cases (Baran et al., 2005; Behnia et al., 2013; Hata et al., 2013). Interestingly, some patients self-describe their disease duration as lasting only a few days, whereas fundus imaging may reveal evidence of prolonged disease; patient-reported disease duration may therefore be considered unreliable (Ooto et al., 2010a). Most studies reporting the spontaneous course of CSC were published before the availability of OCT, meaning that residual shallow detachments were difficult – or impossible – to identify at that time (Wang et al., 1999). Several risk factors for prolonged CSC duration have been identified at presentation, which may influence the decision regarding whether or not to treat. These risk factors include subfoveal choroidal thickness > 500  $\mu\text{m}$ , PED height > 50  $\mu\text{m}$ ,



**Fig. 1.** Multimodal imaging of a 34-year-old male patient diagnosed with acute central serous chorioretinopathy (A–I). The presence of foveal subretinal fluid overlying a thick choroid (526  $\mu\text{m}$ ) with pachyvessels (white arrows) can be detected on optical coherence tomography (OCT, A). On fluorescein angiography there is a focal area of hyperfluorescent dye leakage, which increases and ascends in the subretinal space to produce a ‘smoke stack’ leakage pattern with additional hyperfluorescent areas of choroidal vascular hyperpermeability (white arrows, B, D, F). On indocyanine green angiography there is a similar leakage pattern with additional hyperfluorescent areas of choroidal vascular hyperpermeability (G). The serous detachment seen on OCT (A) and colour fundus photography (H) has a hyperautofluorescent border on fundus autofluorescence (I).

presentation at 40 years of age or older (Daruich et al., 2017), and photoreceptor atrophy of the detached retina together with granular debris in the SRF on OCT (Wang et al., 2005). Patients who present with aCSC with large amounts of SRF may be more prone to photoreceptor loss compared to patients who present with relatively small amounts of SRF (Gerendas et al., 2018; Nair et al., 2012).

In aCSC, 1–3 focal leakage points are typically visible on FA. The classic features of aCSC on FA include a pinpoint hyperfluorescent RPE defect with an ascending area of hyperfluorescence over time, commonly referred to as a ‘smoke stack leakage’ (Fig. 1B, D, F). This pattern of leakage can be caused by a mechanical disruption in the RPE with choroidal heat patterns and molecular differences between the fluorescein dye and the fluorescein albumin conjugate, combined with gravitational forces that give rise to this characteristic pattern of fluorescein dye in the subretinal space. More commonly, an ‘ink-blot’ pattern of leakage occurs, in which the focal leak that appears during dye transit becomes poorly defined, as the dye leaks more slowly into the subretinal space through the RPE defect (Wang et al., 2008). Patients who present with a smoke stack leakage on FA may have a larger serous detachment compared to patients with an ink-blot leakage (Friberg and Campagna, 1989), which can result in increased metamorphopsia. The location of the focal leakage point is usually correlated with a micro-tear in the RPE (Yannuzzi et al., 2015). In aCSC, these defects occur in the absence of diffuse atrophic changes in the RPE (Daruich et al., 2015). In areas in which FA shows focal leakage, ICGA can reveal areas of choroidal vascular hyperpermeability, possibly

depending on whether the pore size is large enough to allow the escape of indocyanine green-bound plasma proteins. On the other hand, choroidal hyperpermeability does not always correspond to the hyperfluorescent area on FA (Yannuzzi et al., 2003). Indeed, the hyperfluorescent areas seen on ICGA are often more extensive than the hyperfluorescent areas on FA (Fig. 1B–G), which is believed to be due to the higher permeability of large choroidal vessels (Scheider et al., 1993; Spaide et al., 1996b). Hypo-autofluorescent abnormalities on FAF have also been found to correlate with areas of leakage on FA (Eandi et al., 2005), which may indicate the involvement of the RPE in the pathophysiology of CSC, as FAF reflects the structural and functional status of the RPE (Freund et al., 2013).

The volume of SRF can be quantified using OCT, and higher SRF volume may be associated with poorer best-corrected visual acuity (BCVA) (Nair et al., 2012). The presence of subretinal hyperreflective dots on OCT – which may represent macrophages that contain phagocytosed outer segments – can migrate progressively into the neuroretina in patients with a prolonged disease course (Spaide and Klancnik, 2005). However, subretinal hyperreflective dots can also represent plasma proteins from the choriocapillaris and inflammatory debris (Wang et al., 2005). OCT can reveal fibrin clots that result from fibrinogen leaking through a defect in the RPE (Yu et al., 2014). Although changes in choroidal haemodynamics have been observed in aCSC using laser speckle flowgraphy (Saito et al., 2015), subfoveal choroidal thickness does not appear to be correlated with the amount of SRF (Goktas, 2014). In contrast, SRF resolution and BCVA in patients with aCSC appear to be related to macular choroidal blood flow velocity, with flow velocity decreasing as aCSC resolves (Saito et al., 2013).

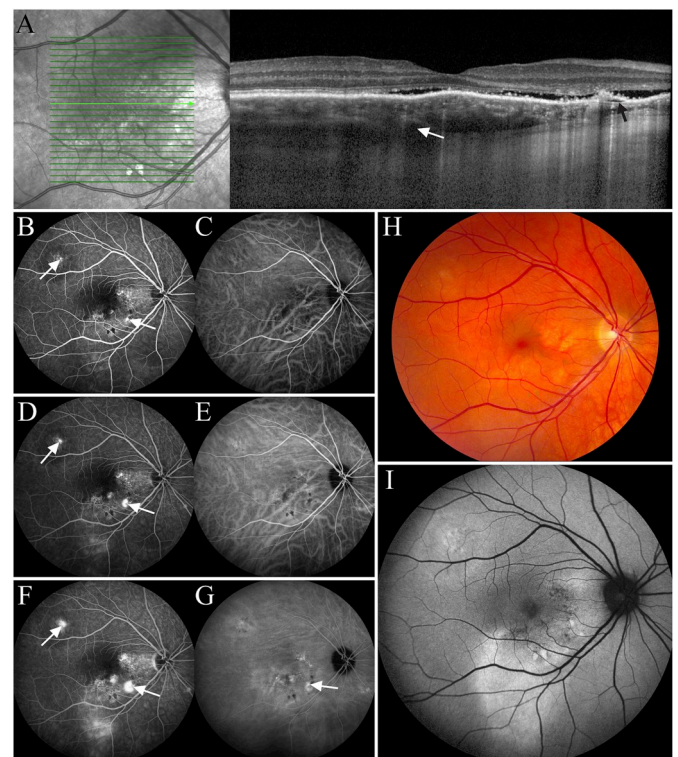
Non-resolving CSC has been described as a variant of aCSC in which SRF persists for more than 4 months without atrophic RPE abnormalities (Daruich et al., 2015). Moreover, recurrent CSC has been defined as an aCSC episode followed by one or more episodes after complete SRF resolution (Daruich et al., 2015).

### 1.1.2. Chronic CSC

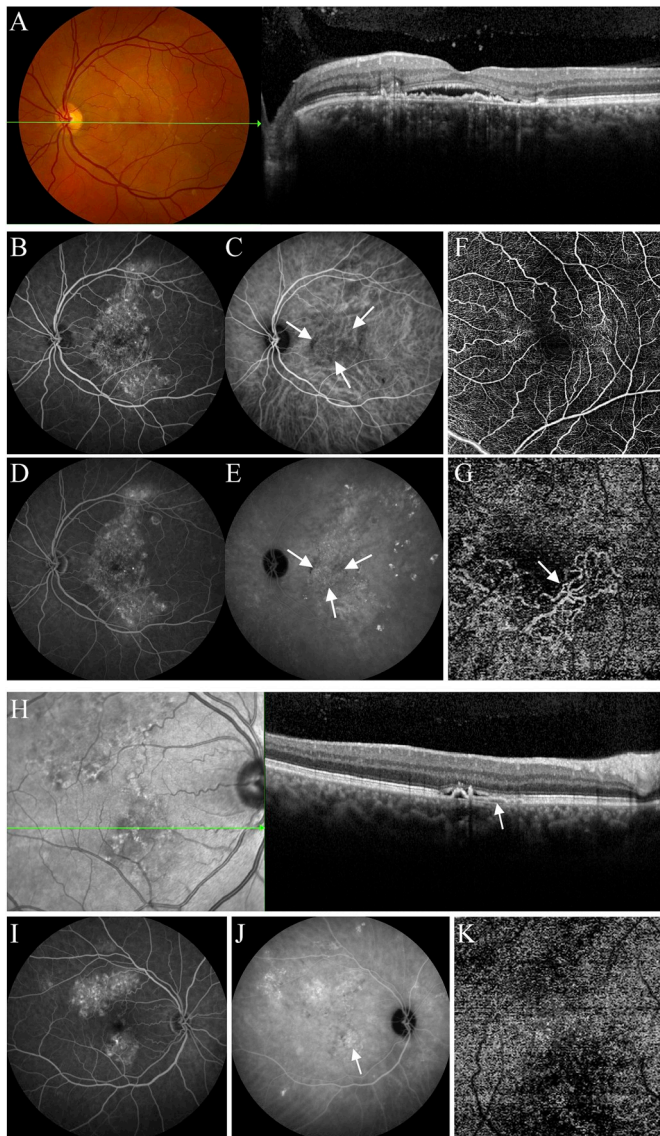
Chronic CSC is characterised by serous detachment of the retina, with either small or more extensive areas of serous detachment of the RPE, together with atrophic changes to the outer retina and RPE developing secondary to choroidal vasculopathy. On FA, one or more focal leakage points can be visible (Fig. 2B, D, F); alternatively, distinct points of leakage can be absent or difficult to identify against a background of irregular RPE translucency. Patients with cCSC typically have persistent serous detachment(s) on OCT for longer than 4–6 months (Daruich et al., 2015). Eyes with cCSC often have widespread ICGA abnormalities (Fig. 2G), including delayed choroidal filling, dilated choroidal veins, and/or choroidal vascular hyperpermeability (Pang et al., 2014). Relatively few patients with cCSC have a history of aCSC, which may indicate significant clinical differences between aCSC and cCSC. Interestingly, however, aCSC and cCSC share several genetic risk factors (Jalkh et al., 1984; Mohabati et al., 2018, 2018c; Otsuka et al., 2002; Yannuzzi et al., 1984) and possible pathophysiological overlap, particularly given similarities with respect to multimodal imaging (Imamura et al., 2009). In this respect, it is interesting to note that a retrospective study found that 50% of unspecified CSC patients developed atrophic changes in the RPE within 12 years of presentation (Castro-Correia et al., 1992). No marked clinical differences have been reported between cCSC patients with focal leakage and those diffuse leakage on FA, which may indicate that the choroid is the primary involved structure both in cCSC patients with focal and with diffuse leakage (van Rijnssen et al., 2019b).

Diffuse atrophic changes in the RPE and atrophic tracts may be the result of previous CSC episodes and the prolonged presence of SRF under the serous neuroretinal detachment, or it may be the result of an underlying choroidal dysfunction that directly affects the RPE, for example as seen in pachychoroid pigment epitheliopathy (Cheung et al., 2018; Mohabati et al., 2018b, 2018c) (Fig. 2). The term gravitational

tract is used to describe areas of RPE and photoreceptor outer segment atrophy, hyperfluorescence on FA, and mixed hyperautofluorescent and hypo-autofluorescent changes on FAF, which extend inferiorly of the prominent points of leakage. These tracts occur passively due to prolonged leakage and should not necessarily be targeted for treatment. The location of the accumulated SRF may be linked to the hyperfluorescent area on OCT (Montero and Ruiz-Moreno, 2005), and granular hypo-autofluorescence due to RPE atrophy may be present on FAF (Lee et al., 2016). The progression of the autofluorescence patterns in cCSC is slow, taking an average of 24 months for the granular hypo-autofluorescent changes to progress to a confluent pattern of hypo-autofluorescence (Zola et al., 2018a). When outer segment debris persists in the subretinal space, it becomes increasingly hyperautofluorescent (Spaide, 2008). In cases of cCSC with more marked and/or extensive atrophic changes in the RPE, patients often do not present with a dome-shaped PED (as in aCSC); rather, these patients present with a shallow, broader PED that – in some cases – can have an underlying neovascular component (Fig. 3). This neovascular component should be suspected in cases in which the space between the shallow PED and Bruch's membrane on OCT contains mid-reflective – presumably neovascular – material rather than being hyporeflective (Fig. 3A), which is more suggestive of sub-RPE fluid (Fig. 2). En face swept-source OCT and OCT angiography can be useful in identifying choroidal neovascularisation (CNV) without the use of conventional angiography (Fig. 3A, G) (de Carlo et al., 2015; Ferrara et al., 2014; Soomro and Talks, 2018).

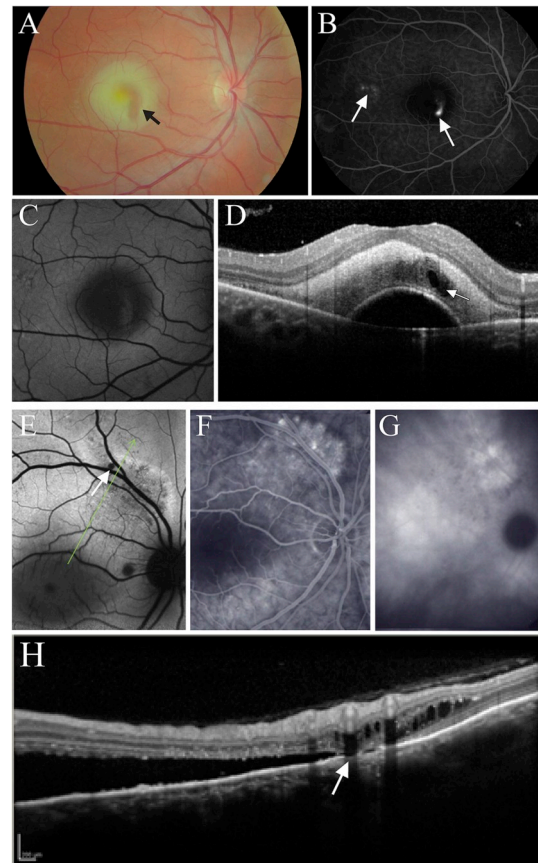


**Fig. 2.** Multimodal imaging of a 44-year old man with chronic central serous chorioretinopathy (A–G). Subretinal fluid, photoreceptor outer segment atrophy, a small retinal pigment epithelial detachment (black arrow), choroidal thickening, and dilated veins in Haller's layer (white arrow) are present on optical coherence tomography (A). Focal areas of hyperfluorescent leakage (white arrows) are seen at 1 min (B), 3 min (D), and 6 min (F) fluorescein angiography. Dilated choroidal vessels and choroidal vascular hyperpermeability (G, white arrow) are present on indocyanine green angiography (C, E, G). Colour fundus photography shows pigmentary abnormalities, some of which correspond to the areas of leakage seen on fluorescein angiography (H). Fundus autofluorescence shows mostly hyperautofluorescent abnormalities, which represent the retinal pigment epithelium atrophy track induced by chronic subretinal fluid (I).



**Fig. 3.** Imaging of a 59-year-old man with chronic central serous chorioretinopathy complicated by an occult neovascular membrane. The left eye (A–G) and right eye (H–K) are depicted. Retinal pigment epithelium alterations on fundus photography, accompanied by foveal subretinal fluid and a relatively flat, irregular retinal pigment epithelial detachment (PED) on optical coherence tomography can be observed (OCT, A). The space below the PED and above Bruch's membrane shows some greyish reflectivity, which could be suggestive of neovascular tissue. Leakage of fluorescein and diffuse retinal pigment epithelium alterations are present on fluorescein angiography (B, D). Indocyanine green angiography (ICGA) shows large hyperfluorescent areas suggestive of choroidal hyperpermeability (C, E), and a smaller macular area with a certain degree of demarcation that is suggestive of a neovascular membrane (delineated by three arrows in C and E). The optical coherence tomography angiogram of the superficial capillary plexus has a relatively normal appearance (F), but a neovascular network is clearly visible when segmentation is adjusted to cover the space between the retinal pigment epithelium and Bruch's membrane (G). In the fellow (right) eye, an extrafoveal, small dome-shaped PED with an attached small, flat PED with surrounding subretinal fluid is seen on OCT (arrow in H); which corresponds with an area of hyperfluorescence on ICGA (J). However, OCT angiography segmented for this area between the PED and Bruch's membrane does not show signs of neovascularisation (K).

Some cases of cCSC can be complicated by the accumulation of cystoid fluid, giving rise to a complication called posterior cystoid retinal degeneration (PCRD), in which the cystoid changes do not necessarily involve the central macula, as they are typically extrafoveal at



**Fig. 4.** Imaging of a 32-year-old man diagnosed with acute-onset central serous chorioretinopathy (A–D). Yellow-white subretinal fibrin can be observed on fundus photography (A), which is hyperreflective on optical coherence tomography (OCT) (D), with a roughly vertical sausage-shaped clear area (arrow in A), which corresponds to a small round hyporeflective zone on OCT (white arrow in D). This clear zone within the lesion on funduscopy and hyporeflective zone on OCT most likely corresponds to the upward leakage track originating from the focal leakage point on fluorescein angiography (right arrow in B). In addition, some mildly atrophic retinal pigment epithelial changes in the temporal macula (left arrow in B) also indicate a certain degree of advanced/chronic disease.

Multimodal imaging of a 46-year-old man with chronic central serous chorioretinopathy with posterior cystoid retinal degeneration (E–H). Multiple leakage points are visible on fluorescein angiography (F), along with hyperfluorescence on indocyanine green angiography (G). Posterior cystoid retinal degeneration is visible in E and H (at the location of the arrows). (For interpretation of the references to colour in this figure legend, the reader is referred to the Web version of this article.)

various locations in the posterior pole (Fig. 4E–H) (Cardillo Piccolino et al., 2008a; Mohabati et al., 2018c). Importantly, PCRD has been reported to cause a severe loss of central vision in some cases of CSC (Iida et al., 2003). The cystoid intraretinal spaces can be seen on OCT, but unlike typical cystoid macular oedema they do not stain on FA. PCRD is associated with cCSC symptoms that persist longer than 5 years (Cardillo Piccolino et al., 2008b). Foveal damage and vision loss can occur due to the intraretinal fluid itself, as well as the associated foveal detachment. In a study of 34 eyes with cCSC and PCRD, Cardillo Piccolino and colleagues found that visual acuity ranged from 20/20 to 20/400, with visual acuity of 20/40 or better in eyes in which the intraretinal fluid spared the foveal centre (Cardillo Piccolino et al., 2008a). Using OCT angiography, Sahoo and colleagues detected CNV in nearly half of the cases (13 out of 29 eyes) with cystoid macular degeneration (Sahoo et al., 2019). Patients with cCSC often experience a gradual decline in BCVA and contrast sensitivity due to damage to

macular photoreceptors (Breukink et al., 2017; Cardillo Piccolino et al., 2005; Ooto et al., 2010b; Spaide et al., 1996a); approximately 13% of these eyes progress to legal blindness, reaching a BCVA of 20/200 or worse after 10 years (Mrejen et al., 2019). This marked loss of visual acuity can be due to atrophic RPE changes at the central fovea together with photoreceptor damage, cystoid macular degeneration, and/or secondary CNV. Descending tracts are more frequent in cCSC compared to aCSC (Imamura et al., 2011). Although visual symptoms in cCSC usually present in only one eye, up to 42% of patients with cCSC show signs of bilateral abnormalities on FA (Gackle et al., 1998; Levine et al., 1989). Bilateral CSC is relatively more common in patients of 50 years or older, with a prevalence of 50% in this age group compared to 28% in patients under the age of 50 (Spaide et al., 1996a). Moreover, bilateral disease activity together with bilateral SRF accumulation is more common in cases with severe cCSC, affecting up to 84% of these patients (Mohabati et al., 2018c; Otsuka et al., 2002). These patients with bilateral severe cCSC are highly prone to develop severe visual impairment (Mohabati et al., 2018c; Mrejen et al., 2019). A rare yet severe manifestation of cCSC caused by many vigorous leaks is bullous retinal detachment, which commonly presents with the significant accumulation of subretinal fibrin. In some cases, bullous retinal detachment is accompanied by complete disruption of the edges of a PED, thereby producing an avulsion (i.e. rip or tear) in the RPE (Balaratnasingam et al., 2016).

### 1.2. Risk factors for developing CSC

On average, men are 2.7–8 times more likely to develop CSC compared to women (Haimovici et al., 2004; Tittl et al., 1999, 2003). The most important external risk factor for developing CSC is corticosteroid use, with an associated odds ratio of up to 37 to 1 (Haimovici et al., 2004). However, the precise effect of corticosteroid use on CSC risk is unclear, as lower odds ratios – in some cases, corresponding with only a slightly increased risk – have been reported in patients who use corticosteroids (Carvalho-Recchia et al., 2002; Rim et al., 2018; Tsai et al., 2014). An increase in choroidal thickness and features of CSC have been reported in 1 out of 18 patients after high-dose corticosteroid treatment (Han et al., 2014). In rare cases, even minimal exposure to corticosteroids via intranasal, inhalation, or extraocular application has been associated with an increased risk of CSC (Carvalho-Recchia et al., 2002; Haimovici et al., 1997). In 1987, Yannuzzi reported an association between CSC and type A behaviour, which has personality traits that include an intense, sustained drive to achieve self-selected goals and an eagerness to compete, along with a desire for recognition and advancement (Yannuzzi, 1987). Additional components that have been reported as being part of the ‘CSC patient profile’ include impulsiveness, a drive to overachieve, emotional instability, and hard-driving competitiveness, all of which have been hypothesised to affect the risk of CSC (Conrad et al., 2014). A stressful life event, shift work, poor sleep quality, and disturbances in the circadian rhythm have also been associated with an increased risk of CSC (Bousquet et al., 2016; Gelber and Schatz, 1987; Ji et al., 2018; Setrouk et al., 2016). Interestingly, individuals with type A behaviour are believed to have increased levels of corticosteroids and catecholamines (Williams et al., 1982), which may underlie their potentially increased risk of developing CSC. Moreover, many studies described an association between CSC risk and both stress and certain personality traits (Fok et al., 2011; Kim et al., 2018b; Lahousen et al., 2016; Matet et al., 2018). In contrast, a recent study involving 86 patients with cCSC found that the prevalence of maladaptive personality traits was similar between patients and a reference population (van Haalen et al., 2018). Various coping strategies have also been associated with CSC (Lahousen et al., 2016; van Haalen et al., 2018), and elevated psychological stress has been reported in CSC patients within a few weeks following the onset of ocular symptoms (Spahn et al., 2003). Moreover, psychosocial status has been correlated to the phase and subtype of CSC (Kim et al., 2018b), with CSC patients

having a lower quality of life, more psychological problems, and higher anxiety compared to healthy controls (Bazzazi et al., 2015; Sahin et al., 2014). A history of psychiatric illness has also been associated with an increased risk of recurrence in CSC cases (Fok et al., 2011). Nevertheless, quantifying and qualifying stress – and its association with CSC – will likely require large systematic studies including detailed psychometric assessments using suitable, validated questionnaires.

Endogenous hypercortisolism (i.e. Cushing's syndrome) has also been reported to increase the risk of developing CSC (Abalem et al., 2016; Bouzas et al., 1993; Carvalho-Recchia et al., 2002; Garg et al., 1997). In addition, several studies found increased levels of cortisol in the serum of patients with CSC patients, albeit without meeting the diagnostic criteria for Cushing's syndrome (Haimovici et al., 2003; Kapetanios et al., 1998; Zakir et al., 2009). CSC can be a presenting symptom in Cushing's syndrome, and SRF was reported to resolve in patients following surgery for treating Cushing's syndrome (van Dijk et al., 2016). In their endocrinological work-up of 86 patients with cCSC, Van Haalen and colleagues found elevated 24-h urinary free cortisol levels, indicating increased activity of the hypothalamic-pituitary-adrenal axis (van Haalen et al., 2018b); however, none of the patients in their study met either the clinical or biochemical criteria for Cushing's syndrome (van Haalen et al., 2018b). Pregnancy has also been associated with an increased risk of CSC along with hypertensive and vascular disorders (Sunness, 1988). This increased risk of CSC during pregnancy may be caused by hormonal changes that can induce vascular changes in the choroid. Although choroidal thickness does not appear to change during a healthy pregnancy, choroidal thickness can be increased in preeclampsia, and associated hypertension may also affect choroidal circulation (Kim et al., 2016). Choroidal hyperpermeability and stasis in the choroidal vessels, which may occur during preeclampsia, may also play a role in the development of CSC during pregnancy.

Patients in need of treatment with mitogen-activated protein kinase (MEK) inhibitors may develop a serous retinal detachment due to toxicity or autoantibodies (Urner-Bloch et al., 2014; van Dijk et al., 2015). These cases have been referred to as MEK inhibitor associated serous retinopathy (MEKAR). In contrast to CSC, no choroidal hyperpermeability is visible on ICGA in these patients, there is no increase in choroidal thickness, and no PEDs or focal leakage on FA are present (Francis et al., 2017; van Dijk et al., 2015). Between 20 and 65% of patients treated with MEK inhibitors may develop a serous retinopathy, with only a minority of these patients developing mild symptoms, which are usually transient, so discontinuation of this treatment for this reason is generally not required (Urner-Bloch et al., 2014; van Dijk et al., 2015).

Other risk factors associated with CSC include gastro-oesophageal disorders such as *Helicobacter pylori* infection, uncontrolled systemic hypertension, antibiotics, alcohol, allergic respiratory disease, high socioeconomic status, alcohol consumption, smoking, coronary heart disease, obstructive sleep apnoea, poor sleep quality, autoimmune disease, and hyperopia; in contrast, myopia was found to protect from CSC (Bagheri et al., 2017; Chatziralli et al., 2017; Daruich et al., 2015; Eom et al., 2012; Haimovici et al., 2004; Ji et al., 2018; Manayath et al., 2016; Matet et al., 2018; Tittl et al., 1999; Yavas et al., 2014). With respect to cardiovascular disease, the pathogenic mechanism for CSC may lie in general endothelial cell dysfunction (Wang et al., 2017).

Some studies reported a familial predisposition for CSC, which suggests that CSC may have a genetic component (Lin et al., 2000; van Dijk et al., 2019; Weenink et al., 2001). Recently, several single nucleotide polymorphisms (SNPs) were associated with an increased risk of CSC. Some of these SNPs are located in genes involved in the complement system, including *CFH*, which encodes complement factor H (de Jong et al., 2015; Hosoda et al., 2018; Miki et al., 2014; Schellevis et al., 2018), the *C4B*, which encodes complement factor 4B (Breukink et al., 2015), and the *NR3C2* gene, which encodes nuclear receptor subfamily 3 group C member 2, a mineralocorticoid receptor (MR) (van

Dijk et al., 2017b). In addition, CSC has been associated with the genes that encode age-related macular degeneration susceptibility 2 (*ARMS2*) (de Jong et al., 2015), cadherin 5 (*CDH5*) (Schubert et al., 2014), vasoactive intestinal peptide receptor 2 (*VIPR2*) (Hosoda et al., 2018), and solute carrier family 7 member 5 (*SLC7A5*) (Miki et al., 2018; Moschos et al., 2016). Interestingly, a familial form of pachychoroid, possibly with an autosomal dominant inheritance pattern, has also been described (Lehmann et al., 2015), as well as an association with variants in the *CFH* and *VIPR2* genes in an Asian cohort (Hosoda et al., 2018). For a more detailed discussion regarding this topic, the reader is referred to Kaye et al. Progress in Retinal and eye Research 2019.

### 1.2.1. Risk of recurrence and disease progression

If untreated, 43–51% of patients with aCSC experience at least one recurrence (Ficker et al., 1988; Matet et al., 2018; Ozkaya et al., 2016; Yap and Robertson, 1996). In patients with untreated cCSC, the reported 1-year recurrence rate is 30–52% (Fok et al., 2011; Gilbert et al., 1984). Several risk factors have been identified for CSC recurrence and disease progression, including the use of corticosteroids, untreated hypertension, a thick subfoveal choroid, non-intense hyperfluorescence on FA, and shift work (Haimovici et al., 2004; Matet et al., 2018). Moreover, depression and anxiety disorders have been associated with an increased risk of recurrence in both aCSC and cCSC (Fok et al., 2011). Severe cCSC tends to be progressive, although treatment can slow the disease's progression and stabilise BCVA (Mohabati et al., 2018c; Otsuka et al., 2002). Interestingly, few patients who present with cCSC have a history of aCSC, which may indicate that in addition to having a different visual prognosis, different underlying disease mechanisms are likely involved in the aetiology and progression of the acute and chronic forms of the disease (Mohabati et al., 2018c).

## 1.3. Pathophysiology

### 1.3.1. Choroidal dysfunction

Based on clinical evidence and FA findings, Gass suggested back in 1967 that hyperpermeability and increased hydrostatic pressure in the choroid may induce damage to the RPE, subsequently giving rise to either a PED or SRF leakage through a defect in the RPE outer blood-retina barrier (Gass, 1967). The presence of choroidal hyperfluorescence on ICGA supports the hypothesis that choroidal dysfunction is the primary underlying pathogenic mechanism in CSC (Hayashi et al., 1986; Spaide et al., 1996b). Other changes in the choroid further support the notion that abnormalities in choroidal structure and function play a fundamental role in the development of CSC; these changes include increased choroidal thickness (Imamura et al., 2009), which can decrease after treatment (Maruko et al., 2010), dilated veins in the Haller layer, atrophy of inner choroidal layers, increased choroidal vascularity index (Agrawal et al., 2016), and dysregulation of choroidal blood flow (Cardillo Piccolino et al., 2018) (Figs. 1A and 2F and G). Pathological processes that contribute to the observed choroidal abnormalities can include choroidal stasis, ischaemia, autonomic dysregulation, inflammation, and abnormalities in the complement system (Gass, 1967; Schellevis et al., 2018). However, classic inflammation within the choroid does not likely play a role in CSC, as corticosteroids can induce or worsen the disease. The above-mentioned pathological processes can lead to damage of the RPE outer blood-retina barrier and RPE alterations including serous PED, hyperplasia, and atrophy, which can be detected on FA and FAF (Darwich et al., 2015; Levine et al., 1989; Spaide and Klanchnik, 2005). This hypothesis is supported by findings on OCT angiography, including increased signal intensity and thicker choriocapillaris vasculature (Chan et al., 2016). The choroidal thickness has been reported to vary over the day, which may lead to diurnal fluctuations in the amount of SRF that is present in CSC (Brown et al., 2009; Siegfried et al., 2019). Choriocapillary hypoperfusion has also been detected on OCT angiography in CSC cases, and this reduced perfusion may result in ischaemia in adjacent retinal tissues due to

insufficient oxygen delivery (Gal-Or et al., 2018; Rochepeau et al., 2018). This focal choriocapillary ischaemia – combined with adjacent hyperperfusion – can result in SRF leakage (Teussink et al., 2015). Choroidal vascular dysfunction is a key feature in theories explaining the pathophysiology of CSC, with RPE alterations being secondary to choroidal changes (Nicholson et al., 2013).

### 1.3.2. Retinal pigment epithelium (RPE) dysfunction

The RPE plays an important role in the pathophysiology of CSC (Marmor, 1988; Spitznas, 1986). Focal areas of leakage through RPE were hypothesised to underlie the accumulation of SRF in a study by Negi and Marmor who suggested that defects in the RPE lead to an outflow of SRF to the choroid (Negi and Marmor, 1984). However, as described in section 1.3.1, there is overwhelming evidence that defects in the RPE are presumably secondary to choroidal dysfunction, as the choroidal abnormalities are more extensive than – or at least as extensive as – the RPE abnormalities (Spaide et al., 1996b), and choroidal dysfunction has been well-described using ICGA, structural OCT, and OCT angiography (Spaide et al., 1996b; Teussink et al., 2015). Interestingly, RPE abnormalities can also be present in the unaffected eye in patients with unilateral CSC, despite an absence of SRF (Gupta et al., 2010; Warrow et al., 2013). Atrophy of the RPE is associated with a reduced choroidal permeability, seen as hypofluorescence on ICGA (Spaide et al., 1996b). This can be the result of progressive quiescence of the choriocapillaris after a long-lasting disease and chronic RPE atrophy, as the secretion of vascular endothelial growth factor (VEGF) from the RPE is required in order to maintain the normal structure and homeostasis of the choriocapillaris (Bhutto and Lutty, 2012). The resulting increased hydrostatic pressure in the choroid may lead to reduced RPE barrier function, resulting in an accumulation of SRF (Gass, 1967). This hypothesis is supported by findings following photodynamic therapy (PDT), measured using both ICGA and enhanced depth imaging OCT (Maruko et al., 2010; Yannuzzi et al., 2003). Apparently, secondary damage to the RPE can range from small focal lesions to extensive degeneration, which is sometimes referred to as either diffuse retinal pigment epitheliopathy or diffuse atrophic RPE alterations (Mohabati et al., 2018c; Polak et al., 1995; von Winning et al., 1982; Yannuzzi et al., 1984). An alternative theory to explain the pathogenesis of CSC posits that a focal loss of polarity of the RPE cells induces the active transport of SRF to the subretinal space (Spitznas, 1986).

### 1.3.3. Pachychoroid disease

CSC is considered part of the pachychoroid disease spectrum (Cheung et al., 2018). This spectrum encompasses several disease entities, all of which have common features that include a diffuse or focal increase in choroidal thickness, atrophy of the inner choroidal layers, dilated outer choroidal veins (i.e. 'pachyvessels'), and choroidal vascular hyperpermeability on ICGA (Cheung et al., 2018). According to the pachychoroid disease hypothesis, disease progression (or regression) can occur in multiple stages, yet many patients presumably never progress from the earlier stages to symptomatic advanced disease with visual impairment. In the earliest stage of the disease, uncomplicated pachychoroid, choroidal changes, and thickening of the choroid are present without visible RPE and/or neuroretinal changes, but the patient does not present with visual symptoms. In the second stage, referred to as pachychoroid pigment epitheliopathy, mild changes in the RPE appear (Warrow et al., 2013). In the third stage of pachychoroid disease progression, CSC (which itself encompasses its own disease spectrum, as discussed above), SRF leakage causes serous neuroretinal detachment, presumably resulting from an acutely or chronically dysfunctional outer blood-retina barrier due to underlying choroidal thickening, congestion, and dysfunction. The fourth stage in the pachychoroid spectrum is pachychoroid neovascularopathy, which can include a polypoidal vasculopathy component (Fig. 3) (Fung et al., 2012). Patients with pachychoroid neovascularopathy – either with or without a

**Table 1**  
Differential diagnosis of central serous chorioretinopathy.

Disease	Clinical characteristics and diagnosis	Treatment options	References
<b>Neovascular disease</b>	Age-related macular degeneration Macular subretinal neovascularisation in context of pachychoroid neovascularopathy Polypoidal choroidal vasculopathy	Intravitreal anti-VEGF injections and/or vitamin supplements Intravitreal anti-VEGF injections Intravitreal anti-VEGF injections and/or (full-setting) photodynamic therapy	Bergen et al. (2019); Mehta et al. (2018) Cheung et al. (2018); Pang and Freund (2015) Cheung et al. (2018a); Cheung et al. (2018); Coscas et al. (2015); Spaide et al. (1995); Yannuzzi et al. (1990) O'Keefe and Rao (2017); Shin et al. (2015)
<b>Inflammatory disease</b>	Vogt-Koyanagi-Harada syndrome Typical features on OCT and numerous central leakage points on FA, in some cases with serous inferior retinal detachment. At least 3 of the following findings: bilateral chronic iridocyclitis, posterior uveitis, neurologic signs, cutaneous signs. May present in 4 phases: prodromal, acute uveitic, convalescent, and chronic recurrent phase. Extraocular manifestations may include tinnitus, hearing loss, vertigo, meningismus, poliosis, and vitiligo (Placoid) subretinal lesions on funduscopy, FA, and OCT, female predominance	Corticosteroids, DMARD Local and/or oral corticosteroids, DMARDS	Birnbaum et al. (2010)
<b>Ocular tumours</b>	White dot syndromes (e.g. acute posterior multifocal placoid pigment epitheliopathy) Solid tumours: choroidal naevus and melanoma Vascular tumours: choroidal haemangioma	Naevi: regular checks; melanomas may be treated with brachytherapy, proton therapy, or enucleation based on staging Photodynamic therapy	Higgins et al. (2016); Shields et al. (2018) Rahman et al. (2013); Shields et al. (2001)
<b>Haematological disorders</b>	Waldenström macroglobulinemia Primary B-cell lymphoma of the choroid	Chemotherapy, radiotherapy, bone marrow transplantation External beam radiotherapy, intravitreal methotrexate, rituximab	Baker et al. (2013); Thomas et al. (1983) Arias et al. (2013)
<b>Genetic diseases</b>	Leukemia Best disease and autosomal recessive bestrophinopathy due to <i>BEST1</i> gene mutations	Chemotherapy, steroids, radiation therapy, stem cell transplantation No treatment available	Malik et al. (2005); Moulin et al. (2010) Boon et al. (2009); Boon et al. (2013)
<b>Ocular developmental anomalies</b>	<i>RPL11</i> -associated occult macular dystrophy Optic disc pit Dome-shaped macula Tilted disc with inferior staphyloma	No treatment available Treatment is controversial; juxtapapillary laser photocoagulation, vitrectomy	Takahashi et al. (2014) Jain and Johnson (2014)
<b>Medication-related disease</b>	MEK inhibitor associated serous retinopathy (MEKAR)	No good evidence on effective treatment No good evidence on effective treatment Observation	Caillaux et al. (2013) Cohen et al. (1998); Nakanishi et al. (2008) Umer-Bloch et al. (2014); van Dijk et al. (2015)

DMARD, disease-modifying antirheumatic drugs; FA, fluorescein angiography; ICGA, indocyanine green angiography; MEK, mitogen-activated protein kinase; OCT, optical coherence tomography; OCTA, optical coherence tomography angiography; RPE, retinal pigment epithelium; SRF, subretinal fluid; VEGF, vascular endothelial growth factor.

polypoidal component – can present with serous SRF without having a history of CSC.

It should be noted the term ‘pachychoroid’ literally means ‘thickened choroid’, and is therefore rather non-specific. Whether or not a choroid can be considered thickened is subject to debate and can depend strongly on a variety of factors such as refractive error, associated axial length, and time of day (Brown et al., 2009; Ikuno et al., 2010). Many patients with a relatively thickened choroid will never develop clinically relevant abnormalities such as pachychoroid pigment epitheliopathy or CSC. Conversely, some patients develop typical CSC despite having choroidal thickness within the normal range. Most CSC patients, however, have a significantly increased choroidal thickness in the affected eye, with only 5 out of 28 unspecified CSC eyes in a retrospective study having a choroidal thickness below 400  $\mu\text{m}$  (Cheung et al., 2018; Imamura et al., 2009). Pachychoroid is associated with hyperopia, and CSC is extremely rare in myopic patients (Ersoz et al., 2018; Manayath et al., 2016); however, typical CSC can still also occur in emmetropic – and even myopic – patients with choroidal thickness within the ‘normal’ range, if the choroid is relatively thickened and dysfunctional. Therefore, a thickened (or relatively thickened) choroid is an important risk factor for CSC, but the actual dysfunctional, congestive, ‘leaky’ properties of such a choroid may be at least as important in the actual disease progression within the pachychoroid spectrum.

#### 1.4. Differential diagnosis

The differential diagnosis for CSC encompasses a broad range of disease categories that should be taken into account when confronted with serous neuroretinal detachment or a clinical picture suggestive of such a detachment. The most common diseases in the differential diagnosis of CSC include diseases associated with macular neovascularisation, such as AMD and polypoidal choroidal vasculopathy. In order to differentiate between these diseases and CSC, one should obtain OCT, OCT angiography, FA, and ICGA imaging. Retinal drusen are a distinctive feature of AMD, while polypoidal lesions on OCT, OCT angiography, FA, and especially ICGA are typical for polypoidal choroidal vasculopathy. Other diseases in the differential diagnosis of CSC include inflammatory ocular diseases, ocular tumours, haematological diseases, genetic retinal diseases, ocular developmental anomalies, and medication-induced disease. An overview of these diseases is given in Table 1. An in-depth discussion of these differential diagnoses is beyond the scope of this review; therefore, the reader is referred to Kaye et al. Progress in Retinal and Eye Research 2019.

## 2. Treatments for CSC

Defining an optimal treatment for CSC is complicated by the broad range of disease presentations and clinical course, as well as the poorly understood pathophysiology of CSC, and lack of consensus on a classification system (Mehta et al., 2017; Singh et al., 2018). Because of the relatively favourable visual prognosis for patients with CSC, the preferred treatment modalities should have a favourable safety profile. Most studies published to date analysed retrospective data and varied with respect to their inclusion and exclusion criteria, clinical definitions, and study endpoints (van Rijnssen et al., 2018a). The only large, prospective multicentre randomised controlled treatment trial for the treatment of cCSC conducted to date is the PLACE trial (van Dijk et al., 2018b). This trial compared differences in percentage of patients with complete resolution of SRF, BCVA, retinal sensitivity on microperimetry, and in the 25-item National Eye Institute Visual Function Questionnaire (NEI-VFQ-25) score between cCSC patients treated with either half-dose PDT or HSML. Additional large, prospective, randomised controlled trials performed over a defined treatment period are particularly important for CSC, given the relatively high likelihood of either spontaneous improvement or resolution of the serous neuroretinal detachment. If the study design is not appropriate – in particular,

lacking a suitable control group – spontaneous improvement may cause the researcher to erroneously conclude that the treatment was effective. Given the range of interventions used for treating CSC (discussed in detail below), it should be obvious that the high rate of spontaneous improvement in CSC may explain the fact that non-systematic, non-prospective, non-randomised testing of a wide range of interventions has yielded many promising findings that have never been replicated satisfactorily.

#### 2.1. Aims of treatment

The aim of treatment for CSC is to preserve the outer neurosensory retinal layers and achieve complete resolution of the serous neuroretinal detachment and the underlying SRF, as even a small amount of remaining SRF can lead to irreversible damage to the photoreceptors (Haga et al., 2017; Loo et al., 2002; van Rijnssen et al., 2018a). It is therefore commonly accepted that complete elimination of SRF, in order to restore normal anatomical and functional photoreceptor-RPE interaction, should be the principal surrogate endpoint in intervention trials regarding CSC. Following restoration of the photoreceptor-RPE anatomy, visual symptoms usually decrease gradually and BCVA improves (van Rijnssen et al., 2018a). Even with anatomically successful treatment, the persistence of visual sequelae due to pre-existing irreversible retinal damage is relatively common; therefore, a meticulous clinical history should be obtained from the patient prior to treatment (Wong et al., 2004). These persistent visual symptoms can include suboptimal visual acuity, metamorphopsia, and loss of contrast and/or colour vision. Another important aim of treatment is to prevent recurrences and subsequent disease progression.

Although an important question is whether the risk of recurrence is associated with any particular treatment(s), insufficient evidence is currently available. In aCSC, which has a relatively high rate of spontaneous resolution, an effective treatment should ideally prevent recurrences and subsequent disease progression. In cCSC, the primary aim of treatment is currently to achieve – and maintain – the complete resolution of SRF and intraretinal fluid (if present). In addition, other factors such as subjective symptoms, the patient's age, and the patient's professional dependence on high visual acuity, may be taken into account. Young patients with CSC generally have a higher cumulative lifetime risk of recurrence compared to older patients, given their longer life expectancy. On the other hand, older patients with CSC have a higher risk of developing neovascularisation and/or polypoidal choroidal vasculopathy.

While complete resolution of SRF should be the principal surrogate endpoint for trials on CSC, this may not be the case in AMD patients with accompanying SRF. In AMD patients with SRF, the BCVA may be relatively preserved and complete resolution of the SRF may not be required to still maintain a relatively favourable BCVA (Dagostar et al., 2009; Jang et al., 2015). However, CSC and AMD are different disease entities with potentially different types of and rates of leakage and a different composition of the SRF. Prolonged SRF can lead to irreversible damage to the photoreceptors (Loo et al., 2002), and a subgroup of cCSC patients can still have a significantly affected vision-related quality of life due to vision loss in progressive disease (Breukink et al., 2017), and may even become legally blind (Mrejen et al., 2019).

#### 2.2. Elimination of risk factors

Regardless of the subtype of CSC, it is important to identify whether the use of corticosteroids or the presence of other risk factors is associated with CSC. Thus, patients may be advised to discontinue the use of all forms of corticosteroids (including topical and inhaled medication) provided that their general health permits (Loo et al., 2002). Patients with CSC should be referred to an endocrinologist if they present with symptoms indicative of Cushing's syndrome, including facial rounding, truncal obesity, and the presence of a dorsal fat pad (van Haalen et al.,

2018b). In this respect, it is important to be aware that the signs and symptoms associated with Cushing's disease can be very subtle, and CSC can even be a presenting feature of this disease (van Dijk et al., 2016). Whether the patient is – or might be – pregnant should be discussed with women of childbearing age who present with CSC. The possibility of eradication of *Helicobacter pylori* infection is described in paragraph 2.3.7.6. Reduction of emotional stress, treating anxiety, a healthy diet, and enough sleep may be advised, although there is no strong evidence of positive effects with regard to CSC in this respect.

### 2.3. Treatment options

#### 2.3.1. Laser photocoagulation

Traditionally, the treatment of choice for CSC has been focal continuous-wave thermal laser treatment (Leaver and Williams, 1979), typically with an argon or diode laser, but also with a krypton or xenon laser (Nicholson et al., 2013; Novak et al., 1987); with the diode laser being superior to argon laser in terms of BCVA outcome (Verma et al., 2004). This method of laser treatment targets the focal leakage point(s) measured on FA and attempts to close the focal defect in the outer blood-retina barrier by applying photocoagulation to the affected area of the RPE. Laser photocoagulation should be limited to extrafoveal leakage sites, as vision loss, scotoma, reduced contrast sensitivity, and/or CNV can occur at the treated area (Daruich et al., 2015; Gemenetzi et al., 2010). Although thermal laser treatment can reduce the duration of SRF, the final BCVA does not differ significantly compared to no treatment (Robertson, 1986; Robertson and Ilstrup, 1983). Laser coagulation treatment has been shown to reduce the prevalence of SRF recurrence to 0 out of 29 treated eyes (compared to 7 out of 16 untreated eyes); moreover, treatment reduced the time until complete resolution to an average of 1 month (compared to 19 months for untreated eyes) (Burumcek et al., 1997). It should be noted that the 1997 study by Burumcek et al. was conducted before OCT became available. Recently, navigated laser photocoagulation was suggested as a safe and effective laser modality for treating CSC (Chhablani et al., 2014; Muller et al., 2018). Navigated laser photocoagulation integrates the information obtained using fundus photography and FA in order to identify the area to be treated; photocoagulation with a 532-nm laser is then performed automatically by computer at the marked area (Kozak et al., 2011). Although navigated laser photocoagulation of the focal leakage point on FA achieves complete resolution of SRF in 75–94% of patients with cCSC, functional outcome with respect to BCVA is inconsistent (Chhablani et al., 2014; Muller et al., 2018). A long-term prospective randomised trial comparing conventional argon laser photocoagulation with no treatment found no difference between the two groups with respect to recurrence rate, visual acuity, or Farnsworth-Munsell 100-hue test outcome (Ficker et al., 1988). Adverse events reported with laser photocoagulation include CNV at the treatment site (in 2 out of 25 patients) (Chhablani et al., 2016; Ficker et al., 1988). Finally, using photocoagulation to treat CSC does not change subfoveal choroidal thickness (Maruko et al., 2010). At this point it is difficult to decide if treatment with photocoagulation is warranted in CSC.

#### 2.3.2. Transpupillary thermotherapy

In the field of ophthalmology, transpupillary thermotherapy (TTT) was first described for treating choroidal melanoma (Oosterhuis et al., 1995). The goal of TTT is to induce a mild increase in temperature specifically in the area to be treated (for example, to 45–60 °C after 1 min of treatment for choroidal melanoma) (Journee-de Korver et al., 1992). This increase in temperature may activate a cascade of reactions that presumably involve the production of heat shock proteins that help to repair the damaged RPE cells and may also lead to choroidal vascular thrombosis (Desmettre et al., 2001). Several techniques have been developed for inducing ocular hyperthermia, including the use of microwave radiation (Lagendijk, 1982), localised current fields (Liggett et al., 1990), ultrasound (Coleman et al., 1986), and thermoseeds (Mieler

et al., 1989). The precise mechanism by which TTT is effective in treating CSC is unclear, but it may involve the induction of apoptosis in endothelial cells and/or vascular thrombosis, which may be useful for treating the underlying choroidal abnormalities in this disease (Wei and Yang, 2005). In CSC, TTT can be performed using an 810-nm pulse diode laser and for this disease it requires a shorter treatment duration (30–45 s) compared to the treatment of choroidal melanomas, as CSC does not involve active proliferation of the choroid (Hussain et al., 2006).

In a study by Hussain et al., 79% of patients with cCSC had a complete resolution of SRF three months after treatment, and 53% of treated eyes had an improvement of  $\geq 3$  lines of visual acuity (Hussain et al., 2006). In a case-control study involving 25 patients who received TTT and 15 observed patients, all of whom had a subfoveal leak, 96% of the treated patients had complete resolution of SRF within 3 months compared to only 53% of control-treated patients (Shukla et al., 2008). However, one eye in the treated group developed subfoveal CNV (Shukla et al., 2008). Manayath and colleagues performed 'graded' subthreshold TTT in 10 eyes with cCSC, initially using 60% of the threshold power; if the SRF persisted at 1 month, the power was increased to 80% of threshold for a second treatment session (Manayath et al., 2012). Using this protocol, the authors found that 8 of the 10 treated eyes (80%) had complete resolution of SRF on OCT and 5 (50%) of eyes had an improvement of BCVA by  $\geq 3$  lines. In a prospective study involving 25 patients with cCSC, Mathur and colleagues found that 52% of patients had complete resolution of SRF at 3 months after TTT (Mathur et al., 2009). In another study involving 5 patients who were treated with ICGA-guided TTT, complete resolution of SRF occurred in 2 patients (40%) at the 12-month follow-up visit (Giudice et al., 2011). In addition, Kawamura and colleagues studied 8 patients who had severe CSC together with bullous retinal detachment, several diffuse leakage spots, or fibrin formation and found complete resolution of SRF in 5 patients within 1 month of receiving TTT treatment (Kawamura et al., 2012). Manayath and colleagues studied 22 patients with cCSC who declined to undergo PDT and therefore underwent TTT (Manayath et al., 2017). The authors found a significant reduction in mean foveal thickness, but no significant difference in BCVA between patients who underwent TTT and patients who underwent PDT; interestingly, however, the patients who underwent TTT required more treatment sessions and had a longer interval until complete resolution of SRF compared to patients who underwent PDT. Finally, Russo and colleagues performed a prospective, randomised interventional pilot study involving 20 patients with cCSC who received TTT with a 689-nm laser at an intensity of 805 mW/m<sup>2</sup> for 118 s; all 20 patients had complete resolution of SRF when assessed 10 months after treatment (Russo et al., 2017). On rare occasions, side effects such as macular infarction may occur following TTT (Benner et al., 2002). Therefore, additional prospective randomised controlled trials are warranted in order to evaluate further the efficacy and safety of using TTT to treat CSC.

#### 2.3.3. Subthreshold micropulse laser

The use of a micropulse diode laser can induce more subtle effects in the outer retina compared to laser photocoagulation. Importantly, at the appropriate dose micropulse laser treatment can selectively target the RPE while preserving the photoreceptors and without causing visible tissue damage. Micropulse laser was first suggested as a viable option for treating macular oedema after retinal venous occlusion (Friberg and Karatza, 1997; Moorman and Hamilton, 1999), and in patients with diabetic retinopathy (Friberg and Karatza, 1997; Moorman and Hamilton, 1999). The first papers describing the use of subthreshold micropulse laser for CSC were published a decade later (Chen et al., 2008; Lanzetta et al., 2008). However, the mechanism of action underlying micropulse laser treatment is poorly understood, and large prospective, randomised controlled trials regarding micropulse laser treatment have not been performed, with the exception of the

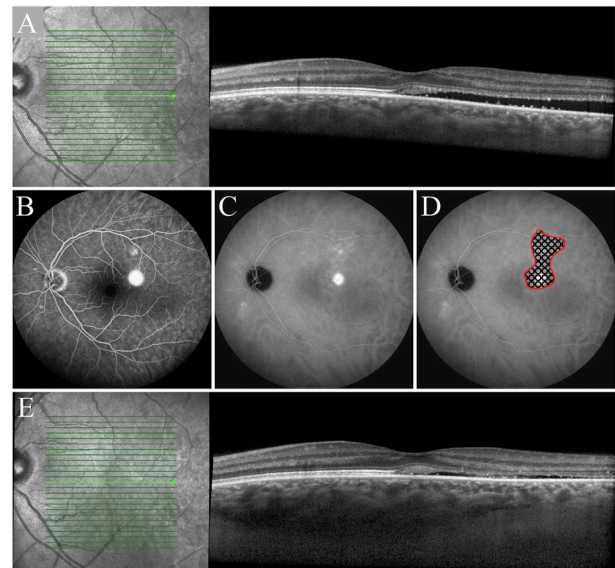
PLACE trial, which compared subthreshold micropulse laser treatment to half-dose PDT in patients with cCSC (van Dijk et al., 2018b). With subthreshold micropulse laser, photonic radiation is delivered to the retina in pulses lasting 0.1–0.5 s, each consisting of a ‘train’ of brief (100–300  $\mu$ s) laser pulses. This approach allows for the dissipation of heat between pulses and minimises collateral damage; thus, the temperature stays below the threshold for denaturing cellular proteins, and no laser burns are induced. Therefore, the subthreshold laser technique does not have any visible effects on the retina. With high-density subthreshold micropulse laser (HSML) treatment for CSC, the laser spots are targeted to the hyperfluorescent abnormalities on ICGA (and in some cases, FA) in a densely packed pattern, with adjacent non-overlapping spots focused on the designated treatment area (Luttrull, 2016; Malik et al., 2015; van Dijk et al., 2018b) (Fig. 5). The radiation is absorbed by chromophores in the RPE – primarily melanin – and is dissipated as heat (Sivaprasad et al., 2010). When applied in a sublethal dose, the treatment is believed to increase the expression of heat shock proteins, which may restore cellular function in the RPE (Sramek et al., 2011). Although no histopathological differences have been observed between micropulse laser application using 810 nm light compared to 532 nm light when measured in rabbits (Yu et al., 2013), the treatment's effects appear to differ between RPE cells of various sizes, shape, and pigmentation types (Pollack et al., 1998).

Several micropulse laser types and strategies have been investigated in interventional studies involving CSC, as summarised in Table 2. The wavelengths that have been used in micropulse laser treatment for CSC include 810 nm, 577 nm, 532 nm, and 527 nm (Ambiya et al., 2016; Arsan et al., 2018; Behnia et al., 2013; Chen et al., 2008; Kang et al., 2016; Yadav et al., 2015), and other adjustable laser settings include the duty cycle, power, spot size, and pulse duration. The duty cycle is defined as the ratio between the ‘ON’ time and the total (‘ON’ plus ‘OFF’) treatment time and ranges from 5% to 15% in various studies involving CSC patients (Breukink et al., 2016b; Maruko et al., 2017). The power setting of the micropulse laser determines the intensity of the laser and ranges from 90 mW to 1800 mW in published studies (Wood et al., 2017). The spot size refers to the size of each individual micropulse laser treatment spot and ranges between 100  $\mu$ m and 200  $\mu$ m (Ntomoka et al., 2018; Roca et al., 2018). Pulse duration (or pulse envelope) is the time interval between each new pulse cycle and ranges from 100 ms to 300 ms (Ambiya et al., 2016; Malik et al., 2015). Thus, to achieve a duty cycle of 5–15% with a pulse duration of 200 ms divided into 100 micropulses, the ‘ON’ time of the micropulse laser per 2 ms micropulse will be 0.1–0.3 ms (Abd Elhamid, 2015). Theoretically, the energy can be delivered to the retina with more precision using a smaller spot size. The combination of various settings determines the ‘dose’ delivered to the retina, and this dose should be high enough to achieve a therapeutic effect, but should not be so high that RPE or neuroretinal damage is induced. To date, no large prospective randomised controlled trials have been performed to compare various micropulse laser protocols. To complicate the analysis further, many settings vary between protocols, including the laser wavelength, making it difficult to compare the results of different treatment studies and determine the feasibility of using HSML for CSC.

Several outcomes have been evaluated following HSML treatment, including retinal thickness (Koss et al., 2012; Kretz et al., 2015; Park et al., 2017), choroidal thickness (Arsan et al., 2018), resolution of SRF (Chen et al., 2008), decrease in SRF height on OCT (Arsan et al., 2018), retinal sensitivity on micropertimetry (Abd Elhamid, 2015), BCVA (Ambiya et al., 2016; Kim et al., 2015c; Roisman et al., 2013), and adverse events (Roca et al., 2018). Overall, 36–100% of patients with cCSC had complete resolution of SRF after HSML treatment based on retrospective studies and case series (Table 2) (Chen et al., 2008; Scholz et al., 2016, 2017). Scholz et al. used ICGA-guided 577 nm HSML treatment in 42 eyes and found that a second treatment was required in 41% of cases at the 6-week follow-up visit (Scholz et al., 2016). Although the authors did not report the percentage of patients who

achieved complete resolution of SRF after this second HSML treatment, 74% of patients had a decrease in central retinal thickness of  $\geq 20$   $\mu$ m after the second treatment (Scholz et al., 2016). The mean follow-up time of 26 eyes with cCSC in a study by Chen and colleagues was 9.5 months, and the authors performed up to three FA-guided subthreshold micropulse laser treatments using an 810 nm laser; they found that 13 out of 26 patients (50%) achieved complete resolution of SRF after these micropulse laser treatments (Chen et al., 2008). In the PLACE trial, the only large prospective, multicentre randomised controlled treatment trial studying HSML in cCSC conducted to date, complete resolution of SRF was achieved in only 14% and 29% of cases at 2 and 7–8 months, respectively, in the HSML group (van Dijk et al., 2018b). The rates of SRF resolution in the PLACE trial are lower than those reported previously by retrospective studies and smaller prospective studies regarding HSML in cCSC. This difference in outcome may be due to the retrospective nature and relatively small sample sizes of the previous studies, as well as possible differences in inclusion and/or exclusion criteria.

Micropulse laser treatment may be more effective in cCSC eyes with focal leakage compared to eyes with diffuse leakage (Chen et al., 2008). According to data from a PLACE trial subgroup consisting of 79 HSML-treated patients with cCSC with either focal or diffuse leakage on FA, 41% and 21% of patients with focal or diffuse leakage, respectively, had complete resolution of SRF at 7–8 months (van Rijssen et al., 2019). These findings suggest that HSML may be more effective in cCSC with focal leakage on FA. Nevertheless, a significantly higher percentage of patients with cCSC who were treated with half-dose PDT had complete resolution of SRF compared to the HSML-treated group, with rates of 75% versus 41%, respectively, among patients with focal leakage and 57% versus 21%, respectively, among patients with diffuse leakage (van Rijssen et al., 2019).



**Fig. 5.** Multimodal imaging of a 48-year-old man with chronic central serous chorioretinopathy, who was treated with high-density subthreshold micropulse laser (HSML). Optical coherence tomography shows subretinal fluid that includes the fovea (A). A clear area of focal leakage can be seen on fluorescein angiography (B). Mid-phase (10 min after injection) indocyanine green angiography (ICGA) shows hyperfluorescent areas (C). The area that was treated with HSML is depicted in D. A schematic illustration of the pattern of closely spaced laser spots (shown larger than the actual spot size that was used for HSML treatment) is depicted within the area delineated by the red line. The complete area of hyperfluorescence on indocyanine green angiography within the vascular arcades was treated with HSML laser. The subretinal fluid decreased but persisted after this treatment (E). (For interpretation of the references to colour in this figure legend, the reader is referred to the Web version of this article.)

**Table 2**  
Overview of micropulse laser treatment studies in central serous chorioretinopathy.

Study	CSC subtype	Study design	Mean age (years)	Laser	Settings	N	Follow-up (months)	Complete resolution of SRF (%) at final follow-up	Reported parameters and outcomes
Arora et al. (2018)	aCSC	Randomised controlled trial	35	810 nm infrared diode laser	Spot size: 125 µm, pulse envelopes: 100 × 300 µs micropulses, duty cycle: 15%	34 eyes	6	Not reported	Mean BCVA improved -0.56 LogMAR, mean contrast testing chart improved +0.51, mean SRF height decreased -239 µm, CMT decreased -99 µm <sup>a</sup> Mean BCVA improved -0.23 LogMAR
Behnia et al. (2013)	aCSC	Randomised controlled trial	39	532 nm green laser	Spot size: 100 µm, duration: 0.05 s, power: 80 mW, reduced with 20% until no visible burns	18 eyes	6	Not reported	Mean BCVA improved from 0.27 to 0.02 LogMAR in the 50% power group, and from 0.34 to 0.14 LogMAR in the 25% power group Mean BCVA improved +1 ETDRS letter, mean retinal sensitivity increased +2 dB
Zhou et al. (2019)	aCSC	Prospective, interventional, non-randomised, comparative case series	41	577 nm yellow laser	Spot size: 100 µm, duration: 200 ms, duty cycle: 5%	54 patients	3	83% (50% power group), 54% (25% power group)	Mean BCVA improved +13 ETDRS letters, mean CMT decreased -173 µm <sup>a</sup> Mean ETDRS BCVA improved +7 letters, mean CMT decreased -69 µm Mean BCVA increased +0.43 (Snellen), mean contrast sensitivity improved +0.49 dB, mean CMT decreased -119 µm <sup>a</sup> Mean BCVA improved from 20/80 to 20/40, mean CMT decreased -142 µm <sup>a</sup> Not reported within HSML-treated subgroup
van Dijk et al. (2018b)	cCSC	Open-label, multicentre, randomised controlled clinical trial	49	810 nm micropulse laser	Duty cycle: 5%, frequency: 500 Hz, duration: 0.2 s	90 patients (90 eyes)	8	29%	Mean BCVA improved from 0.44 to 0.37 LogMAR, mean SRF height decreased -139 µm Treatment response after HSML in 79% of the patients, mean CRT decreased -148 µm <sup>a</sup> Mean BCVA improvement: 0.06 LogMAR, mean CRT decreased -115 µm <sup>a</sup>
Roisman et al. (2013)	cCSC	Prospective, randomised, double-blind, sham-controlled pilot trial	40	810 nm micropulse diode laser	Spot size: 125 µm, duty cycle: 15%, duration: 300 ms	10 patients (10 eyes)	12	90%	(continued on next page)
Kretz et al. (2015)	cCSC	Randomised controlled trial	47	810 nm infrared diode laser	Spot size: 75–125 µm, duration: 300 ms, duty cycle: 15%	20 eyes (20 patients)	4	80%	
Arsan et al. (2018)	cCSC	Prospective study	43	577 nm supra 577Y subliminal laser	Spot diameter: 160 µm, duration: 20 ms, duty cycle: 5%	39 eyes (39 patients)	12	92%	
Ashraf et al. (2018)	cCSC	Prospective nonrandomised interventional case series	38	MC300 photocoagulator (532 nm)	Spot size: 100 µm, wavelength: 80–100 mW, duration: 0.15 s	20 eyes (20 patients)	3–7	75%	
Breukink et al. (2016b)	cCSC	Interventional prospective case series	48	810 nm diode laser	Power: ≤ 1800 mW, frequency: 500 Hz exposure time 0.2s, duty cycle: 5%	10 eyes	2–32	10%	
Ricci et al. (2009)	cCSC	Interventional prospective non-comparative case series	39	810 nm micropulse laser	Spot size: 112.5 µm, power: 500 mW	7 patients (7 eyes)	12	71%	
Roca et al. (2018)	cCSC	Multicentre, retrospective comparative study	44	Yellow micropulse laser	Spot size: 100–200 µm, duty cycle: 5%, power: 320–660 mW	92 patients (92 eyes)	12	92%	
Gawecki et al. (2017)	cCSC	Retrospective study	56	577 nm yellow micropulse	Spot size: 160 µm, power: 250 mW, exposure: 0.2 s, duty cycle: 5%	51 eyes	12	71%	
Park et al. (2017)	cCSC	Retrospective case series study	51	527 nm micropulse laser	Frequency: 100 Hz, pulse energy ramp with maximal 15 pulses	49 patients (50 eyes)	3	74%	
Scholz et al. (2016)	cCSC	Retrospective study	49	577 nm micropulse laser	Spot size: 160 µm, duty cycle: 5%, duration: 0.2 s	42 patients (42 eyes)	1.5	36%	
Scholz et al. (2015)	cCSC	Retrospective study	51	577 nm micropulse laser	Spot size: 160 µm, duty cycle: 5%, duration: 0.2 s	38 patients (38 eyes)	5	24%	

**Table 2 (continued)**

Study	CSC subtype	Study design	Mean age (years)	Laser	Settings	N	Follow-up (months)	Complete resolution of SRF (%) at final follow-up	Reported parameters and outcomes
Niomoka et al. (2018)	cCSC	Retrospective study	49	577 nm NAVILAS laser	Spot size: 100 µm, duty cycle: 5%, duration: 200 ms	20 patients (22 eyes)	6	59%	Mean BCVA improved +0.12 LogMAR
Ozmerit et al. (2016)	cCSC	Retrospective comparative case series	45	577 nm subthreshold yellow micropulse laser	Spot size: 160 µm, duty cycle: 5%, duration: 200 µs	15 eyes	≥ 12	80%	, mean CMT decreased -86 µm <sup>a</sup> Mean BCVA improved +4 ETDERS letters
Yadav et al. (2015)	cCSC	Retrospective analysis	49	577 nm yellow laser	Spot size: 200 µm, duration: 200 ms, duty cycle: 10%	13 patients (15 eyes)	2 (mean)	40%	, mean CMT decreased -149 µm <sup>a</sup> Median BCVA improved from 20/40 to 20/30. The average decrease in SRF height was 79%
Kang et al. (2016)	cCSC	Retrospective study	49	527 nm Nd:YLF laser	30 pulses per spot, pulse duration: 1.7 µs, pulse repetition: 100 Hz	12 eyes (12 patients)	≤ 12	75% (at 3 months after treatment)	Mean BCVA improved from 0.23 LogMAR at baseline to 0.14 at 3 months after treatment
Malik et al. (2015)	cCSC	Retrospective, interventional case series	Not mentioned	810 nm subthreshold micropulse laser	Power: 750-100mW, duration: 0.2-0.3 s, duty cycle: 5%	11 eyes (10 patients)	2-12	Not reported	Mean BCVA improved +6 ETDERS letters,
Kim et al. (2015c)	cCSC	Retrospective case series	44	577 nm subthreshold micropulse yellow laser	Spot size: 100 µm duration: 20 ms, duty cycle: 15%, energy: 250-350 mW	10 eyes (10 patients)	6-24 (8 mean)	Not reported	mean CMT decreased -97 µm <sup>a</sup> Mean BCVA improved from 0.21 LogMAR at baseline to 0.055 LogMAR at final visit,
Gawecki (2015)	cCSC	Case report	33	577 nm multispot laser	Spot size: 160 µm, power: 550 mW, duration: 0.2 s, duty cycle: 5%	1 eye	1	0%	Increased SRF, appearance of intraretinal fluid
Ambiya et al. (2016)	Nonresolving CSC	Prospective study	38	577 nm µs yellow laser	Spot size: 100 µm, 0.1 s exposure time, duty cycle: 5%	10 eyes (10 patients)	6	60%	Mean BCVA improved +3 ETDERS letters, mean low contrast visual acuity improved -0.13 LogMAR, mean retinal sensitivity improved +2 dB
Abd Elhamid, 2015	Nonresolving CSC	Prospective interventional noncomparative clinical study	36	577 nm subthreshold micropulse laser	Spot size: 200 µm, pulse envelope duration: 200 ms, micropulse duration 0.2 ms, duty cycle: 10%	15 eyes	6	Not reported	Mean BCVA improved +0.18 (Snellen), mean CMT decreased -126 µm <sup>a</sup> , mean contrast sensitivity improved +0.25 (Pelli-Robson sensitivity chart)
Chen et al. (2008)	Idiopathic CSC	Prospective, noncomparative, interventional case series	44	810 nm micropulse diode laser	Spot size: 125 µm, duration: 200 ms, 100 pulses of 300 µs over 2 ms, duty cycle: 15%	26 eyes (25 patients)	8	50%	BCVA: ≥ 3 lines gain (58%), mean CMT decreased -180 µm <sup>a</sup>
Ricci et al. (2004)	Recurrent CSC	Case report	35	810 nm diode laser	Envelopes of 500ms, duty cycle: 10%	1 eye (1 patient)	2	0%	After 8 weeks SRF was almost completely resolved in this patient
Koss et al. (2012)	CSC	Comparative, controlled, prospective study	51	810 nm infrared diode laser	Spot size: 125 µm, duration: 200 ms, duty cycle: 15%	52 eyes (52 patients)	10	87%	Mean BCVA changed from 16/16 to 2/16, mean CMT decreased -94 µm
Lanzetta et al. (2008)	CSC	Prospective study	47	810 nm micropulse diode laser	Spot size: 200 µm, power: 1-2W, duty cycle: 15%, duration: 0.2 s	22 patients (24 eyes)	3-36	75% (improved/resolved)	Median BCVA was 6/9.6 before treatment, and 6/7.5 at the end of follow up.
Lavinsky and Palanker (2015)	CSC	Prospective, nonrandomised, interventional case series	57	577 nm, PASCAL laser	Spot size: 250 µm, pulses: 15 ms, power: 90-150 mW	16 eyes (15 patients)	6	75%	Mean BCVA improved 12 ETDERS letters,
Beger et al. (2012)	CSC	Comparative, controlled, prospective study	51	810 nm micropulse	Spot size: 125 µm, duration: 200 ms, duty cycle: 15%	16 eyes	10	87.5%	mean CMT decreased -68 µm <sup>a</sup> Mean BCVA improved +6 ETDERS letters

(continued on next page)

Table 2 (continued)

Study	CSC subtype	Study design	Mean age (years)	Laser	Settings	N	Follow-up (months)	Complete resolution of SRF (%) at final follow-up	Reported parameters and outcomes
Maruko et al. (2017)	CSC	Retrospective study	47	577 nm micropulse yellow laser	Spot size: 200 µm, duration: 0.2 s, power: 140–200 mw, duty cycle: 15%	14 patients (14 eyes)	2	64%	Mean BCVA improved +0.02 Snellen, mean CRT decreased -136 µm <sup>a</sup> , mean SFCT decreased -10 µm Mean CMT decreased -258 µm <sup>a</sup>
Luttrull (2016)	CSC	Retrospective study	44	810 nm subthreshold micropulse laser	Spot size: 200 µm, duty cycle: 5%, duration: 0.15 s	11 eyes (11 patients)	1–45	100%	Improvement of BCVA in 3 patients, but remained stable in 2 patients
Gupta et al. (2009)	Both aCSC and cCSC	Retrospective case series	46	810 nm infrared diode laser	Spot size: 125 µm, pulse duration: 0.2 s, duty cycle: 15%	5 patients	6–24	80%	

aCSC, acute central serous chorioretinopathy; BCVA, best-corrected visual acuity; cCSC, chronic central serous chorioretinopathy; CMT, central macular thickness; CRT, central retinal thickness; CSC, central serous chorioretinopathy; ETDRS, Early Treatment of Diabetic Retinopathy Study Letters; FA, fluorescein angiography; HSML, high-density subthreshold micropulse laser; LogMAR, logarithm of the minimal angle of resolution; NAVLAS, navigated retina laser therapy; Nd:YLF, neodymium-doped yttrium lithium fluoride; OCT, optical coherence tomography; PASCAL, patterned scanning laser; PDT, photodynamic therapy; SFCT, subfoveal choroidal thickness; SRF, subretinal fluid.

<sup>a</sup> The methods to obtain CMT or CRT differed between studies. Some studies may have included the SRF in this measurement.

It has been suggested that performing HSML treatment directly after intravenous administration of indocyanine green may increase the selectivity for RPE cells (Ricci et al., 2004, 2009). During this procedure, patients receive an intravenous injection of 25 mg indocyanine green dissolved in 2 mL of a 5% glucose solution. After a brief waiting period of 15–20 min, patients undergo HSML treatment with an 810 nm laser. In a small prospective case series, 5 out of 7 patients with cCSC had complete resolution of SRF, and the amount of SRF was reduced in the other two patients within 8 weeks following treatment (Ricci et al., 2009). In summary, the efficacy of subthreshold micropulse laser treatment for cCSC can be improved by standardising the laser settings and understanding the mechanism of action, and additional prospective randomised clinical trials will help determine its feasibility as a treatment modality for CSC (Wood et al., 2017).

#### 2.3.4. Photodynamic therapy (PDT)

Although PDT was originally developed as a treatment for skin cancer, subsequent improvements in lasers and powerful light sources eventually paved the way for its introduction in the field of ophthalmology (Daniell and Hill, 1991; Miller and Miller, 1993; Miller et al., 1991, 1995; Yannuzzi et al., 2003). In PDT applications in ophthalmology, the benzoporphyrin derivate verteporfin is currently approved for use in treating retinal disease, as it has a high affinity for the RPE (Kramer et al., 1996; Ziemssen and Heimann, 2012). The high lysosomal activity in the RPE can lead to the binding of verteporfin to plasma low density lipoproteins, which bind to surface receptors of the cell membrane of vascular and reticuloendothelial cells (Schmidt-Erfurth and Hasan, 2000). However, compared to photocoagulation, the PDT-induced effects to the RPE are far less destructive (Schmidt-Erfurth and Hasan, 2000). The treatment effect of PDT in CSC is presumably based on the formation of free radicals upon illumination of the treatment site – specifically, the choriocapillaris – which leads to damage to the vascular endothelium and hypoperfusion, and subsequent remodelling of the vessels in the capillary bed underlying the damaged RPE. Because of the treatment's high selectivity, retinal photoreceptors are spared (Chan et al., 2003; Schlotzer-Schrehardt et al., 2002). In ophthalmology, PDT was originally developed for treating CNV secondary to AMD (Newman, 2016). After it was approved for use in treating AMD, verteporfin was soon used off-label in PDT for treating CSC, particularly cCSC. The studies that were performed to evaluate PDT in 50 or more patients with CSC are summarised in Table 3. Yannuzzi and colleagues were among the first groups to report PDT as a possible treatment strategy for cCSC (Yannuzzi et al., 2003). In the initial reports, verteporfin was used at the same dose as for neovascular AMD ('full-dose PDT', 6 mg/m<sup>2</sup>). Later, however, several reduced-intensity PDT regimens such as half-dose, half-fluence, and half-time PDT (see section 2.3.4.1) were developed in order to avoid a possible complication of profound angiographic closure that has been reported – albeit rarely – following PDT for neovascular AMD (see section 2.3.4.4.) (Alkin et al., 2014; Neves et al., 2016; Shin et al., 2011; Shiode et al., 2015).

Choroidal thickness can transiently increase immediately following PDT treatment for CSC. In one study, mean choroidal thickness increased to 119% of pre-treatment thickness in 8 eyes at 2 days after treatment (Maruko et al., 2010). This transient effect on choroidal thickness can be accompanied by a transient increase in the height of the serous neuroretinal detachment, and increased visual symptoms have been reported in up to 38% of treated patients measured up to 4 weeks after treatment (Maruko et al., 2010; van Dijk et al., 2018a). Changes in choroidal thickness and SRF height typically decrease within 1 week of treatment and stabilise at 1 month, and are often accompanied by a resolution of SRF, gradually improving visual acuity, and reduced visual symptoms compared to pre-treatment levels (Maruko et al., 2011; van Dijk et al., 2018b). After PDT treatment for unilateral CSC, choroidal thickness in the treated eye can decrease to the same choroidal thickness value as in the unaffected eye, resulting in

**Table 3**  
Overview of studies in which more than 50 patients with central serous chorioretinopathy were treated with photodynamic therapy (PDT).

Study	CSC subtype	Study design	Mean age (years)	PDT settings	N	Follow-up (months)	Complete resolution of SRF (%) at final follow-up	Reported parameters and outcomes
Zhao et al. (2015)	aCSC	Noninferiority, double-masked, randomised, controlled clinical trial	43	Half-dose or 30% dose	131 eyes (131 patients)	12	75% (30% dose group), 95% (half-dose group)	The mean BCVA improved from 75 to 83 ETDRS letters in the 30% dose group, and from 75 to 85 ETDRS letters in the half-dose group
van Dijk et al. (2018b)	cCSC	Open-label, multicentre, randomised controlled clinical trial	49	Half-dose	89 eyes (89 patients)	7–8 months	67%	Mean BCVA improved of +7 ETDRS letters and mean retinal sensitivity improved +3 dB
Lim et al. (2014)	cCSC	Retrospective case series	52	Full or reduced-setting	237 patients	Range of 1–12 months	81%	Post-PDT BCVA was correlated with baseline BCVA ( $r = 0.70$ , $p < 0.001$ )
Fujita et al. (2015)	cCSC	Retrospective, interventional case series with no controls	53	Half-dose	204 eyes (204 patients)	12	89%	Mean BCVA improved from 0.11 to $-0.01$ LogMAR ( $p < 0.0001$ )
Lai et al. (2016)	cCSC	Retrospective multicentre interventional case series	49	Half-dose	136 eyes (123 patients)	Mean of 58 months	97% (36 months after treatment)	The mean LogMAR BCVA improved from 0.36 to 0.15 at 36 months
Breukink et al. (2016a)	cCSC	Retrospective case-control study	55 (corticosteroid users), 54 (controls)	Half-dose or half-time	Corticosteroid users: 35 eyes (33 patients), controls: 88 eyes (84 patients)	Mean of 48 weeks in corticosteroid group, 50 weeks in control group	74% (corticosteroid group), 60% (control group)	Mean BCVA was comparable between the corticosteroid group and control (72 and 71 ETDRS letters, respectively)
Sheptulin et al. (2018)	cCSC	Retrospective case series study	49 (median)	Half-time	114 eyes (103 patients)	12	87%	Median improvement of LogMAR BCVA from 0.22 to 0.1 ( $p < 0.0001$ )
Ozkaya et al. (2016)	cCSC	Retrospective case-control study	52	Half-fluence	101 eyes (101 patients)	3	Not reported	With regard to OCT and FA findings there was no significant difference between responders and non-responders to PDT, for all of the evaluated findings ( $p > 0.05$ for all)
Ruiz-Moreno et al. (2010)	cCSC	Non-randomised, multicentre, interventional case series	46	Full-settings PDT	82 eyes (72 patients)	Mean of 12 months	100%	Mean LogMAR BCVA improved from 0.53 to 0.37
Haga et al. (2017)	cCSC	Retrospective observational case series	52	Half-dose	79 eyes (73 patients)	36	81%	LogMAR BCVA improved from 0.21 to 0.08 ( $p < 0.001$ )
Lai et al. (2015)	cCSC	Retrospective review of consecutive CSC patients	45	Half-dose	75 eyes	Mean of 69 months	93%	Mean BCVA improved from 0.35 to 0.14 at 3 years after treatment
Oh and Yu (2015)	cCSC	Retrospective, comparative interventional case series study	56 (full-fluence), 52 (half-fluence)	Full-fluence or half-fluence	Full-fluence: 25 eyes (25 patients), half-fluence: 43 eyes (43 patients)	Mean of 16 months	Not reported	SFCT decreased from 351 $\mu$ m (full-fluence) and 362 $\mu$ m (half-fluence) to 267 $\mu$ m and 318 $\mu$ m at 12 months, respectively
Roca et al. (2018)	cCSC	Retrospective comparative study	47	Half-dose	67 eyes	12	95%	Mean BCVA improved from 0.50 to 0.47 LogMAR ( $p = 0.89$ )
Alkin et al. (2014)	cCSC	Retrospective study	45 (low-fluence group), 44 (half-dose group)	Low-fluence or half-dose	Low fluence: 36 eyes (34 patients), half-dose: 28 eyes (26 patients)	Mean of 13 months	92% (low-fluence group), 93% (half-dose group)	Mean BCVA increased by 7 ETDRS letters in the low-fluence group, and by 5 ETDRS letters in the half-dose group
Chung et al. (2018)	cCSC	Consecutive series	51	Half-dose	61 eyes	3	88%	Mean BCVA improved from 0.47 to 0.31 LogMAR at 3 months ( $p < 0.001$ )
Shin et al. (2011)	cCSC	Retrospective comparison study	48 (half-fluence), 51 (full-fluence)	Full-fluence versus half fluence	60 patients	Mean of 13 months	94% (half-fluence), 100% (full-fluence)	There was no difference in final LogMAR BCVA between the 2 groups (0.17 versus 0.21; $p = 0.603$ )
Nicolo et al. (2014)	cCSC	Retrospective comparison study	49	Half-fluence versus half-dose	Half-fluence: 31 eyes (28 patients), half-dose: 29 eyes (28 patients)	12	84% (half-fluence group), 100% (half-dose group)	Mean LogMAR BCVA improved significantly ( $p < 0.001$ ), both in the half-fluence group (from 0.187 to 0.083, and in the half-dose group (from 0.126 to 0.068)

(continued on next page)

**Table 3 (continued)**

Study	CSC subtype	Study design	Mean age (years)	PDT settings	N	Follow-up (months)	Complete resolution of SRF (%) at final follow-up	Reported parameters and outcomes
Scholz et al. (2016)	cCSC	Retrospective study	53	Half-dose	58 eyes (58 patients)	6 weeks	21%	Mean CRT decreased $-76 \mu\text{m}^a$
Kim et al. (2015d)	cCSC	Retrospective study	47	Half-fluence or half-dose	57 eyes (52 patients)	Mean of 34 months	72%	Treatment with PDT resulted in a significant improvement in BCVA and a significant reduction in CMT and SFCT (all $p < 0.001$ )
Tseng and Chen (2015)	cCSC	Retrospective, interventional case series	45	Half-dose	56 eyes (56 patients)	Mean of 56 months	100% (at 12 months)	Mean LogMAR BCVA improved significantly from 0.36 to 0.13 at 6 months after treatment
Kim et al. (2015e)	cCSC	Retrospective study	47	Half-fluence or half-dose	52 patients	Mean of 21 months in the half-fluence group, and 22 months in the half-dose group	96%	Complete photoreceptor recovery, defined as a continuous ellipsoid zone with a discernible interdigitation zone, was observed in 19 (73%) and 14 patients (54%) in the half-fluence and half-dose groups respectively ( $p = 0.150$ )
Mohabati et al. (2018b)	Severe cCSC	Retrospective study	49 (severe cCSC), 47 (controls)	Half-dose or half-time	81 eyes (66 patients) in the severe cCSC group, 37 eyes (35 patients) in the control group	Mean of 90 weeks after PDT	88% in severe cCSC group, 95% in the control group	Mean BCVA improved in both groups, from 66 to 72 ETDRS letters in the severe cCSC group ( $p < 0.001$ ), and from 78 to 82 ETDRS letters in the control group ( $p < 0.001$ )
Liu et al. (2016)	aCSC or cCSC	Retrospective, comparative case series	46	FA-guided, half-dose or half-time PDT	61 eyes	Mean of 15 months	91% in the half-dose group versus 100% in the half-time group	Mean LogMAR BCVA significantly improved after both half-dose and half-time PDT

aCSC, acute central serous chorioretinopathy; BCVA, best-corrected visual acuity; cCSC, chronic central serous chorioretinopathy; CMT, central macular thickness; CRT, central retinal thickness; CSC, central serous chorioretinopathy; ETDRS, Early Treatment of Diabetic Retinopathy Study Letters; FA, fluorescein angiography, ETDRS, early treatment diabetic retinopathy study; LogMAR, logarithm of the minimal angle of resolution; OCT, optical coherence tomography; PDT, photodynamic therapy; SFCT, subfoveal choroidal thickness; SRF, subretinal fluid.

<sup>a</sup> The methods to obtain CMT or CRT differed between studies. Some studies may have included the SRF in this measurement.

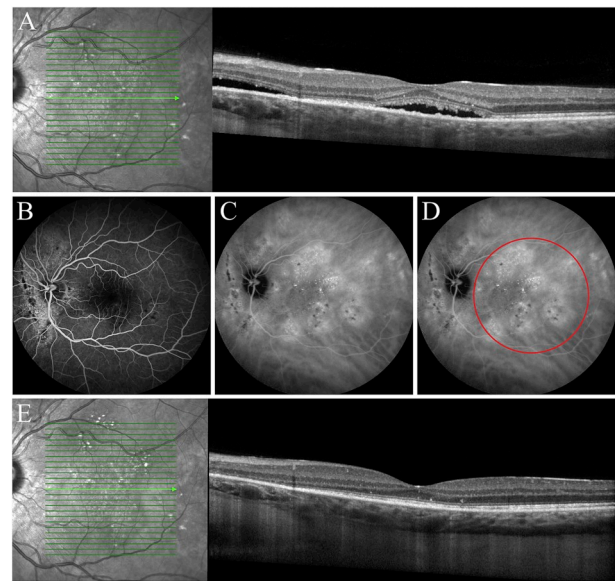
no significant difference in choroidal thickness between the two eyes (Pryds and Larsen, 2012). This finding suggests that PDT reduces the choroidal vascular hyperpermeability and thickening that play a key role in the pathogenesis of CSC (Izumi et al., 2017; Maruko et al., 2010).

**2.3.4.1. Treatment algorithms and mode of action.** The efficacy of using PDT with verteporfin relies upon the proper selection of the target area to be irradiated with a circular spot of light. A common selection strategy is to set the centre and diameter of this spot so that it covers the area of hyperfluorescent abnormalities on mid-phase ICGA and the corresponding point(s) of leakage on FA and OCT, as this is the apparent point of origin for the SRF (van Dijk et al., 2018b; Yannuzzi et al., 2003) (Fig. 6). In preparation for the procedure, the pupil of the eye to be treated is first dilated using a mydriatic agent. Subsequently, either 6 mg/m<sup>2</sup> (for full-dose PDT) or 3 mg/m<sup>2</sup> (for half-dose PDT) verteporfin (Visudyne®; Novartis, Basel, Switzerland or Bausch & Lomb, Rochester, NY, USA) is delivered via an intravenous infusion over a 10-min time course. Within 10–15 min after the start of the verteporfin infusion, an anaesthetic eye drop (e.g. oxybuprocaine 0.4%) is administered to the eye to be treated, and a contact lens – typically, a 1.6x magnification PDT lens – is positioned on the cornea. Light at 689 nm is then applied to the area to be treated at a fluence of 50 J/cm<sup>2</sup> for 83 s. Alternatively, half-fluence (25 J/cm<sup>2</sup>) PDT can be used, with a full dose of verteporfin (6 mg/m<sup>2</sup>) and full treatment duration (83 s). A final option is half-time PDT, which uses full-dose verteporfin (6 mg/m<sup>2</sup>), full fluence (50 J/cm<sup>2</sup>), and a treatment duration of 42 s. Patients should be advised to avoid exposure to direct sunlight and other sources of UV radiation for 48 h after receiving half-dose PDT, and this period of time should be increased or decreased accordingly based on the verteporfin dose.

Half-dose PDT has been reported to be as effective as – or superior to – full-dose, half-fluence, and half-time PDT regimens with respect to both aCSC and cCSC. Because of the reduced risk of systemic side effects (see paragraph 2.6.4.), half-dose PDT is preferred in some treatment centres. Most studies of PDT for CSC involved patients with cCSC, in which the spontaneous resolution of SRF is less common than in aCSC (see section 1.1.1.). Alkin and colleagues found no significant difference in efficacy between half-dose PDT and half-fluence PDT in treating cCSC (Alkin et al., 2014). In contrast, Nicolo and colleagues reported that half-dose PDT group led to complete resolution more rapidly than half-fluence PDT, with 86% and 61% of patients with cCSC, respectively, reaching complete resolution of SRF at the 1 month follow-up point (Nicolo et al., 2014). In other studies, half-fluence PDT was found to be just as effective as full-fluence PDT in treating cCSC (Shin et al., 2011), and half-dose PDT was found to be just as effective as full-dose PDT in treating persistent CSC (Boni et al., 2012). Moreover, efficacy is similar between half-time PDT and half-dose PDT (Liu et al., 2016; Shiode et al., 2015). In a retrospective case series, Liu and colleagues compared half-dose PDT with full-fluence to half-dose PDT with half-fluence in patients with cCSC and found that complete resolution of SRF was achieved in 93% and 64% of cases, respectively, which was a statistically significant difference (Liu et al., 2014). In a study designed to determine the optimal verteporfin dose for PDT in treating aCSC, Zhao and colleagues tested a range of doses from 10% to 70% and found that 30% was the lowest effective dose (Zhao et al., 2009). Moreover, in their subsequent study, the same group found that half-dose PDT (i.e. with a 50% verteporfin dose) was superior to a 30% dose, with 95% of patients achieving complete SRF resolution, compared to only 75% of patients in the lower dose group (Zhao et al., 2015). In a different retrospective study involving 16 patients with cCSC, half-dose (3 mg/m<sup>2</sup>) PDT was found to be superior to one-third dose (2 mg/m<sup>2</sup>) PDT, with 100% cases achieving complete resolution of the serous neuroretinal detachment compared to only 33% in the one-third dose group (Uetani et al., 2012). Thus, PDT treatment using a one-third dose of verteporfin appears to be suboptimal with respect to achieving

complete resolution of SRF in CSC (Dang et al., 2014).

**2.3.4.2. PDT in acute CSC.** In patients with aCSC, PDT treatment can provide faster SRF resolution, more rapid recovery of retinal sensitivity (Casalino et al., 2016; Hagen et al., 2013), and higher BCVA compared to placebo (Chan et al., 2008a). Indeed, complete resolution of SRF has been reported in 74–100% of patients following PDT treatment (Chan et al., 2008a; Kim et al., 2014; Zhao et al., 2015). Chan and colleagues performed a randomised controlled trial to compare half-dose ICGA-guided PDT with placebo in patients with aCSC and found a significantly larger improvement in BCVA in the PDT-treated group; moreover, 95% of patients achieved complete resolution of SRF following PDT, which was significantly higher than the placebo group, in which only 58% of patients achieved complete resolution (Chan et al., 2008a). These results suggest that half-dose PDT may be a suitable treatment option for aCSC, despite the high probability of spontaneous resolution of SRF if left untreated. In a non-randomised retrospective study comparing 11 patients who received half-dose FA-guided PDT and 10 patients who received placebo treatment, Kim and colleagues found complete resolution of SRF in 80% of aCSC patients at 1 month after PDT, 100% at 3 months after PDT, and 90% at 12 months after PDT, compared to only 18%, 27%, and 64% of patients, respectively, in the placebo group (Kim et al., 2014). Both ICGA-guided and FA-guided PDT treatment can be effective in aCSC. Achieving rapid resolution of SRF can be important in order to quickly improve BCVA in some patients, for example patients who depend heavily on optimal BCVA for professional reasons (Lu et al.,



**Fig. 6.** Multimodal imaging of a 37-year-old man diagnosed with chronic central serous chorioretinopathy, who was treated with half-dose photodynamic therapy (PDT). Multifocal serous neuroretinal detachments are present in the macula, including the fovea (A). Diffuse hyperfluorescent retinal pigment epithelial abnormalities can be seen nasally of the optic disc on 3-min fluorescein angiography, with relatively limited abnormalities and discrete leakage in the macula (B). In contrast, indocyanine green angiography (10 min after injection of indocyanine green) shows intense, multifocal hyperfluorescence that is much more extensive than the abnormalities on fluorescein angiography (C). The area that was treated with half-dose PDT included most of the area of hyperfluorescence that fitted in a single PDT laser spot (area within the red circle, D). After a single PDT treatment, a complete resolution of subretinal fluid was observed on optical coherence tomography (OCT) (E), with a decrease in choroidal thickness as compared to the OCT image before treatment (A). Toward the optic disc there is increasing photoreceptor layer atrophy without pigment epithelium loss, a characteristic finding in central serous chorioretinopathy. (For interpretation of the references to colour in this figure legend, the reader is referred to the Web version of this article.)

2016; Ober et al., 2005; Tsai and Hsieh, 2014). However, Kim et al. found that long-term BCVA outcome and the prevalence of complete resolution of SRF did not differ significantly between patients who received half-dose PDT compared to patients who received placebo, with 90% and 64% of patients achieving complete resolution in the PDT and placebo groups, respectively, after 12 months of follow-up (Kim et al., 2014). Importantly, treatment with low-fluence PDT may also decrease the risk of recurrence of SRF in patients with aCSC patients, as a recent study by Ozkaya and colleagues found that 51% of untreated patients had recurrence compared to only 25% of patients who were treated with low-fluence PDT (Ozkaya et al., 2016). Finally, our group performed a retrospective study of 295 eyes with aCSC and found that SRF recurred in 24% of untreated eyes compared with only 4% of the eyes that received early treatment consisting primarily of FA-guided half-dose PDT (Mohabati et al., 2019).

Some patients have an isolated PED without the presence of SRF. When these patients have such an isolated PED in combination with pachychoroid changes, these cases can be considered a variant of pachychoroid pigment epitheliopathy (Warrow et al., 2013). Given that PED is a frequent and possibly essential element of the pathogenesis of CSC, it is not surprising that non-neovascular PED without serous detachment of the retina has been seen in fellow eyes of patients with CSC and in patients without CSC, some of whom eventually convert to CSC (Arif et al., 2018). In cases where an isolated PED is found under the fovea, associated metamorphopsia may give rise to considerable binocular visual complaints. This has prompted attempts to flatten the PED by (half-dose) PDT in long-standing cases of isolated PED with persistent visual symptoms. Arif et al. found that a single session of PDT was followed by complete resolution of the PED in 7 (78%) of 9 eyes. Of 13 untreated eyes, 5 eyes (38%) underwent spontaneous resolution of the PED. PDT may be useful especially in cases with underlying pachychoroid on OCT and hyperfluorescent choroidal congestion and hyperpermeability on ICGA.

**2.3.4.3. PDT in chronic CSC.** In 2003, the use of ICGA-guided full-setting PDT was first applied to patients with cCSC, with Yannuzzi and colleagues reporting complete resolution of SRF in 12 out of 20 eyes (60%) within 6 weeks (Yannuzzi et al., 2003). In the same year, Cardillo Piccolino and colleagues reported complete resolution in 12 out of 16 eyes (75%) within 1 month (Cardillo Piccolino et al., 2003). Although the risk of both short-term and long-term side effects appears to be relatively low in standard full-setting PDT (see section 2.3.4.4.) (Vasconcelos et al., 2013), several studies have experimented with using either a reduced verteporfin dose for treating cCSC (Chan et al., 2008b; Nicholson et al., 2013), half-fluence PDT (Nicolo et al., 2014; Smretschnig et al., 2013), or half-time PDT (Liu et al., 2016; Shiode et al., 2015). In the PLACE trial, Van Dijk et al. found complete resolution of SRF after ICGA-guided half-dose PDT in 51% and 67% of patients after 6–8 weeks and 7–8 months, respectively (van Dijk et al., 2018b). In addition, a non-randomised prospective case series of 18 patients revealed that 85% of patients achieved complete resolution of SRF at 1 month after treatment (Lai et al., 2006). The long-term efficacy of half-dose PDT is generally favourable, with SRF resolution rates of 91% and 81% at a mean follow-up of 19 and 50 months, respectively (Dhirani et al., 2017; Haga et al., 2017). In a retrospective study in 204 Asian cCSC patients, Fujita and colleagues reported complete resolution of SRF in 89% of patients at 12 months after treatment (Fujita et al., 2015). Finally, a retrospective study in 52 predominantly Asian cCSC patients found that 93% of patients with cCSC had complete SRF resolution 34 months after reduced-setting PDT (Kim et al., 2015d), while a separate retrospective study found that 97% of Asian patients with cCSC had no detectable SRF 36 months after half-dose PDT (Lai et al., 2016).

Another important measure of successful treatment for CSC – in addition to complete resolution of SRF – is retinal sensitivity on microperimetry. Although BCVA is an important parameter in macular

diseases such as CSC, BCVA can still be relatively preserved in patients with CSC despite the presence of SRF (Karakus et al., 2013). In the PLACE trial, the mean retinal sensitivity of patients with cCSC improved by 2 dB and 3 dB at 6–8 weeks and 7–8 months, respectively, after half-dose PDT (van Dijk et al., 2018b). Mean retinal sensitivity was also reported to improve within 1 month following half-dose PDT in patients with cCSC, whereas an improvement in BCVA was detected after 3 months (Fujita et al., 2012b). This improved retinal sensitivity may be correlated with reattachment of the cone outer segment tips and the ellipsoid line on OCT (Fujita et al., 2012a). Despite an increase in retinal sensitivity following PDT for unilateral CSC, the final retinal sensitivity remains generally lower than in the unaffected eye (Fujita et al., 2012b; Sanguansak et al., 2015; Senturk et al., 2011).

Reduced-setting PDT for cCSC has a favourable long-term BCVA outcome, with an average gain of 5 ETDRS letters measured 7–8 months after treatment (van Dijk et al., 2018b), and a mean increase in BCVA from 0.11 to –0.01 logarithm of the minimal angle of resolution (LogMAR) units at 12 months (Fujita et al., 2015). In a 4-year follow-up study, Silva and colleagues reported that patients who received full-setting PDT had a mean increase in BCVA from 59 ETDRS letters at baseline to 67 ETDRS letters at final follow-up visit (Silva et al., 2013). Some patients with cCSC may experience a temporary decrease in BCVA shortly after PDT, which may be due to an abrupt reattachment of photoreceptors and/or a temporary increase in SRF, which occasionally occurs together with transient thickening of the choroid (Iacono et al., 2018; van Dijk et al., 2018a). Treating cCSC using PDT can also lead to a decrease in central retinal thickness, which has been described as a desired effect (Ohkuma et al., 2013). However, large variations in the methods used to measure central retinal thickness preclude a comprehensive analysis of cumulative data (van Rijssen et al., 2018a). In a study in which SRF was included in the measure of central retinal thickness, the decrease in thickness was not correlated with BCVA (Copete et al., 2012). However, SRF should not be included when measuring central retinal thickness. Thus, to exclude SRF, which was inappropriately included in some of the previous studies regarding PDT in CSC, the distance between the internal limiting membrane and the ellipsoid zone on spectral-domain OCT can be measured and used as a surrogate measure of central retinal thickness (van Rijssen et al., 2018a). Using this approach, we recently reported that half-dose PDT actually causes a slight increase in central retinal thickness.

Patients who do not achieve complete SRF resolution after reduced-setting PDT may experience a smaller reduction in central retinal thickness compared to patients who achieved complete resolution (Kim et al., 2015d). Recurrent SRF after initial complete SRF resolution following ICGA-guided half-dose PDT for cCSC occurred in 13% of patients measured at a mean follow-up of 19 months (Dhirani et al., 2017), and in 18% of patients measured at a mean follow-up of 50 months (Haga et al., 2017). In a retrospective study of 75 eyes with CSC treated with half-dose PDT or placebo and followed for at least 3 years, only 20% of eyes in the half-dose PDT group had recurrent CSC compared to 53% of untreated eyes (Lai et al., 2015). Interestingly, the rate of recurrence after half-dose PDT is higher among patients with bilateral cCSC compared to patients with unilateral cCSC (Lai et al., 2016). Moreover, a 4-year follow-up study of cCSC patients by Silva and colleagues found that 3 out of 46 eyes (6.5%) had persistent SRF 4 years after full-dose PDT (Silva et al., 2013).

Several putative predictors of treatment outcome following PDT for CSC have been proposed. For example, PDT can be ineffective and/or have a high rate of recurrence in patients with cCSC who have: 1) PCRD, 2) an absence of an intense hyperfluorescent area on ICGA, 3) poor baseline BCVA, 4) a disruption in the ellipsoid zone, 5) a diffuse hyperfluorescent pattern on ICGA, and/or 6) the presence of shallow irregular RPE detachments on OCT (Cardillo Piccolino et al., 2008a; Chung et al., 2018; Fujita et al., 2015; Inoue et al., 2010; Nicolo et al., 2012; van Rijssen et al., 2018b). On the other hand, patients with cCSC generally respond better to half-dose PDT compared to HSML treatment

regardless of the presence of either focal or diffuse leakage on FA (van Rijnssen et al., 2019). This may indicate that the same pathophysiological processes are involved in both cCSC with focal leakage and cCSC with diffuse leakage. When subretinal deposits are visible on FAF, foveal damage may already exist and may not be restored following PDT (Pryds and Larsen, 2013). When atypical features such as massive exudation with large serous retinal detachment and multiple white subretinal deposits are present, PDT can also be effective. An absence of hyperfluorescent abnormalities on ICGA in cCSC can be predictive of a non-resolving serous neuroretinal detachment following PDT (Inoue et al., 2010; van Rijnssen et al., 2018b). Finally, Breukink and colleagues found no difference between cCSC patients who use corticosteroids and cCSC patients who do not use corticosteroids with respect to outcome following PDT, with complete resolution of SRF in 69% and 50% of patients, respectively (Breukink et al., 2016a).

**2.3.4.4. Safety of PDT in CSC.** To date, only a few side effects have been reported in association with PDT using the standard (i.e. 'full') treatment settings that were previously described for treating AMD. These side effects can include nausea, headache, dyspnoea, syncope, dizziness, a decrease in BCVA, and possible side effects at the site of verteporfin infusion (according to the package insert for verteporfin), including pain, oedema, inflammation, and extravasation. Rare side effects that have been reported include hypersensitivity reactions to the infusion (including anaphylactic reactions with convulsions), temporary renal artery stenosis, and non-perfusion of the choroidal vasculature at the treated area. Therefore, patients should be monitored closely during the PDT procedure. Contraindications for PDT include pregnancy, porphyria, and poor liver function.

Neither systemic nor ocular side effects were observed in a study involving 46 eyes with cCSC in 42 patients who were followed for 4 years after full-dose PDT treatment (Silva et al., 2013). In contrast, adverse events were reported in non-human primates after full-dose PDT and included RPE proliferation, closure of the choroidal vasculature, foveal thinning, and retinal oedema (Tzekov et al., 2006). The severity and risk of adverse effects following PDT can increase when fluency is doubled from the standard fluence of 50 J/cm<sup>2</sup>, and corresponding to 4 times the fluence used in half-fluence PDT (25 J/cm<sup>2</sup>) that is often used for the treatment of CSC (Schlotzer-Schrehardt et al., 2002). In a meta-analysis of studies comparing full-dose PDT and placebo-treated patients with AMD and CNV, Azab and colleagues found a higher rate of visual disturbances in the PDT-treated group (22–42%) compared to the placebo group (16–23%), including abnormal vision, decreased vision, and visual field defects (Azab et al., 2004). Moreover, they found that 1–5% of patients treated with full-dose PDT had an acute decrease in visual acuity (Azab et al., 2004); interestingly, BCVA still improved by at least 1 line in 71% of patients who experienced this acute decrease in visual acuity (Arnold et al., 2004). Few severe side effects have been reported in association with PDT for CSC. For example, a case report of one patient with cCSC and two patients with serous PED who developed severe choroidal ischaemia after receiving full-setting PDT has been published (Lee et al., 2009). Moreover, a transient loss of visual acuity was reported in a patient with cCSC following half-fluence PDT; visual acuity recovered within 22 months (Gutierrez-Hernandez et al., 2015). When using full-dose PDT in patients with CSC, the presence of fibrin underneath the neurosensory detachment may increase the treatment reaction by conjugating verteporfin with fibrin. Therefore, caution is advised in these cases with subretinal fibrin (Fig. 4A–D), although there currently is no clear evidence with respect to using PDT in such cases.

To minimise the risk of PDT-related side effects, reduced-setting PDT was developed for CSC. Overall, reduced-setting PDT is well-tolerated, and no treatment-related severe adverse events such as CNV or RPE atrophy have been reported by the many studies conducted to date (Liu et al., 2014; Tseng and Chen, 2015; van Dijk et al., 2018b). The relatively low risk of systemic photosensitivity (i.e. sunburn on the

skin) can be reduced further using half-dose PDT instead of half-fluence PDT. Thus, treating ophthalmologists may wish to consider whether this side effect is a high risk for their patients and – if so – may opt for half-dose PDT rather than half-fluence or half-time PDT. In a study involving 39 aCSC patients who were treated with half-dose PDT, no ocular or systemic side effects were observed during 12 months of follow-up (Chan et al., 2008b). Similarly, in the PLACE trial, no ocular or systemic side effects were observed in 89 cCSC patients treated with half-dose PDT during a follow-up period of 7–8 months (van Dijk et al., 2018b). Recently, Fujita and colleagues reported no systemic or ocular side effects in 204 eyes with cCSC treated with half-dose PDT, with the sole exception of a polypoidal lesion 8 months after treatment in one eye; however, given that CSC is part of the pachychoroid disease spectrum, this side effect cannot be attributed definitively to PDT, but may represent the natural course of the disease (Fujita et al., 2015). Despite the overall favourable safety profile of PDT in treating CSC, a retrospective study involving either full-dose or reduced-setting PDT revealed RPE atrophy in 10 out of 250 eyes (4%) and an acute severe visual decrease (not further specified) in 4 out of 265 eyes (1.5%) (Lim et al., 2014). In a study involving 199 patients with severe cCSC with pre-existing fovea-involving RPE atrophy, Mohabati and colleagues found a decrease of > 2 ETDRS lines in 9 patients (5%) after PDT; in three of these patients (2%), the decrease in BCVA was permanent and involved a loss of 11–13 ETDRS letters (Mohabati et al., 2018b). Although the vision loss in this very specific category of severe cCSC with fovea-involving RPE atrophy may be due to the PDT treatment, it is also possible that the progressive RPE atrophy is part of the natural course of this more severe form of cCSC. However, this relatively small minority of patients with cCSC with extensive foveal RPE atrophy should be counselled regarding the risk of further vision loss following PDT, and further studies are needed in order to investigate these findings in further detail.

Some patients with cCSC may require re-treatment with reduced-setting PDT due to recurrence of SRF or persistent SRF. However, in the PLACE trial, a second treatment with half-dose PDT was able to achieve complete resolution of SRF in only 32% of cases (van Dijk et al., 2018b). The risk of not responding to PDT treatment may be high in patients who present with hypofluorescence on ICGA at the area corresponding with the focal leakage point on FA (Inoue et al., 2010; van Rijnssen et al., 2018b). Repeat PDT treatment may still be effective, particularly in patients who have a serous retinal detachment with SRF when the leakage results from persistent – or recurrent – hyperfluorescent choroidal changes on ICGA in association with focal leakage on FA. For example, this may be the case when these areas were not included in the initial PDT treatment spot. Whether repeat treatment(s) can induce cumulative changes in the choroid that can eventually lead to adverse effects such as RPE atrophy is currently unknown; therefore, some groups limit the maximum number of PDT treatments for CSC to 2 or 3 treatments per eye.

### 2.3.5. Intravitreal injection of anti-vascular endothelial growth factor (VEGF)

Experimental evidence suggests that inhibiting VEGF has an anti-proliferative and anti-hyperpermeability effect on choroidal endothelial cells (Gragoudas et al., 2004; Peters et al., 2007). In addition, several clinical studies involving patients with AMD and diabetic macular oedema have shown that inhibiting VEGF has a robust inhibitory effect on leakage and fibrovascular proliferation, decreases choroidal blood flow, and reduces central choroidal thickness (Koizumi et al., 2016; Nourinia et al., 2018; Roohipoor et al., 2016). Because CSC is believed to originate from the choroidal vasculature, intravitreal injections of anti-VEGF compounds such as bevacizumab, ranibizumab, and aflibercept have been suggested as a possible treatment for CSC by modifying choroidal vascular permeability (Torres-Soriano et al., 2008). However, the use of anti-VEGF injections for treating CSC is generally off-label, so informed consent should be obtained from the patient prior to treatment,

**Table 4**  
Overview of studies that have assessed intravitreal anti-vascular endothelial growth factor injections for the treatment of central serous chorioretinopathy.

Study	CSC subtype	Study design	Mean age (years)	Drug and treatment strategy	N	Follow-up (months)	Complete resolution of subretinal fluid (%) at final follow-up	Reported parameters and outcomes
Kim et al. (2013)	aCSC	Prospective, randomised comparative study	43	Single dose of ranibizumab (0.5 mg)	20 eyes (20 patients)	> 6	100%	BCVA improved from 0.37 LogMAR to 0.17 LogMAR
Aydin, 2013	aCSC	Prospective, comparative study	46	1 intravitreal injection of 2.0 mg bevacizumab	13 eyes (22 patients)	6	Not reported	Mean BCVA improved from 0.39 to 0.73, mean CMT decreased 216 μm <sup>a</sup>
Tekin et al. (2018)	aCSC	Retrospective comparative study	43	Either bevacizumab (1.25 mg) or ranibizumab (0.5 mg)	43 patients	Mean of 18 months	100% (near complete resolution)	Mean CMT decreased 3 μm <sup>a</sup>
Park et al. (2014)	aCSC	Retrospective study	45	Either bevacizumab (1.25 mg) or ranibizumab (0.5 mg)	21 patients	12	95%	Significantly more patients in the anti-VEGF group (57.1%) had a moderate BCVA improvement (< 0.1 LogMAR) compared to the control group (26.7%)
Artunay et al. (2010)	cCSC	Prospective, randomised controlled trial	38	1 intravitreal injection of 2.5 mg bevacizumab	15 eyes (15 patients)	6	80%	Mean BCVA in LogMAR improved from 0.32 at baseline to 0.03 at final visit, mean CMT decreased 211 μm <sup>a</sup>
Semeraro et al. (2012)	cCSC	Prospective comparative interventional study	35	Intravitreal injection(s) of 1.25 mg bevacizumab, as needed	12 eyes	9	Not reported	Mean BCVA improved from 20 to 43 ETDRS letters
Bae et al. (2014)	cCSC	Prospective, noncomparative	49	3 consecutive monthly injections of 0.5 mg ranibizumab	16 eyes	12	13%	Mean BCVA improved 0.19 LogMAR, mean CMT decreased 71 μm <sup>a</sup>
Pitcher et al. (2015)	cCSC	Prospective, noncomparative	54	1 intravitreal injection of 2.0 mg aflibercept	12 eyes	6	50%	Mean BCVA improved from 62 to 64 ETDRS letters
Bae et al. (2011)	cCSC	Prospective, noncomparative	43	3 consecutive monthly injections of 0.5 mg ranibizumab	8 eyes	6	75%	Mean BCVA improved 0.06 LogMAR
Entezari et al. (2012)	cCSC	Prospective, noncomparative	40	1 intravitreal injection of 1.25 mg bevacizumab	5 eyes (5 patients)	6	100%	Mean CMT decreased 159 μm <sup>a</sup>
Inoue et al. (2011)	cCSC	Prospective, noncomparative	46	1-4 intravitreal injection(s) of 1.25 mg bevacizumab	5 eyes	12	Not reported	Mean BCVA increased from 0.23 to 0.17 LogMAR, and the mean CMT significantly decreased from 323 μm to 171 μm
Lee et al. (2011)	cCSC	Retrospective, non-comparative case series	47	1-6 intravitreal injection(s) of 1.25 mg bevacizumab	16 patients	Mean of 7 months	56%	Mean BCVA improved from 0.32 LogMAR to 0.18 LogMAR
Lim and Kim (2011)	CSC > 3 months	Prospective, noncomparative	46	1-2 intravitreal injection(s) of 1.25 mg bevacizumab	40 eyes	> 12	83% (within 3 months)	Mean age in the non-resolution group was significantly younger than in the resolution group (41 versus 49 years)
Koss et al. (2012)	CSC > 3 months	Prospective, comparative	46	1-3 intravitreal injection(s) of 1.25 mg bevacizumab	10 eyes	10	Not reported	Mean CMT decreased -38 μm <sup>a</sup>
Lim et al. (2010)	CSC > 3 months	Retrospective, noncomparative	42	Intravitreal injection(s) of 1.25 mg bevacizumab, as needed	6 eyes	9	100% (5 out of 5 patients)	Mean BCVA improved from 41 to 53 ETDRS letters at 3 months after treatment
Kim et al. (2015b)	Persistent CSC	Retrospective study	49	Intravitreal injection(s) of 1.25 mg bevacizumab, as needed	42 eyes (42 patients)	Mean of 9 months	60%	Mean BCVA increased from 0.35 to 0.32 LogMAR, mean CMT decreased 60 μm
Chan et al. (2007)	CSC with neovascularisation	Prospective, nonrandomised, interventional case series	38	3 consecutive monthly injections of 1.25 mg bevacizumab	15 eyes (15 patients)	6	Not reported	Mean BCVA improved from 0.48 to 0.17 LogMAR, mean CMT decreased 105 μm <sup>a</sup>
Peiretti et al. (2018)	CSC with neovascularisation	Retrospective study of a consecutive series	59	Either bevacizumab (1.25 mg) or ranibizumab (0.5 mg), or pegaptanib (0.3 mg)	18 eyes	12	Not reported	Mean BCVA improved from 0.69 to 0.39 LogMAR
Roy et al. (2017)	CSC with choroidal neovascular membrane	Retrospective case series	43	Either bevacizumab (1.25 mg) or ranibizumab (0.5 mg)	10 eyes (9 patients)	Mean of 28 months	60%	Mean BCVA improved from 0.62 to 0.47 LogMAR

(continued on next page)

Table 4 (continued)

Study	CSC subtype	Study design	Mean age (years)	Drug and treatment strategy	N	Follow-up (months)	Complete resolution of subretinal fluid (%) at final follow-up	Reported parameters and outcomes
Unlu et al. (2016a)	Unspecified	Retrospective comparative study	46	Intravitreal injection(s) of 1.25 mg bevacizumab, as needed	22 patients	Mean of 12 months	100% (near complete resolution)	Mean BCVA improved from 0.38 to 0.24 LogMAR, mean CMT decreased 135 $\mu\text{m}$ <sup>a</sup>
Kim et al. (2015a)	Unspecified	Retrospective, noncomparative	48	Multiple intravitreal injection(s) of 1.25 mg bevacizumab	30 eyes	> 6	67%	SFCT (non-responders group) increased 3 $\mu\text{m}$ , SFCT (responders group) decreased 63 $\mu\text{m}$
Unlu et al. (2016b)	Unspecified	Retrospective study	46	Intravitreal injection(s) of 1.25 mg bevacizumab, as needed	21 patients	Mean of 10 months	76%	The mean BCVA improved from 0.49 to 0.19 LogMAR, mean SFCT decreased 22 $\mu\text{m}$ (not significant)
Huang et al. (2009)	Unspecified	Case report	42	1 intravitreal injection of 1.25 mg bevacizumab	1 eye	6	100%	VA improved from 20/40 to 20/20

aCSC, acute central serous chorioretinopathy; BCVA, best-corrected visual acuity; cCSC, chronic central serous chorioretinopathy; CMT, central macular thickness; CSC, central serous chorioretinopathy; ETDRS, Early Treatment of Diabetic Retinopathy Study; FA, fluorescein angiography; LogMAR, logarithm of the minimal angle of resolution; OCT, optical coherence tomography; SFCT, subfoveal choroidal thickness; SRF, subretinal fluid; VEGF, vascular endothelial growth factor.

<sup>a</sup> The methods to obtain CMT or CRT differed between studies. Some studies may have included the SRF in this measurement.

emphasizing this off-label use.

Although some studies have investigated the use of anti-VEGF for CSC (see Table 4 for a summary of studies published to date), no large, prospective randomised controlled clinical trials have been performed. Some studies found a positive effect. For example, Artunay and colleagues found that 80% of 15 patients treated with bevacizumab had complete resolution of SRF, compared to 53% of 15 untreated control group patients (Artunay et al., 2010). In a prospective study of 20 patients with aCSC who received ranibizumab and 20 patients who received no treatment, SRF resolved in 4 weeks compared to 13 weeks, respectively (Kim et al., 2013). In a randomised, non-controlled pilot study involving 8 cCSC eyes treated with 3 intravitreal injections of ranibizumab, 2 eyes (25%) had complete resolution of SRF at 3 months (Bae et al., 2011). However, in a subsequent prospective study with ranibizumab, Bae and colleagues reported complete resolution in only 13% of cCSC eyes treated with ranibizumab after 12 months, compared to 89% of eyes treated using low-fluence PDT (Bae et al., 2014). Despite these positive reports, however, a meta-analysis failed to confirm the putative positive effects of bevacizumab, ranibizumab, or aflibercept for aCSC, although the authors did suggest that certain subtypes of cCSC might benefit from anti-VEGF treatment (Chung et al., 2013; Ji et al., 2017). This may be particularly true for patients with CSC with associated CNV (Chan et al., 2007; Chhablani et al., 2015).

A prospective pilot study involving 12 cCSC patients revealed that intravitreal aflibercept led to complete resolution of SRF in 6 patients (50%), but had no significant effect on BCVA (Pitcher et al., 2015). Moreover, changes in choroidal thickness have been observed after intravitreal injections of anti-VEGF. Specifically, Kim and colleagues reported that choroidal thickness was decreased by an average of 22  $\mu\text{m}$  in 42 cCSC eyes measured at a mean follow-up of 9 months after the start of intravitreal injections of bevacizumab (Kim et al., 2015b). This decrease is similar to the results reported using aflibercept and bevacizumab for AMD, which both resulted in a decrease in choroidal thickness of approximately 36  $\mu\text{m}$  (Koizumi et al., 2016; Ting et al., 2016). Because these studies were performed before the availability of OCT angiography, it is unclear whether the SRF that resolved occurred due to CSC or due to secondary CNV, which is difficult to distinguish based on FA and ICGA images. Given the lack of large prospective trials and the unknown explanation for its efficacy in CSC, intravitreal injections of anti-VEGF agents should probably be limited to patients with CSC together with CNV and/or polypoidal choroidal vasculopathy, as discussed in section 3.3.

### 2.3.6. Antagonists of mineralocorticoid receptors (MR) and glucocorticoid receptors

Elevated levels of cortisol and endogenous mineralocorticoid dysfunction have been described in CSC patients (Haimovici et al., 2003). Moreover, there appears to be an association between corticosteroid use and CSC, and rats that received corticosteroids have increased expression of MRs. These findings led to the hypothesis that MR antagonists may be used to treat CSC (Daruich et al., 2015; Zhao et al., 2010, 2012). Pilot studies using the MR antagonists eplerenone and spironolactone in patients with CSC have yielded promising results (Bousquet et al., 2013, 2015) (see Table 5). However, the patient's renal function and potassium levels should be monitored closely before treatment and at regular intervals during treatment, as MR antagonists can induce hyperkalaemia, which has been associated with cardiac arrhythmia. Patients whose serum potassium level exceeds 5.5 mEq/L and/or have a creatinine clearance rate of  $\leq 30$  mL/min should not receive treatment with MR antagonists. On the other hand, patients with a relatively thick choroid ( $> 515 \mu\text{m}$ ) may respond better to treatment with MR antagonists (Bousquet et al., 2019).

Glucocorticoids likely play a role in the pathogenesis of CSC, and glucocorticoid receptors are expressed in both the retina and choroid (Brinks et al., 2018; Zhao et al., 2010). In rats, corticosterone can cause choroidal thickening, a feature common among patients with CSC

**Table 5**  
Overview of studies that have assessed oral mineralocorticoid receptor antagonists for the treatment of central serous chorioretinopathy.

Study	CSC subtype	Mean age (years)	Study design	Drug(s)	Dosage and duration	N	Follow-up	Complete resolution of subretinal fluid (%) at final follow-up	Reported parameters and outcomes
Sun et al. (2018)	aCSC	43	Prospective, randomised controlled clinical study	Spirolactone	40 mg, twice daily for 2 months	30 eyes (30 patients)	2 months	56%	Mean LogMAR BCVA improved from 0.25 to 0.05, mean CMT decreased from 536 to 248 µm
Chai et al. (2016)	aCSC	51	Prospective, randomised comparative study	Spirolactone and fenofibrate versus fenofibrate	100 mg/200 mg for 8 weeks	60 eyes (60 patients)	8 weeks after treatment	67%	Mean BCVA improved from 0.35 to 0.22 LogMAR
Zucchiatti et al. (2018)	aCSC	44	Charts of consecutive patients	Eplerenone	25 mg for 1 week; 50 mg after 1 week for 12 weeks	15 eyes (15 patients)	3 months	80%	Mean BCVA improved from 0.15 to 0.06 LogMAR (p = 0.011)
Rahimy et al. (2018)	cCSC	50	Prospective, randomised, double-blind, placebo-controlled study	Eplerenone	25 mg for 1 week; 50 mg after 1 week	15 eyes (10 patients)	9 weeks	33%	Mean BCVA improved 0.06 LogMAR, mean CMT decreased 82 µm <sup>a</sup>
Schwartz et al. (2017)	cCSC	51	Prospective, double-blind, randomised placebo-controlled study	Eplerenone	25 mg for 1 week; 50 mg after 1 week	13 eyes	Up to 6 months after start of treatment	23% (after 3 months)	Mean BCVA improved from 0.50 to 0.48 LogMAR (not significant)
Gergely et al. (2017)	cCSC	49	Prospective clinical trial	Eplerenone	50 mg/day for 3 months	28 patients	6 months after treatment start	32%	A mean BCVA increase of > 5 letters was observed in 36% at final visit
Sacconi et al. (2018)	cCSC	45	Interventional, open-label, non-randomised clinical study	Eplerenone	25 mg for 1 week; 50 mg after 1 week, max. 13 weeks	29 eyes (27 patients)	21 weeks	58%	Mean BCVA improved from 0.20 to 0.10 LogMAR at the end of treatment, mean SFCT decreased 21 µm
Falavarjani et al. (2017)	cCSC	40	Prospective interventional case series	Spirolactone	25 mg for a minimum of 6 weeks	16 eyes (14 patients)	6.4 ± 4.3 months	44%	Mean BCVA improved from 0.54 to 0.42 LogMAR
Rajesh et al. (2018)	cCSC	46	Prospective, non-randomised study	Eplerenone	50 mg daily for 1 month, 25 mg daily for 2 months	22 eyes (11 patients)	6 months	63%	Mean BCVA improved from 0.27 to 0.19 LogMAR
Herold et al. (2014)	cCSC	46	Interventional, uncontrolled, prospective case series	Spirolactone	25 mg twice daily	20 eyes (18 patients)	3 months	25%	Mean BCVA improved from 0.32 at baseline to 0.20 LogMAR at final visit
Bousquet et al. (2013)	cCSC	54	Nonrandomised pilot study	Eplerenone	25 mg for 1 week; 50 mg after 1 week for 1 or 3 months	13 eyes (13 patients)	3 months	67%	Mean BCVA improved from 0.52 LogMAR to 0.27 LogMAR, mean CMT decreased 163 µm
Ghadiali et al. (2016)	cCSC	58	Retrospective observational case series	Spirolactone versus eplerenone	Either 50 or 25 mg daily	23 eyes (14 patients)	6–12 months	Not reported	No change in SFCT and CMT <sup>a</sup>
Singh et al. (2015)	cCSC	57	Retrospective consecutive case series	Eplerenone	25 or 50 mg daily for a maximum of 300 days	17 eyes (13 patients)	Mean 181 days (38–300 days)	35%	Mean CMT decreased 70 µm <sup>a</sup>
Zola et al., 2018	cCSC	53	Retrospective study	Eplerenone versus spironolactone	25 or 50 mg daily, mean 21 months (range 10–24 months)	16 eyes (16 patients)	24 months	81%	LogMAR BCVA was 0.14 at baseline and 0.07 at 24 months of follow-up
Bousquet et al. (2015)	Non-resolving CSC	47	Randomised controlled crossover study	Spirolactone + placebo versus placebo + spironolactone	50 mg for 30 days	15 eyes (15 patients)	60 days	50%	Mean ETDRS BCVA increased from 74 to 77 letters. SFCT decreased 29 µm
		47		Spirolactone				71% (reduction of SRF)	(continued on next page)

**Table 5 (continued)**

Study	CSC subtype	Mean age (years)	Study design	Drug(s)	Dosage and duration	N	Follow-up	Complete resolution of subretinal fluid (%) at final follow-up	Reported parameters and outcomes
Herold et al. (2017)	Non-resolving CSC		Interventional uncontrolled open-label prospective clinical trial		25 mg twice daily for 3 months	21 eyes (20 patients)	12 months after start of treatment		Mean BCVA improved from 0.25 LogMAR to 0.17 LogMAR
Daruich et al. (2016)	Non-resolving CSC	53	Retrospective case series of consecutive patients	Eplerenone versus spironolactone	25 mg for 1 week, 50 mg after 1 week	54 eyes (42 patients)	6 months after treatment introduction	50%	Mean CMT decreased 57 $\mu\text{m}^{\text{a}}$
Kim et al. (2019)	Non-resolving CSC	49	Retrospective, interventional, comparative study	Spironolactone	50 mg daily	26 eyes (26 patients)	Mean of 15.2 months	69%	Mean LogMAR BCVA improved from 0.39 to 0.2 LogMAR
Lee et al. (2019)	Non-resolving CSC	53	Retrospective review	Spironolactone	50 mg daily	18 eyes (18 patients)	Up to 6 months	39%	Mean BCVA improved from 0.32 to 0.24 LogMAR, mean CMT decreased 120 $\mu\text{m}$
Cakir et al. (2016)	Atrophic/non-resolving CSC	56	Retrospective, uncontrolled open-label cohort study	Eplerenone	25 mg for 1 week, 50 mg after 1 week	24 patients	21–364 days	29%	Mean BCVA improved from 0.35 LogMAR to 0.30 LogMAR, mean CMT decreased 67 $\mu\text{m}$
Pichi et al. (2017)	Persistent CSC	51	Prospective, placebo-controlled trial	Eplerenone versus spironolactone	25 mg for 1 week, then increase to 50 mg, with cross-overs	60 eyes (60 patients)	4 months	Not reported	Both spironolactone and eplerenone did not show a statistical reduction in choroidal thickness (17 and 15 $\mu\text{m}$ mean reduction, respectively)
Chin et al. (2015)	Recalcitrant CSC	58	Retrospective consecutive observational case series	Eplerenone versus spironolactone versus eplerenone followed by spironolactone	25 or 50 mg twice daily for 1–8.5 months	23 patients	15 months	Not reported	Mean CMT decreased 41 $\mu\text{m}^{\text{a}}$
Rubsam et al. (2017)	aCSC/cCSC	44	Interventional, controlled, and retrospective cohort study	Acetazolamide followed by eplerenone or spironolactone	100 mg spironolactone or 50 mg eplerenone daily	20 patients	12 weeks	Not reported	Mean change in SRF volume was 1.07 $\text{mm}^3$
Kim et al. (2018a)	Steroid induced CSC	49	Retrospective review	Spironolactone	50 mg daily, mean of 2.6 months	17 eyes (15 patients)	Mean of 17 months	82%	Mean CMT decreased 160 $\mu\text{m}$
Ramos-Yau et al. (2018)	Bullous CSC	45	Case report	Spironolactone	50 mg	1 patient	> 4 months	100%	BCVA was 20/200 and improved to 20/40 after treatment
Kapoor and Wagner (2016)	Unspecified	56 (eplerenone), 59 (spironolactone)	Retrospective chart review	Spironolactone or eplerenone	50 mg daily	32 patients	3–10 months	58% (at 3 months)	Mean BCVA improved from 0.42 LogMAR to 0.31 LogMAR (spironolactone), mean BCVA improved from 0.55 LogMAR to 0.32 LogMAR (eplerenone)

aCSC, acute central serous chorioretinopathy; BCVA, best-corrected visual acuity; cCSC, chronic central serous chorioretinopathy; CMT, central macular thickness; CSC, central serous chorioretinopathy; ETDRS, Early Treatment of Diabetic Retinopathy Study; FA, fluorescein angiography; LogMAR, logarithm of the minimal angle of resolution; MR, mineralocorticoid receptor; OCT, optical coherence tomography; SFCT, subfoveal choroidal thickness; SRF, subretinal fluid.

<sup>a</sup> The methods to obtain CMT differed between studies. Some studies may have included the SRF in this measurement.

(Zhao et al., 2012). This finding has prompted experimental treatment of CSC using the glucocorticoid receptor antagonist mifepristone (Jampol et al., 2002).

**2.3.6.1. Spironolactone.** Spironolactone is a potassium-sparing diuretic that binds to the distal tubule in the kidney as a binding competitor of aldosterone. Spironolactone slows the exchange of sodium and potassium in the distal tubule and has been approved for treating congestive heart failure and primary hyperaldosteronism. The most common side effects of spironolactone (reported in > 10% of treated patients) are headache, diarrhoea, fatigue, gynaecomastia, decreased libido, and menstrual disruption (Delyani, 2000). Patients treated with spironolactone must be monitored closely for hyperkalaemia, which can induce cardiac arrest. Patients with diabetes mellitus, liver disorders, kidney disorders, and elderly patients are particularly at risk. Contraindications for spironolactone use include the concomitant use of potassium supplements, the use of potassium-sparing diuretics, the use of potent CYP3A4 inhibitors, or the combined use of an angiotensin-converting enzyme inhibitor with an angiotensin receptor blocker, as taking these drugs together with spironolactone can increase the risk of hyperkalaemia and subsequent cardiac arrhythmia.

Several studies have shown beneficial effects of spironolactone in CSC, including improved BCVA, reduced choroidal thickness, and reduced SRF (Bousquet et al., 2015; Chai et al., 2016; Chin et al., 2015; Daruich et al., 2016; Falavarjani et al., 2017; Herold et al., 2014, 2017; Kapoor and Wagner, 2016; Kim et al., 2018a; Pichi et al., 2017). In a randomised controlled crossover study involving 15 patients with non-resolving CSC, spironolactone treatment was associated with an average reduction in choroidal thickness of 102 µm, compared to only 10 µm with placebo (Bousquet et al., 2015); the number of patients who achieved complete resolution of the serous neuroretinal detachment was not reported. In a prospective case series, 16 eyes with cCSC were treated with 25 mg spironolactone per day for at least 6 weeks, resulting in complete resolution of SRF in 7 eyes (44%) and a significant increase in BCVA compared to baseline (Falavarjani et al., 2017). In a prospective clinical trial involving 21 eyes with cCSC treated with 25 mg spironolactone twice daily, 15 eyes (71%) had decreased SRF on OCT 12 months after the start of treatment (Herold et al., 2017). In another prospective randomised controlled clinical trial involving 30 eyes with aCSC, a significantly higher percentage of eyes had complete SRF resolution at two months in the spironolactone-treated group (10 out of 18 eyes, 56%) compared to the observed control group (1 out of 12 eyes, 8%) (Sun et al., 2018). Recently, Kim and colleagues retrospectively analysed the outcome after using spironolactone to treat 17 eyes with steroid-induced CSC; the authors found complete SRF resolution in 14 eyes (82%) of patients who remained on glucocorticoids (Kim et al., 2018a). Despite these promising initial results, prospective randomised controlled trials of sufficient power and duration are needed in order to fully evaluate the clinical benefits of using spironolactone for CSC.

**2.3.6.2. Eplerenone.** Similar to spironolactone, eplerenone is primarily used to treat heart failure (Pitt et al., 2003). Eplerenone was originally designed to avoid the hormone-associated side effects of spironolactone, serving as a more selective MR antagonist due to the addition of a 9,11-epoxide group (Cook et al., 2003; Delyani, 2000; McMahan, 2001). Although eplerenone likely has more tolerable side effects compared to spironolactone, eplerenone does not appear to be clinically superior to – and possibly not equivalent to – spironolactone in treating CSC (Chin et al., 2015; Pichi et al., 2017). However, after the patent on eplerenone expired, the price difference between eplerenone and spironolactone became negligible, and patients – particularly male patients – should first try eplerenone, as it is far less likely to induce gynaecomastia and mastalgia, aside from other possible side effects. Before starting eplerenone treatment, the patient's serum potassium and creatinine levels should be checked. Different approaches for the

monitoring of serum potassium exist, and the following protocol is an example. Treatment with eplerenone should not be initiated if serum potassium is > 5.5 mEq/L or if the creatinine clearance is ≤ 30 mL/min. Patients usually commence with 1 dose of 25 mg eplerenone a day. Serum potassium should be reassessed after approximately 1 week. If potassium is < 5.0 mEq/L, the eplerenone dose is increased (from 25 mg daily to 50 mg daily or from 25 mg every other day to 25 mg daily). If serum potassium is between 5.0 and 5.4 mEq/L, eplerenone treatment should remain at the current dose. If serum potassium is between 5.5 and 5.9 mEq/L, eplerenone is reduced (from 25 mg every other day to withhold, from 25 mg daily to 25 mg every other day, or from 50 mg daily to 25 mg daily). When serum potassium is ≥ 6.0 mEq/L, eplerenone treatment should be stopped, but can be restarted when serum potassium levels fall below 5.5 mEq/L. Serum potassium levels should be checked monthly, and the dosage should be adjusted accordingly.

Patients taking eplerenone should be instructed to contact their physician if they experience any side effects such as nausea, diarrhoea, dizziness, or headache, which can occur in up to 10% of patients. Similar to spironolactone, contraindications for eplerenone include the use of potassium supplements, potassium-sparing diuretics, potent CYP3A4 inhibitors, or combined treatment with an angiotensin-converting enzyme inhibitor and angiotensin receptor blocker.

In a prospective pilot study, Bousquet and colleagues prescribed eplerenone to 13 patients with cCSC and reported a reduction in SRF, reduced central macular thickness, and improved BCVA (Bousquet et al., 2013). Cakir and colleagues retrospectively reported that 29% of patients with cCSC who failed to respond to oral acetazolamide, intravitreal bevacizumab, focal laser photocoagulation, or PDT achieved complete resolution of SRF after a median of 106 days of daily eplerenone (Cakir et al., 2016). Other studies have also shown that eplerenone can have clinical value, as summarised in Table 4. Importantly, an absence of CNV on OCT angiography and the presence of a focal leakage point on ICGA may serve as predictive factors for complete resolution of SRF following eplerenone treatment (Sacconi et al., 2018). On the other hand, patients who present with widespread changes in the RPE may benefit less from eplerenone treatment compared to patients who present without these abnormalities (Bousquet et al., 2019; Cakir et al., 2016). The duration of eplerenone treatment in published studies ranged from 1 month to 51 months (Table 4), and although the effects of eplerenone in CSC should be evident within a few months, information on when treatment effect may occur is scarce (Bousquet et al., 2019; Rahimy et al., 2018; Schwartz et al., 2017). To date, no large, prospective randomised controlled trials have been conducted in order to measure the efficacy or long-term outcome of using eplerenone or spironolactone to treat CSC. However, two prospective studies are currently in progress; one study is designed to compare eplerenone with sham treatment (VICI trial, ISRCTN registry: 92746680), and the other is designed to compare eplerenone with half-dose PDT (SPECTRA trial, ClinicalTrials.gov identifier: NCT03079141) (see sections 4.1 and 4.2).

**2.3.6.3. Mifepristone.** Mifepristone (also known as RU-486) is a glucocorticoid antagonist that binds to the cytosolic glucocorticoid receptor and prevents gene transcription by blocking recruitment of coactivators, thus rendering the receptor complex inactive. In addition, mifepristone competes with progesterone binding to the progesterone receptor. Mifepristone is currently approved for pharmaceutically induced abortion (Cadepond et al., 1997; Clark, 2008). Given that steroids are the most important external risk factor for developing CSC, stimulation of the glucocorticoid receptor may play a role in the pathogenesis of CSC, thereby providing the rationale for using mifepristone to treat CSC. In a prospective study of 16 patients with cCSC who received 200 mg/day mifepristone for up to 12 weeks, 5 patients (31%) had an improvement in BCVA of ≥ 5 ETDRS letters, with no severe adverse events reported (Nielsen and Jampol, 2011). Currently, a randomised placebo-controlled clinical trial designed to

test the effects of mifepristone in 16 patients with CSC is underway (STOMP-CSC, [ClinicalTrials.gov](https://clinicaltrials.gov/ct2/show/study/NCT02354170) identifier: NCT02354170), and the results of this study are expected to be released in the near future.

### 2.3.7. Other systemic treatment strategies

A variety of other oral pharmaceutical-based treatments have been reported, primarily from relatively small, retrospective studies (Salehi et al., 2015). These studies should be interpreted with caution, as spontaneous recovery is common in aCSC, and spontaneous improvement and resolution can also occur in cCSC.

**2.3.7.1. Antioxidants.** Treatment with high-dose antioxidants was studied in patients with aCSC in a randomised placebo-controlled trial. In a group of 29 patients who received high-dose antioxidants, 22 (76%) achieved complete resolution of SRF, compared to 14 out of 29 patients (48%) who received placebo (Ratanasukon et al., 2012). It is important to note that during this trial, patients were able to receive additional treatments as needed, which complicates the analysis of the putative effects of antioxidants. Oral administration of a curcumin-phospholipid formulation, which purportedly has antioxidant and anti-inflammatory properties, was found to reduce the height of the neurosensory retinal detachment in 78% of 12 patients with CSC, although no information was provided with respect to whether the patients had aCSC or cCSC (Mazzolani, 2012; Mazzolani and Togni, 2013). According to the currently available evidence, there is no clear indication for treating CSC using antioxidants.

**2.3.7.2. Aspirin.** Aspirin (acetylsalicylic acid) inhibits platelet aggregation and may reduce serum levels of plasminogen activator inhibitor 1, which can be increased in CSC (Iijima et al., 1999). A prospective case series described a positive effect of aspirin in 109 patients with unspecified CSC patients; specifically, BCVA improved to a larger extent in patients who were treated with aspirin compared to historical control patients (Caccavale et al., 2010). However, because the control group was based on retrospective data, the conclusions should be interpreted with caution. Thus, there is currently extremely limited evidence supporting the notion that aspirin is a viable treatment for CSC with aspirin.

**2.3.7.3. Beta-blockers.** In a case report, Tatham and Macfarlane found that treating two patients with recurrent CSC with the selective  $\beta_1$  receptor blocker metoprolol resulted in resolution of SRF in both patients (Tatham and Macfarlane, 2006). In a small, randomised controlled trial, the effect of the non-specific beta-blocker nadolol was evaluated in 8 patients with unspecified CSC; the authors found that the size of the subretinal detachment was reduced to a lesser extent in patients who were treated with nadolol compared to patients who received placebo (with an average decrease of 4.3 mm<sup>2</sup> and 16.0 mm<sup>2</sup>, respectively), although difference was not statistically significant (Browning, 1993). This finding suggests that nadolol may actually reduce the likelihood of achieving SRF resolution and is therefore unlikely to be useful in treating CSC. Consistent with this notion, a recent study found that a different non-specific beta-blocker – metipranolol – had no significant effect in patients with aCSC with respect to resolving SRF compared to control-treated patients (Chrapek et al., 2015). Taken together, the currently available evidence suggests that beta-blockers are not likely to be a viable treatment for CSC.

**2.3.7.4. Carbonic anhydrase inhibitors.** Oral administration of the carbonic anhydrase inhibitor dorzolamide was found to have clinical benefits in treating cystoid macular oedema in patients with retinitis pigmentosa (Grover et al., 1997). Subsequently, Wolfensberger and colleagues hypothesised that acidification of the subretinal space increases fluid resorption through the RPE, possibly due to a perturbation in carbonic anhydrase type IV, leading to the proposal that carbonic anhydrase inhibitors may be a viable option for treating

CSC (Wolfensberger et al., 1999). However, although a retrospective study of 15 patients with unspecified CSC indicated that oral treatment with the carbonic anhydrase inhibitor acetazolamide can reduce the time until complete resolution of SRF compared to untreated control group (3 weeks versus 8 weeks, respectively), BCVA and the rate of recurrence did not differ between acetazolamide-treated and untreated patients (Pikkel et al., 2002). Moreover, large, well-designed studies designed to assess the clinical benefits of inhibiting carbonic anhydrases in patient with CSC have not been performed. Thus, carbonic anhydrase inhibitors are not likely to be a viable treatment for CSC.

**2.3.7.5. Finasteride.** Finasteride is an inhibitor of dihydrotestosterone synthesis and is used to treat benign prostatic hyperplasia and hair loss. Because androgens such as testosterone may play a role in CSC, finasteride has been evaluated as a possible treatment for CSC (Ferooghian et al., 2011; Moisseiev et al., 2016). However, a pilot study involving 5 patients with cCSC found that taking 5 mg/day finasteride for 3 months had no effect on BCVA measured at 6 months compared to baseline; the rate of SRF resolution was not reported (Ferooghian et al., 2011; Moisseiev et al., 2016). In contrast, a retrospective review of 23 patients with cCSC found that 76% of patients who were treated with finasteride had complete SRF resolution after a mean follow-up duration of 15 months (Moisseiev et al., 2016). With respect to side effects, two patients in the pilot study by Ferooghian and colleagues reported a loss of libido, whereas no side effects were observed by Moisseiev and colleagues. These relatively preliminary studies should be followed by larger studies in order to evaluate whether finasteride treatment can benefit patients with CSC.

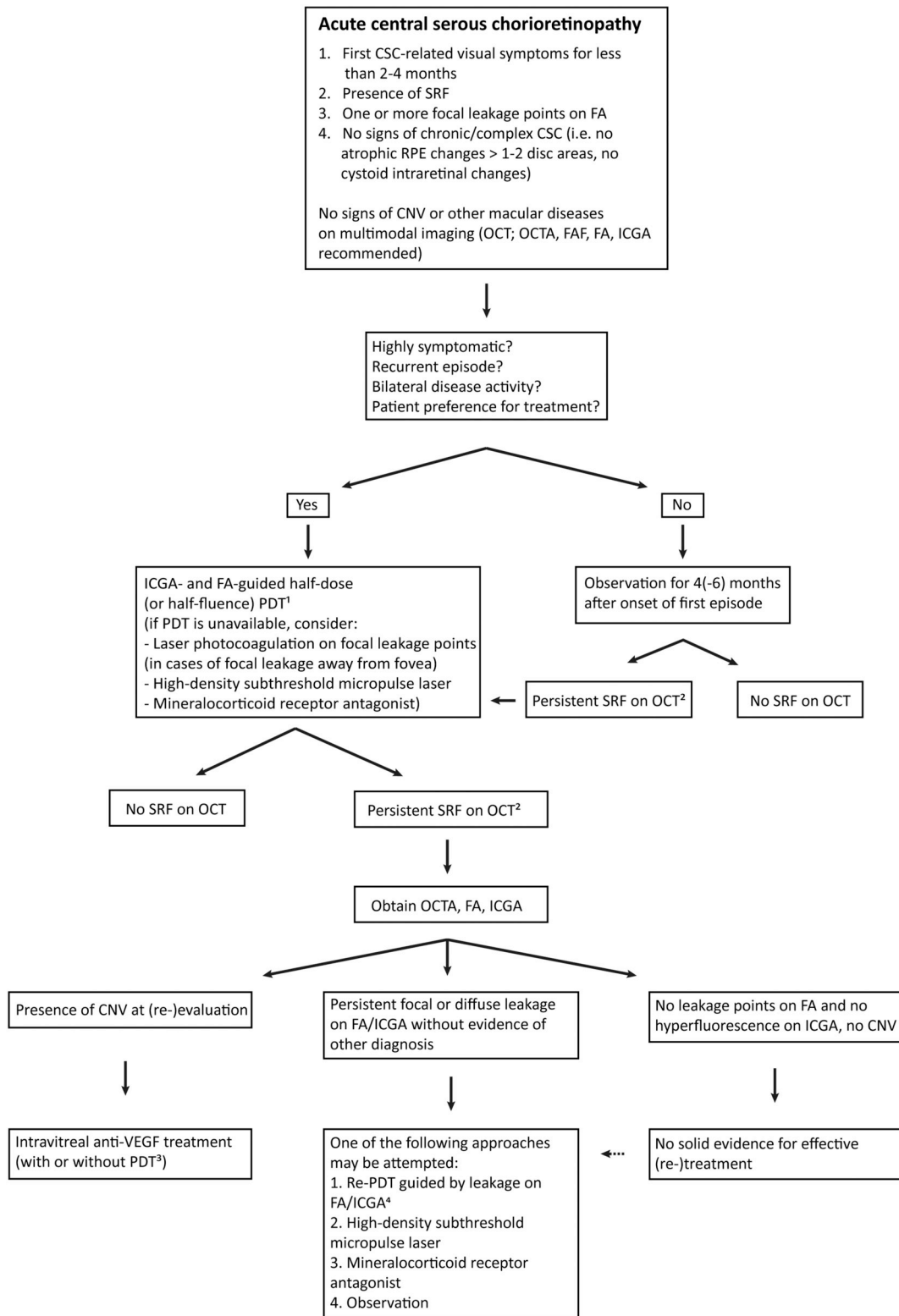
**2.3.7.6. Helicobacter pylori eradication.** Infection with the bacterium *H. pylori* has been proposed as a risk factor for CSC, although this putative association has not been demonstrated conclusively (Chatziralli et al., 2017). *H. pylori* infection can be eradicated using metronidazole or omeprazole together with amoxicillin and/or clarithromycin (Zavoloka et al., 2016). Interestingly, successful eradication of *H. pylori* in patients with unspecified CSC has been reported to lead to more rapid resolution of SRF in a retrospective, comparative study of 25 patients compared to 25 untreated patients who did not have an *H. pylori* infection (Rahbani-Nobar et al., 2011). With respect to aCSC, eradicating *H. pylori* was found to improve retinal sensitivity but had no effect on BCVA or complaints of metamorphopsia (Dang et al., 2013). Nonetheless, a prospective, randomised, case-controlled, non-blinded study involving 33 patients with aCSC and *H. pylori* found that treating the *H. pylori* infection improved BCVA and retinal sensitivity measured using automated static perimetry (Zavoloka et al., 2016). As noted above, there is currently no compelling evidence supporting the notion that *H. pylori* infection is a major risk factor for CSC, and the evidence to date to support the idea that eradicating *H. pylori* may serve as a possible treatment for CSC is limited. Nevertheless, patients with CSC should be tested for *H. pylori* if they present with symptoms associated with this bacterial infection such as stomach ache or heartburn.

**2.3.7.7. Ketoconazole.** Ketoconazole is primarily used as an anti-fungal agent, but it also has glucocorticoid receptor antagonising properties. These glucocorticoid-related effects may be of clinical value in treating CSC, as CSC may be associated with an upregulation of glucocorticoid receptors. Two studies examined the effects of oral ketoconazole (200 or 600 mg/day for 4 weeks) in 15 patients with aCSC and 5 patients with cCSC (Golshahi et al., 2010; Meyerle et al., 2007). The authors found that ketoconazole decreased endogenous urine cortisol levels, but had no significant effect on visual acuity or serous neuroretinal detachment; moreover, erectile dysfunction and nausea were reported in one patient each. These results indicate that further study is warranted before ketoconazole can be considered as a possible first-line treatment for CSC.

2.3.7.8. **Melatonin.** The effects of melatonin on the circadian rhythm have been suggested to also have positive effects in CSC (Pandi-Perumal et al., 2008). To test this hypothesis, Gramajo and colleagues performed a prospective, comparative case study in which 13 cCSC patients were treated with melatonin (Gramajo et al., 2015). The authors found that the patients who received melatonin had a larger improvement in BCVA compared to a control group. Moreover, 3 out of 13 treated patients

(38%) had complete resolution of SRF at the 1-month follow-up visit. No side effects were reported. No additional evidence is available regarding the use of melatonin in treating CSC; therefore, further study is warranted.

2.3.7.9. **Methotrexate.** Methotrexate is an antimetabolic, immunosuppressive drug used primarily in treating inflammatory



(caption on next page)

**Fig. 7.** Flowchart of the proposed treatment strategy for acute central serous chorioretinopathy. *If there is current corticosteroid use, possible cessation should be discussed with the patient.*

<sup>1</sup> Treat hyperfluorescent areas on indocyanine green angiography (ICGA) that correspond to the area of (focal) leakage on fluorescein angiography (FA) and subretinal fluid on optical coherence tomography (OCT). In case of multiple areas with focal leakage, a large spot including all areas can be used, or multifocal immediately sequential spots may be used, starting with the area including the fovea (if fovea is involved).

<sup>2</sup> In case of only a small amount of residual subretinal fluid (SRF), a conservative approach may be followed, with a follow-up visit including OCT imaging after 1–3 months to see if SRF eventually resolves completely. In case of persistent/increased SRF at that stage, the downstream treatment path may be followed.

<sup>3</sup> Half-dose or half-fluence photodynamic therapy (PDT) may be added in order to treat the choroidal dysfunction/pachychoroid factor of the disease, but limited data is available to support this combined treatment. When a neovascular component of polypoidal choroidal vasculopathy (aneurysmal type 1 neovascularization) is present, PDT (either full-dose, half-dose, or half-fluence) can also be added to anti-vascular endothelial growth factor treatment.

<sup>4</sup> Another half-dose or half-fluence PDT can be performed, but full-dose with full-fluence PDT may also be considered.

Abbreviations in flow chart: CNV, choroidal neovascularisation; CSC, central serous chorioretinopathy; FA, fluorescein angiography; FAF, fundus autofluorescence; ICGA, indocyanine green angiography; OCT, optical coherence tomography; OCTA, optical coherence tomography angiography; PDT, photodynamic therapy; RPE, retinal pigment epithelium; SRF, subretinal fluid; VEGF, vascular endothelial growth factor.

disorders such as rheumatoid arthritis. Because of its non-immunosuppressive properties – for example, its interaction with steroid receptors – methotrexate may be beneficial for treating cCSC (Kurup et al., 2012). Two studies tested this hypothesis, and both found that treating patients with cCSC for 12 weeks with oral low-dose methotrexate resulted in significant improvements in BCVA (Abrishami et al., 2015; Kurup et al., 2012). Abrishami and colleagues prospectively studied 23 patients and found that 13 patients (62%) had complete resolution of SRF at their 6-month follow-up visit (Abrishami et al., 2015). In a retrospective study by Kurup and colleagues, 9 patients with cCSC were treated with low-dose methotrexate for an average of 89 days, with 83% of patients achieving complete resolution of SRF after an average treatment duration of 12 weeks (Kurup et al., 2012). Although these results suggest that additional well-designed randomised controlled trials are warranted, methotrexate is a generally unattractive treatment option in CSC, as it can have severe side effects, including bone marrow suppression and pulmonary, hepatic, and renal toxicity.

**2.3.7.10. Nonsteroidal anti-inflammatory drugs.** Topical application of the nonsteroidal anti-inflammatory drug (NSAID) nepafenac (0.1%) has also been suggested for treating aCSC. Alkin and colleagues retrospectively studied this hypothesis and found a significantly larger improvement in BCVA after 6 months (from 0.19 to 0.09 LogMAR) in 31 eyes treated 3 times daily for 4 weeks or until complete SRF resolution, compared to an untreated control group (0.13–0.1 LogMAR); moreover, at the 6-month follow-up visit 14 out of 17 eyes (82%) in the treatment group had complete resolution of SRF, compared to 6 out of 14 eyes (43%) in the control group, and no treatment-related or systemic side effects were reported (Alkin et al., 2013). In a case report, Chong and colleagues reported that a patient with aCSC who received topical ketorolac (another NSAID) had SRF resolution after 18 weeks (Chong et al., 2012). These relatively small studies should be supported by more robust evidence before NSAIDs can be introduced into clinical practice for treating CSC.

**2.3.7.11. Rifampicin.** Rifampicin (or rifampin) is used primarily for its antimicrobial properties, but it can also affect the metabolism of endogenous steroids by upregulating cytochrome P450 3A4. The 5'-untranslated region in the *CYP3A4* gene includes glucocorticoid regulatory elements that may be altered in CSC (Guengerich, 1999). A prospective single-arm study of rifampicin (300 mg twice daily for 3 months) showed that SRF resolved in 4 out of 14 eyes (29%) at 6 months; treatment was discontinued in two patients due to cholelithiasis (in one patient) and increased blood pressure (in one patient) (Shulman et al., 2016). Moreover, a single case report described the resolution of SRF in a patient with cCSC 1 month after the start of rifampicin treatment (300 mg twice daily) (Steinle et al., 2012). In addition, Venkatesh and colleagues performed a retrospective analysis of patients with cCSC who were treated with rifampicin and found that 4 eyes with focal leakage on FA (44%) had complete

resolution of SRF after an average follow-up of 10 months; in contrast, the eyes with diffuse leakage on FA had persistent SRF (Venkatesh et al., 2018). Finally, an observational clinical study of 38 eyes in 31 patients with idiopathic CSC revealed that rifampin (300 mg daily for 3 months) improved mean BCVA from 0.56 to 0.47 LogMAR units measured 4 weeks after cessation of treatment (Khan et al., 2016). Despite these promising results, further studies have low priority given the side effects associated with rifampicin and the relatively slow treatment response with CSC – if at all –.

### 2.3.8. Other treatment modalities

Several small studies and case reports have described non-conventional treatments for CSC, including wearing an eye patch (Earl et al., 2014), intravitreal injections of dobesilate (Cuevas et al., 2012), and acupuncture (Lu and Friberg, 1987). Interestingly, an ophthalmologist with CSC reported that he was able to photocoagulate his own leak by 'sungazing' (Gartner, 1987).

## 3. Currently preferred treatments for CSC

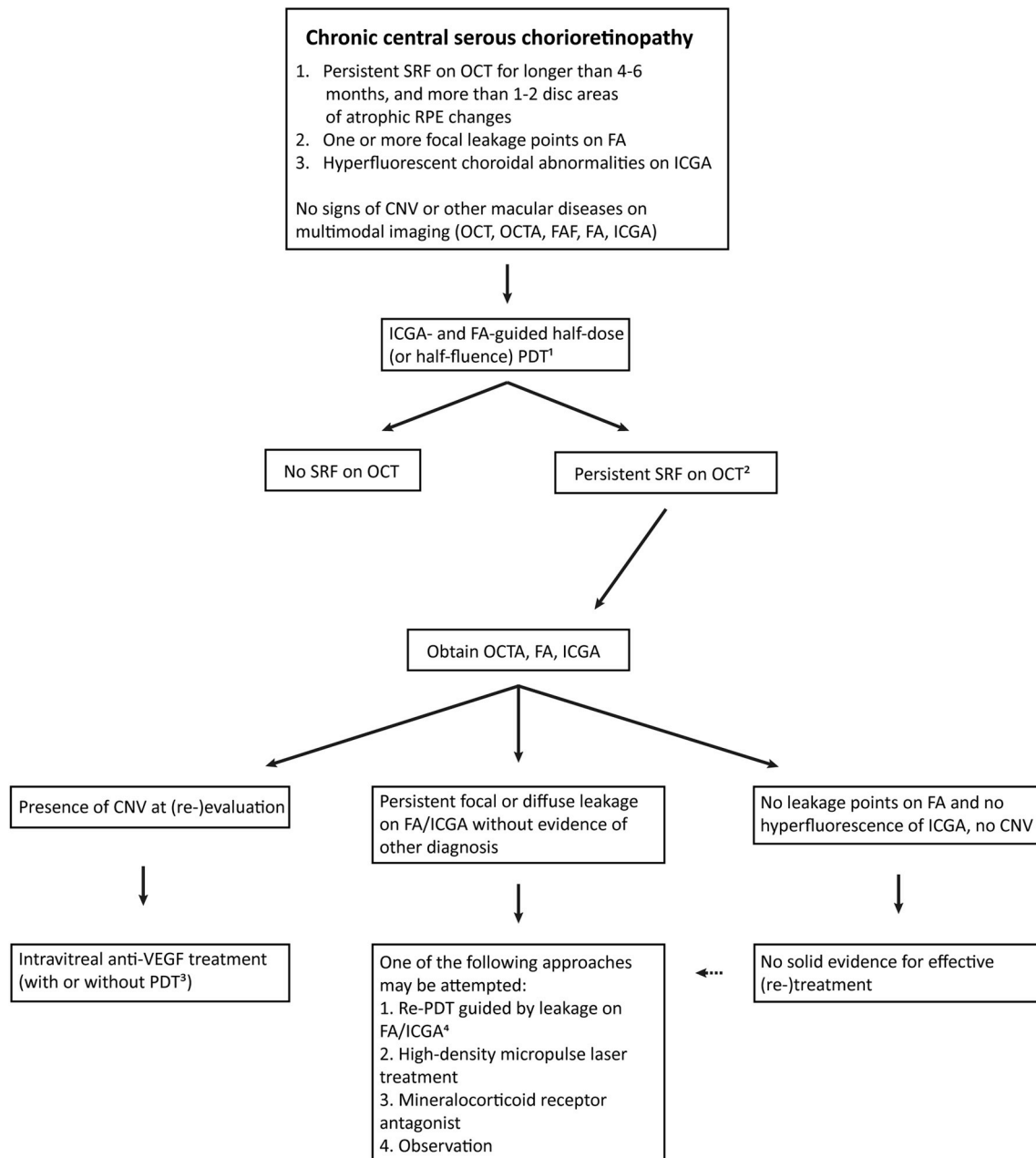
Central serous chorioretinopathy is commonly divided into two categories based on the duration of symptoms, the extent of leakage on angiography, and the presence of RPE atrophy; these two categories are aCSC and cCSC. Chronic CSC can be complicated by CNV and/or PCRD, which may be viewed upon as specific complicated subcategories of cCSC. According to the literature, most investigators support this incomplete and relatively rudimentary classification of CSC. However, there currently is no clear consensus regarding the criteria for classification, and a better defined classification system is needed (Singh et al., 2018). Our current lack of an established classification system complicates the study of the natural disease progression of CSC, its therapeutic management, and the design of interventional trials, which must take into account the relatively early onset maculopathy, the common spontaneous resolution of SRF, and the disease's relatively benign course (Daruich et al., 2015; Mohabati et al., 2018c; Otsuka et al., 2002). Narrowing the scope of clinical CSC subgroups may influence the treatment outcome and may help guiding the development of treatments tailored to each clinical subtype of CSC (Daruich et al., 2015). In this regard, safety is of the utmost importance when developing new treatment strategies for CSC, given that CSC usually presents early in life and has a relatively benign disease course (Daruich et al., 2015; Mohabati et al., 2018c; Otsuka et al., 2002).

### 3.1. Acute CSC

A summarising flowchart with a proposal for decision making in treatment of aCSC is shown in Fig. 7. Because of the high rate of spontaneous SRF resolution within three to four months in aCSC (Klein et al., 1974; Yannuzzi, 2010), observation during the first four months is the most widely used strategy, except in patients who require rapid SRF resolution and visual rehabilitation, for example for professional

reasons, or in cases with outer segment atrophy and/or granular debris in the subretinal space. Although aCSC often resolves spontaneously, retinal damage can still occur in the early phases and may progress as long as the serous neuroretinal detachment persists due to SRF accumulation (Hata et al., 2013). An essential insight gained with OCT is

that the SRF may not be resolved, yet the residual subfoveal fluid can be so shallow that it evades detection by slit-lamp biomicroscopy (Wang et al., 1999). This residual detachment can still lead to atrophy of photoreceptor outer segments and vision loss over a period of years (Wang et al., 2002). Thus, the prevailing clinical recommendation of



**Fig. 8.** Flowchart of the proposed treatment strategy for chronic central serous chorioretinopathy. *If there is current corticosteroid use, possible cessation should be discussed with the patient.*

<sup>1</sup> Treat hyperfluorescent areas on indocyanine green angiography (ICGA) that correspond to the area of (focal) leakage on fluorescein angiography (FA) and subretinal fluid on optical coherence tomography (OCT). In case of multiple areas with focal leakage, a large spot including all areas can be used, or multifocal immediate sequential spots may be used, starting with the area including the fovea (if fovea is involved).

<sup>2</sup> In case of only a small amount of residual subretinal fluid (SRF), a conservative approach may be followed, with a follow-up visit including OCT imaging after 1–3 months to see if SRF eventually resolves completely. In case of persistent/increased SRF at that stage, the downstream treatment path may be followed.

<sup>3</sup> Half-dose or half-fluence photodynamic therapy (PDT) may be added in order to treat the choroidal dysfunction/pachychoroid factor of the disease, but limited data is available to support this combined treatment. When a neovascular component of polypoidal choroidal vasculopathy (aneurysmal type 1 neovascularization) is present, PDT (either full-dose, half-dose, or half-fluence) can also be added to anti-vascular endothelial growth factor treatment.

<sup>4</sup> Another half-dose or half-fluence PDT can be performed, but full-dose with full-fluence PDT may also be considered.

Abbreviations in flow chart: CNV, choroidal neovascularisation; CSC, central serous chorioretinopathy; FA, fluorescein angiography; FAF, fundus autofluorescence; ICGA, indocyanine green angiography; OCT, optical coherence tomography; OCTA, optical coherence tomography angiography; PDT, photodynamic therapy; RPE, retinal pigment epithelium; SRF, subretinal fluid; VEGF, vascular endothelial growth factor.

waiting four months after presentation before considering intervention is not strongly supported by objective evidence. This recommendation also fails to take into consideration the fact that OCT can be used to diagnose atrophic photoreceptor outer segments due to months or years of chronic foveal SRF, even in the absence of RPE abnormalities (Wang et al., 2005).

The goals of an intervention in aCSC should be to reduce the time needed to restore vision and to stabilise the visual prognosis. In practice, this means that SRF should be resolved and recurrent serous neuroretinal detachment should be prevented. Although some treatments such as PDT, HSML, and eplerenone can decrease the time needed to achieve complete resolution of SRF (Arora et al., 2018; Chan et al., 2008a; Sun et al., 2018; Zucchiatti et al., 2018), solid data from large prospective trials are currently lacking, particularly with respect to HSML and eplerenone.

Photocoagulation of a focal leak on angiography can sometimes lead to the rapid and complete resolution of SRF; however, these ‘ideal’ cases – which have a solitary source of leakage at a relatively safe distance from the fovea – are uncommon, and limited evidence is available with respect to long-term efficacy and safety (Leaver and Williams, 1979). Photocoagulation does not clearly address the underlying choroidal leakage, and it carries the risk of inducing CNV, symptomatic paracentral scotoma, and/or a chorioretinal adhesion with secondary intraretinal cystoid oedema (Cardillo Piccolino et al., 2008a; Wang et al., 2008).

Half-dose PDT was shown to increase the likelihood of SRF resolution and improved visual outcome in the sole reasonably-sized prospective, double-masked, placebo-controlled, randomised clinical trial in aCSC conducted to date (Chan et al., 2008a). In addition, retrospective evidence suggests that the risk of recurrence of SRF leakage in aCSC is reduced following PDT (Lu et al., 2016; Nicholson et al., 2013; Ober et al., 2005). Based on current evidence, relatively early treatment (within 4 months of presentation) with half-dose PDT may be considered the treatment of choice in patients with active aCSC who had previous episodes of SRF, patients with bilateral disease activity, and/or patients who rely on their vision for professional reasons. In the event of persistent SRF following half-dose PDT (and upon reconsideration of the initial diagnosis), the clinician may consider re-treatment or another treatment strategy such as an MR antagonist or HSML. ICGA-guided PDT may be the treatment of choice for aCSC, as it may also target the primary choroidal abnormalities; however, large, prospective randomised studies are needed in order to establish a clear basis for an evidence-based approach to treating aCSC.

### 3.2. Chronic CSC

A summarising flowchart with a proposal for decision making in treatment of cCSC is shown in Fig. 8. The persistence of SRF in cCSC is associated with partly irreversible, progressive photoreceptor damage, leading to loss of visual acuity and an accompanying loss of vision-related quality of life (Breukink et al., 2017; Mrejen et al., 2019; Nicholson et al., 2013). Therefore, the aim of treatment should be to stop this progression and to improve vision. The most commonly used treatments for cCSC are PDT, eplerenone, HSML, and argon laser photocoagulation.

HSML can induce complete resolution of SRF in 14–71% of CSC patients (Lanzetta et al., 2008; Ricci et al., 2009; van Dijk et al., 2018b), with a more favourable outcome in patients with a focal leakage spot on FA compared to patients with diffuse leakage (Chen et al., 2008). The PLACE trial, an investigator-initiated study, is the only large, prospective multicentre randomised controlled trial comparing ICGA-guided 810 nm HSML with ICGA-guided half-dose PDT in patients with cCSC (van Dijk et al., 2018b). In this trial, half-dose PDT was superior to HSML in terms of both short-term (6–8 weeks post-treatment) complete resolution of SRF (51% versus 14% of patients, respectively) and long-term (7–8 months post-treatment) complete resolution of SRF (67%

versus 29% of patients, respectively). Moreover, at 6–8 weeks, both the increase in BCVA and retinal sensitivity on microperimetry were significantly higher in the half-dose PDT group compared to the HSML group (van Dijk et al., 2018b). No comparable data are available for HSML using a 577 nm laser. In addition to significant differences in treatment efficacy measured the PLACE trial, the value of using HSML to treat cCSC is further complicated by the wide range of treatment regimens, laser settings, and wavelengths that have been reported thus far (Wood et al., 2017).

Treatment with MR antagonists has been associated with complete resolution of the neuroretinal detachment in 20–66% of patients (Bousquet et al., 2013; Cakir et al., 2016; Daruich et al., 2016; Rahimy et al., 2018; Rajesh et al., 2018; Sampo et al., 2016; Singh et al., 2015). Although spironolactone and eplerenone appear to be similarly effective at their respective preferred doses (Pichi et al., 2017), eplerenone is preferred due to its favourable safety profile. Recurrences of SRF are more likely to occur after spironolactone than after half-dose PDT (Kim et al., 2019). The current evidence available from clinical studies is considerably less convincing for MR antagonists compared to PDT and HSML, which stems primarily from retrospective studies that reported lower rates of SRF resolution compared to PDT.

The results of the PLACE trial are supported by a large body of retrospective evidence indicating that 62–100% of patients with cCSC can achieve complete SRF resolution following PDT (Lai et al., 2016; Nicolo et al., 2012; Stewart, 2006; Tseng and Chen, 2015), with reported patients numbers that are vastly higher than those studied in both HSML and eplerenone treatment. Although no large study has compared MR antagonists with PDT, such a study is currently underway (see section 4.2, SPECTRA trial). Importantly, the risk of treatment-related side effects is relatively low, and neither eplerenone nor PDT treatment appears to induce permanent damage to the choriocapillaris (Rabiolo et al., 2018).

Laser photocoagulation may be considered for patients with cCSC with focal leakage located outside of the macular area, for example when PDT is either unavailable at the treatment centre or cost-prohibitive. However, long-term outcome following photocoagulation does not appear to be superior to no treatment (i.e. observation), although the evidence to date is relatively scarce (Gilbert et al., 1984). On the other hand, other treatments such as half-dose PDT do not have these limitations and have good long-term safety profiles, with few reported side effects (Tseng and Chen, 2015).

Based on currently available data, half-dose or half-fluence PDT appears to be the most effective and safest treatment for cCSC without additional complications. However, it should be noted that half-dose PDT treatment with verteporfin is considerably more expensive compared to some other treatments, and requires the use of a specific laser machine. When half-dose PDT is unavailable and/or cost-prohibitive, other treatments can be considered, including focal argon laser at eccentric focal leakage points on FA, MR antagonists, and HSML (Chhablani et al., 2014; Nicholson et al., 2013); the choice of treatment should be based on a case-by-case discussion, as robust evidence with respect to these non-PDT treatment modalities is currently lacking. Half-dose or half-fluence PDT may also be considered in symptomatic cCSC patients with SRF outside the fovea (van Dijk et al., 2017a). In the case of persistent SRF following half-dose PDT, re-treatment with PDT or another treatment such as MR antagonists or HSML may be considered (Scholz et al., 2015). Moreover, further research – preferably prospective studies – is needed in order to determine whether the relatively small subgroup of patients who have extensive atrophic RPE changes that include the fovea should be excluded from PDT due to the risk of irreversible mild to moderate vision loss, which was reported to occur in up to 2% of patients in this highly specific subtype of severe cCSC (Mohabati et al., 2018b). Alternative treatments such as MR antagonists and HSML may be considered in this subgroup of patients with severe cCSC that includes atrophic RPE changes affecting the fovea, even though these treatments appear to be less effective than PDT in

accomplishing resolution of SRF accumulation in these cases (Ramos-Yau et al., 2018; Zola et al., 2018).

### 3.2.1. Chronic CSC complicated by subretinal neovascularisation

Macular subretinal neovascularisation can occur in patients with CSC, and presents most often in patients with severe cCSC (Peiretti et al., 2015) (Fig. 3). Moreover, CNV was reported to occur in 2–18% of cCSC patients (Fung et al., 2012; Loo et al., 2002; Nicholson et al., 2018; Shiragami, 2018; Spaide et al., 1996a). Although CNV can be present at the start of a CSC episode, it can also develop gradually, particularly in patients over the age of 50 and/or patients with prolonged disease. Subretinal leakage from type 1 (sub-RPE) neovascularisation due to pachychoroid neovascularopathy can mimic uncomplicated cCSC (Fung et al., 2012; Pang and Freund, 2015). CNV can be identified using multimodal imaging techniques such as OCT, FA, ICGA, and – in particular – OCT angiography (Fig. 3), although this detection can be challenging in small, early-stage CNV and severe cCSC with extensive chorioretinal abnormalities. Therefore, it may not be uncommon for a patient to be initially diagnosed with having CSC without CNV, even though a small CNV may have actually been present at the time of diagnosis. The clinician should suspect CNV particularly in patients who were relatively old at onset, have a mid/hyperreflective signal below a flat irregular RPE detachment (Fig. 3A), a putative CNV structure on OCT angiography (Fig. 3F and G), and/or a well-demarcated CNV ‘plaque’ (with or without a polypoidal component) on ICGA (Fig. 3E). Because up to two-thirds of patients with CSC with CNV can have a polypoidal component, ICGA is an important imaging tool for identifying and localising these polypoidal structures.

The standard treatment for CSC complicated by active subretinal CNV is intravitreal anti-VEGF treatment possibly supplemented by half-dose or half-fluence PDT, as several studies have demonstrated good efficacy in these cases (Chhablani et al., 2015, 2016; Lai et al., 2018; Peiretti et al., 2018). For example, the MINERVA study found that intravitreal ranibizumab is effective in CNV with an unusual origin, including CNV due to CSC (Lai et al., 2018). At the primary endpoint (2 months), the authors found that eyes with CNV due to CSC treated with ranibizumab had an improvement in BCVA of 6.6 ETDRS letters, compared with only 1.6 letters in the sham group (Lai et al., 2018). With respect to polypoidal choroidal vasculopathy, large randomised controlled trials based on the EVEREST II and PLANET studies found that a combination of full-dose PDT and intravitreal ranibizumab or aflibercept were beneficial (Koh et al., 2017; Lee et al., 2018). In addition, Peiretti and colleagues recently reported that 50% of polypoidal lesions were closed after full-fluence PDT monotherapy, compared to 25% of lesions in patients who received anti-VEGF monotherapy (Peiretti et al., 2018). An interesting group of patients with vascularised CSC is characterised by flat irregular PEDs in which a thin neovascular network can be detected on OCT angiography but not with other imaging techniques (Quaranta-El Maftouhi et al., 2015). This so-called ‘silent type 1 CNV’ may actually be quite common in cCSC (Quaranta-El Maftouhi et al., 2015). However, given that the contribution of this type of CNV to subretinal leakage, as well as its role in the progression of vision loss, has not been investigated, the use of anti-VEGF therapy in these cases should be weighed carefully and may be deferred until active leakage becomes evident.

### 3.2.2. Severe chronic CSC

Because of the likelihood of progressing to severe vision loss, treatment should be advocated for patients with cCSC complicated by PCRD. However, the efficacy of standard PDT and half-dose PDT is relatively poor in this patient group (Cardillo Piccolino et al., 2003; Nicolo et al., 2012). Using various reduced-setting PDT protocols in 25 eyes with severe cCSC with PCRD, Mohabati and colleagues achieved complete resolution of intraretinal fluid in 11 eyes (44%), reduced PCRD in 12 eyes (48%), and observed no changes in 2 eyes (8%) at first visit after treatment (Mohabati et al., 2018b). In contrast, Silva and

colleagues reported complete resolution of intraretinal fluid in 10 out of 10 patients with cCSC and PCRD after treatment with full-setting PDT (Silva et al., 2013). The relatively poor responses to PDT could be due to the degenerative pathophysiological nature of PCRD in cCSC, in which factors other than persistent SRF and choroidal-RPE dysfunction become relevant once PCRD becomes chronic. Inconsistent results obtained after using PDT for cCSC with PCRD – regardless of the PDT setting used – may also be due to relatively common presence of diffuse atrophic RPE changes, which can make it difficult to select the area for laser treatment. In evaluating these results, it should be also noted that intraretinal fluid may be reabsorbed at a slower rate than SRF (Cardillo Piccolino, 2010; Mohabati et al., 2018b). Moreover, a strong topographic correlation has been found between the cystoid intraretinal spaces and points of chorioretinal adherence at the site of subretinal atrophy and fibrosis (Cardillo Piccolino et al., 2008a, 2008b). Subretinal fibrotic scars have also been reported to develop from subretinal fibrin in eyes with severe CSC (Schatz et al., 1995). These scars may represent focal areas of chorioretinal adherence and breakdown of the RPE barrier, providing a direct passage for fluid to diffuse from the choroid into the retina in the case of choroidal hyperperfusion (Cardillo Piccolino et al., 2008a, 2008b). OCT angiography, FA, and/or ICGA should be performed to rule out the possibility of CNV in patients with cCSC patients with intraretinal fluid, as up to 45% of these cases may indeed have CNV and should be treated accordingly (see section 3.2.1) (Sahoo et al., 2019).

### 3.3. Unclear cases

Some patients do not fit into the classification systems discussed above. For example, in some cases the presence of CNV can be ambiguous. In cases in which the diagnosis is not clear, determining the optimal treatment can be challenging. In such cases, the treatment strategy may depend on a variety of factors, including the patient's wishes, the BCVA and age, the prognosis with respect to disease progression, the treating physician's personal preferences, and a range of other clinical and non-clinical parameters.

## 4. Future perspectives

The results of several ongoing prospective randomised controlled clinical trials will be available in the next few years. These studies include the investigator-initiated multicentre VICI and SPECTRA trials, both of which are expected to report their results within the coming two years.

### 4.1. VICI trial

The VICI trial (‘Clinical efficacy and mechanistic evaluation of eplerenone for central serous chorio-retinopathy – the VICI randomised trial’; ISRCTN registry: 92746680) is the first large, prospective multicentre randomised placebo-controlled trial designed to investigate the use of eplerenone in treating cCSC (Willcox et al., 2019). In this trial, 104 patients with cCSC are randomly allocated to receive either eplerenone or sham treatment. The primary outcome of the VICI trial is BCVA measured at the 12-month follow-up visit. Secondary outcomes include low luminance visual acuity, central macular thickness, height of the SRF, choroidal thickness, and adverse events. The placebo-controlled aspect of this trial will provide valuable information regarding the natural course of cCSC, as both aCSC and cCSC can resolve spontaneously without treatment.

### 4.2. SPECTRA trial

The Study on half-dose Photodynamic therapy versus Eplerenone in chronic CentRAL serous chorioretinopathy (SPECTRA trial, ClinicalTrials.gov identifier: NCT03079141) is the first prospective

multicentre randomised controlled trial designed to compare half-dose PDT with eplerenone treatment with respect to achieving complete resolution of SRF and improving the quality of vision. This study follows the PLACE trial, in which PDT was found to be superior to treatment with HSML in cCSC (van Dijk et al., 2018b). The target number of patients to be included in the SPECTRA trial is 107. The primary endpoint of the SPECTRA trial is a measure of the difference between half-dose PDT and eplerenone treatment in patients with cCSC in terms of both complete resolution of SRF on OCT and safety. The secondary functional endpoints include BCVA (in ETDRS letters), retinal sensitivity on macular microperimetry, and vision-related quality of life measured using a validated questionnaire (NEI-VFQ-25). Additional secondary endpoints include the number of patients who receive crossover treatment in each treatment arm, the mean change in ETDRS BCVA over time among those patients with subsequent treatment (i.e. crossover) and patients without subsequent treatment, and the mean changes in ETDRS BCVA, retinal sensitivity, and NEI-VFQ-25 over time. These parameters are obtained up to two years after enrolment.

#### 4.3. Towards an evidence-based treatment guideline

The results of these trials and other large studies will likely lead to an evidence-based treatment guideline for CSC. At the same time, it is just as important to more accurately define the subtypes of CSC by performing detailed multimodal imaging studies. These studies will facilitate reaching a consensus regarding the classification of CSC, which is urgently needed given that the optimal treatment strategy likely differs among CSC subtypes. It is also essential that intervention studies use comparable clinical endpoints and aim to achieve complete resolution of the serous neuroretinal detachment (van Rijssen et al., 2018a). In this respect, artificial intelligence and 'deep learning' are likely to become important in the diagnosis and follow-up care of retinal diseases, including CSC (De Fauw et al., 2018). For example, artificial intelligence can be used to discover new characteristics and prognostic markers in CSC by analysing large amounts of annotated multimodal imaging data. Deep learning protocols and artificial intelligence may also reveal CSC-specific patterns on multimodal imaging. With the addition of clinical parameters, it may one day be possible to develop an algorithm to support treatment decisions. Moreover, large studies regarding genetic and other risk factors may shed new light on the pathophysiology of CSC. For example, recent studies revealed similar genetic risk loci with partly opposite effects between CSC and AMD (Miki et al., 2018; Mohabati et al., 2018; Schellevis et al., 2018). These findings may also have future implications for treating CSC. With the ability to culture choroidal endothelial cells (Brinks et al., 2018), it may now be possible to study the effects of various substances such as corticosteroids using an *in vitro* approach. Studies involving these *in vitro* choroidal cell models may eventually lead to the identification of pathophysiological pathways in CSC and help develop new treatment strategies for CSC. Another emerging topic of interest that warrants further study with respect to preventing and treating CSC is based on the haemodynamic condition of patients with CSC. A growing body of evidence suggests that patients with CSC may have a functional change in the physiological mechanisms that regulate choroidal blood flow, and this change may even be induced by emotional and/or physical stress (Cardillo Piccolino et al., 2018; Roybal et al., 2018; Tittl et al., 2005).

## 5. Conclusions

The classification and treatment of CSC has long been – and remains today – subject to controversy. In recent years, several relatively large studies regarding the treatment of CSC have been published, some of which were conducted in a multicentre prospective randomised controlled setting. Based on the subtypes of CSC that were roughly defined in these studies, the treatment outcomes and treatment strategies of

choice are slowly evolving. With respect to aCSC, treatment can often be deferred, unless specific circumstances such as professional reliance on optimal vision indicate intervention. When treatment is indicated in aCSC, the current evidence suggests that half-dose or half-fluence PDT guided by either ICGA or FA may be the treatment of choice for accelerating SRF resolution, improving vision, and decreasing the risk of recurrence.

Based on efficacy and safety data from retrospective and prospective studies such as the prospective multicentre randomised controlled PLACE trial, half-dose (or half-fluence) PDT should be considered the treatment of choice for cCSC. Thus, the available evidence to support the use of PDT in cCSC may also alleviate current restrictions in reimbursement for this off-label treatment indication. In elderly patients who present with a clinical picture of CSC, the presence of a shallow RPE detachment with mid- or mixed reflectivity below the RPE detachment is highly suggestive of a neovascular membrane, which can be confirmed using OCT angiography and ICGA. ICGA can also be used to visually determine whether such a sub-RPE neovascular membrane has a polypoidal component. Evidence suggests that these CSC cases with subretinal CNV should be treated using intravitreal injections of anti-VEGF compounds and/or half-dose or half-fluence PDT. In the case of polypoidal choroidal vasculopathy, intravitreal anti-VEGF either as a monotherapy or combined with PDT should be considered for targeting the choroidal abnormalities such as pachychoroid and hyperpermeability, as well as the neovascular and/or polypoidal component. Large multicentre randomised controlled trials are currently underway and will likely shed more light on the efficacy of various treatments such as eplerenone, providing a better comparative overview of the principal treatment options that are currently available. The controversy regarding the classification of CSC and the desired clinical endpoints of treatment remain important topics that will need to be addressed in order to optimise the design of future randomised controlled trials. The outcome of these studies will certainly facilitate the establishment of an evidence-based treatment guideline for CSC.

#### Author statement

#### Competing Interests

no conflicting relationship exists for any author.

#### Funding

This work was supported by the following foundations: MaculaFonds, Retina Netherlands, BlindenPenning, and Landelijke Stichting voor Blinden en Slechtienden, that contributed through Uitzicht, as well as Rotterdamse Stichting Blindenbelangen, Haagse Stichting Blindenhulp, ZonMw VENI Grant, and Gisela Thier Fellowship of Leiden University (CJFB).

#### Role of funding organizations

The funding organizations had no role in the design or conduct of the study; collection, management, analysis, and interpretation of the data; preparation, review, or approval of the manuscript; and decision to submit the manuscript for publication. They provided unrestricted grants.

Components of the study were facilitated by ERN-EYE, the European Reference Network for Rare Eye Diseases.

#### Financial disclosures

FGH: Consultant to Acucela, Apellis, Allergan, Formycon, Galimedix, Grayburg Vision, Heidelberg Engineering, Novartis, Bayer, Ellex, Oxurion, Roche/Genentech, Zeiss. Research grants from Acucela, Allergan, Apellis, Formycon, Ellex, Heidelberg Engineering, Novartis,

Bayer, CenterVue.

Heidelberg Engineering, Roche/Genentech, NightStar X, Zeiss.  
KBF: consultant to Zeiss, Heidelberg Engineering, Optovue, Novartis, and Allergan. He receives research support from Genentech/Roche.

ML: ML and his employer the Rigshospitalet have received payments for the conduct of clinical trials and consulting fees from Novartis, Alcon, Bayer, Roche, Oculis, Sanofi, Novo Nordisk, Acucela, AbbVie and GSK.

SF: employee (Hoffman-La Roche, Basel, Switzerland).

SS: received travel grants, research grants, attended advisory board meetings of Novartis, Allergan, Bayer, Roche, Boehringer Ingelheim, Optos.

TYYL: received honorarium for consultancy and lecture fees from Allergan, Bayer, Boehringer Ingelheim, Novartis and Roche; research support from Kanghong Biotech, Novartis, and Roche; and travel grants from Santen.

No financial disclosures exist for any of the other authors.

## References

- Abalem, M.F., Machado, M.C., Santos, H.N., Garcia, R., Helal Jr., J., Carricondo, P.C., Pimentel, S.L., Monteiro, M.L., Qian, C.X., Bronstein, M.D., Fragoso, M.C., 2016. Choroidal and retinal abnormalities by optical coherence tomography in endogenous cushing's syndrome. *Front. Endocrinol.* 7, 154.
- Abd Elhamid, A.H., 2015. Subthreshold micropulse yellow laser treatment for nonresolving central serous chorioretinopathy. *Clin. Ophthalmol.* 9, 2277–2283.
- Abrishami, M., Mousavi, M., Hosseini, S.M., Norouzpour, A., 2015. Treatment of chronic central serous chorioretinopathy with oral methotrexate. *J. Ocul. Pharmacol. Ther.* 31, 468–475.
- Agrawal, R., Chhablani, J., Tan, K.A., Shah, S., Sarvaiya, C., Banker, A., 2016. Choroidal vascularity index in central serous chorioretinopathy. *Retina* 36, 1646–1651.
- Alkin, Z., Osmanbasoglu, O.A., Ozkaya, A., Karatas, G., Yazici, A.T., 2013. Topical nepafenac in treatment of acute central serous chorioretinopathy. *Med. Hypothesis, Discov. Innovation (MEHDI) Ophthalmol.* 2, 96–101.
- Alkin, Z., Perente, I., Ozkaya, A., Alp, D., Agca, A., Ayyigit, E.D., Korkmaz, S., Yazici, A.T., Demirok, A., 2014. Comparison of efficacy between low-fluence and half-dose verteporfin photodynamic therapy for chronic central serous chorioretinopathy. *Clin. Ophthalmol.* 8, 685–690.
- Ambiya, V., Goud, A., Mathai, A., Rani, P.K., Chhablani, J., 2016. Microsecond yellow laser for subfoveal leaks in central serous chorioretinopathy. *Clin. Ophthalmol.* 10, 1513–1519.
- Arias, J.D., Kumar, N., Fulco, E.A., Spaide, R., Yannuzzi, L., Shields, J.A., Shields, C.L., 2013. The seasick choroid: a finding on enhanced depth imaging spectral-domain optical coherence tomography of choroidal lymphoma. *Retin. Cases Brief Rep.* 7, 19–22.
- Arif, F., Pryds, A., Larsen, M., 2018. Isolated pigment epithelium detachment: evidence for relation to central serous chorioretinopathy and effect of photodynamic therapy. *Acta Ophthalmol.* 96, 821–827.
- Arnold, J.J., Blinder, K.J., Bressler, N.M., Bressler, S.B., Burdan, A., Haynes, L., Lim, J.I., Miller, J.W., Potter, M.J., Reaves, A., Rosenfeld, P.J., Sickenberg, M., Slakter, J.S., Soubbrane, G., Strong, H.A., Stur, M., 2004. Acute severe visual acuity decrease after photodynamic therapy with verteporfin: case reports from randomized clinical trials-tap and vip report no. 3. *Am. J. Ophthalmol.* 137, 683–696.
- Arora, S., Sridharan, P., Arora, T., Chhabra, M., Ghosh, B., 2018. Subthreshold diode micropulse laser versus observation in acute central serous chorioretinopathy. *Clin. Exp. Optom.* 102, 79–85.
- Arsan, A., Kanar, H.S., Sonmez, A., 2018. Visual outcomes and anatomic changes after sub-threshold micropulse yellow laser (577-nm) treatment for chronic central serous chorioretinopathy: long-term follow-up. *Eye* 32, 726–733.
- Artunay, O., Yuzbasioglu, E., Rasier, R., Sengul, A., Bahcecioglu, H., 2010. Intravitreal bevacizumab in treatment of idiopathic persistent central serous chorioretinopathy: a prospective, controlled clinical study. *Curr. Eye Res.* 35, 91–98.
- Ashraf, H., Jamshidian, M., Khalili, M.R., Zare, M., Shamsi, A., 2018. Subthreshold continuous wave autofluorescence-controlled laser treatment of chronic central serous chorioretinopathy. *J. Ophthalmic Vis. Res.* 13, 236–240.
- Aydin, E., 2013. The efficacy of intravitreal bevacizumab for acute central serous chorioretinopathy. *J. Ocul. Pharmacol. Ther.* 29, 10–13.
- Azab, M., Benchaboune, M., Blinder, K.J., Bressler, N.M., Bressler, S.B., Gragoudas, E.S., Fish, G.E., Hao, Y., Haynes, L., Lim, J.I., Menchini, U., Miller, J.W., Mones, J., Potter, M.J., Reaves, A., Rosenfeld, P.J., Strong, A., Su, X.Y., Slakter, J.S., Schmidt-Erfurth, U., Sorenson, J.A., 2004. Verteporfin therapy of subfoveal choroidal neovascularization in age-related macular degeneration: meta-analysis of 2-year safety results in three randomized clinical trials: treatment of age-related macular degeneration with photodynamic therapy and verteporfin in photodynamic therapy study report no. 4. *Retina* 24, 1–12.
- Bae, S.H., Heo, J., Kim, C., Kim, T.W., Shin, J.Y., Lee, J.Y., Song, S.J., Park, T.K., Moon, S.W., Chung, H., 2014. Low-fluence photodynamic therapy versus ranibizumab for chronic central serous chorioretinopathy: one-year results of a randomized trial. *Ophthalmology* 121, 558–565.
- Bae, S.H., Heo, J.W., Kim, C., Kim, T.W., Lee, J.Y., Song, S.J., Park, T.K., Moon, S.W., Chung, H., 2011. A randomized pilot study of low-fluence photodynamic therapy versus intravitreal ranibizumab for chronic central serous chorioretinopathy. *Am. J. Ophthalmol.* 152, 784–792 e782.
- Bagheri, M., Rashe, Z., Ahoor, M.H., Somi, M.H., 2017. Prevalence of helicobacter pylori infection in patients with central serous chorioretinopathy: a review. *Med. Hypothesis, Discov. Innovation (MEHDI) Ophthalmol.* 6, 118–124.
- Baker, P.S., Garg, S.J., Fineman, M.S., Chiang, A., Alshareef, R.A., Belmont, J., Brown, G.C., 2013. Serous macular detachment in waldenstrom macroglobulinemia: a report of four cases. *Am. J. Ophthalmol.* 155, 448–455.
- Balaratnasingam, C., Freund, K.B., Tan, A.M., Mrejen, S., Hunyor, A.P., Keegan, D.J., Dansingani, K.K., Dayani, P.N., Barbazetto, I.A., Sarraf, D., Jampol, L.M., Yannuzzi, L.A., 2016. Bullous variant of central serous chorioretinopathy: expansion of phenotypic features using multimethod imaging. *Ophthalmology* 123, 1541–1552.
- Baran, N.V., Gurlu, V.P., Esgin, H., 2005. Long-term macular function in eyes with central serous chorioretinopathy. *Clin. Exp. Ophthalmol.* 33, 369–372.
- Bazzazi, N., Ahmadvanah, M., Akbarzadeh, S., Seif Rabiei, M.A., Holsboer-Trachsler, E., Brand, S., 2015. In patients suffering from idiopathic central serous chorioretinopathy, anxiety scores are higher than in healthy controls, but do not vary according to sex or repeated central serous chorioretinopathy. *Neuropsychiatric Dis. Treat.* 11, 1131–1136.
- Beger, I., Koss, M.J., Koch, F., 2012. [treatment of central serous chorioretinopathy: micropulse photocoagulation versus bevacizumab]. *Der Ophthalmologe* 109, 1224–1232.
- Behnia, M., Khabazkhoob, M., Aliakbari, S., Abadi, A.E., Hashemi, H., Pourvahidi, P., 2013. Improvement in visual acuity and contrast sensitivity in patients with central serous chorioretinopathy after macular subthreshold laser therapy. *Retina* 33, 324–328.
- Benner, J.D., Ahuja, R.M., Butler, J.W., 2002. Macular infarction after transpupillary thermotherapy for subfoveal choroidal neovascularization in age-related macular degeneration. *Am. J. Ophthalmol.* 134, 765–768.
- Bennett, G., 1955. Central serous retinopathy. *Br. J. Ophthalmol.* 39, 605–618.
- Bergen, A.A., Arya, S., Koster, C., Pilgrim, M.G., Wiatrek-Moumoulidis, D., van der Spek, P.J., Hauck, S.M., Boon, C.J.F., Emri, E., Stewart, A.J., Lengyel, I., 2019. On the origin of proteins in human drusen: the meet, greet and stick hypothesis. *Prog. Retin. Eye Res.* 70, 55–84.
- Bhutto, I., Luty, G., 2012. Understanding age-related macular degeneration (amd): relationships between the photoreceptor/retinal pigment epithelium/bruch's membrane/choriocapillaris complex. *Mol. Asp. Med.* 33, 295–317.
- Birnbaum, A.D., Blair, M.P., Tessler, H.H., Goldstein, D.A., 2010. Subretinal fluid in acute posterior multifocal placoid pigment epitheliopathy. *Retina* 30, 810–814.
- Boni, C., Kloos, P., Valmaggia, C., 2012. New guidelines in the treatment of persistent central serous chorioretinopathy: pdt with half-dose verteporfin. *Klin. Monatsblätter Augenheilkd.* 229, 327–330.
- Boon, C.J., Klevering, B.J., Leroy, B.P., Hooyng, C.B., Keunen, J.E., den Hollander, A.I., 2009. The spectrum of ocular phenotypes caused by mutations in the best1 gene. *Prog. Retin. Eye Res.* 28, 187–205.
- Boon, C.J., van den Born, L.I., Visser, L., Keunen, J.E., Bergen, A.A., Boonij, J.C., Riemslag, F.C., Florijn, R.J., van Schooneveld, M.J., 2013. Autosomal recessive bestrophinopathy: differential diagnosis and treatment options. *Ophthalmology* 120, 809–820.
- Borrelli, E., Sarraf, D., Freund, K.B., Sadda, S.R., 2018. Oct angiography and evaluation of the choroid and choroidal vascular disorders. *Prog. Retin. Eye Res.* 67, 30–55.
- Bousquet, E., Beydoun, T., Rothschild, P.R., Bergin, C., Zhao, M., Batista, R., Brandely, M.L., Couraud, B., Farman, N., Gaudric, A., Chast, F., Behar-Cohen, F., 2015. Spirolactone for nonresolving central serous chorioretinopathy: a randomized controlled crossover study. *Retina* 35, 2505–2515.
- Bousquet, E., Beydoun, T., Zhao, M., Hassan, L., Offret, O., Behar-Cohen, F., 2013. Mineralocorticoid receptor antagonism in the treatment of chronic central serous chorioretinopathy: a pilot study. *Retina* 33, 2096–2102.
- Bousquet, E., Dhundass, M., Lehmann, M., Rothschild, P.R., Bayon, V., Leger, D., Bergin, C., Dirani, A., Beydoun, T., Behar-Cohen, F., 2016. Shift work: a risk factor for central serous chorioretinopathy. *Am. J. Ophthalmol.* 165, 23–28.
- Bousquet, E., Dhundass, M., Lejoyeux, R., Shinjima, A., Krivosic, V., Mrejen, S., Gaudric, A., Tadayoni, R., 2019. Predictive factors of response to mineralocorticoid receptor antagonists in nonresolving central serous chorioretinopathy. *Am. J. Ophthalmol.* 198, 80–87.
- Bouzas, E.A., Scott, M.H., Mastorakos, G., Chrousos, G.P., Kaiser-Kupfer, M.I., 1993. Central serous chorioretinopathy in endogenous hypercortisolism. *Arch. Ophthalmol.* 111, 1229–1233.
- Breukink, M.B., Dingemans, A.J., den Hollander, A.I., Keunen, J.E., MacLaren, R.E., Fauser, S., Querques, G., Hoyng, C.B., Downes, S.M., Boon, C.J., 2017. Chronic central serous chorioretinopathy: long-term follow-up and vision-related quality of life. *Clin. Ophthalmol.* 11, 39–46.
- Breukink, M.B., Mohabati, D., van Dijk, E.H., den Hollander, A.I., de Jong, E.K., Dijkman, G., Keunen, J.E., Hoyng, C.B., Boon, C.J., 2016a. Efficacy of photodynamic therapy in steroid-associated chronic central serous chorioretinopathy: a case-control study. *Acta Ophthalmol.* 94, 565–572.
- Breukink, M.B., Mohr, J.K., Ossawaarde-van Norel, A., den Hollander, A.I., Keunen, J.E., Hoyng, C.B., Boon, C.J., 2016b. Half-dose photodynamic therapy followed by diode micropulse laser therapy as treatment for chronic central serous chorioretinopathy: evaluation of a prospective treatment protocol. *Acta Ophthalmol.* 94, 187–197.
- Breukink, M.B., Schellevis, R.L., Boon, C.J., Fauser, S., Hoyng, C.B., den Hollander, A.I., de Jong, E.K., 2015. Genomic copy number variations of the complement component c4b gene are associated with chronic central serous chorioretinopathy. *Investig. Ophthalmol. Vis. Sci.* 56, 5608–5613.

- Brinks, J., van Dijk, E.H.C., Habeeb, M., Nikolaou, A., Tsonaka, R., Peters, H.A.B., Sips, H.C.M., van de Merbel, A.F., de Jong, E.K., Notenboom, R.G.E., Kielbasa, S.M., van der Maarel, S.M., Quax, P.H.A., Meijer, O.C., Boon, C.J.F., 2018. The effect of corticosteroids on human choroidal endothelial cells: a model to study central serous chorioretinopathy. *Investig. Ophthalmol. Vis. Sci.* 59, 5682–5692.
- Brown, J.S., Flitcroft, D.I., Ying, G.S., Francis, E.L., Schmid, G.F., Quinn, G.E., Stone, R.A., 2009. In vivo human choroidal thickness measurements: evidence for diurnal fluctuations. *Investig. Ophthalmol. Vis. Sci.* 50, 5–12.
- Browning, D.J., 1993. Nadolol in the treatment of central serous retinopathy. *Am. J. Ophthalmol.* 116, 770–771.
- Burumcek, E., Mudun, A., Karacoru, S., Arslan, M.O., 1997. Laser photocoagulation for persistent central serous retinopathy: results of long-term follow-up. *Ophthalmology* 104, 616–622.
- Caccavale, A., Romanazzi, F., Imparato, M., Negri, A., Morano, A., Ferentini, F., 2010. Low-dose aspirin as treatment for central serous chorioretinopathy. *Clin. Ophthalmol.* 4, 899–903.
- Cadepond, F., Ulmann, A., Baulieu, E.E., 1997. Ru486 (mifepristone): mechanisms of action and clinical uses. *Annu. Rev. Med.* 48, 129–156.
- Caillaux, V., Gaucher, D., Gualino, V., Massin, P., Tadayoni, R., Gaudric, A., 2013. Morphologic characterization of dome-shaped macula in myopic eyes with serous macular detachment. *Am. J. Ophthalmol.* 156, 958–967 e951.
- Cakir, B., Fischer, F., Ehlken, C., Buhler, A., Stahl, A., Schlunck, G., Bohringer, D., Agostini, H., Lange, C., 2016. Clinical experience with eplerenone to treat chronic central serous chorioretinopathy. *Graefes Arch. Clin. Exp. Ophthalmol.* 254, 2151–2157.
- Cardillo Piccolino, F., 2010. Effect of ocular contusion in a patient with chronic central serous chorioretinopathy. *Retin. Cases Brief Rep.* 4, 47–50.
- Cardillo Piccolino, F., Borgia, L., Zinicola, E., Zingirian, M., 1995. Indocyanine green angiographic findings in central serous chorioretinopathy. *Eye* 9 (Pt 3), 324–332.
- Cardillo Piccolino, F., De La Longrais, R.R., Manea, M., Cicinelli, S., 2008a. Posterior cystoid retinal degeneration in central serous chorioretinopathy. *Retina* 28, 1008–1012.
- Cardillo Piccolino, F., De La Longrais, R.R., Manea, M., Cicinelli, S., Ravera, G., 2008b. Risk factors for posterior cystoid retinal degeneration in central serous chorioretinopathy. *Retina* 28, 1146–1150.
- Cardillo Piccolino, F., de la Longrais, R.R., Ravera, G., Eandi, C.M., Ventre, L., Abdullahi, A., Manea, M., 2005. The foveal photoreceptor layer and visual acuity loss in central serous chorioretinopathy. *Am. J. Ophthalmol.* 139, 87–99.
- Cardillo Piccolino, F., Eandi, C.M., Ventre, L., Rigault de la Longrais, R.C., Grignolo, F.M., 2003. Photodynamic therapy for chronic central serous chorioretinopathy. *Retina* 23, 752–763.
- Cardillo Piccolino, F., Lupidi, M., Cagini, C., Fruttini, D., Nicolo, M., Eandi, C.M., Tito, S., 2018. Choroidal vascular reactivity in central serous chorioretinopathy. *Investig. Ophthalmol. Vis. Sci.* 59, 3897–3905.
- Carvalho-Recchia, C.A., Yannuzzi, L.A., Negro, S., Spaide, R.F., Freund, K.B., Rodriguez-Coleman, H., Lenharo, M., Iida, T., 2002. Corticosteroids and central serous chorioretinopathy. *Ophthalmology* 109, 1834–1837.
- Casalino, G., Del Turco, C., Corvi, F., Rafaeeli, O., Bandello, F., Querques, G., 2016. Short-term retinal sensitivity and metamorphopsia changes following half-fluence photodynamic therapy in central serous chorioretinopathy. *Ophthalmic Res.* 56, 23–29.
- Castro-Correia, J., Coutinho, M.F., Rosas, V., Maia, J.J.D.O., 1992. Long-term follow-up of central serous retinopathy in 150 patients. *Eye* 11, 379–386.
- Chai, Y., Liu, R.Q., Yi, J.L., Ye, L.H., Zou, J., Jiang, N., Shao, Y., 2016. Clinical research of fenofibrate and spironolactone for acute central serous chorioretinopathy. *Int. J. Ophthalmol.* 9, 1444–1450.
- Chan, S.Y., Wang, Q., Wei, W.B., Jonas, J.B., 2016. Optical coherence tomographic angiography in central serous chorioretinopathy. *Retina* 36, 2051–2058.
- Chan, W.M., Lai, T.Y., Lai, R.Y., Liu, D.T., Lam, D.S., 2008a. Half-dose verteporfin photodynamic therapy for acute central serous chorioretinopathy: one-year results of a randomized controlled trial. *Ophthalmology* 115, 1756–1765.
- Chan, W.M., Lai, T.Y., Lai, R.Y., Tang, E.W., Liu, D.T., Lam, D.S., 2008b. Safety enhanced photodynamic therapy for chronic central serous chorioretinopathy: one-year results of a prospective study. *Retina* 28, 85–93.
- Chan, W.M., Lai, T.Y., Liu, D.T., Lam, D.S., 2007. Intravitreal bevacizumab (avastin) for choroidal neovascularization secondary to central serous chorioretinopathy, secondary to punctate inner choroidopathy, or of idiopathic origin. *Am. J. Ophthalmol.* 143, 977–983.
- Chan, W.M., Lam, D.S., Lai, T.Y., Tam, B.S., Liu, D.T., Chan, C.K., 2003. Choroidal vascular remodelling in central serous chorioretinopathy after indocyanine green guided photodynamic therapy with verteporfin: a novel treatment at the primary disease level. *Br. J. Ophthalmol.* 87, 1453–1458.
- Chatziralli, I., Kabanarou, S.A., Parikakis, E., Chatzirallis, A., Xirou, T., Mitropoulos, P., 2017. Risk factors for central serous chorioretinopathy: multivariate approach in a case-control study. *Curr. Eye Res.* 42, 1069–1073.
- Chen, S.N., Hwang, J.F., Tseng, L.F., Lin, C.J., 2008. Subthreshold diode micropulse photocoagulation for the treatment of chronic central serous chorioretinopathy with juxtafoveal leakage. *Ophthalmology* 115, 2229–2234.
- Cheung, C.M.G., Lai, T.Y.Y., Ruamviboonsuk, P., Chen, S.J., Chen, Y., Freund, K.B., Gomi, F., Koh, A.H., Lee, W.K., Wong, T.Y., 2018a. Polypoidal choroidal vasculopathy: definition, pathogenesis, diagnosis, and management. *Ophthalmology* 125, 708–724.
- Cheung, C.M.G., Lee, W.K., Koizumi, H., Dansingani, K., Lai, T.Y.Y., Freund, K.B., 2018. Pachychoroid disease. *Eye* 33, 14–33.
- Chhablani, J., Kozak, I., Pichi, F., Chenworth, M., Berrocal, M.H., Bedi, R., Singh, R.P., Wu, L., Meyerle, C., Casella, A.M., Mansour, A., Bashshur, Z., Scorza, A., Carrai, P., Nucci, P., Arevalo, J.F., 2015. Outcomes of treatment of choroidal neovascularization associated with central serous chorioretinopathy with intravitreal antiangiogenic agents. *Retina* 35, 2489–2497.
- Chhablani, J., Pichi, F., Silva, R., Casella, A.M., Murthy, H., Banker, A., Nowlaty, S.R., Carrai, P., Nucci, P., Arevalo, J.F., 2016. Antiangiogenics in choroidal neovascularization associated with laser in central serous chorioretinopathy. *Retina* 36, 901–908.
- Chhablani, J., Rani, P.K., Mathai, A., Jalali, S., Kozak, I., 2014. Navigated focal laser photocoagulation for central serous chorioretinopathy. *Clin. Ophthalmol.* 8, 1543–1547.
- Chin, E.K., Almeida, D.R., Roybal, C.N., Niles, P.I., Gehrs, K.M., Sohn, E.H., Boldt, H.C., Russell, S.R., Folk, J.C., 2015. Oral mineralocorticoid antagonists for recalcitrant central serous chorioretinopathy. *Clin. Ophthalmol.* 9, 1449–1456.
- Chong, C.F., Yang, D., Pham, T.Q., Liu, H., 2012. A novel treatment of central serous chorioretinopathy with topical anti-inflammatory therapy. *BMJ Case Rep.* <https://doi.org/10.1136/bcr-2012-006970>, 2012.
- Chrapek, O., Jirkova, B., Kandrnl, V., Rehak, J., Sin, M., 2015. Treatment of central serous chorioretinopathy with beta-blocker metipranolol. *Biomed. Pap. Med. Fac. Palacky Univ. Olomouc Czech Repub.* 159, 120–123.
- Chung, C.Y., Chan, Y.Y., Li, K.K.W., 2018. Angiographic and tomographic prognostic factors of chronic central serous chorioretinopathy treated with half-dose photodynamic therapy. *Ophthalmologica* 240, 37–44.
- Chung, Y.R., Seo, E.J., Lew, H.M., Lee, K.H., 2013. Lack of positive effect of intravitreal bevacizumab in central serous chorioretinopathy: meta-analysis and review. *Eye* 27, 1339–1346.
- Clark, R.D., 2008. Glucocorticoid receptor antagonists. *Curr. Top. Med. Chem.* 8, 813–838.
- Cohen, S.Y., Quntel, G., Guiberteau, B., Delahaye-Mazza, C., Gaudric, A., 1998. Macular serous retinal detachment caused by subretinal leakage in tilted disc syndrome. *Ophthalmology* 105, 1831–1834.
- Coleman, D.J., Lizzi, F.L., Burgess, S.E., Silverman, R.H., Smith, M.E., Driller, J., Rosado, A., Ellsworth, R.M., Haik, B.G., Abramson, D.H., et al., 1986. Ultrasonic hyperthermia and radiation in the management of intraocular malignant melanoma. *Am. J. Ophthalmol.* 101, 635–642.
- Conrad, R., Geiser, F., Kleiman, A., Zur, B., Karpawitz-Godt, A., 2014. Temperament and character personality profile and illness-related stress in central serous chorioretinopathy. *Sci. World J.*, 631687 2014.
- Cook, C.S., Berry, L.M., Bible, R.H., Hribar, J.D., Hajdu, E., Liu, N.W., 2003. Pharmacokinetics and metabolism of [14c]eplerenone after oral administration to humans. *Drug Metab. Dispos.* 31, 1448–1455.
- Copete, S., Ruiz-Moreno, J.M., Cava, C., Montero, J.A., 2012. Retinal thickness changes following photodynamic therapy in chronic central serous chorioretinopathy. *Graefes Arch. Clin. Exp. Ophthalmol.* 250, 803–808.
- Coscas, G., Lupidi, M., Coscas, F., Benjelloun, F., Zerbib, J., Dirani, A., Semoun, O., Souied, E.H., 2015. Toward a specific classification of polypoidal choroidal vasculopathy: idiopathic disease or subtype of age-related macular degeneration. *Investig. Ophthalmol. Vis. Sci.* 56, 3187–3195.
- Cuevas, P., Outeirino, L.A., Azanza, C., Angulo, J., Gimenez-Gallego, G., 2012. Short-term efficacy of intravitreal dobesilate in central serous chorioretinopathy. *Eur. J. Med. Res.* 17, 22.
- Dadgostar, H., Ventura, A.A., Chung, J.Y., Sharma, S., Kaiser, P.K., 2009. Evaluation of injection frequency and visual acuity outcomes for ranibizumab monotherapy in exudative age-related macular degeneration. *Ophthalmology* 116, 1740–1747.
- Dang, Y., Mu, Y., Zhao, M., Li, L., Guo, Y., Zhu, Y., 2013. The effect of eradicating helicobacter pylori on idiopathic central serous chorioretinopathy patients. *Ther. Clin. Risk Manag.* 9, 355–360.
- Dang, Y., Sun, X., Xu, Y., Mu, Y., Zhao, M., Zhao, J., Zhu, Y., Zhang, C., 2014. Subfoveal choroidal thickness after photodynamic therapy in patients with acute idiopathic central serous chorioretinopathy. *Ther. Clin. Risk Manag.* 10, 37–43.
- Daniell, M.D., Hill, J.S., 1991. A history of photodynamic therapy. *Aust. N. Z. J. Surg.* 61, 340–348.
- Daruich, A., Matet, A., Dirani, A., Bousquet, E., Zhao, M., Farman, N., Jaisser, F., Behar-Cohen, F., 2015. Central serous chorioretinopathy: recent findings and new physiopathology hypothesis. *Prog. Retin. Eye Res.* 48, 82–118.
- Daruich, A., Matet, A., Dirani, A., Gallice, M., Nicholson, L., Sivaprasad, S., Behar-Cohen, F., 2016. Oral mineralocorticoid-receptor antagonists: real-life experience in clinical subtypes of nonresolving central serous chorioretinopathy with chronic epitheliopathy. *Transl. Vis. Sci. Technol.* 5, 2.
- Daruich, A., Matet, A., Marchionno, L., De Azevedo, J.D., Ambresin, A., Mantel, I., Behar-Cohen, F., 2017. Acute central serous chorioretinopathy: factors influencing episode duration. *Retina* 37, 1905–1915.
- de Carlo, T.E., Bonini Filho, M.A., Chin, A.T., Adhi, M., Ferrara, D., Bauman, C.R., Witkin, A.J., Reichel, E., Duker, J.S., Waheed, N.K., 2015. Spectral-domain optical coherence tomography angiography of choroidal neovascularization. *Ophthalmology* 122, 1228–1238.
- De Fauw, J., Ledsam, J.R., Romera-Paredes, B., Nikolov, S., Tomasev, N., Blackwell, S., Askham, H., Glorot, X., O'Donoghue, B., Visentin, D., van den Driessche, G., Lakshminarayanan, B., Meyer, C., Mackinder, F., Bouton, S., Ayoub, K., Chopra, R., King, D., Karthikesalingam, A., Hughes, C.O., Raine, R., Hughes, J., Sim, D.A., Egan, C., Tufail, A., Montgomery, H., Hassabis, D., Rees, G., Back, T., Khaw, P.T., Suleyman, M., Cornibise, J., Keane, P.A., Ronneberger, O., 2018. Clinically applicable deep learning for diagnosis and referral in retinal disease. *Nat. Med.* 24, 1342–1350.
- de Jong, E.K., Breukink, M.B., Schellevis, R.L., Bakker, B., Mohr, J.K., Fauser, S., Keunen, J.E., Hoyng, C.B., den Hollander, A.L., Boon, C.J., 2015. Chronic central serous chorioretinopathy is associated with genetic variants implicated in age-related macular degeneration. *Ophthalmology* 122, 562–570.
- Delyani, J.A., 2000. Mineralocorticoid receptor antagonists: the evolution of utility and pharmacology. *Kidney Int.* 57, 1408–1411.
- Desai, U.R., Alhalel, A.A., Campen, T.J., Schiffman, R.M., Edwards, P.A., Jacobsen, G.R.,

2003. Central serous chorioretinopathy in african americans. *J. Natl. Med. Assoc.* 95, 553–559.
- Desmettre, T., Maurage, C.A., Mordon, S., 2001. Heat shock protein hyperexpression on chorioretinal layers after transpupillary thermotherapy. *Investig. Ophthalmol. Vis. Sci.* 42, 2976–2980.
- Dhirani, N.A., Yang, Y., Somani, S., 2017. Long-term outcomes in half-dose verteporfin photodynamic therapy for chronic central serous retinopathy. *Clin. Ophthalmol.* 11, 2145–2149.
- Duke-Elder, S., 1940. *Text-book of Ophthalmology*, vol. 3. pp. 2592.
- Eandi, C.M., Ober, M., Iranmanesh, R., Peiretti, E., Yannuzzi, L.A., 2005. Acute central serous chorioretinopathy and fundus autofluorescence. *Retina* 25, 989–993.
- Earl, J.B., Lee, C.S., Yom, V., Van Stavern, G.P., Abuattieh, M., Chin-Yee, D., Rao, P.K., Apte, R.S., 2014. Visual cycle suppression via patching in central serous chorioretinopathy. *Ophthalmology* 121, 2502–2504 e2501.
- Entezari, M., Ramezani, A., Yaseri, M., 2012. Intravitreal bevacizumab for treatment of refractory central serous chorioretinopathy. *Korean J. Ophthalmol.* 26, 139–142.
- Eom, Y., Oh, J., Kim, S.W., Huh, K., 2012. Systemic factors associated with central serous chorioretinopathy in koreans. *Korean J. Ophthalmol.* 26, 260–264.
- Ersoz, M.G., Arf, S., Hocaoglu, M., Sayman Muslubas, I., Karacorlu, M., 2018. Patient characteristics and risk factors for central serous chorioretinopathy: an analysis of 811 patients. *Br. J. Ophthalmol.* 103, 725–729.
- Falavarjani, K.G., Amirsardari, A., Habibi, A., Eshaghi, A., Bakhti, S., Aghdam, K.A., 2017. Visual and anatomical outcomes of spironolactone therapy in patients with chronic central serous chorioretinopathy. *J. Ophthalmic Vis. Res.* 12, 281–289.
- Ferrara, D., Mohler, K.J., Waheed, N., Adhi, M., Liu, J.J., Grulkowski, I., Kraus, M.F., Bauml, C., Hornegger, J., Fujimoto, J.G., Duker, J.S., 2014. En face enhanced-depth swept-source optical coherence tomography features of chronic central serous chorioretinopathy. *Ophthalmology* 121, 719–726.
- Ficker, L., Vafidis, G., While, A., Leaver, P., 1988. Long-term follow-up of a prospective trial of argon laser photocoagulation in the treatment of central serous retinopathy. *Br. J. Ophthalmol.* 72, 829–834.
- Fine, S.L., Owens, S.L., 1980. Central serous retinopathy in a 7-year-old girl. *Am. J. Ophthalmol.* 90, 871–873.
- Fok, A.C., Chan, P.P., Lam, D.S., Lai, T.Y., 2011. Risk factors for recurrence of serous macular detachment in untreated patients with central serous chorioretinopathy. *Ophthalmic Res.* 46, 160–163.
- Foroghian, F., Meleth, A.D., Cukras, C., Chew, E.Y., Wong, W.T., Meyerle, C.B., 2011. Finasteride for chronic central serous chorioretinopathy. *Retina* 31, 766–771.
- Francis, J.H., Habib, L.A., Abramson, D.H., Yannuzzi, L.A., Heinemann, M., Gounder, M.M., Grisham, R.N., Postow, M.A., Shoushtari, A.N., Chi, P., Segal, N.H., Yaeger, R., Ho, A.L., Chapman, P.B., Catalanotti, F., 2017. Clinical and morphologic characteristics of mek inhibitor-associated retinopathy: differences from central serous chorioretinopathy. *Ophthalmology* 124, 1788–1798.
- Freund, K.B., Mrejen, S., Jung, J., Yannuzzi, L.A., Boon, C.J., 2013. Increased fundus autofluorescence related to outer retinal disruption. *JAMA Ophthalmol* 131, 1645–1649.
- Friberg, T.R., Campagna, J., 1989. Central serous chorioretinopathy: an analysis of the clinical morphology using image-processing techniques. *Graefes Arch. Clin. Exp. Ophthalmol.* 27, 201–205.
- Friberg, T.R., Karatza, E.C., 1997. The treatment of macular disease using a micropulsed and continuous wave 810-nm diode laser. *Ophthalmology* 104, 2030–2038.
- Fujita, K., Imamura, Y., Shinoda, K., Matsumoto, C.S., Mizutani, Y., Hashizume, K., Mizota, A., Yuzawa, M., 2015. One-year outcomes with half-dose verteporfin photodynamic therapy for chronic central serous chorioretinopathy. *Ophthalmology* 122, 555–561.
- Fujita, K., Shinoda, K., Imamura, Y., Matsumoto, C.S., Mizutani, Y., Mizota, A., Yuzawa, M., 2012a. Correlation of integrity of cone outer segment tips line with retinal sensitivity after half-dose photodynamic therapy for chronic central serous chorioretinopathy. *Am. J. Ophthalmol.* 154, 579–585.
- Fujita, K., Shinoda, K., Matsumoto, C.S., Imamura, Y., Tanaka, E., Mizutani, Y., Mizota, A., Yuzawa, M., 2012b. Microperimetric evaluation of chronic central serous chorioretinopathy after half-dose photodynamic therapy. *Clin. Ophthalmol.* 6, 1681–1687.
- Fung, A.T., Yannuzzi, L.A., Freund, K.B., 2012. Type 1 (sub-retinal pigment epithelial) neovascularization in central serous chorioretinopathy masquerading as neovascular age-related macular degeneration. *Retina* 32, 1829–1837.
- Gackle, H.C., Lang, G.E., Freissler, K.A., Lang, G.K., 1998. [central serous chorioretinopathy. Clinical, fluorescein angiography and demographic aspects]. *Der Ophthalmologe* 95, 529–533.
- Gal-Or, O., Dansingani, K.K., Sebrow, D., Dolz-Marco, R., Freund, K.B., 2018. Inner choroidal flow signal attenuation in pachychoroid disease: optical coherence tomography angiography. *Retina* 38, 1984–1992.
- Garg, S.P., Dada, T., Talwar, D., Biswas, N.R., 1997. Endogenous cortisol profile in patients with central serous chorioretinopathy. *Br. J. Ophthalmol.* 81, 962–964.
- Gartner, J., 1987. Long-term follow-up of an ophthalmologist's central serous retinopathy, photocoagulated by sungazing. *Doc. Ophthalmol.* 66, 19–33.
- Gass, J.D., 1967. Pathogenesis of disciform detachment of the neuroepithelium: II. Idiopathic central serous chorioidopathy. *Am. J. Ophthalmol.* 63 587/515-615/543.
- Gawecki, M., 2015. Increase in central retinal edema after subthreshold diode micropulse laser treatment of chronic central serous chorioretinopathy. *Case Rep. Ophthalmol. Med.* 813414 2015.
- Gawecki, M., Jaszczuk-Maciejewska, A., Jurska-Jasko, A., Grzybowski, A., 2017. Functional and morphological outcome in patients with chronic central serous chorioretinopathy treated by subthreshold micropulse laser. *Graefes Arch. Clin. Exp. Ophthalmol.* 255, 2299–2306.
- Gelber, G.S., Schatz, H., 1987. Loss of vision due to central serous chorioretinopathy following psychological stress. *Am. J. Psychiatry* 144, 46–50.
- Gemenetz, M., De Salvo, G., Lotery, A.J., 2010. Central serous chorioretinopathy: an update on pathogenesis and treatment. *Eye* 24, 1743–1756.
- Gerendas, B.S., Kroisamer, J.S., Buehl, W., Rezar-Dreindl, S.M., Eibenberger, K.M., Pablik, E., Schmid-Erfurth, U., Sacu, S., 2018. Correlation between morphological characteristics in spectral-domain-optical coherence tomography, different functional tests and a patient's subjective handicap in acute central serous chorioretinopathy. *Acta Ophthalmol.* 96, e776–e782.
- Gergely, R., Kovacs, I., Schneider, M., Resch, M., Papp, A., Recsan, Z., Nagy, Z.Z., Ecsedy, M., 2017. Mineralocorticoid receptor antagonist treatment in bilateral chronic central serous chorioretinopathy: a comparative study of exudative and nonexudative fellow eyes. *Retina* 37, 1084–1091.
- Ghadiali, Q., Jung, J.J., Yu, S., Patel, S.N., Yannuzzi, L.A., 2016. Central serous chorioretinopathy treated with mineralocorticoid antagonists: a one-year pilot study. *Retina* 36, 611–618.
- Gilbert, C.M., Owens, S.L., Smith, P.D., Fine, S.L., 1984. Long-term follow-up of central serous chorioretinopathy. *Br. J. Ophthalmol.* 68, 815–820.
- Giudice, G.L., de Belvis, V., Tavolato, M., Galan, A., 2011. Large-spot subthreshold transpupillary thermotherapy for chronic serous macular detachment. *Clin. Ophthalmol.* 5, 355–360.
- Goktas, A., 2014. Correlation of subretinal fluid volume with choroidal thickness and macular volume in acute central serous chorioretinopathy. *Eye* 28, 1431–1436.
- Golshahi, A., Klingmuller, D., Holz, F.G., Eter, N., 2010. Ketoconazole in the treatment of central serous chorioretinopathy: a pilot study. *Acta Ophthalmol.* 88, 576–581.
- Gragoudas, E.S., Adamis, A.P., Cunningham Jr., E.T., Feinsod, M., Guyer, D.R., 2004. Pegaptanib for neovascular age-related macular degeneration. *N. Engl. J. Med.* 351, 2805–2816.
- Gramajo, A.L., Marquez, G.E., Torres, V.E., Juarez, C.P., Rosenstein, R.E., Luna, J.D., 2015. Therapeutic benefit of melatonin in refractory central serous chorioretinopathy. *Eye* 29, 1036–1045.
- Grover, S., Fishman, G.A., Fiscella, R.G., Adelman, A.E., 1997. Efficacy of dorzolamide hydrochloride in the management of chronic cystoid macular edema in patients with retinitis pigmentosa. *Retina* 17, 222–231.
- Guengerich, F.P., 1999. Cytochrome p-450 3a4: regulation and role in drug metabolism. *Annu. Rev. Pharmacol. Toxicol.* 39, 1–17.
- Gupta, B., Elagouz, M., McHugh, D., Chong, V., Sivaprasad, S., 2009. Micropulse Diode Laser Photocoagulation for Central Serous Chorio-Retinopathy.
- Gupta, P., Gupta, V., Dogra, M.R., Singh, R., Gupta, A., 2010. Morphological changes in the retinal pigment epithelium on spectral-domain oct in the unaffected eyes with idiopathic central serous chorioretinopathy. *Int. Ophthalmol.* 30, 175–181.
- Gutierrez-Hernandez, J.C., Martinez-Camarillo, J.C., Sada, S.R., 2015. Long-term follow-up of photoreceptor loss and recovery after half-fluence photodynamic therapy for chronic central serous chorioretinopathy. *Retin. Cases Brief Rep.* 9, 109–113.
- Guyer, D.R., Yannuzzi, L.A., Slakter, J.S., Sorenson, J.A., Ho, A., Orlock, D., 1994. Digital indocyanine green videoangiography of central serous chorioretinopathy. *Arch. Ophthalmol.* 112, 1057–1062.
- Haga, F., Maruko, R., Sato, C., Kataoka, K., Ito, Y., Terasaki, H., 2017. Long-term prognostic factors of chronic central serous chorioretinopathy after half-dose photodynamic therapy: a 3-year follow-up study. *PLoS One* 12, e0181479.
- Hagen, S., Ansari-Shahrezaei, S., Smetschnig, E., Glittenberg, C., Krebs, I., Graf, A., Binder, S., 2013. The effect of photodynamic therapy on macular sensitivity in eyes with acute central serous chorioretinopathy. *Graefes Arch. Clin. Exp. Ophthalmol.* 251, 1081–1089.
- Haimovici, R., Gragoudas, E.S., Duker, J.S., Sjaarda, R.N., Elliott, D., 1997. Central serous chorioretinopathy associated with inhaled or intranasal corticosteroids. *Ophthalmology* 104, 1653–1660.
- Haimovici, R., Koh, S., Gagnon, D.R., Lehrfeld, T., Wellik, S., 2004. Risk factors for central serous chorioretinopathy: a case-control study. *Ophthalmology* 111, 244–249.
- Haimovici, R., Rumelt, S., Melby, J., 2003. Endocrine abnormalities in patients with central serous chorioretinopathy. *Ophthalmology* 110, 698–703.
- Han, J.M., Hwang, J.M., Kim, J.S., Park, K.H., Woo, S.J., 2014. Changes in choroidal thickness after systemic administration of high-dose corticosteroids: a pilot study. *Investig. Ophthalmol. Vis. Sci.* 55, 440–445.
- Hata, M., Oishi, A., Shimozone, M., Mandai, M., Nishida, A., Kurimoto, Y., 2013. Early changes in foveal thickness in eyes with central serous chorioretinopathy. *Retina* 33, 296–301.
- Hayashi, K., Hasegawa, Y., Tokoro, T., 1986. Indocyanine green angiography of central serous chorioretinopathy. *Int. Ophthalmol.* 9, 37–41.
- Herold, T.R., Prause, K., Wolf, A., Mayer, W.J., Ulbig, M.W., 2014. Spironolactone in the treatment of central serous chorioretinopathy - a case series. *Graefes Arch. Clin. Exp. Ophthalmol.* 252, 1985–1991.
- Herold, T.R., Rist, K., Priglinger, S.G., Ulbig, M.W., Wolf, A., 2017. Long-term results and recurrence rates after spironolactone treatment in non-resolving central serous chorio-retinopathy (cscr). *Graefes Arch. Clin. Exp. Ophthalmol.* 255, 221–229.
- Higgins, T.P., Khoo, C.T., Magrath, G., Shields, C.L., 2016. Flat choroidal melanoma masquerading as central serous chorioretinopathy. *Oman J. Ophthalmol.* 9, 174–176.
- Horniker, E., 1927. Su di una forma retinite centrale di origine vasoneurotica (retinite centrale capillaro-spastica). *Ann. Ottal. Vis.* 55, 578–600.
- Horniker, E., 1937. *Klin. Monatsblätter Augenheilkd.* 98, 487.
- Hosoda, Y., Yoshikawa, M., Miyake, M., Tabara, Y., Ahn, J., Woo, S.J., Honda, S., Sakurada, Y., Shiragami, C., Nakanishi, H., Oishi, A., Ooto, S., Miki, A., Iida, T., Iijima, H., Nakamura, M., Khor, C.C., Wong, T.Y., Song, K., Park, K.H., Yamada, R., Matsuda, F., Tsujikawa, A., Yamashiro, K., 2018. Cfh and vipr2 as susceptibility loci in choroidal thickness and pachychoroid disease central serous chorioretinopathy. *Proc. Natl. Acad. Sci. U. S. A.* 115, 6261–6266.
- Huang, W.C., Chen, W.L., Tsai, Y.Y., Chiang, C.C., Lin, J.M., 2009. Intravitreal

- bevacizumab for treatment of chronic central serous chorioretinopathy. *Eye* 23, 488–489.
- Hussain, N., Khanna, R., Hussain, A., Das, T., 2006. Transpupillary thermotherapy for chronic central serous chorioretinopathy. *Graefes Arch. Clin. Exp. Ophthalmol.* 244, 1045–1051.
- Iacono, P., Tedeschi, M., Boccassini, B., Chiaravallotti, A., Varano, M., Parravano, M., 2018. Chronic central serous chorioretinopathy: early and late morphological and functional changes after verteporfin photodynamic therapy. *Retina* 39, 980–987.
- Iida, T., Yannuzzi, L.A., Spaide, R.F., Borodoker, N., Carvalho, C.A., Negrao, S., 2003. Cystoid macular degeneration in chronic central serous chorioretinopathy. *Retina* 23, 1–7 quiz 137–138.
- Iijima, H., Iida, T., Murayama, K., Imai, M., Gohdo, T., 1999. Plasminogen activator inhibitor 1 in central serous chorioretinopathy. *Am. J. Ophthalmol.* 127, 477–478.
- Ikuno, Y., Kawaguchi, K., Nouchi, T., Yasuno, Y., 2010. Choroidal thickness in healthy Japanese subjects. *Investig. Ophthalmol. Vis. Sci.* 51, 2173–2176.
- Imamura, Y., Fujiwara, T., Margolis, R., Spaide, R.F., 2009. Enhanced depth imaging optical coherence tomography of the choroid in central serous chorioretinopathy. *Retina* 29, 1469–1473.
- Imamura, Y., Fujiwara, T., Spaide, R.F., 2011. Fundus autofluorescence and visual acuity in central serous chorioretinopathy. *Ophthalmology* 118, 700–705.
- Inoue, M., Kadonosono, K., Watanabe, Y., Kobayashi, S., Yamane, S., Arakawa, A., 2011. Results of one-year follow-up examinations after intravitreal bevacizumab administration for chronic central serous chorioretinopathy. *Ophthalmologica* 225, 37–40.
- Inoue, R., Sawa, M., Tsujikawa, M., Gomi, F., 2010. Association between the efficacy of photodynamic therapy and indocyanine green angiography findings for central serous chorioretinopathy. *Am. J. Ophthalmol.* 149, 441–446 e441–442.
- Izumi, T., Koizumi, H., Maruko, I., Takahashi, Y., Sonoda, S., Sakamoto, T., Iida, T., 2017. Structural analyses of choroid after half-dose verteporfin photodynamic therapy for central serous chorioretinopathy. *Br. J. Ophthalmol.* 101, 433–437.
- Jain, N., Johnson, M.W., 2014. Pathogenesis and treatment of maculopathy associated with cavitory optic disc anomalies. *Am. J. Ophthalmol.* 158, 423–435.
- Jalkh, A.E., Jabbour, N., Avila, M.P., Trempe, C.L., Schepens, C.L., 1984. Retinal pigment epithelium decompensation. I. Clinical features and natural course. *Ophthalmology* 91, 1544–1548.
- Jampol, L.M., Weinreb, R., Yannuzzi, L., 2002. Involvement of corticosteroids and catecholamines in the pathogenesis of central serous chorioretinopathy: a rationale for new treatment strategies. *Ophthalmology* 109, 1765–1766.
- Jang, L., Gianniou, C., Ambresin, A., Mantel, I., 2015. Refractory subretinal fluid in patients with neovascular age-related macular degeneration treated with intravitreal ranibizumab: visual acuity outcome. *Graefes Arch. Clin. Exp. Ophthalmol.* 253, 1211–1216.
- Ji, S., Wei, Y., Chen, J., Tang, S., 2017. Clinical efficacy of anti-vegf medications for central serous chorioretinopathy: a meta-analysis. *Int. J. Clin. Pharm.* 39, 514–521.
- Ji, Y., Li, M., Zhang, X., Peng, Y., Wen, F., 2018. Poor sleep quality is the risk factor for central serous chorioretinopathy. *J. Ophthalmol.* 9450297 2018.
- Journee-de Korver, J.G., Oosterhuis, J.A., Kakebeke-Kemme, H.M., de Wolff-Rouendaal, D., 1992. Transpupillary thermotherapy (ttt) by infrared irradiation of choroidal melanoma. *Doc. Ophthalmol.* 82, 185–191.
- Kang, S., Park, Y.G., Kim, J.R., Seifert, E., Theisen-Kunde, D., Brinkmann, R., Roh, Y.J., 2016. Selective retina therapy in patients with chronic central serous chorioretinopathy: a pilot study. *Medicine (Baltimore)* 95, e2524.
- Kapetanios, A.D., Donati, G., Bouzas, E., Mastorakos, G., Pourmaras, C.J., 1998. [serous central chorioretinopathy and endogenous hypercortisolemia]. *Klin. Monatsblätter Augenheilkd.* 212, 343–344.
- Kapoor, K.G., Wagner, A.L., 2016. Mineralocorticoid antagonists in the treatment of central serous chorioretinopathy: a comparative analysis. *Ophthalmic Res.* 56, 17–22.
- Karakus, S.H., Basarir, B., Pinarci, E.Y., Kirandi, E.U., Demirok, A., 2013. Long-term results of half-dose photodynamic therapy for chronic central serous chorioretinopathy with contrast sensitivity changes. *Eye* 27, 612–620.
- Kawamura, R., Ideta, H., Hori, H., Yuki, K., Uno, T., Tanabe, T., Tsubota, K., Kawasaki, T., 2012. Transpupillary thermotherapy for atypical central serous chorioretinopathy. *Clin. Ophthalmol.* 6, 175–179.
- Khan, M.S., Sameen, M., Lodhi, A.A., Ahmed, M., Ahmed, N., Kamal, M., Junejo, S.A., 2016. Effect of half adult dose of oral rifampicin (300mg) in patients with idiopathic central serous chorioretinopathy. *Pak. J. Med. Sci.* 32, 1158–1163.
- Kim, D.Y., Joe, S.G., Yang, S.J., Lee, J.Y., Kim, J.G., Yoon, Y.H., 2015a. The association between choroidal thickness variations and response to intravitreal bevacizumab in central serous chorioretinopathy. *Korean J. Ophthalmol.* 29, 160–167.
- Kim, D.Y., Lee, J.Y., Lee, E.K., Kim, J.Y., 2019. Comparison of visual/anatomical outcomes and recurrence rate between oral spironolactone and photodynamic therapy for nonresolving central serous chorioretinopathy. *Retina*. <https://doi.org/10.1097/IAE.0000000000002507>.
- Kim, G.A., Rim, T.H., Lee, S.C., Byeon, S.H., Koh, H.J., Kim, S.S., Lee, C.S., 2015b. Clinical characteristics of responders to intravitreal bevacizumab in central serous chorioretinopathy patients. *Eye* 29, 732–740 quiz 741.
- Kim, J.W., Park, M.H., Kim, Y.J., Kim, Y.T., 2016. Comparison of subfoveal choroidal thickness in healthy pregnancy and pre-eclampsia. *Eye* 30, 349–354.
- Kim, J.Y., Chae, J.B., Kim, J., Kim, D.Y., 2018a. Mineralocorticoid receptor antagonist treatment for steroid-induced central serous chorioretinopathy patients with continuous systemic steroid treatment. *J. Ophthalmol.* 4258763 2018.
- Kim, J.Y., Park, H.S., Kim, S.Y., 2015c. Short-term efficacy of subthreshold micropulse yellow laser (577-nm) photocoagulation for chronic central serous chorioretinopathy. *Graefes Arch. Clin. Exp. Ophthalmol.* 253, 2129–2135.
- Kim, K.S., Lee, W.K., Lee, S.B., 2014. Half-dose photodynamic therapy targeting the leakage point on the fluorescein angiography in acute central serous chorioretinopathy: a pilot study. *Am. J. Ophthalmol.* 157, 366–373 e361.
- Kim, M., Lee, S.C., Lee, S.J., 2013. Intravitreal ranibizumab for acute central serous chorioretinopathy. *Ophthalmologica* 229, 152–157.
- Kim, Y.K., Ryoo, N.K., Woo, S.J., Park, K.H., 2015d. Choroidal thickness changes after photodynamic therapy and recurrence of chronic central serous chorioretinopathy. *Am. J. Ophthalmol.* 160, 72–84 e71.
- Kim, Y.K., Ryoo, N.K., Woo, S.J., Park, K.H., 2015e. Comparison of visual and anatomical outcomes of half-fluence and half-dose photodynamic therapy in eyes with chronic central serous chorioretinopathy. *Graefes Arch. Clin. Exp. Ophthalmol.* 253, 2063–2073.
- Kim, Y.K., Woo, S.J., Park, K.H., Chi, Y.K., Han, J.W., Kim, K.W., 2018b. Association of central serous chorioretinopathy with psychosocial factors is dependent on its phase and subtype. *Korean J. Ophthalmol.* 32, 281–289.
- Kitahara, S., 1936. Ueber klinische beobachtungen bei der in Japan häufig vorkommenden chorioretinitis centralis serosa. *Klin. Monatsbl. Augenheilkd.* 97, 345–362.
- Kitzmann, A.S., Pulido, J.S., Diehl, N.N., Hodge, D.O., Burke, J.P., 2008. The incidence of central serous chorioretinopathy in olmsted county, Minnesota, 1980–2002. *Ophthalmology* 115, 169–173.
- Klein, M.L., Van Buskirk, E.M., Friedman, E., Gragoudas, E., Chandra, S., 1974. Experience with nontreatment of central serous chorioidopathy. *Arch. Ophthalmol.* 91, 247–250.
- Koh, A., Lai, T.Y.Y., Takahashi, K., Wong, T.Y., Chen, L.J., Ruamviboonsuk, P., Tan, C.S., Feller, C., Margaron, P., Lim, T.H., Lee, W.K., 2017. Efficacy and safety of ranibizumab with or without verteporfin photodynamic therapy for polypoidal choroidal vasculopathy: a randomized clinical trial. *JAMA Ophthalmol* 135, 1206–1213.
- Koizumi, H., Kano, M., Yamamoto, A., Saito, M., Maruko, I., Sekiryu, T., Okada, A.A., Iida, T., 2016. Subfoveal choroidal thickness during aflibercept therapy for neovascular age-related macular degeneration: twelve-month results. *Ophthalmology* 123, 617–624.
- Koss, M.J., Beger, I., Koch, F.H., 2012. Subthreshold diode laser micropulse photocoagulation versus intravitreal injections of bevacizumab in the treatment of central serous chorioretinopathy. *Eye* 26, 307–314.
- Kozak, I., Oster, S.F., Cortes, M.A., Dowell, D., Hartmann, K., Kim, J.S., Freeman, W.R., 2011. Clinical evaluation and treatment accuracy in diabetic macular edema using navigated laser photocoagulator navilas. *Ophthalmology* 118, 1119–1124.
- Kramer, M., Miller, J.W., Michaud, N., Moulton, R.S., Hasan, T., Flotte, T.J., Gragoudas, E.S., 1996. Liposomal benzoporphyrin derivative verteporfin photodynamic therapy. Selective treatment of choroidal neovascularization in monkeys. *Ophthalmology* 103, 427–438.
- Kretz, F.T., Beger, I., Koch, F., Nowomiejska, K., Auffarth, G.U., Koss, M.J., 2015. Randomized clinical trial to compare micropulse photocoagulation versus half-dose verteporfin photodynamic therapy in the treatment of central serous chorioretinopathy. *Ophthalmic Surg. Lasers Imaging Retina* 46, 837–843.
- Kurup, S.K., Oliver, A., Emanuelli, A., Hau, V., Callanan, D., 2012. Low-dose methotrexate for the treatment of chronic central serous chorioretinopathy: a retrospective analysis. *Retina* 32, 2096–2101.
- Laatikainen, L., 1994. Diffuse chronic retinal pigment epitheliopathy and exudative retinal detachment. *Acta Ophthalmol.* 72, 533–536.
- Legendijk, J.J., 1982. A microwave heating technique for the hyperthermic treatment of tumours in the eye, especially retinoblastoma. *Phys. Med. Biol.* 27, 1313–1324.
- Lahousen, T., Painold, A., Luxenberger, W., Schienle, A., Kapfhammer, H.P., Ille, R., 2016. Psychological factors associated with acute and chronic central serous chorioretinopathy. *Nord. J. Psychiatry* 70, 24–30.
- Lai, F.H., Ng, D.S., Bakthavatsalam, M., Chan, V.C., Young, A.L., Luk, F.O., Tsang, C.W., Brelen, M.E., 2016. A multicenter study on the long-term outcomes of half-dose photodynamic therapy in chronic central serous chorioretinopathy. *Am. J. Ophthalmol.* 170, 91–99.
- Lai, T.Y., Chan, W.M., Li, H., Lai, R.Y., Liu, D.T., Lam, D.S., 2006. Safety enhanced photodynamic therapy with half dose verteporfin for chronic central serous chorioretinopathy: a short term pilot study. *Br. J. Ophthalmol.* 90, 869–874.
- Lai, T.Y., Wong, R.L., Chan, W.M., 2015. Long-term outcome of half-dose verteporfin photodynamic therapy for the treatment of central serous chorioretinopathy (an american ophthalmological society thesis). *Trans. Am. Ophthalmol. Soc.* 113, T8.
- Lai, T.Y., Staurengi, G., Lanzetta, P., Holz, F.G., Melissa Liew, S.H., Desset-Brethes, S., Staines, H., Hykin, P.G., 2018. Efficacy and safety of ranibizumab for the treatment of choroidal neovascularization due to uncommon cause: twelve-month results of the minerva study. *Retina* 38, 1464–1477.
- Lanzetta, P., Furlan, F., Morgante, L., Veritti, D., Bandello, F., 2008. Nonvisible subthreshold micropulse diode laser (810 nm) treatment of central serous chorioretinopathy. A pilot study. *Eur. J. Ophthalmol.* 18, 934–940.
- Lavinsky, D., Palanker, D., 2015. Nondamaging photothermal therapy for the retina: initial clinical experience with chronic central serous retinopathy. *Retina* 35, 213–222.
- Leaver, P., Williams, C., 1979. Argon laser photocoagulation in the treatment of central serous retinopathy. *Br. J. Ophthalmol.* 63, 674–677.
- Lee, J.H., Lee, S.C., Kim, H., Lee, C.S., 2019. Comparison of short-term efficacy between oral spironolactone treatment and photodynamic therapy for the treatment of non-resolving central serous chorioretinopathy. *Retina* 39, 127–133.
- Lee, J.Y., Chae, J.B., Yang, S.J., Kim, J.G., Yoon, Y.H., 2011. Intravitreal bevacizumab versus the conventional protocol of photodynamic therapy for treatment of chronic central serous chorioretinopathy. *Acta Ophthalmol.* 89, e293–294.
- Lee, P.Y., Kim, K.S., Lee, W.K., 2009. Severe choroidal ischemia following photodynamic therapy for pigment epithelial detachment and chronic central serous chorioretinopathy. *Jpn. J. Ophthalmol.* 53, 52–56.
- Lee, W.J., Lee, J.H., Lee, B.R., 2016. Fundus autofluorescence imaging patterns in central serous chorioretinopathy according to chronicity. *Eye* 30, 1336–1342.
- Lee, W.K., Iida, T., Ogura, Y., Chen, S.J., Wong, T.Y., Mitchell, P., Cheung, G.C.M., Zhang, Z., Leal, S., Ishibashi, T., 2018. Efficacy and safety of intravitreal aflibercept for

- polypoidal choroidal vasculopathy in the planet study: a randomized clinical trial. *JAMA Ophthalmol* 136, 786–793.
- Lehmann, M., Bousquet, E., Beydoun, T., Behar-Cohen, F., 2015. Pachychoroid: an inherited condition? *Retina* 35, 10–16.
- Levine, R., Brucker, A.J., Robinson, F., 1989. Long-term follow-up of idiopathic central serous chorioretinopathy by fluorescein angiography. *Ophthalmology* 96, 854–859.
- Liggett, P.E., Pince, K.J., Astrahan, M., Rao, N., Petrovich, Z., 1990. Localized current field hyperthermia: effect on normal ocular tissue. *Int. J. Hyperth.* 6, 517–527.
- Lim, J.I., Glassman, A.R., Aiello, L.P., Chakravarthy, U., Flaxel, C.J., Spaide, R.F., 2014. Collaborative retrospective macula society study of photodynamic therapy for chronic central serous chorioretinopathy. *Ophthalmology* 121, 1073–1078.
- Lim, J.W., Kim, M.U., 2011. The efficacy of intravitreal bevacizumab for idiopathic central serous chorioretinopathy. *Graefes Arch. Clin. Exp. Ophthalmol.* 249, 969–974.
- Lim, S.J., Roh, M.I., Kwon, O.W., 2010. Intravitreal bevacizumab injection for central serous chorioretinopathy. *Retina* 30, 100–106.
- Lin, E., Arrigg, P.G., Kim, R.Y., 2000. Familial central serous choroidopathy. *Graefes Arch. Clin. Exp. Ophthalmol.* 238, 930–931.
- Liu, C.F., Chen, L.J., Tsai, S.H., Lai, C.C., Chan, W.C., Wu, W.C., Wang, N.K., Chen, K.J., Hwang, Y.S., Chen, Y.P., Yeung, L., 2014. Half-dose verteporfin combined with half-fluence photodynamic therapy for chronic central serous chorioretinopathy. *J. Ocul. Pharmacol. Ther.* 30, 400–405.
- Liu, H.Y., Yang, C.H., Yang, C.M., Ho, T.C., Lin, C.P., Hsieh, Y.T., 2016. Half-dose versus half-time photodynamic therapy for central serous chorioretinopathy. *Am. J. Ophthalmol.* 167, 57–64.
- Loo, R.H., Scott, I.U., Flynn Jr., H.W., Gass, J.D., Murray, T.G., Lewis, M.L., Rosenfeld, P.J., Smiddy, W.E., 2002. Factors associated with reduced visual acuity during long-term follow-up of patients with idiopathic central serous chorioretinopathy. *Retina* 22, 19–24.
- Lu, H.Q., Wang, E.Q., Zhang, T., Chen, Y.X., 2016. Photodynamic therapy and anti-vascular endothelial growth factor for acute central serous chorioretinopathy: a systematic review and meta-analysis. *Eye* 30, 15–22.
- Lu, J.G., Friberg, T.R., 1987. Idiopathic central serous retinopathy in China: a report of 600 cases (624 eyes) treated by acupuncture. *Ophthalmic Surg.* 18, 608–611.
- Luttrull, J.K., 2016. Low-intensity/high-density subthreshold diode micropulse laser for central serous chorioretinopathy. *Retina* 36, 1658–1663.
- Malik, K.J., Sampat, K.M., Mansouri, A., Steiner, J.N., Glaser, B.M., 2015. Low-intensity/high-density subthreshold micropulse diode laser for chronic central serous chorioretinopathy. *Retina* 35, 532–536.
- Malik, R., Shah, A., Greaney, M.J., Dick, A.D., 2005. Bilateral serous macular detachment as a presenting feature of acute lymphoblastic leukemia. *Eur. J. Ophthalmol.* 15, 284–286.
- Manayath, G.J., Arora, S., Parikh, H., Shah, P.K., Tiwari, S., Narendran, V., 2016. Is myopia a protective factor against central serous chorioretinopathy? *Int. J. Ophthalmol.* 9, 266–270.
- Manayath, G.J., Karandikar, S.S., Narendran, S., Kumarswamy, K.A., Saravanan, V.R., Morris, R.J., Venkatapathy, N., 2017. Low fluence photodynamic therapy versus graded subthreshold transpupillary thermotherapy for chronic central serous chorioretinopathy: results from a prospective study. *Ophthalmic Surg. Lasers Imaging Retina* 48, 334–338.
- Manayath, G.J., Narendran, V., Arora, S., Morris, R.J., Saravanan, V.R., Shah, P.K., 2012. Graded subthreshold transpupillary thermotherapy for chronic central serous chorioretinopathy. *Ophthalmic Surg. Lasers Imaging* 43, 284–290.
- Marmor, M.F., 1988. New hypotheses on the pathogenesis and treatment of serous retinal detachment. *Graefes Arch. Clin. Exp. Ophthalmol.* 226, 548–552.
- Maruko, I., Iida, T., Sugano, Y., Furuta, M., Sekiryu, T., 2011. One-year choroidal thickness results after photodynamic therapy for central serous chorioretinopathy. *Retina* 31, 1921–1927.
- Maruko, I., Iida, T., Sugano, Y., Ojima, A., Ogasawara, M., Spaide, R.F., 2010. Subfoveal choroidal thickness after treatment of central serous chorioretinopathy. *Ophthalmology* 117, 1792–1799.
- Maruko, I., Koizumi, H., Hasegawa, T., Arakawa, H., Iida, T., 2017. Subthreshold 577 nm micropulse laser treatment for central serous chorioretinopathy. *PLoS One* 12, e0184112.
- Matet, A., Daruich, A., Zola, M., Behar-Cohen, F., 2018. Risk factors for recurrences of central serous chorioretinopathy. *Retina* 38, 1403–1414.
- Mathur, V., Parihar, J., Maggon, R., Mishra, S.K., 2009. Role of transpupillary thermotherapy in central serous chorioretinopathy. *Med. J. Armed Forces India* 65, 323–327.
- Maumenee, A.E., 1965. Macular diseases: clinical manifestations. *Trans. Am. Acad. Ophthalmol. Otolaryngol.* 69, 605–613.
- Mazzolani, F., 2012. Pilot study of oral administration of a curcumin-phospholipid formulation for treatment of central serous chorioretinopathy. *Clin. Ophthalmol.* 6, 801–806.
- Mazzolani, F., Togni, S., 2013. Oral administration of a curcumin-phospholipid delivery system for the treatment of central serous chorioretinopathy: a 12-month follow-up study. *Clin. Ophthalmol.* 7, 939–945.
- McMahon, E.G., 2001. Recent studies with eplerenone, a novel selective aldosterone receptor antagonist. *Curr. Opin. Pharmacol.* 1, 190–196.
- Mehta, H., Tufail, A., Daien, V., Lee, A.Y., Nguyen, V., Ozturk, M., Barthelmes, D., Gillies, M.C., 2018. Real-world outcomes in patients with neovascular age-related macular degeneration treated with intravitreal vascular endothelial growth factor inhibitors. *Prog. Retin. Eye Res.* 65, 127–146.
- Mehta, P.H., Meyerle, C., Sivaprasad, S., Boon, C., Chhablani, J., 2017. Preferred practice pattern in central serous chorioretinopathy. *Br. J. Ophthalmol.* 101, 587–590.
- Meyerle, C.B., Freund, K.B., Bhatnagar, P., Shah, V., Yannuzzi, L.A., 2007. Ketoconazole in the treatment of chronic idiopathic central serous chorioretinopathy. *Retina* 27, 943–946.
- Mieler, W.F., Jaffe, G.J., Steeves, R.A., 1989. Ferromagnetic hyperthermia and iodine 125 brachytherapy in the treatment of choroidal melanoma in a rabbit model. *Arch. Ophthalmol.* 107, 1524–1528.
- Miki, A., Kondo, N., Yanagisawa, S., Bessho, H., Honda, S., Negi, A., 2014. Common variants in the complement factor h gene confer genetic susceptibility to central serous chorioretinopathy. *Ophthalmology* 121, 1067–1072.
- Miki, A., Sakurada, Y., Tanaka, K., Semba, K., Mitamura, Y., Yuzawa, M., Tajima, A., Nakatochi, M., Yamamoto, K., Matsuo, K., Imoto, I., Honda, S., 2018. Genome-wide association study to identify a new susceptibility locus for central serous chorioretinopathy in the Japanese population. *Investig. Ophthalmol. Vis. Sci.* 59, 5542–5547.
- Miller, H., Miller, B., 1993. Photodynamic therapy of subretinal neovascularization in the monkey eye. *Arch. Ophthalmol.* 111, 855–860.
- Miller, J.W., Stinson, W.G., Gregory, W.A., el-Koumy, H.A., Puliafito, C.A., 1991. Phthalocyanine photodynamic therapy of experimental iris neovascularization. *Ophthalmology* 98, 1711–1719.
- Miller, J.W., Walsh, A.W., Kramer, M., Hasan, T., Michaud, N., Flotte, T.J., Haimovici, R., Gragoudas, E.S., 1995. Photodynamic therapy of experimental choroidal neovascularization using lipoprotein-delivered benzoporphyrin. *Arch. Ophthalmol.* 113, 810–818.
- Mohabati, D., de Jong, E.K., Boon, C.J.F., Yzer, S., 2019. Risk of Recurrence and Transition to Chronic Disease in Acute Central Serous Chorioretinopathy. *Investig. Ophthalmol. Vis. Sci.* Submitted for publication.
- Mohabati, D., Schellevis, R.L., van Dijk, E.H.C., Altay, L., Fauser, S., Hoyng, C.B., De Jong, E.K., Boon, C.J.F., Yzer, S., 2018. Genetic risk factors in acute central serous chorioretinopathy. *Retina*. <https://doi.org/10.1097/IAE.0000000000002333>.
- Mohabati, D., van Dijk, E.H., van Rijnssen, T.J., de Jong, E.K., Breukink, M.B., Martinez-Ciriano, J.P., Dijkman, G., Hoyng, C.B., Fauser, S., Yzer, S., Boon, C.J., 2018b. Clinical spectrum of severe chronic central serous chorioretinopathy and outcome of photodynamic therapy. *Clin. Ophthalmol.* 12, 2167–2176.
- Mohabati, D., van Rijnssen, T.J., van Dijk, E.H., Luyten, G.P., Missotten, T.O., Hoyng, C.B., Yzer, S., Boon, C.J., 2018c. Clinical characteristics and long-term visual outcome of severe phenotypes of chronic central serous chorioretinopathy. *Clin. Ophthalmol.* 12, 1061–1070.
- Moisseiev, E., Holmes, A.J., Moshiri, A., Morse, L.S., 2016. Finasteride is effective for the treatment of central serous chorioretinopathy. *Eye* 30, 850–856.
- Montero, J.A., Ruiz-Moreno, J.M., 2005. Optical coherence tomography characterisation of idiopathic central serous chorioretinopathy. *Br. J. Ophthalmol.* 89, 562–564.
- Moorman, C.M., Hamilton, A.M., 1999. Clinical applications of the micropulse diode laser. *Eye* 13 (Pt 2), 145–150.
- Moschos, M.M., Gazouli, M., Gatziofias, Z., Brouzas, D., Nomikarios, N., Sivaprasad, S., Mitropoulos, P., Chatziralli, I.P., 2016. Prevalence of the complement factor h and gstm1 genes polymorphisms in patients with central serous chorioretinopathy. *Retina* 36, 402–407.
- Moulin, A.P., Bucher, M., Pournaras, J.A., Nguyen, C., Ambresin, A., 2010. Fluorescein and indocyanine green angiography findings in b cell lymphoblastic leukemia mimicking acute central serous chorioretinopathy. *Klin. Monatsblätter Augenheilkd.* 227, 342–344.
- Mrejen, S., Balaratnasingam, C., Kaden, T.R., Bottini, A., Dansingani, K., Bhavsar, K.V., Yannuzzi, N.A., Patel, S., Chen, K.C., Yu, S., Stoffels, G., Spaide, R.F., Freund, K.B., Yannuzzi, L.A., 2019. Long-term visual outcomes and causes of vision loss in chronic central serous chorioretinopathy. *Ophthalmology* 126, 576–588.
- Muller, B., Tatsios, J., Klöner, J., Pilger, D., Jousen, A.M., 2018. Navigated laser photocoagulation in patients with non-resolving and chronic central serous chorioretinopathy. *Graefes Arch. Clin. Exp. Ophthalmol.* 256, 1581–1588.
- Nair, U., Ganekal, S., Soman, M., Nair, K., 2012. Correlation of spectral domain optical coherence tomography findings in acute central serous chorioretinopathy with visual acuity. *Clin. Ophthalmol.* 6, 1949–1954.
- Nakanishi, H., Tsujikawa, A., Gotoh, N., Hayashi, H., Iwama, D., Tamura, H., Otani, A., Yoshimura, N., 2008. Macular complications on the border of an inferior staphyloma associated with tilted disc syndrome. *Retina* 28, 1493–1501.
- Negi, A., Marmor, M.F., 1984. Experimental serous retinal detachment and focal pigment epithelial damage. *Arch. Ophthalmol.* 102, 445–449.
- Neves, F., Costa, J., Fonseca, S., Silva, L., Agrelos, L., 2016. Half-dose photodynamic therapy for chronic central serous chorioretinopathy: efficacy and safety outcomes in real world. *Photodiagn. Photodyn. Ther.* 14, 173–177.
- Newman, D.K., 2016. Photodynamic therapy: current role in the treatment of chorioretinal conditions. *Eye* 30, 202–210.
- Nicholson, B., Noble, J., Forooghian, F., Meyerle, C., 2013. Central serous chorioretinopathy: update on pathophysiology and treatment. *Surv. Ophthalmol.* 58, 103–126.
- Nicholson, B.P., Ali Idris, A.M., Bakri, S.J., 2018. Central serous chorioretinopathy: clinical characteristics associated with visual outcomes. *Semin. Ophthalmol.* 1–4.
- Nicolo, M., Eandi, C.M., Alovisi, C., Grignolo, F.M., Traverso, C.E., Musetti, D., Cardillo Piccolino, F., 2014. Half-fluence versus half-dose photodynamic therapy in chronic central serous chorioretinopathy. *Am. J. Ophthalmol.* 157, 1033–1037.
- Nicolo, M., Zoli, D., Musolino, M., Traverso, C.E., 2012. Association between the efficacy of half-dose photodynamic therapy with indocyanine green angiography and optical coherence tomography findings in the treatment of central serous chorioretinopathy. *Am. J. Ophthalmol.* 153, 474–480 e471.
- Nielsen, J.S., Jampol, L.M., 2011. Oral mifepristone for chronic central serous chorioretinopathy. *Retina* 31, 1928–1936.
- Nourinia, R., Ahmadi, H., Nekoei, E., Malekifar, P., Tofighi, Z., 2018. Changes in central choroidal thickness after treatment of diabetic macular edema with intravitreal bevacizumab correlation with central macular thickness and best-corrected

- visual acuity. *Retina* 38, 970–975.
- Novak, M.A., Singerman, L.J., Rice, T.A., 1987. Krypton and argon laser photocoagulation for central serous chorioretinopathy. *Retina* 7, 162–169.
- Ntomoka, C.G., Rajesh, B., Muriithi, G.M., Goud, A., Chhablani, J., 2018. Comparison of photodynamic therapy and navigated microsecond laser for chronic central serous chorioretinopathy. *Eye* 32, 1079–1086.
- O'Keefe, G.A., Rao, N.A., 2017. Vogt-koyanagi-harada disease. *Surv. Ophthalmol.* 62, 1–25.
- Ober, M.D., Yannuzzi, L.A., Do, D.V., Spaide, R.F., Bressler, N.M., Jampol, L.M., Angelilli, A., Eandi, C.M., Lyon, A.T., 2005. Photodynamic therapy for focal retinal pigment epithelial leaks secondary to central serous chorioretinopathy. *Ophthalmology* 112, 2088–2094.
- Oh, B.L., Yu, H.G., 2015. Choroidal thickness after full-fluence and half-fluence photodynamic therapy in chronic central serous chorioretinopathy. *Retina* 35, 1555–1560.
- Ohkuma, Y., Hayashi, T., Sakai, T., Watanabe, A., Tsunooka, H., 2013. One-year results of reduced fluence photodynamic therapy for central serous chorioretinopathy: the outer nuclear layer thickness is associated with visual prognosis. *Graefes Arch. Clin. Exp. Ophthalmol.* 251, 1909–1917.
- Oosterhuis, J.A., Journee-de Korver, H.G., Kakebeeke-Kemme, H.M., Bleeker, J.C., 1995. Transpupillary thermotherapy in choroidal melanomas. *Arch. Ophthalmol.* 113, 315–321.
- Ooto, S., Hangai, M., Sakamoto, A., Tsujikawa, A., Yamashiro, K., Ojima, Y., Yamada, Y., Mukai, H., Oshima, S., Inoue, T., Yoshimura, N., 2010a. High-resolution imaging of resolved central serous chorioretinopathy using adaptive optics scanning laser ophthalmoscopy. *Ophthalmology* 117, 1800–1809. e1801-1802.
- Ooto, S., Tsujikawa, A., Mori, S., Tamura, H., Yamashiro, K., Yoshimura, N., 2010b. Thickness of photoreceptor layers in polypoidal choroidal vasculopathy and central serous chorioretinopathy. *Graefes Arch. Clin. Exp. Ophthalmol.* 248, 1077–1086.
- Otsuka, S., Ohba, N., Nakao, K., 2002. A long-term follow-up study of severe variant of central serous chorioretinopathy. *Retina* 22, 25–32.
- Ozkaya, A., Alkin, Z., Ozveren, M., Yazici, A.T., Taskapili, M., 2016. The time of resolution and the rate of recurrence in acute central serous chorioretinopathy following spontaneous resolution and low-fluence photodynamic therapy: a case-control study. *Eye* 30, 1005–1010.
- Ozmert, E., Demirel, S., Yanik, O., Batioglu, F., 2016. Low-fluence photodynamic therapy versus subthreshold micropulse yellow wavelength laser in the treatment of chronic central serous chorioretinopathy. *J. Ophthalmol.* 3513794 2016.
- Pandi-Perumal, S.R., Trakht, I., Spence, D.W., Srinivasan, V., Dagan, Y., Cardinali, D.P., 2008. The roles of melatonin and light in the pathophysiology and treatment of circadian rhythm sleep disorders. *Nat. Clin. Pract. Neurol.* 4, 436–447.
- Pang, C.E., Freund, K.B., 2015. Pachychoroid neovascularopathy. *Retina* 35, 1–9.
- Pang, C.E., Shah, V.P., Sarraf, D., Freund, K.B., 2014. Ultra-widefield imaging with autofluorescence and indocyanine green angiography in central serous chorioretinopathy. *Am. J. Ophthalmol.* 158, 362–371 e362.
- Park, S.U., Lee, S.J., Kim, M., 2014. Intravitreal anti-vascular endothelial growth factor versus observation in acute central serous chorioretinopathy: one-year results. *Korean J. Ophthalmol.* 28, 306–313.
- Park, Y.G., Kang, S., Kim, M., Yoo, N., Roh, Y.J., 2017. Selective retina therapy with automatic real-time feedback-controlled dosimetry for chronic central serous chorioretinopathy in Korean patients. *Graefes Arch. Clin. Exp. Ophthalmol.* 255, 1375–1383.
- Patz, A., Maumenee, A.E., Ryan, S.J., 1971. Argon laser photocoagulation in macular diseases. *Trans. Am. Ophthalmol. Soc.* 69, 71–83.
- Peiretti, E., Caminiti, G., Serra, R., Querques, L., Pertile, R., Querques, G., 2018. Anti-vascular endothelial growth factor therapy versus photodynamic therapy in the treatment of choroidal neovascularization secondary to central serous chorioretinopathy. *Retina* 38, 1526–1532.
- Peiretti, E., Ferrara, D.C., Caminiti, G., Mura, M., Hughes, J., 2015. Choroidal neovascularization in caucasian patients with longstanding central serous chorioretinopathy. *Retina* 35, 1360–1367.
- Peters, S., Julien, S., Heiduschka, P., Grisanti, S., Ziemssen, F., Adler, M., Schraermeyer, U., Bartz-Schmidt, K.U., 2007. Antipermiability and antiproliferative effects of standard and frozen bevacizumab on choroidal endothelial cells. *Br. J. Ophthalmol.* 91, 827–831.
- Pichi, F., Carrai, P., Ciardella, A., Behar-Cohen, F., Nucci, P., Central Serous Chorioretinopathy Study, G., 2017. Comparison of two mineralcorticosteroids receptor antagonists for the treatment of central serous chorioretinopathy. *Int. Ophthalmol.* 37, 1115–1125.
- Pikkel, J., Beiran, I., Ophir, A., Miller, B., 2002. Acetazolamide for central serous retinopathy. *Ophthalmology* 109, 1723–1725.
- Pitcher 3rd, J.D., Witkin, A.J., DeCros, F.C., Ho, A.C., 2015. A prospective pilot study of intravitreal aflibercept for the treatment of chronic central serous chorioretinopathy: the contain study. *Br. J. Ophthalmol.* 99, 848–852.
- Pitt, B., Remme, W., Zannad, F., Neaton, J., Martinez, F., Roniker, B., Bittman, R., Hurley, S., Kleiman, J., Gatlin, M., 2003. Eplerenone, a selective aldosterone blocker, in patients with left ventricular dysfunction after myocardial infarction. *N. Engl. J. Med.* 348, 1309–1321.
- Polak, B.C., Baarsma, G.S., Snyers, B., 1995. Diffuse retinal pigment epitheliopathy complicating systemic corticosteroid treatment. *Br. J. Ophthalmol.* 79, 922–925.
- Pollack, J.S., Kim, J.E., Pulido, J.S., Burke, J.M., 1998. Tissue effects of subclinical diode laser treatment of the retina. *Arch. Ophthalmol.* 116, 1633–1639.
- Prunte, C., Flammer, J., 1996. Choroidal capillary and venous congestion in central serous chorioretinopathy. *Am. J. Ophthalmol.* 121, 26–34.
- Pryds, A., Larsen, M., 2012. Choroidal thickness following extrafoveal photodynamic treatment with verteporfin in patients with central serous chorioretinopathy. *Acta Ophthalmol.* 90, 738–743.
- Pryds, A., Larsen, M., 2013. Foveal function and thickness after verteporfin photodynamic therapy in central serous chorioretinopathy with hyperautofluorescent subretinal deposits. *Retina* 33, 128–135.
- Quaranta-El Maftouhi, M., El Maftouhi, A., Eandi, C.M., 2015. Chronic central serous chorioretinopathy imaged by optical coherence tomographic angiography. *Am. J. Ophthalmol.* 160, 581–587 e581.
- Rabiolo, A., Zucchiatti, I., Marchese, A., Baldin, G., Sacconi, R., Montorio, D., Cicinelli, M.V., Querques, L., Bandello, F., Querques, G., 2018. Multimodal retinal imaging in central serous chorioretinopathy treated with oral eplerenone or photodynamic therapy. *Eye* 32, 55–66.
- Rahbani-Nobar, M.B., Javadzadeh, A., Ghojzadeh, L., Rafeey, M., Ghorbanhaghjo, A., 2011. The effect of helicobacter pylori treatment on remission of idiopathic central serous chorioretinopathy. *Mol. Vis.* 17, 99–103.
- Rahimy, E., Pitcher 3rd, J.D., Hsu, J., Adam, M.K., Shahlaee, A., Samara, W.A., Vander, J.F., Kaiser, R.S., Chiang, A., Spinn, M.J., Fineman, M.S., 2018. A randomized double-blind placebo-control pilot study of eplerenone for the treatment of central serous chorioretinopathy (ecelsior). *Retina* 38, 962–969.
- Rahman, W., Horgan, N., Hungerford, J., 2013. Circumscribed choroidal haemangioma mimicking chronic central serous chorioretinopathy. *J. Fr. Ophthalmol.* 36, e37–40.
- Rajesh, B., Agrawal, H., Peguda, H.K., Chhablani, J., 2018. Predictors of outcome during eplerenone therapy in chronic central serous chorioretinopathy: A prospective, open-label pilot clinical study. *Ophthalmic Surg. Lasers Imaging Retina* 49, 479–486.
- Ramos-Yau, E.C., Munoz-Dominguez, E., Contreras-Merida, S.P., Valencia-Londono, L.M., 2018. Spironolactone as a therapeutic alternative for the bullous variant of central serous chorioretinopathy. *Retin. Cases Brief Rep.* <https://doi.org/10.1097/ICB.0000000000000719>.
- Ratanasukon, M., Bhurayanontachai, P., Jirattanasopa, P., 2012. High-dose anti-oxidants for central serous chorioretinopathy; the randomized placebo-controlled study. *BMC Ophthalmol.* 12, 20.
- Ricci, F., Missiroli, F., Cerulli, L., 2004. Indocyanine green dye-enhanced micropulsed diode laser: a novel approach to subthreshold rpe treatment in a case of central serous chorioretinopathy. *Eur. J. Ophthalmol.* 14, 74–82.
- Ricci, F., Missiroli, F., Regine, F., Grossi, M., Dorin, G., 2009. Indocyanine green enhanced subthreshold diode-laser micropulse photocoagulation treatment of chronic central serous chorioretinopathy. *Graefes Arch. Clin. Exp. Ophthalmol.* 247, 597–607.
- Rim, T.H., Kim, H.S., Kwak, J., Lee, J.S., Kim, D.W., Kim, S.S., 2018. Association of corticosteroid use with incidence of central serous chorioretinopathy in South Korea. *JAMA Ophthalmol* 136, 1164–1169.
- Robertson, D.M., 1986. Argon laser photocoagulation treatment in central serous chorioretinopathy. *Ophthalmology* 93, 972–974.
- Robertson, D.M., Ilstrup, D., 1983. Direct, indirect, and sham laser photocoagulation in the management of central serous chorioretinopathy. *Am. J. Ophthalmol.* 95, 457–466.
- Roca, J.A., Wu, L., Fromow-Guerra, J., Rodriguez, F.J., Berrocal, M.H., Rojas, S., Lima, L.H., Gallego-Pinazo, R., Chhablani, J., Arevalo, J.F., Lozano-Rechy, D., Serrano, M., 2018. Yellow (577 nm) micropulse laser versus half-dose verteporfin photodynamic therapy in eyes with chronic central serous chorioretinopathy: results of the pan-american collaborative retina study (pacores) group. *Br. J. Ophthalmol.* 102, 1696–1700.
- Rochepeau, C., Kodjikian, L., Garcia, M.A., Coulon, C., Burillon, C., Denis, P., Delaunay, B., Mathis, T., 2018. Optical coherence tomography quantitative assessment of choriocapillaris blood flow in central serous chorioretinopathy. *Am. J. Ophthalmol.* 194, 26–34.
- Roisman, L., Magalhaes, F.P., Lavinsky, D., Moraes, N., Hirai, F.E., Cardillo, J.A., Farah, M.E., 2013. Micropulse diode laser treatment for chronic central serous chorioretinopathy: a randomized pilot trial. *Ophthalmic Surg. Lasers Imaging Retina* 44, 465–470.
- Roohipour, R., Sharifian, E., Ghassemi, F., Riaz-Esfahani, M., Karkhaneh, R., Fard, M.A., Zarei, M., Modjtahedi, B.S., Moghimi, S., 2016. Choroidal thickness changes in proliferative diabetic retinopathy treated with panretinal photocoagulation versus panretinal photocoagulation with intravitreal bevacizumab. *Retina* 36, 1997–2005.
- Roy, R., Saurabh, K., Das, D., Panigrahi, P.K., Das, S., Pal, S.S., Jain, A., 2017. Variation in visual outcome to anti-vascular endothelial growth factors in choroidal neovascular membrane developing in eyes with previously untreated versus focal laser-treated central serous chorioretinopathy. *Semin. Ophthalmol.* 32, 781–786.
- Roybal, C.N., Sledz, E., Elshatory, Y., Zhang, L., Almeida, D.R.P., Chin, E.K., Critser, B., Abramoff, M.D., Russell, S.R., 2018. Dysfunctional autonomic regulation of the choroid in central serous chorioretinopathy. *Retina* 38, 1205–1210.
- Rubsam, A., Thieme, C.E., Schlomberg, J., Winterhalter, S., Muller, B., Jousen, A.M., Stubiger, N., 2017. Therapy rationale for mineralocorticoid-receptor antagonists, acetazolamide and a switch of therapy in nonresponders in central serous chorioretinopathy. *J. Ocul. Pharmacol. Ther.* 33, 141–148.
- Ruiz-Moreno, J.M., Lugo, F.L., Armada, F., Silva, R., Montero, J.A., Arevalo, J.F., Arias, L., Gomez-Ulla, F., 2010. Photodynamic therapy for chronic central serous chorioretinopathy. *Acta Ophthalmol.* 88, 371–376.
- Russo, A., Turano, R., Morescalchi, F., Gambicorti, E., Cancarini, A., Duse, S., Costagliola, C., Semeraro, F., 2017. Comparison of half-dose photodynamic therapy and 689 nm laser treatment in eyes with chronic central serous chorioretinopathy. *Graefes Arch. Clin. Exp. Ophthalmol.* 255, 1141–1148.
- Sacconi, R., Baldin, G., Carnevali, A., Querques, L., Rabiolo, A., Marchini, G., Bandello, F., Querques, G., 2018. Response of central serous chorioretinopathy evaluated by multimodal retinal imaging. *Eye* 32, 734–742.
- Sahin, A., Bez, Y., Kaya, M.C., Turkcu, F.M., Sahin, M., Yuksel, H., 2014. Psychological distress and poor quality of life in patients with central serous chorioretinopathy. *Semin. Ophthalmol.* 29, 73–76.
- Sahoo, N.K., Mishra, S.B., Iovino, C., Singh, S.R., Munk, M.R., Berger, L., Peiretti, E.,

- Chhablani, J., 2019. Optical coherence tomography angiography findings in cystoid macular degeneration associated with central serous chorioretinopathy. *Br. J. Ophthalmol.* <https://doi.org/10.1136/bjophthalmol-2018-313048>.
- Saito, M., Saito, W., Hashimoto, Y., Yoshizawa, C., Fujiya, A., Noda, K., Ishida, S., 2013. Macular choroidal blood flow velocity decreases with regression of acute central serous chorioretinopathy. *Br. J. Ophthalmol.* *97*, 775–780.
- Saito, M., Saito, W., Hirooka, K., Hashimoto, Y., Mori, S., Noda, K., Ishida, S., 2015. Pulse waveform changes in macular choroidal hemodynamics with regression of acute central serous chorioretinopathy. *Investig. Ophthalmol. Vis. Sci.* *56*, 6515–6522.
- Salehi, M., Wenick, A.S., Law, H.A., Evans, J.R., Gehlbach, P., 2015. Interventions for central serous chorioretinopathy: a network meta-analysis. *Cochrane Database Syst. Rev.* CD011841.
- Sampo, M., Soler, V., Gascon, P., Ho Wang Yin, G., Hoffart, L., Denis, D., Matonti, F., 2016. [Eplerenone treatment in chronic central serous chorioretinopathy]. *J. Fr. Ophtalmol.* *39*, 535–542.
- Sanguansak, T., Pitujaturont, P., Yospaiboon, Y., Sinawat, S., Ratanapakorn, T., Bhoomibunchoo, C., 2015. Macular sensitivity after half-dose verteporfin photodynamic therapy in central serous chorioretinopathy. *Clin. Ophthalmol.* *9*, 2257–2261.
- Schatz, H., McDonald, H.R., Johnson, R.N., Chan, C.K., Irvine, A.R., Berger, A.R., Folk, J.C., Robertson, D.M., 1995. Subretinal fibrosis in central serous chorioretinopathy. *Ophthalmology* *102*, 1077–1088.
- Scheider, A., Nagemann, J.E., Lund, O.E., 1993. Fluorescein and indocyanine green angiographies of central serous choroidopathy by scanning laser ophthalmoscopy. *Am. J. Ophthalmol.* *115*, 50–56.
- Schellevis, R.L., van Dijk, E.H.C., Breukink, M.B., Altay, L., Bakker, B., Koeleman, B.P.C., Kiemene, L.A., Swinkels, D.W., Keunen, J.E.E., Fauser, S., Hoyng, C.B., den Hollander, A.I., Boon, C.J.F., de Jong, E.K., 2018. Role of the complement system in chronic central serous chorioretinopathy: a genome-wide association study. *JAMA Ophthalmol* *136*, 1128–1136.
- Schlötzer-Schrehardt, U., Viestenz, A., Naumann, G.O., Laqua, H., Michels, S., Schmidt-Erfurth, U., 2002. Dose-related structural effects of photodynamic therapy on choroidal and retinal structures of human eyes. *Graefes Arch. Clin. Exp. Ophthalmol.* *240*, 748–757.
- Schmidt-Erfurth, U., Hasan, T., 2000. Mechanisms of action of photodynamic therapy with verteporfin for the treatment of age-related macular degeneration. *Surv. Ophthalmol.* *45*, 195–214.
- Scholz, P., Altay, L., Fauser, S., 2016. Comparison of subthreshold micropulse laser (577 nm) treatment and half-dose photodynamic therapy in patients with chronic central serous chorioretinopathy. *Eye* *30*, 1371–1377.
- Scholz, P., Altay, L., Fauser, S., 2017. A review of subthreshold micropulse laser for treatment of macular disorders. *Adv. Ther.* *34*, 1528–1555.
- Scholz, P., Ersoy, L., Boon, C.J., Fauser, S., 2015. Subthreshold micropulse laser (577 nm) treatment in chronic central serous chorioretinopathy. *Ophthalmologica* *234*, 189–194.
- Schubert, C., Pryds, A., Zeng, S., Xie, Y., Freund, K.B., Spaide, R.F., Merriam, J.C., Barbazetto, I., Slakter, J.S., Chang, S., Munch, I.C., Drack, A.V., Hernandez, J., Yzer, S., Merriam, J.E., Linneberg, A., Larsen, M., Yannuzzi, L.A., Mullins, R.F., Allikmets, R., 2014. Cadherin 5 is regulated by corticosteroids and associated with central serous chorioretinopathy. *Hum. Mutat.* *35*, 859–867.
- Schwartz, R., Habet-Wilner, Z., Martinez, M.R., Nutman, A., Goldenberg, D., Cohen, S., Shulman, S., Guzman-Gur, H., Loewenstein, A., Goldstein, M., 2017. Eplerenone for chronic central serous chorioretinopathy—a randomized controlled prospective study. *Acta Ophthalmol.* *95*, e610–e618.
- Semeraro, F., Romano, M.R., Danzi, P., Morescalchi, F., Costagliola, C., 2012. Intravitreal bevacizumab versus low-fluence photodynamic therapy for treatment of chronic central serous chorioretinopathy. *Jpn. J. Ophthalmol.* *56*, 608–612.
- Senturk, F., Karacorlu, M., Ozdemir, H., Karacorlu, S.A., Uysal, O., 2011. Microperimetric changes after photodynamic therapy for central serous chorioretinopathy. *Am. J. Ophthalmol.* *151*, 303–309 e301.
- Setrouk, E., Hubault, B., Vankemmel, F., Zambrowski, O., Nazeyrollas, P., Delemer, B., Durlach, V., Ducasse, A., Arndt, C., 2016. Circadian disturbance and idiopathic central serous chorioretinopathy. *Graefes Arch. Clin. Exp. Ophthalmol.* *254*, 2175–2181.
- Sheptulin, V., Purtskhvanidze, K., Roider, J., 2018. Half-time photodynamic therapy in treatment of chronic central serous chorioretinopathy. *Graefes Arch. Clin. Exp. Ophthalmol.* *256*, 2027–2034.
- Shields, C.L., Dalvin, L.A., Ancona-Lezama, D., Yu, M.D., Di Nicola, M., Williams Jr., B.K., Lucio-Alvarez, J.A., Ang, S.M., Maloney, S., Welch, R.J., Shields, J.A., 2018. Choroidal nevi imaging features in 3,806 cases and risk factors for transformation into melanoma in 2,355 cases. In: *The 2020 Taylor R. Smith and Victor T. Curtin Lecture. Retina*.
- Shields, C.L., Honavar, S.G., Shields, J.A., Cater, J., Demirci, H., 2001. Circumscribed choroidal hemangioma: clinical manifestations and factors predictive of visual outcome in 200 consecutive cases. *Ophthalmology* *108*, 2237–2248.
- Shin, J.Y., Woo, S.J., Yu, H.G., Park, K.H., 2011. Comparison of efficacy and safety between half-fluence and full-fluence photodynamic therapy for chronic central serous chorioretinopathy. *Retina* *31*, 119–126.
- Shin, W.B., Kim, M.K., Lee, C.S., Lee, S.C., Kim, H., 2015. Comparison of the clinical manifestations between acute vogt-koyanagi-harada disease and acute bilateral central serous chorioretinopathy. *Korean J. Ophthalmol.* *29*, 389–395.
- Shiode, Y., Morizane, Y., Kimura, S., Hosokawa, M., Kawata, T., Doi, S., Hosogi, M., Fujiwara, A., Shiraga, F., 2015. Comparison of halving the irradiation time or the verteporfin dose in photodynamic therapy for chronic central serous chorioretinopathy. *Retina* *35*, 2498–2504.
- Shiragami, C., 2018. Reply. *Am. J. Ophthalmol.* *195*, 246.
- Shukla, D., Kolluru, C., Vignesh, T.P., Karthikprakash, S., Kim, R., 2008. Transpupillary thermotherapy for subfoveal leaks in central serous chorioretinopathy. *Eye* *22*, 100–106.
- Shulman, S., Goldenberg, D., Schwartz, R., Habet-Wilner, Z., Barak, A., Ehrlich, N., Loewenstein, A., Goldstein, M., 2016. Oral rifampin treatment for longstanding chronic central serous chorioretinopathy. *Graefes Arch. Clin. Exp. Ophthalmol.* *254*, 15–22.
- Siegfried, F., Rommel, F., Rothe, M., Brinkmann, M.P., Sochurek, J.A.M., Freitag, J., Grisanti, S., Ranjbar, M., 2019. Evaluating diurnal changes in choroidal sublayer perfusion using optical coherence tomography angiography. *Acta Ophthalmol.* <https://doi.org/10.1111/aos.14140>.
- Silva, R.M., Ruiz-Moreno, J.M., Gomez-Ulla, F., Montero, J.A., Gregorio, T., Cachulo, M.L., Pires, I.A., Cunha-Vaz, J.G., Murta, J.N., 2013. Photodynamic therapy for chronic central serous chorioretinopathy: a 4-year follow-up study. *Retina* *33*, 309–315.
- Singh, R.P., Sears, J.E., Bedi, R., Schachat, A.P., Ehlers, J.P., Kaiser, P.K., 2015. Oral eplerenone for the management of chronic central serous chorioretinopathy. *Int. J. Ophthalmol.* *8*, 310–314.
- Singh, S.R., Matet, A., van Dijk, E.H.C., Daruich, A., Fauser, S., Yzer, S., Peiretti, E., Sivaprasad, S., Lotery, A.J., Boon, C.J.F., Behar-Cohen, F., Freund, K.B., Chhablani, J., 2018. Discrepancy in current central serous chorioretinopathy classification. *Br. J. Ophthalmol.* *103*, 737–742.
- Sivaprasad, S., Elagouz, M., McHugh, D., Shona, O., Dorin, G., 2010. Micropulsed diode laser therapy: evolution and clinical applications. *Surv. Ophthalmol.* *55*, 516–530.
- Smretschnik, E., Ansari-Shahrezaei, S., Hagen, S., Glittenberg, C., Krebs, I., Binder, S., 2013. Half-fluence photodynamic therapy in chronic central serous chorioretinopathy. *Retina* *33*, 316–323.
- Song, I.S., Shin, Y.U., Lee, B.R., 2012. Time-periodic characteristics in the morphology of idiopathic central serous chorioretinopathy evaluated by volume scan using spectral-domain optical coherence tomography. *Am. J. Ophthalmol.* *154*, 366–375 e364.
- Soomro, T., Talks, J., 2018. The use of optical coherence tomography angiography for detecting choroidal neovascularization, compared to standard multimodal imaging. *Eye* *32*, 661–672.
- Spahn, C., Wiek, J., Burger, T., Hansen, L., 2003. Psychosomatic aspects in patients with central serous chorioretinopathy. *Br. J. Ophthalmol.* *87*, 704–708.
- Spaide, R., 2008. Autofluorescence from the outer retina and subretinal space: hypothesis and review. *Retina* *28*, 5–35.
- Spaide, R.F., Campeas, L., Haas, A., Yannuzzi, L.A., Fisher, Y.L., Guyer, D.R., Slakter, J.S., Sorenson, J.A., Orlock, D.A., 1996a. Central serous chorioretinopathy in younger and older adults. *Ophthalmology* *103*, 2070–2079 discussion 2079–2080.
- Spaide, R.F., Hall, L., Haas, A., Campeas, L., Yannuzzi, L.A., Fisher, Y.L., Guyer, D.R., Slakter, J.S., Sorenson, J.A., Orlock, D.A., 1996b. Indocyanine green videoangiography of older patients with central serous chorioretinopathy. *Retina* *16*, 203–213.
- Spaide, R.F., Klancnik Jr., J.M., 2005. Fundus autofluorescence and central serous chorioretinopathy. *Ophthalmology* *112*, 825–833.
- Spaide, R.F., Yannuzzi, L.A., Slakter, J.S., Sorenson, J., Orlock, D.A., 1995. Indocyanine green videoangiography of idiopathic polypoidal choroidal vasculopathy. *Retina* *15*, 100–110.
- Spitznas, M., 1986. Pathogenesis of central serous retinopathy: a new working hypothesis. *Graefes Arch. Clin. Exp. Ophthalmol.* *224*, 321–324.
- Sramek, C., Mackanos, M., Spittler, R., Leung, L.S., Nomoto, H., Contag, C.H., Palanker, D., 2011. Non-damaging retinal phototherapy: dynamic range of heat shock protein expression. *Investig. Ophthalmol. Vis. Sci.* *52*, 1780–1787.
- Steinle, N.C., Gupta, N., Yuan, A., Singh, R.P., 2012. Oral rifampin utilisation for the treatment of chronic multifocal central serous retinopathy. *Br. J. Ophthalmol.* *96*, 10–13.
- Stewart, J.M., 2006. Half dose verteporfin pdt for central serous chorioretinopathy. *Br. J. Ophthalmol.* *90*, 805–806.
- Sun, X., Shuai, Y., Fang, W., Li, J., Ge, W., Yuan, S., Liu, Q., 2018. Spironolactone versus observation in the treatment of acute central serous chorioretinopathy. *Br. J. Ophthalmol.* *102*, 1060–1065.
- Sunness, J.S., 1988. The pregnant woman's eye. *Surv. Ophthalmol.* *32*, 219–238.
- Takahashi, H., Hayashi, T., Tsuneoka, H., Nakano, T., Yamada, H., Katagiri, S., Fujino, Y., Noda, Y., Yoshimoto, M., Kawashima, H., 2014. Occult macular dystrophy with bilateral chronic subfoveal serous retinal detachment associated with a novel rp111 mutation (p.S1199p). *Doc. Ophthalmol.* *129*, 49–56.
- Tatham, A., Macfarlane, A., 2006. The use of propranolol to treat central serous chorioretinopathy: an evaluation by serial oct. *J. Ocul. Pharmacol. Ther.* *22*, 145–149.
- Tekin, K., Sekeroglu, M.A., Cankaya, A.B., Teke, M.Y., Doguizi, S., Yilmazbas, P., 2018. Intravitreal bevacizumab and ranibizumab in the treatment of acute central serous chorioretinopathy: a single center retrospective study. *Semin. Ophthalmol.* *33*, 265–270.
- Teussink, M.M., Breukink, M.B., van Grinsven, M.J., Hoyng, C.B., Klevering, B.J., Boon, C.J., de Jong, E.K., Theelen, T., 2015. Oct angiography compared to fluorescein and indocyanine green angiography in chronic central serous chorioretinopathy. *Investig. Ophthalmol. Vis. Sci.* *56*, 5229–5237.
- Thomas, E.L., Olk, R.J., Markman, M., Braine, H., Patz, A., 1983. Irreversible visual loss in waldenström's macroglobulinemia. *Br. J. Ophthalmol.* *67*, 102–106.
- Ting, D.S., Ng, W.Y., Ng, S.R., Tan, S.P., Yeo, I.Y., Mathur, R., Chan, C.M., Tan, A.C., Tan, G.S., Wong, T.Y., Cheung, C.M., 2016. Choroidal thickness changes in age-related macular degeneration and polypoidal choroidal vasculopathy: a 12-month prospective study. *Am. J. Ophthalmol.* *164*, 128–136 e121.
- Tittl, M., Maar, N., Polska, E., Weigert, G., Stur, M., Schmetterer, L., 2005. Choroidal hemodynamic changes during isometric exercise in patients with inactive central serous chorioretinopathy. *Investig. Ophthalmol. Vis. Sci.* *46*, 4717–4721.
- Tittl, M., Polska, E., Kircher, K., Kruger, A., Maar, N., Stur, M., Schmetterer, L., 2003.

- Topical fundus pulsation measurement in patients with active central serous chorioretinopathy. *Arch. Ophthalmol.* 121, 975–978.
- Tittl, M.K., Spaide, R.F., Wong, D., Pilotto, E., Yannuzzi, L.A., Fisher, Y.L., Freund, B., Guyer, D.R., Slakter, J.S., Sorenson, J.A., 1999. Systemic findings associated with central serous chorioretinopathy. *Am. J. Ophthalmol.* 128, 63–68.
- Torres-Soriano, M.E., Garcia-Aguirre, G., Kon-Jara, V., Ustariz-Gonzales, O., Abraham-Marin, M., Ober, M.D., Quiroz-Mercado, H., 2008. A pilot study of intravitreal bevacizumab for the treatment of central serous chorioretinopathy (case reports). *Graefes Arch. Clin. Exp. Ophthalmol.* 246, 1235–1239.
- Tsai, D.C., Chen, S.J., Huang, C.C., Chou, P., Chung, C.M., Chan, W.L., Huang, P.H., Lin, S.J., Chen, J.W., Chen, T.J., Leu, H.B., 2014. Risk of central serous chorioretinopathy in adults prescribed oral corticosteroids: a population-based study in taiwan. *Retina* 34, 1867–1874.
- Tsai, M.J., Hsieh, Y.T., 2014. Half-time photodynamic therapy for central serous chorioretinopathy. *Optom. Vis. Sci.* 91, 1140–1145.
- Tseng, C.C., Chen, S.N., 2015. Long-term efficacy of half-dose photodynamic therapy on chronic central serous chorioretinopathy. *Br. J. Ophthalmol.* 99, 1070–1077.
- Tzekov, R., Lin, T., Zhang, K.M., Jackson, B., Oyejide, A., Orilla, W., Kulkarni, A.D., Kuppermann, B.D., Wheeler, L., Burke, J., 2006. Ocular changes after photodynamic therapy. *Investig. Ophthalmol. Vis. Sci.* 47, 377–385.
- Uetani, R., Ito, Y., Oiwa, K., Ishikawa, K., Terasaki, H., 2012. Half-dose vs one-third-dose photodynamic therapy for chronic central serous chorioretinopathy. *Eye* 26, 640–649.
- Unlu, C., Erdogan, G., Aydogan, T., Sezgin Akcay, B.I., Kardes, E., Kiray, G.A., Bozkurt, T.K., 2016a. Intravitreal bevacizumab for treatment of central serous chorioretinopathy. *J. Ophthalmic Vis. Res.* 11, 61–65.
- Unlu, C., Erdogan, G., Gezginaslan, T.A., Akcay, B.I., Kardes, E., Bozkurt, T.K., 2016b. Subfoveal choroidal thickness changes after intravitreal bevacizumab therapy for central serous chorioretinopathy. *Arq. Bras. Oftalmol.* 79, 308–311.
- Urner-Bloch, U., Urner, M., Stieger, P., Galliker, N., Winterton, N., Zuber, A., Moutouh-de Parseval, L., Dummer, R., Goldinger, S.M., 2014. Transient mek inhibitor-associated retinopathy in metastatic melanoma. *Ann. Oncol.* 25, 1437–1441.
- van Dijk, E.H., Dijkman, G., Biermasz, N.R., van Haalen, F.M., Pereira, A.M., Boon, C.J., 2016. Chronic central serous chorioretinopathy as a presenting symptom of cushing syndrome. *Eur. J. Ophthalmol.* 26, 442–448.
- van Dijk, E.H., van Herpen, C.M., Marinkovic, M., Haanen, J.B., Amundson, D., Luyten, G.P., Jager, M.J., Kapiteijn, E.H., Keunen, J.E., Adamas, G., Boon, C.J., 2015. Serous retinopathy associated with mitogen-activated protein kinase inhibition (binimetinib) for metastatic cutaneous and uveal melanoma. *Ophthalmology* 122, 1907–1916.
- van Dijk, E.H.C., Dijkman, G., Boon, C.J.F., 2017a. Photodynamic therapy in chronic central serous chorioretinopathy with subretinal fluid outside the fovea. *Graefes Arch. Clin. Exp. Ophthalmol.* 255, 2029–2035.
- van Dijk, E.H.C., Dijkman, G., Theelen, T., Hoyng, C.B., Boon, C.J.F., 2018a. Short-term findings on optical coherence tomography and microperimetry in chronic central serous chorioretinopathy patients treated with half-dose photodynamic therapy. *Retin. Cases Brief Rep.* 12, 266–271.
- van Dijk, E.H.C., Fauser, S., Breukink, M.B., Blanco-Garavito, R., Groenewoud, J.M.M., Keunen, J.E.E., Peters, P.J.H., Dijkman, G., Souied, E.H., MacLaren, R.E., Querques, G., Downes, S.M., Hoyng, C.B., Boon, C.J.F., 2018b. Half-dose photodynamic therapy versus high-density subthreshold micropulse laser treatment in patients with chronic central serous chorioretinopathy: the place trial. *Ophthalmology* 125, 1547–1555.
- van Dijk, E.H.C., Schellevis, R.L., Breukink, M.B., Mohabati, D., Dijkman, G., Keunen, J.E.E., Yzer, S., den Hollander, A.I., Hoyng, C.B., de Jong, E.K., Boon, C.J.F., 2019. Familial central serous chorioretinopathy. *Retina* 39, 398–407.
- van Dijk, E.H.C., Schellevis, R.L., van Bergen, M., Breukink, M.B., Altay, L., Scholz, P., Fauser, S., Meijer, O.C., Hoyng, C.B., den Hollander, A.I., Boon, C.J.F., de Jong, E.K., 2017b. Association of a haplotype in the nr3c2 gene, encoding the mineralocorticoid receptor, with chronic central serous chorioretinopathy. *JAMA Ophthalmol* 135, 446–451.
- van Haalen, F.M., van Dijk, E.H.C., Andela, C.D., Dijkman, G., Biermasz, N.R., Pereira, A.M., Boon, C.J.F., 2018. Maladaptive personality traits, psychological morbidity and coping strategies in chronic central serous chorioretinopathy. *Acta Ophthalmol.* 97, 572–579.
- van Haalen, F.M., van Dijk, E.H.C., Dekkers, O.M., Bizino, M.B., Dijkman, G., Biermasz, N.R., Boon, C.J.F., Pereira, A.M., 2018b. Cushing's syndrome and hypothalamic-pituitary-adrenal axis hyperactivity in chronic central serous chorioretinopathy. *Front. Endocrinol.* 9, 39.
- van Rijnssen, T.J., Mohabati, D., Dijkman, G., Theelen, T., de Jong, E.K., van Dijk, E.H.C., Boon, C.J.F., 2018a. Correlation between redefined optical coherence tomography parameters and best-corrected visual acuity in non-resolving central serous chorioretinopathy treated with half-dose photodynamic therapy. *PLoS One* 13, e0202549.
- van Rijnssen, T.J., van Dijk, E.H.C., Dijkman, G., Boon, C.J.F., 2018b. Clinical characteristics of chronic central serous chorioretinopathy patients with insufficient response to reduced-settings photodynamic therapy. *Graefes Arch. Clin. Exp. Ophthalmol.* 256, 1395–1402.
- van Rijnssen, T.J., van Dijk, E.H.C., Scholz, P., Breukink, M.B., Blanco-Garavito, R., Souied, E.H., Keunen, J.E.E., MacLaren, R.E., Querques, G., Fauser, S., Downes, S.M., Hoyng, C.B., Boon, C.J.F., 2019. Focal and diffuse chronic central serous chorioretinopathy treated with half-dose photodynamic therapy or subthreshold micropulse laser. *Am. J. Ophthalmol.* <https://doi.org/10.1016/j.ajo.2019.03.025>.
- van Rijnssen, T.J., van Dijk, E.H.C., Scholz, P., Breukink, M.B., Blanco-Garavito, R., Souied, E.H., MacLaren, R.E., Querques, G., Fauser, S., Hoyng, C.B., Downes, S.M., Boon, C.J.F., 2019b. Patient characteristics of untreated chronic central serous chorioretinopathy patients with focal versus diffuse leakage. *Graefes Arch. Clin. Exp. Ophthalmol.* 257, 1419–1425.
- Vasconcelos, H., Marques, I., Santos, A.R., Melo, P., Pires, I., Figueira, J., de Abreu, J.F., Cachulo, M.L., Silva, R., 2013. Long-term chorioretinal changes after photodynamic therapy for chronic central serous chorioretinopathy. *Graefes Arch Clin Exp Ophthalmol* 251, 1697–1705. <https://doi.org/10.1007/s00417-013-2270-2>.
- Venkatesh, R., Agarwal, M., Kantha, M., 2018. Efficacy of oral rifampicin in chronic central serous chorioretinopathy. *Ther. Adv. Ophthalmol.* 10, 2515841418807130.
- Verma, L., Sinha, R., Venkatesh, P., Tewari, H.K., 2004. Comparative evaluation of diode laser versus argon laser photocoagulation in patients with central serous retinopathy: a pilot, randomized controlled trial [isrctn84128484]. *BMC Ophthalmol.* 4, 15.
- von Graefe, A., 1866. Ueber centale recidiverende retinitis. v. *Graefes Arch. Ophthal.* 12, 211–214.
- von Winning, C.H., Oosterhuis, J.A., Renger-van Dijk, A.H., Hornstra-Limburg, H., Polak, B.C., 1982. Diffuse retinal pigment epitheliopathy. *Ophthalmologica* 185, 7–14.
- Wang, M., Munch, I.C., Hasler, P.W., Prunte, C., Larsen, M., 2008. Central serous chorioretinopathy. *Acta Ophthalmol.* 86, 126–145.
- Wang, M., Sander, B., la Cour, M., Larsen, M., 2005. Clinical characteristics of subretinal deposits in central serous chorioretinopathy. *Acta Ophthalmol. Scand.* 83, 691–696.
- Wang, M., Sander, B., Lund-Andersen, H., Larsen, M., 1999. Detection of shallow detachments in central serous chorioretinopathy. *Acta Ophthalmol. Scand.* 77, 402–405.
- Wang, M.S., Sander, B., Larsen, M., 2002. Retinal atrophy in idiopathic central serous chorioretinopathy. *Am. J. Ophthalmol.* 133, 787–793.
- Wang, N.K., Fu, Y., Wang, J.P., Kang, E.Y., Wu, A.L., Tseng, Y.J., Yeh, L.K., Chen, K.J., Wu, W.C., Ho, W.J., Lai, C.C., 2017. Peripheral vascular endothelial dysfunction in central serous chorioretinopathy. *Investig. Ophthalmol. Vis. Sci.* 58, 4524–4529.
- Warrow, D.J., Hoang, Q.V., Freund, K.B., 2013. Pachychoroid pigment epitheliopathy. *Retina* 33, 1659–1672.
- Weenink, A.C., Borsje, R.A., Oosterhuis, J.A., 2001. Familial chronic central serous chorioretinopathy. *Ophthalmologica* 215, 183–187.
- Wei, S.Y., Yang, C.M., 2005. Transpupillary thermotherapy in the treatment of central serous chorioretinopathy. *Ophthalmic Surg. Lasers Imaging* 36, 412–415.
- Willcox, A., Culliford, L., Ellis, L., Rogers, C.A., Cree, A., Chakravarthy, U., Ennis, S., Behar-Cohen, F., Reeves, B.C., Sivaprasad, S., Lotery, A., 2019. Clinical efficacy of eplerenone versus placebo for central serous chorioretinopathy: study protocol for the vici randomised controlled trial. *Eye* 33, 295–303.
- Williams Jr., R.B., Lane, J.D., Kuhn, C.M., Melosh, W., White, A.D., Schanberg, S.M., 1982. Type a behavior and elevated physiological and neuroendocrine responses to cognitive tasks. *Science* 218, 483–485.
- Wolfensberger, T.J., Dmitriev, A.V., Govardovskii, V.I., 1999. Inhibition of membrane-bound carbonic anhydrase decreases subretinal pH and volume. *Doc. Ophthalmol.* 97, 261–271.
- Wong, R., Chopdar, A., Brown, M., 2004. Five to 15 year follow-up of resolved idiopathic central serous chorioretinopathy. *Eye* 18, 262–268.
- Wood, E.H., Karth, P.A., Sanislo, S.R., Moshfeghi, D.M., Palanker, D.V., 2017. Nondamaging laser therapy for treatment of central serous chorioretinopathy: what is the evidence? *Retina* 37, 1021–1033.
- Yadav, N.K., Jayadev, C., Mohan, A., Vijayan, P., Battu, R., Dabir, S., Shetty, B., Shetty, R., 2015. Subthreshold micropulse yellow laser (577 nm) in chronic central serous chorioretinopathy: safety profile and treatment outcome. *Eye* 29, 258–264 quiz 265.
- Yannuzzi, L.A., 1987. Type a behavior and central serous chorioretinopathy. *Retina* 7, 111–131.
- Yannuzzi, L.A., 2010. Central serous chorioretinopathy: a personal perspective. *Am. J. Ophthalmol.* 149, 361–363.
- Yannuzzi, L.A., Shakin, J.L., Fisher, Y.L., Altomonte, M.A., 1984. Peripheral retinal detachments and retinal pigment epithelial atrophic tracts secondary to central serous pigment epitheliopathy. *Ophthalmology* 91, 1554–1572.
- Yannuzzi, L.A., Slakter, J.S., Gross, N.E., Spaide, R.F., Costa, D., Huang, S.J., Klancnik Jr., J.M., Aizman, A., 2003. Indocyanine green angiography-guided photodynamic therapy for treatment of chronic central serous chorioretinopathy: a pilot study. *Retina* 23, 288–298.
- Yannuzzi, L.A., Sorenson, J., Spaide, R.F., Lipson, B., 1990. Idiopathic polypoidal choroidal vasculopathy (ipcv). *Retina* 10, 1–8.
- Yannuzzi, N.A., Mrejen, S., Capuano, V., Bhavsar, K.V., Querques, G., Freund, K.B., 2015. A central hypofluorescent subretinal lucency correlates with a region of focal leakage on fluorescein angiography in eyes with central serous chorioretinopathy. *Ophthalmic Surg. Lasers Imaging Retina* 46, 832–836.
- Yap, E.Y., Robertson, D.M., 1996. The long-term outcome of central serous chorioretinopathy. *Arch. Ophthalmol.* 114, 689–692.
- Yavas, G.F., Kusbeci, T., Kasikci, M., Gunay, E., Dogan, M., Unlu, M., Inan, U.U., 2014. Obstructive sleep apnea in patients with central serous chorioretinopathy. *Curr. Eye Res.* 39, 88–92.
- Yu, A.K., Merrill, K.D., Truong, S.N., Forward, K.M., Morse, L.S., Telander, D.G., 2013. The comparative histologic effects of subthreshold 532- and 810-nm diode micropulse laser on the retina. *Investig. Ophthalmol. Vis. Sci.* 54, 2216–2224.
- Yu, J., Jiang, C., Xu, G., 2014. Study of subretinal exudation and consequent changes in acute central serous chorioretinopathy by optical coherence tomography. *Am. J. Ophthalmol.* 158, 752–756 e752.
- Zakir, S.M., Shukla, M., Simi, Z.U., Ahmad, J., Sajid, M., 2009. Serum cortisol and testosterone levels in idiopathic central serous chorioretinopathy. *Indian J. Ophthalmol.* 57, 419–422.
- Zavoloka, O., Bezditko, P., Lahorzhevskaya, I., Zubkova, D., Ilyina, Y., 2016. Clinical efficiency of helicobacter pylori eradication in the treatment of patients with acute central serous chorioretinopathy. *Graefes Arch. Clin. Exp. Ophthalmol.* 254, 1737–1742.
- Zhao, M., Celerier, I., Bousquet, E., Jeanny, J.C., Jonet, L., Savoldelli, M., Offret, O., Curan, A., Farman, N., Jaisser, F., Behar-Cohen, F., 2012. Mineralocorticoid receptor

- is involved in rat and human ocular chorioretinopathy. *J. Clin. Investig.* 122, 2672–2679.
- Zhao, M., Valamanesh, F., Celerier, I., Savoldelli, M., Jonet, L., Jeanny, J.C., Jaisser, F., Farman, N., Behar-Cohen, F., 2010. The neuroretina is a novel mineralocorticoid target: aldosterone up-regulates ion and water channels in muller glial cells. *FASEB J.* 24, 3405–3415.
- Zhao, M., Zhang, F., Chen, Y., Dai, H., Qu, J., Dong, C., Kang, X., Liu, Y., Yang, L., Li, Y., Zhou, P., Pan, C.T., Zhang, L., Liu, P., Zhou, H., Jiao, X., Xiong, Y., Tian, R., Lu, Y., Yu, X., Li, X., 2015. A 50% vs 30% dose of verteporfin (photodynamic therapy) for acute central serous chorioretinopathy: one-year results of a randomized clinical trial. *JAMA Ophthalmol* 133, 333–340.
- Zhao, M.W., Zhou, P., Xiao, H.X., Lv, Y.S., Li, C.A., Liu, G.D., Li, X.X., 2009. Photodynamic therapy for acute central serous chorioretinopathy: the safe effective lowest dose of verteporfin. *Retina* 29, 1155–1161.
- Zhou, L., Chong, V., Lai, K., Huang, C., Xu, F., Gong, Y., Youlidaxi, M., Li, T., Lu, L., Jin, C., 2019. A pilot prospective study of 577-nm yellow subthreshold micropulse laser treatment with two different power settings for acute central serous chorioretinopathy. *Lasers Med. Sci.* <https://doi.org/10.1007/s10103-019-02721-8>.
- Ziemssen, F., Heimann, H., 2012. Evaluation of verteporfin pharmacokinetics—redefining the need of photosensitizers in ophthalmology. *Expert Opin. Drug Metabol. Toxicol.* 8, 1023–1041.
- Zola, M., Chatziralli, I., Menon, D., Schwartz, R., Hykin, P., Sivaprasad, S., 2018a. Evolution of fundus autofluorescence patterns over time in patients with chronic central serous chorioretinopathy. *Acta Ophthalmol.* 96, e835–e839.
- Zola, M., Daruich, A., Matet, A., Mantel, I., Behar-Cohen, F., 2018. Two-year follow-up of mineralocorticoid receptor antagonists for chronic central serous chorioretinopathy. *Br. J. Ophthalmol.* <https://doi.org/10.1136/bjophthalmol-2018-312892>.
- Zucchiatti, I., Sacconi, R., Parravano, M.C., Costanzo, E., Querques, L., Montorio, D., Bandello, F., Querques, G., 2018. Eplerenone versus observation in the treatment of acute central serous chorioretinopathy: a retrospective controlled study. *Ophthalmol. Ther.* 7, 109–118.