

# PostScript

## MATTERS ARISING

### Antiphospholipid antibodies and rheumatoid arthritis

We read with interest the letter entitled "Antiphospholipid antibodies and RA: presence of  $\beta_2$ GP1 independent aCL" by Bonnet *et al* published in the *Annals* in March 2001.<sup>1</sup> We believe that the letter needs additional clarification owing to inconsistencies in the terminology, methodology of antiphospholipid antibody (aPL) detection, and determination of positive values.

The use of the term "anticardiolipin antibodies" was somewhat misleading. The term was introduced and abbreviated as "aCL", a group of antibodies detected in many conditions, but the  $\beta_2$  glycoprotein 1 ( $\beta_2$ GP1) dependence of the aCL was not defined, even though the authors focused on  $\beta_2$ GP1 independent aCL. It is generally agreed that the term aCL, if not stated otherwise, defines the antibodies detected by the classical aCL enzyme linked immunosorbent assay (ELISA),<sup>2,3</sup>—that is, both  $\beta_2$ GP1 dependent and  $\beta_2$ GP1 independent antibodies.

There were some potential methodological errors in determining  $\beta_2$ GP1 independent aCL. It was shown that antibodies against  $\beta_2$ GP1 (anti- $\beta_2$ GP1) from patients with the antiphospholipid syndrome (APS) have the ability to bind  $\beta_2$ GP1 in complexes with cardiolipin only if the  $\beta_2$ GP1 concentration in solution is high enough. The threshold concentration of  $\beta_2$ GP1 was found to be just about

2  $\mu$ g/ml, because no binding of anti- $\beta_2$ GP1 was seen when serum samples were diluted 1:200 or more.<sup>4</sup> As the physiological concentration of  $\beta_2$ GP1 in human serum is approximately 200  $\mu$ g/ml, the threshold binding concentration is reached at a serum dilution of 1:100. In the presence of a relatively high concentration of endogenous  $\beta_2$ GP1, the statement that antibodies detected by this method are exclusively  $\beta_2$ GP1 independent is unjustified, as the sera containing high titres of anti- $\beta_2$ GP1 might have yielded positive results by the method described in the letter.

The definition of antibody units in the letter is not clear and using Harris's standards for  $\beta_2$ GP1 independent aCL is not appropriate. With the use of Harris's standards,<sup>5</sup> the units should be abbreviated as GPL (for IgG) and MPL (for IgM) as previously defined.<sup>5</sup> However, Harris's standards were designed for use in the classical aCL ELISA and were prepared by pooling serum samples from patients with APS. Therefore, they contain mainly, or predominantly,  $\beta_2$ GP1 dependent aCL.  $\beta_2$ GP1 independent aCL were not defined in those standards and they were not meant as standards for  $\beta_2$ GP1 independent assays.

The interpretation of anti- $\beta_2$ GP1 ELISA as a method to detect  $\beta_2$ GP1 dependent aCL may not be valid in all cases. It was shown that not all anti- $\beta_2$ GP1 binding  $\beta_2$ GP1 adsorbed on polystyrene high binding plates also recognise  $\beta_2$ GP1 associated with cardiolipin. We reported this binding pattern for anti- $\beta_2$ GP1 in children with atopic dermatitis,<sup>6</sup> and the same was shown also for some patients with autoimmune diseases, including APS.<sup>7</sup>

The method for purification of  $\beta_2$ GP1 was not described. Because the authors focused on patients with rheumatoid arthritis (RA), it should be ensured that immunoglobulins were specifically removed from the  $\beta_2$ GP1 preparation. If this purification step was not carried out, traces of immunoglobulins in the  $\beta_2$ GP1 preparation might have yielded positive results for sera containing high titres of rheumatoid factor (RF). In fact, all sera containing IgM anti- $\beta_2$ GP1 also had RF and the authors already suspected that this might be due to non-specific binding involving RF.

The method for determining cut off values was not explained and the number of normal human sera (NHS) included in the study as negative controls was not given. From the data presented in the letter, one may conclude that the cut off values were arbitrarily set at 20 units both for IgG and IgM isotypes of  $\beta_2$ GP1 independent aCL and for anti- $\beta_2$ GP1. We recently compared the sensitivity of anti-

$\beta_2$ GP1 ELISA and classical aCL ELISA. The results showed great differences between their sensitivities and therefore also between the cut off values calibrated by the same standards.<sup>8</sup> In addition, the authors did not report the proportion of NHS positive for each assay and the values of positive samples compared with patients with RA. Instead, they just referred to one study,<sup>9</sup> which is only one of the several published estimations of aPL in healthy subjects.

We would like to support our criticism by adding some data about aPL in our patients with RA. We randomly selected 53 serum samples from patients fulfilling the ARA criteria for RA and 53 NHS as negative controls. The samples were tested for anti- $\beta_2$ GP1,  $\beta_2$ GP1 dependent aCL, and  $\beta_2$ GP1 independent aCL. The assays were calibrated with  $\beta_2$ GP1 dependent monoclonal aCL (IgG and IgM anti- $\beta_2$ GP1 ELISA and  $\beta_2$ GP1 dependent aCL ELISA) and positive in-house standards (all IgA assays and  $\beta_2$ GP1 independent aCL). The cut off values for anti- $\beta_2$ GP1 were set as described<sup>8</sup> by calculating the mean + 2 SD of logarithms of absorbance values for NHS and the 95th centile value of 32 NHS for both  $\beta_2$ GP1 dependent and  $\beta_2$ GP1 independent aCL. For the anti- $\beta_2$ GP1 determination, we used affinity purified  $\beta_2$ GP1 adsorbed on Costar high binding plates as previously described.<sup>8</sup> The  $\beta_2$ GP1 preparation did not contain any immunoglobulins.  $\beta_2$ GP1 independent aCL were tested as described in the letter, but the sera were diluted 1:200. Serum samples were tested simultaneously for  $\beta_2$ GP1 dependent aCL on the same plate by adding  $\beta_2$ GP1 in parallel duplicate wells. The final concentration of  $\beta_2$ GP1 was 10  $\mu$ g/ml. This experimental design enabled direct comparison of binding to cardiolipin coated wells in the presence and absence of  $\beta_2$ GP1. For the final determination of  $\beta_2$ GP1 dependent binding, the values obtained in wells without  $\beta_2$ GP1 were subtracted from the values measured in wells with added  $\beta_2$ GP1. The patients' histories were evaluated for the occurrence of arterial or venous thrombosis and recurrent fetal loss. Statistical analysis was performed with the  $\chi^2$  test where appropriate.

Table 1 presents the frequency of positive sera in each group (NHS, RA, RA-RF positive, and RA-RF negative). The frequency of increased anti- $\beta_2$ GP1,  $\beta_2$ GP1 dependent aCL, and  $\beta_2$ GP1 independent aCL was higher in patients with RA than in controls, but the difference was significant only for anti- $\beta_2$ GP1. There were no differences in the frequency of

If you have a burning desire to respond to a paper published in the *Annals of the Rheumatic Diseases*, why not make use of our "rapid response" option?

Log on to our website ([www.annrheumdis.com](http://www.annrheumdis.com)), find the paper that interests you, and send your response via email by clicking on the "eLetters" option in the box at the top right hand corner.

Providing it isn't libellous or obscene, it will be posted within seven days. You can retrieve it by clicking on "read eLetters" on our homepage.

The editors will decide as before whether also to publish it in a future paper issue.

**Table 1** Frequency of anti- $\beta_2$ GP1,  $\beta_2$ GP1 dependent aCL, and  $\beta_2$ GP1 independent aCL in patients with rheumatoid arthritis (positive or negative for RF) and normal controls

No of positive samples:	Anti- $\beta_2$ GP1*				$\beta_2$ GP1 dependent aCL†				$\beta_2$ GP1 independent aCL†															
	IgG		IgM		IgA		Any Ig		IgG		IgM		IgA											
	No	%	No	%	No	%	No	%	No	%	No	%	No	%										
NHS (n=53*; n=32†)	1	2	2	4	1	2	4	8	1	3	2	6	1	3	3	9	2	6	2	6	2	6	5	16
RA (n=53)	3	6	6	11	4	8	11	21	2	4	6	11	2	4	9	17	4	8	4	8	9	17	12	23
RA - RF+ (n=36)	2	6	4	11	3	8	8	22	2	6	3	8	2	6	6	17	2	6	4	11	7	19	9	25
RA - RF- (n=17)	1	6	2	12	1	6	3	18	0	0	3	18	0	0	3	18	2	12	0	0	2	12	3	18

aCL, Anticardiolipin antibodies;  $\beta_2$ GP1,  $\beta_2$  glycoprotein I; NHS, normal human sera; RA, rheumatoid arthritis; RF, rheumatoid factor.

any type of antibodies between the RF positive and negative patients. One patient (a male, 66 years old) had a history of deep venous thrombosis and pulmonary embolism together with positive anti- $\beta_2$ GP1 and  $\beta_2$ GP1 dependent aCL of IgA isotype. Interestingly, 5/11 RA sera which showed binding to  $\beta_2$ GP1 adsorbed on a high binding plate did not recognise  $\beta_2$ GP1 associated with cardiolipin, as already reported.<sup>6,7</sup> In contrast, 3/9 RA sera binding  $\beta_2$ GP1 complexed with cardiolipin did not recognise  $\beta_2$ GP1 adsorbed on the surface of high binding plates. This phenomenon probably reflects the heterogeneous nature of anti- $\beta_2$ GP1 in RA, which may differ in fine specificity from anti- $\beta_2$ GP1 in APS.

The sera from our patients with RA exhibited an even higher frequency of  $\beta_2$ GP1 independent aCL than that reported in the letter. As expected from reported data, the presence of  $\beta_2$ GP1 independent aCL was not associated with signs of APS in our patients. We also found that the addition of  $\beta_2$ GP1 (10  $\mu$ g/ml) lowered the binding of  $\beta_2$ GP1 independent aCL by about 50%, most probably owing to the competition between  $\beta_2$ GP1 independent aCL and  $\beta_2$ GP1 for the same binding sites on cardiolipin.

In conclusion, patients with RA may have anti- $\beta_2$ GP1 and  $\beta_2$ GP1 dependent aCL, which might be associated with the signs of APS. The importance of distinguishing  $\beta_2$ GP1 independent aCL has not been fully clarified. It seems that  $\beta_2$ GP1 independent aCL do not confer an increased risk for APS in RA.

**A Ambrozic, B Bozic, M Hojnik, T Kveder, B Rozman**

Department of Rheumatology, University Medical Centre Ljubljana, Slovenia

Correspondence to: Dr A Ambrozic, Department of Rheumatology, University Medical Centre, Vodnikova 62, 1000 Ljubljana, Slovenia (SI); ales.ambrozic@mf.uni-lj.si

## References

- Bonnet C, Vergne P, Bertin P, Treves R. Antiphospholipid antibodies and RA: presence of  $\beta_2$ GP1 independent aCL. *Ann Rheum Dis* 2001;60:303-4.
- Loizou S, McCrea JD, Rudge AC, Reynolds R, Boyle CC, Harris EN. Measurement of anti-cardiolipin antibodies by an enzyme-linked immunosorbent assay (ELISA): standardisation and quantitation of results. *Clin Exp Immunol* 1985;62:738-45.
- Tincani A, Balestrieri G, Allegrì F, Cinquini M, Vianelli M, Taglietti M, et al. Overview on anticardiolipin ELISA standardization. *J Autoimmun* 2000;15:195-7.
- Koike T. Anticardiolipin antibodies and beta 2-glycoprotein I. *Clin Immunol Immunopathol* 1994;72:187-92.
- Harris EN. Special report. The second international anti-cardiolipin standardization workshop/the Kingston anti-phospholipid antibody study (KAPS) group. *Am J Clin Pathol* 1990;94:476-84.
- Ambrozic A, Kveder T, Ichikawa K, Avcin T, Matsuura E, Rozman B, et al.  $\beta_2$ -glycoprotein 1 antibodies in children with atopic dermatitis [abstract]. *J Autoimmun* 2000;15:A23.
- Cabral AR, Amigo MC, Cabiedes J, Alarcon-Segovia D. The antiphospholipid/cofactor syndromes: a primary variant with antibodies to beta 2-glycoprotein-I but no antibodies detectable in standard antiphospholipid assays. *Am J Med* 1996;101:472-81.
- Avcin T, Ambrozic A, Kuhar M, Kveder T, Rozman B. Anticardiolipin and anti- $\beta_2$ -glycoprotein 1 antibodies in sera of 61 apparently healthy children at regular preventive visits. *Rheumatology (Oxford)* 2001;40:565-73.
- Cacoub P, Musset L, Amoura Z, Guilani P, Chabre H, Lunel F, et al. Anticardiolipin,

anti-beta-glycoprotein 1, and antinucleosome antibodies in hepatitis C virus infection and mixed cryoglobulinemia. *J Rheumatol* 1997;24:2139-44.

## Authors' reply

In response to the comments of Ambrozic *et al* we would like to add some information to the data published earlier in the *Annals*.<sup>1</sup>

The term "anticardiolipin antibodies" (aCL) is classically used to designate antibodies directed against the cardiolipin antigen and detected in sera. Commonly, the dependence of aCL on  $\beta_2$  glycoprotein 1 ( $\beta_2$ GP1) is assessed by an enzyme linked immunosorbent assay (ELISA) test using exogenous  $\beta_2$ GP1 in blocking buffer (containing fetal calf sera or bovine sera). In our study, the blocking solution did not contain bovine or calf sera but only purified bovine serum albumin. So, this method was adapted to detect antibodies directed against cardiolipin antigen alone and not against the complexes of cardiolipin bound to exogenous  $\beta_2$ GP1. This method justified the terminology of  $\beta_2$ GP1 independent aCL for sera containing aCL without anti- $\beta_2$ GP1 antibodies; the absence of anti- $\beta_2$ GP1 antibodies was shown by another ELISA test specific for the detection of these antibodies. Both ELISAs were used to screen all sera.

The concentration of endogenous  $\beta_2$ GP1 contained in human serum is not significant at a 1/100 dilution (the dilution employed to screen our sera), in comparison with the 10% of calf sera added to the test as source of exogenous  $\beta_2$ GP1 in the assays used for the detection of  $\beta_2$ GP1 dependent aCL. In addition, the sera containing aCL (detected by an ELISA without addition of exogenous  $\beta_2$ GP1) did not react with the purified  $\beta_2$ GP1 in the other ELISA test specifically designed to detect anti- $\beta_2$ GP1 autoantibodies, and therefore which could detect hypothetically high titres of anti- $\beta_2$ GP1 antibodies contained in these sera.

Harris's standards were used after calibration of our positive control sera from patients with proven antiphospholipid syndrome (APS), which were used as positive controls in every microtitration plate. We used these for the detection of aCL in our previous studies employing ELISA test without bovine or calf sera.<sup>3,4</sup> The antiphospholipid antibodies, including aCL, are directed against several antigenic targets. Among them, some epitopes are located on the cardiolipin alone. These data were described by Harris when aCL were first characterised in systemic lupus erythematosus sera reacting in a VDRL test. By radioimmunoassay, he showed that antibodies contained in these sera were directed against cardiolipin contained in liposomes used as a reagent of the VDRL test.<sup>2</sup> These reagents were constituted by lipids alone without any other cofactor such as  $\beta_2$ GP1. So, Harris's standard can also be used to detect aCL directed only against phospholipid and not against the complex  $\beta_2$ GP1-cardiolipin. In addition, the use of Harris's standards seems to be better adapted to the detection of polyclonal antiphospholipid antibodies, than monoclonal human aCL used as internal controls.

The  $\beta_2$ GP1 used in our assay was provided by Stago laboratories (Asnières, France) and was purified from human sera. We used sodium dodecyl sulphate-polyacrylamide gel electrophoresis and western blotting to ensure that this purified protein was not contaminated.

For every antibody determination, aCL and anti- $\beta_2$ GP1 autoantibodies, normal levels were established from studies of a large

number of normal subjects (blood donors) as previously described.<sup>3,4</sup> In this study, 50 serum samples, provided by consenting healthy donors, were tested as controls.

Cut off values were determined as the mean and two standard deviations of the arbitrary units obtained by reference to positive and negative internal standards. For every serum, we defined the corrected optical density (OD) (that is, the mean OD obtained in three coated wells minus the OD corresponding to non-specific binding of each serum, obtained in three uncoated wells). The cut off values defined for anti- $\beta_2$ GP1 and anti-cardiolipin ELISA were 20 units in both tests. The standards for the anti- $\beta_2$ GP1 test corresponded to positive controls from patients with APS and were used according to previous studies.<sup>3,4</sup>

In contrast with the report of Ambrozic *et al*, we did not find raised levels of aCL or anti- $\beta_2$ GP1 antibodies in normal sera; the percentage of positive normal serum samples was <3%. These differences between our results and those of Ambrozic *et al* are probably associated with a differing sensitivity and specificity of the methods between the two laboratories.

**M O Jauberteau**

Department of Immunology, University of Limoges, France

**C Bonnet**

Department of Rheumatology, University of Limoges

Correspondence to: Dr C Bonnet, Department of Rheumatology, Centre Hospitalier de Limoges, 2 Avenue Martin-Luther King, 87042 Limoges cedex, France

## References

- Bonnet C, Vergne P, Bertin P, Treves R. Antiphospholipid antibodies and RA: presence of  $\beta_2$ GP1 independent aCL. *Ann Rheum Dis* 2001;60:303-4.
- Harris EN, Gharavi AE, Boey ML, Patel BM, Mackworth-Young CG, Loizou S, et al. Anticardiolipin antibodies: detection by radioimmunoassay and association with thrombosis in systemic lupus erythematosus. *Lancet* 1983;8361:1211-14.
- Liozon E, Roussel V, Roblot P, Liozon F, Preud'homme JL, Loustaud V, et al. Absence of anti- $\beta_2$  glycoprotein I in giant cell arteritis: a study of 45 biopsy-proven cases. *Br J Rheumatol* 1998;37:1129-31.
- Roussel V, Yi FH, Jauberteau MO, Couderc C, Lacombe C, Michelet V, et al. Prevalence and clinical significance of anti-phospholipid antibodies in multiple sclerosis: a study of 89 patients. *J Autoimmun* 2000;14:259-65.

## Methotrexate and postoperative complications

Grennan *et al* report the safety of continued methotrexate in the perioperative period.<sup>1</sup> Previous investigators have despaired of answering this question definitively owing to the difficulty in recruiting subjects.<sup>2</sup> It is reassuring to see that methotrexate use throughout the postoperative period does not interfere with wound healing or increase the incidence of early complications.

Despite this important finding, we believe that the results of this study should be regarded with some reservation: continuation of methotrexate throughout the perioperative period should be accompanied by significant caution. The elderly and those with renal impairment are at increased risk of methotrexate related pancytopenia.<sup>3,5</sup> Indeed, in a community based, observational study of methotrexate use in 460 patients we found the

perioperative period to be especially hazardous for patients with renal impairment and sepsis.<sup>6</sup> Two subjects developed pancytopenia under these conditions, one of whom died.

Although all consecutive patients were included in the study by Grennan *et al*, it is unclear whether Wrightington Hospital is a tertiary referral centre. Renal impairment is an important comorbidity, although no comment is made about the prevalence of this in the study group. It is important to note that this is a study of methotrexate use in elective surgery.

We suggest caution should be taken in patients with renal impairment (best assessed by creatinine clearance) and in the elderly with comorbid cardiovascular disease when approaching surgery. Sudden volume loss, bleeding, or dehydration will impair methotrexate excretion and increase the risk of bone marrow toxicity in this group. It may be prudent in those assessed as at high risk of this complication to stop methotrexate one week before the operation and restart treatment one or two weeks after the operation, depending on postoperative progress. This time period without methotrexate treatment will not alter disease control in the vast majority of patients, although after four weeks without treatment, most will have a flare of the disease.<sup>7</sup>

#### A Wluka

Department of Epidemiology and Preventive Medicine, Monash University, Australia

#### R Buchbinder

Department of Epidemiology, Cabrini Hospital, Malvern, Australia and Monash University, Australia

#### S Hall

Cabrini Medical Centre, Malvern, Australia

#### G Littlejohn

Monash Medical Centre, Clayton, Australia

Correspondence to: Dr A Wluka, Department of Epidemiology and Preventive Medicine, Monash University, Central and Eastern Clinical School, Alfred Hospital, Prahran, Victoria 3181, Australia

#### References

- Grennan DM, Gray J, Loudon J, Fear S. Methotrexate and early postoperative complications in patients with rheumatoid arthritis undergoing elective orthopedic surgery. *Ann Rheum Dis* 2001;60:214–17.
- Alarcon GS, Moreland LW, Jaffe K, Phillips RM, Bocanegra T, Russell IJ. The use of methotrexate perioperatively in patients with rheumatoid arthritis undergoing major joint replacement surgery: will we ever have consensus about its use? *J Clin Rheumatol* 1996;2:6–8.
- Howland WL. Methotrexate-associated bone marrow suppression following surgery. *Arthritis Rheum* 1988;31:1586–7.
- Buchbinder R, Hall S, Harkness A, Littlejohn G, Ryan PF. Severe bone marrow failure due to low dose methotrexate. *J Rheumatol* 1988;15:1586–8.
- Gutierrez-Urena S, Molina JF, Garcia CO, Cuellar ML, Espinoza LR. Pancytopenia secondary to methotrexate therapy in rheumatoid arthritis. *Arthritis Rheum* 1996;39:272–6.
- Wluka AE, Buchbinder R, Mylvaganam A, Hall S, Harkness A, Lewis D, *et al*. Long term community based methotrexate use in rheumatoid arthritis: 12 year follow up of 460 patients. *J Rheumatol* 2000;27:1864–71.
- Kremer JM, Rynes JM, Bartholomew LE. Severe flare of rheumatoid arthritis after discontinuation of long-term methotrexate therapy. *Am J Med* 1987;82:781–6.

#### Authors' reply

Dr Wluka draws attention to the potential hazard of methotrexate prescribing in sub-

jects with chronic renal failure and sepsis, and we would not disagree with this point. The risk of surgery is increased by any coincidental medical disease including renal failure and sepsis as well as chronic vascular disease. We noted this in our study.

The role of the doctor/rheumatologist is to ensure that any such chronic medical problems are under optimal control before elective orthopaedic surgery. Methotrexate treatment should not be withdrawn from patients with rheumatoid arthritis if the disease is well controlled before elective surgery. The comments of Dr Wluka do not invalidate this conclusion.

#### D M Grennan, J Gray

Department of Rheumatology, Wrightington Hospital NHS Trust, Hall Lane, Appley bridge, Wigan WN6 9EW, UK

## LETTERS

### Proximal myopathy and bone pain as the presenting features of coeliac disease

It is rare for coeliac disease to present only with symptoms of osteomalacia, without the classic symptoms of diarrhoea, steatorrhoea, and abdominal discomfort.<sup>1–5</sup>

A 22 year old woman presented with 18 months of a waddling gait disturbance. Hip and back x rays were normal. She experienced bone pain when being hugged, when laughing, or coughing, and had difficulty standing up from a low chair and holding her arms up to blow-dry her hair. She had extreme tiredness and thought she might have lost some weight, but there were no gastrointestinal symptoms.

On examination, she was pale and had difficulty squatting and holding her arms above her head.

Investigations showed a mild anaemia secondary to  $\beta$  thalassaemia minor and iron deficiency. Other investigations disclosed a raised alkaline phosphatase of 1375 U/l (normal 30–120 U/l), reduced red blood cell folate level of 290 nmol/l (>300 nmol/l), corrected calcium of 1.75 mmol/l (2.15–2.65 mmol/l), phosphate 1.0 mmol/l (0.8–1.4 mmol/l), 25-hydroxy vitamin D <5 nmol/l (15–110 nmol/l), and raised parathyroid hormone 53.1 pmol/l (1.0–6.5 pmol/l).

Investigations were carried out for a malabsorption syndrome. Antigliadin, antiendomysial, and antitglutaminase antibodies were strongly positive, and a small bowel biopsy showed almost total villous atrophy, confirming the diagnosis of coeliac disease.

A bone scan demonstrated increased activity throughout the skeleton, consistent with secondary hyperparathyroidism. Osteoporosis was demonstrated by dual emission x ray absorptiometry estimation of bone mineral density, with the lumbar spine measuring 0.882 g/cm<sup>2</sup> (2.65 SD below the young adult female mean) and the neck of the femur 0.633 g/cm<sup>2</sup> (2.9 SD below the mean).

Treatment involved a gluten free diet, ergocalciferol 3000 IU daily, calcium carbonate 600 mg twice a day, slow release ferrous sulphate 350 mg daily, and folic acid 5 mg daily.

Within two months her bone pain and tiredness resolved and her strength had returned to normal. Calcium was within the normal range, and alkaline phosphatase reduced to 374 U/l. Bone mineral density had increased markedly after 12 months of treatment, with the lumbar spine increasing by

37% to 1.204 g/cm<sup>2</sup> (mean level for young adult women), and the neck of the femur by 39% to 0.878 g/cm<sup>2</sup> (0.8 SD below the mean). She had also gained more than 7 kg in weight, and repeat gastroscopy and duodenal biopsy were normal.

Osteomalacia is now an uncommon disease, and even more uncommon is the presenting symptom of coeliac disease. Since its first description in 1965,<sup>1</sup> there have been several more case reports of coeliac disease presenting with bone pain, proximal myopathy, radiographic findings of pseudofractures and Looser's zones, or secondary hyperparathyroidism evident on bone scan.<sup>2–5</sup> Most patients were middle aged and responded within six months to treatment with a gluten-free diet, supplemental calcium, and vitamin D, and in some cases with the addition of bisphosphonates.<sup>3</sup> A recent case finding study of coeliac disease showed that many patients in fact present with non-gastrointestinal symptoms, of which anaemia is the most common.<sup>6</sup>

Hypocalcaemia in coeliac disease is caused by reduced gut absorption of calcium as a consequence of reduced levels of the fat soluble vitamin D. It is also due to reduced absorptive surface area secondary to villous atrophy, and calcium lost in the stools by binding to unabsorbed dietary fatty acids to form insoluble calcium soaps.<sup>7</sup>

Secondary hyperparathyroidism can develop as it did in this case, causing increased bone turnover.<sup>4</sup> Low bone mineral density is probably due to a combination of hypocalcaemia, impaired bone mineralisation, and reduced exercise because of skeletal pain and proximal weakness.<sup>4,6</sup>

Early diagnosis of coeliac disease is important because untreated patients have an increased risk of gastrointestinal lymphomas. Useful screening blood tests include determination of antigliadin and antiendomysial antibodies. They have a high sensitivity and specificity, with a negative predictive value of around 95%.<sup>6–8</sup> There is a genetic influence on the susceptibility to coeliac disease, with a 10% prevalence rate among first degree relatives. On screening our patient's relatives, one of two siblings was also found to have coeliac disease. A strong association has been found with HLA-DR3 and DR5/DR7.<sup>9</sup>

Treatment with a gluten-free diet with subsequent villous restitution on repeat biopsy has been associated with rapid gains and even normalisation of bone mineral density; the greater the degree of osteopenia, the more rapid the gain.<sup>4,10</sup> The change is due to improvement of calcium and vitamin D status, leading to remineralisation of the large volume of unmineralised osteoid matrix.<sup>4</sup> Introduction of hormone replacement therapy in women approaching the menopause, and bisphosphonates in patients with osteoporotic fractures, should also be considered.<sup>4,5</sup>

Osteomalacia presenting with muscle weakness and aches may be the only presenting features of coeliac disease. Prompt treatment and diagnosis is important because treatment with a gluten-free diet and replacement therapy including vitamin D may lead to rapid and effective recovery.<sup>4</sup>

#### M Wong, J Scally, K Watson, J Best

University of Melbourne Department of Medicine, St Vincent's Hospital, Melbourne, Victoria, Australia; wongbell@bigpond.com

#### References

- Moss AJ, Waterhouse C, Terry R. Gluten-sensitive enteropathy with osteomalacia

- but without steatorrhea. *N Engl J Med* 1965;272:825-30.
- Hajjar ET, Vincenti FV, Salti IS. Gluten induced enteropathy. Osteomalacia as its principal manifestation. *Arch Intern Med* 1974;134:565-6.
  - De Boer WA, Tytgat GN. A patient with osteomalacia as single presenting symptom of gluten-sensitive enteropathy. *J Intern Med* 1992;232:81-5.
  - McFarlane XA, Bhalla AK, Robertson DAF. Effect of a gluten free diet on osteopenia in adults with newly diagnosed coeliac disease. *Gut* 1996;39:180-4.
  - Basu RA, Elmer K, Babu A, Kelly CA. Coeliac disease can still present with osteomalacia. *Rheumatology (Oxford)* 2000;39:335-6.
  - Hin H, Bird G, Fisher P, Mahy N, Jewell D. Coeliac disease in primary care: case finding study. *BMJ* 1999;318:164-7.
  - Lindh E, Ljunghall S, Larsson K, Lavo B. Screening of antibodies against gliadin in patients with osteoporosis. *J Intern Med* 1992;231:403-6.
  - Unsworth DJ. Serological diagnosis of gluten sensitive enteropathy. *J Clin Pathol* 1996;49:704-11.
  - Sollid L, Thorsby E. HLA susceptibility genes in coeliac disease: Genetic mapping and role in pathogenesis. *Gastroenterology* 1993;105:910-22.
  - Valdimarsson T, Toss G, Ross I, Lofman O, Strom M. Bone mineral density in coeliac disease. *Scand J Gastroenterol* 1994;29:457-61.

## Plasma and peripheral blood mononuclear cells levels of Zn and Cu among Indian patients with RA

Plasma and serum levels of zinc (Zn) and copper (Cu) have been reported to be altered in patients with rheumatoid arthritis (RA).<sup>1,2</sup> Few studies have measured these levels in tissues, particularly peripheral blood mononuclear cells (PBMCs), the site for a host of immunological aberrations.<sup>3</sup> In a previous study we measured levels of Zn and Cu in plasma and PBMCs to see if they correlated with disease activity and reported reduced levels of Zn in the serum of patients with active RA.<sup>4</sup>

Patients attending the rheumatology clinic at our institute and satisfying the American College of Rheumatology (formerly American Rheumatism Association) criteria for the diagnosis of RA were studied.<sup>5</sup> Patients were categorised as either active or inactive RA. All patients classified as active RA had at least three of the following: morning stiffness for

more than 45 minutes, five swollen joints, five tender joints, and erythrocyte sedimentation rate (Westergren) more than 45 mm/1st h.<sup>6</sup> Both plasma and lysed PBMC samples were read on atomic absorption spectrophotometer (Perkin Ellmer, Norwalk, CT) at a wavelength of 213.8 nm for Zn and 324.7 nm for Cu. The atomic absorption spectrophotometer was calibrated with reference standards obtained from Sigma Chemicals Company (St Louis, MA).

Thirty nine patients (31 women) with RA had a mean (SD) age of 36.2 (8.3) years (range 18-52) and mean disease duration of 55.8 (36.6) months (range 6-168). Twenty patients had inactive and 19 patients active disease, respectively. Twenty two healthy controls (14 women), well matched for age (mean age 34.2 (6.2) years, range 20-56) with the two patient groups, were studied at the same time. Both patients and controls were of middle socioeconomic status. Table 1 shows the plasma and PBMC levels of Zn and Cu.

Our results are in agreement with earlier studies which showed that plasma Zn levels are significantly lower and plasma Cu levels significantly higher in patients with active RA.<sup>1,2</sup> Additionally, it is shown here that PBMC levels of these elements have an inverse relation with plasma levels.

With acute inflammation, the acute phase response may move Zn into the liver and the reduced plasma concentration may not be indicative of overall deficiency.<sup>7</sup> Possibly, also, PBMCs may be an additional site to which Zn is moved during inflammatory states. The average disease duration of patients with active disease was more than 54 months. In such a long process it is unclear whether chronic cytokine release, as is seen in RA, causes a shift of Zn from one compartment to another or if there is a true Zn depletion. Significantly, there was no correlation between age or duration of disease and plasma or PBMC levels of Zn.

The finding of raised Cu levels in the plasma is to be expected because of a concomitant rise of caeruloplasmin, which is an acute phase reactant.<sup>1,2</sup> The reduced levels in PBMCs may signify a movement of Cu from PBMCs to the liver where it is absorbed and attached to caeruloplasmin. Thus the findings of plasma and PBMC Cu levels may merely be a reflection of an acute phase response, and the alterations may be due to increased hepatic synthesis of caeruloplasmin.

The effect of concomitant drugs also needs to be considered. The number of patients receiving non-steroidal anti-inflammatory

and second line drugs was similar. None of the patients received corticosteroids in the preceding eight weeks.

It would be premature to speculate about a possible role for supplementation with Zn and Cu for patients with RA. From the results shown in this study, patients with inactive RA had similar levels of Cu and Zn as controls. If the diet of patients with active RA were deficient in Zn (as shown by plasma levels) it would be unlikely to contain an excess of Cu and vice versa for PBMC levels. The more plausible explanation would be that this represents a redistribution of trace elements between plasma and PBMCs, and a control of inflammation would lead to levels close to those seen in controls. Hence, further studies need to be carried out on paired samples in a cohort of patients, once when the disease is active and again when it becomes inactive. If plasma Zn levels increase and Cu levels decrease with the control of inflammation and attain the levels of controls then there would be no indication for dietary supplementation with these metals.

**A Wanchu, A Sud, P Bamberg**

Department of Internal Medicine, Post-Graduate Institute of Medical Education and Research, Chandigarh, 160012 India

**R Prasad, V Kumar**

Department of Biochemistry, Post-Graduate Institute of Medical Education and Research, Chandigarh

Correspondence to: Dr Wanchu; awanchu@glide.net.in

## References

- Whitehouse HW. Trace element supplementation for inflammatory disease. In: Dixon JS, Furst DE, eds. *Second line agents in the treatment of rheumatic diseases*. New York: Marcel Dekker, 1992:549-78.
- Zoli A, Altomonte L, Caricchio R, Galossi A, Mironi L, Ruffini MP, et al. Serum zinc and copper in active rheumatoid arthritis: correlation with interleukin 1 beta and tumor necrosis factor. *Clin Rheumatol* 1998;17:378-82.
- Honkanen VE, Lamberg-Allardi CH, Vesterinen MK, Lehto JH, Westermark TW, Metsa-Ketela TK, et al. Plasma zinc and copper concentrations in rheumatoid arthritis: influence of dietary factors and disease activity. *Am J Clin Nutr* 1991;54:1082-6.
- Wanchu A, Deodhar SD, Gill KD, Sarin S, Bamberg P, Sud A. Serum zinc levels in patients with active rheumatoid arthritis. *Journal of the Indian Rheumatism Association* 1996;4:96-9.
- Arnett FC, Edworthy YSM, Bloch DA, McShane DJ, Fries JF, Cooper NS, et al. The American Rheumatism Association revised criteria for the classification of rheumatoid arthritis. *Arthritis Rheum* 1988;31:315-24.
- Wanchu A, Deodhar SD, Sharma M, Gupta V, Bamberg P, Sud A. Elevated levels of anti-proteus antibodies in patients with active rheumatoid arthritis. *Indian J Med Res* 1997;105:39-42.
- Shenkin A. Trace elements and inflammatory response: implications for nutritional support. *Nutrition* 1995;11:110-15.

## Essential cryoglobulinaemia (type 1) in three patients characterised by Raynaud's phenomenon, arthralgia-arthritis, and skin lesions

The relevance of monoclonal gammopathy in relation to rheumatic disorders has recently been reviewed.<sup>1</sup> Monoclonal gammopathy or

**Table 1** Copper and zinc levels in plasma and PBMCs of patients with RA. Results are given as mean (SD)

	Active RA	Inactive RA	Overall RA	Controls
Plasma zinc ( $\mu\text{g/l}$ )*	687 (467)	982 (264)	824 (386)	1024 (428)
PBMC zinc ( $\mu\text{g}/10^6$ cells)†	135.2 (28.6)	108.3 (38.4)	121.4 (34.4)	98.4 (16.4)
Plasma copper ( $\mu\text{g/l}$ )‡	1646 (357)	1016 (296)	1426 (324)	946 (446)
PBMC copper ( $\mu\text{g}/10^6$ cells)§	58.0 (43.2)	86.4 (33.2)	74.3 (38.2)	104.2 (8.5)

PBMCs, peripheral blood mononuclear cells; there was no correlation between age, duration of disease, rheumatoid factor positivity, or any second line drug with plasma or PBMC levels of Zn and Cu.

\*Overall levels were significantly lower among patients than controls ( $p < 0.05$ ) and patients with active RA had lower levels than those with inactive RA ( $p < 0.05$ ); †overall levels were significantly higher among patients than controls ( $p < 0.05$ ) and patients with active RA as compared with those with inactive RA ( $p < 0.05$ ). There was overall a negative correlation between plasma and PBMC zinc levels ( $p < 0.05$ ); ‡overall, patients with RA had higher levels than controls ( $p < 0.01$ ) and those with active RA had higher levels than those with inactive disease ( $p < 0.01$ ); §overall, patients with RA had lower levels than controls ( $p < 0.01$ ) and those with active RA had lower levels than those with inactive disease ( $p < 0.01$ ). There was a negative correlation between plasma and PBMC copper levels ( $p < 0.05$ ).

paraproteins can be detected in healthy adults and in different disease entities like amyloidosis, malignant proliferative disorders,<sup>2</sup> associated with hepatitis C infections,<sup>3</sup> and rheumatic diseases.<sup>4</sup> The overall incidence of paraproteins in adults is about 1%.<sup>5</sup> This incidence is higher in people over 70 and increases with age.<sup>6</sup> When a paraprotein is detected and no underlying disease is present, the condition is referred to as a monoclonal gammopathy of undetermined significance.

Owing to their immunochemical properties, paraproteins can be precipitated by lowering the temperature below 37°C. In this way they form an essential part of the so-called cryoglobulins. When cryoglobulins are detected in the serum of a patient, this finding is usually associated with the coexistence of paraproteins. Recently, three patients with a clinical picture of a necrotising vasculitis associated with an essential cryoglobulinaemia (type 1) were admitted to our department. The causative relationship between the cryoglobulinaemia and the clinical symptoms was shown by the reduced severity of the clinical signs when paraprotein levels were decreased.

### Case reports

Patient A was a 69 year old man who, in May 1999, developed extremely painful purpura of the upper part of the third finger of his left hand. In the following days the upper part of his finger became necrotic. Angiography of his arteries showed normal vessels. Immune electrophoresis showed the presence of 8 g/l of an M component (IgG $\lambda$ ). An assay for the detection of cryoglobulinaemia was positive.

Laboratory examinations showed a normal plasma viscosity; antinuclear antibodies could not be detected and neither could rheumatoid factor. Complement components showed decreased C1q levels 46 IE/ml (normal 81–128), C3 1.3 g/l (normal 0.9–1.8), and low C4 levels 35 mg/l (normal 150–400). Virus serology was negative for cytomegalovirus, hepatitis A, B, and C. A skin biopsy of non-affected skin showed no evidence for vasculitis, but thrombus formation was detected in one artery. A diagnosis of multiple myeloma was ruled out by extensive laboratory examination.

Treatment was started with prednisone 60 mg daily and chlorambucil 8 mg daily until the M component concentration reached a plateau. During this treatment the skin lesions on his foot disappeared and his finger became necrotic. The M component decreased to 5 g/l. After almost a year of follow up he is still free of complaints.

Patient B was a 60 year old man who was admitted to our hospital in January 2000 with arthritis of the small joints and severe Raynaud's phenomenon of his ears, which affected him so severely that he could not leave his house. Furthermore, he felt short of breath when breathing cold air. Physical examination showed purpura skin lesions on both helices of his ears. A paraprotein was detected with an M component of 4 g/l. The presence of a cryoglobulinaemia was shown, which consisted exclusively of the M component (IgG $\kappa$ ). Further laboratory examination showed very low levels of the complement component C1q <15 IE/ml (normal 81–128), C3 1.42 g/l (normal 0.9–1.8), and C4 300 mg/l (normal 150–400). Virus serology was positive for cytomegalovirus and negative for hepatitis A, B, and C. Plasma viscosity was normal. No evidence for multiple myeloma and/or lymphoma was obtained. A skin biopsy of the non-affected skin showed only a slight perivascular infiltrate, and no evidence for a

necrotising vasculitis was seen. He was treated with chlorambucil 8 mg daily, which after two weeks was switched to melphalan (6 mg/m<sup>2</sup>) and prednisone (60 mg/m<sup>2</sup>) every four weeks for six months. The M component fell to 2 g/l and the severe Raynaud's phenomenon disappeared.

Patient C was a 78 year old woman who was admitted to our hospital in May 2000 with cyanosis in both feet, indicating possible arterial occlusion in both legs. Both feet were cold and very painful. Angiography showed normal vessels, which strongly suggested vasculitis of the end arterial vessels of her feet.

Laboratory examination showed a paraprotein (8 g/l) combined with a cryoglobulinaemia consisting of the monoclonal protein (IgG $\lambda$ ). Other laboratory examinations showed no abnormalities. Virus serology showed only a positive cytomegalovirus titre. She was treated with chlorambucil (8 mg/day) and prednisone (60 mg/day), which improved the necrosis of her legs. The necrosis of her right leg disappeared and on the left foot the necrosis began to demarcate to the upper part of her foot. While waiting for the complete demarcation so that an amputation could be planned, she developed a sepsis and died.

Few patients with essential cryoglobulinaemia type 1 have been reported. Until now a defined clinical syndrome could never be associated with classification of the cryoglobulins. Overall Raynaud's phenomenon and necrosis of the skin has been described as in our three patients. None of our three patients showed abnormalities on angiographic examination, which may indicate that only the small vessels are affected in the disease process.

In our patients we were able to show that the cryoglobulins were formed by the monoclonal immunoglobulin. When the serum concentration of the paraproteins was reduced, the disease symptoms in our patients improved. These cases suggest that a paraprotein found in patients with a rheumatic syndrome is not only indicative of a developing malignancy or other disease but may also be interpreted as a causative agent. We conclude that paraproteins seen in rheumatic syndromes have a role in the pathogenesis and should be treated when serious symptoms are present.

J G den Hollander

Department of Internal Medicine, Zuiderziekenhuis, Rotterdam, Amsterdam

A J G Swaak

Department of Rheumatology, Zuiderziekenhuis, Groene Hilledijk 315, 3075 EA Rotterdam, The Netherlands

Correspondence to: Dr Swaak

### References

- 1 Naschwitz JE, Rosner I, Rozenbaum M, Zuckerman E, Yeshurun D. Rheumatic syndromes: clues to occult neoplasia. *Semin Arthritis Rheum* 1999;29:43–55.
- 2 Kyle RA. Monoclonal gammopathy of undetermined significance. *Natural history in 241 Cases. Am J Med* 1978;64:814–26.
- 3 Kelly CA. Paraproteins in rheumatoid arthritis and related disorders. *Int J Clin Lab Res* 1992;21:288–91.
- 4 Hallen J. Discrete gammaglobulin (M component) in serum. Clinical study of 150 subjects without myelomatosis. *Acta Med Scand Suppl* 1966;462:1–127.
- 5 Saleun JP, Vicariot M, Deroff P, Morin JF. Monoclonal gammopathies in the adult population of Finistre, France. *J Clin Pathol* 1982;35:63–8.

6 Crawford J, Eye MK, Cohen HJ. Evaluation of monoclonal gammopathies in the "well" elderly. *Am J Med* 1982;82:39–45.

### Cryoglobulinaemic vasculitis as presenting manifestation of infective endocarditis

Seroimmunological alterations, including antibodies and/or cryoglobulins, are common in infective endocarditis (IE); however, specific autoimmune disorders, such as cryoglobulinaemic vasculitis (CV) associated with IE have seldom been described.<sup>3,5</sup> CV is related to the vascular deposition of circulating immune complexes, mainly cryoglobulins, and complement<sup>3,5</sup>; in 70–90% of patients with CV a triggering role of hepatitis C virus (HCV) has been suggested.<sup>7,8</sup> We report the case of two patients who showed a typical CV with severe neurological involvement as the presenting manifestation of underlying IE.

### Case 1

In November 1994 a 63 year old woman presented with fever, purpura, paraesthesias, and pseudoataxic gait. Her past clinical history was unremarkable except for a prosthetic implant of the left hip four years previously. Table 1 shows the main clinicoserological features. Repeated blood cultures were negative. Neurological examination showed abnormal tactile sensation in the arms and legs; mild ideomotor slowing down; shaky movements; and unsteady gait. An electrophysiological study recorded a moderate sensorimotor peripheral neuropathy, while ECG, chest x ray examination, abdominal echography, and echocardiography were normal. Cutaneous purpura biopsy disclosed a leucocytoclastic vasculitis. Truncoccephalic magnetic resonance imaging showed multiple, T<sub>2</sub> weighted high signal intensity, punctiform lesions at the white matter consistent with brain vasculitis. Thus a central and peripheral neuropathy complicating CV was established, and prednisone (50 mg) combined with cyclophosphamide (100 mg) was given daily. However, the patient's clinical status progressively worsened and, finally, she died owing to cardiorespiratory failure during the following month of treatment. Necropsy disclosed coarse endocardial vegetations on the left sided valves infected by *Kingella*.

### Case 2

In January 1999 a 75 year old woman with no risk factors for infections presented with fever, purpura, and acroparaesthesias. Table 1 shows the main clinical and laboratory features suggestive of CV. Prednisone (25 mg/day) was started, with a rapid clinical improvement. One month later, she had an exacerbation of purpura, arthralgias, acroparaesthesias, and impairment of distal muscle strength. An electrophysiological study confirmed a sensorimotor peripheral neuropathy. Thus a higher steroid dose (50 mg/day) was given. A week later fever persisted and the patient complained of precordial pain and cardiac murmurs were found. A chest x ray examination and transoesophageal echocardiography detected cardiomegaly and endocardial vegetations on the tricuspid valve; in addition, *Staphylococcus aureus* infection was shown by repeated blood cultures. Despite appropriate antibiotic treatment, the patient died one month later because of severe, refractory heart failure.

### Discussion

Our two patients show some interesting peculiarities: the unusual presentation of IE

**Table 1** Epidemiological, clinical, and seroimmunological features in two female patients with infective (bacterial) endocarditis, at the first visit

	Patient 1	Patient 2
Age (years)	63	75
Disease duration (weeks)	7	9
Purpura	Haemorrhagic papulonodular	Haemorrhagic nodular
Weakness	Severe	Mild-moderate
Arthralgias	Recurrent	Constant
Hepatopathy	Absent	Absent
Nephropathy	Absent	Absent
Neurological involvement	Peripheral + central	Peripheral
Cardiac symptoms	Absent	Absent
ESR (mm/1st h)	83	77
CRP (normal <5 mg/l)	53	41
WBC (normal 5–10 × 10 <sup>4</sup> /l)	89 000	83 600
Neutrophils (%)	87	81
Lymphocytes (%)	10	9
γ-Globulinaemia (g/l)	19.5	21.3
RF (normal <20 IU/ml)	575	157
C3 (normal 500–1200 mg/l)	930	790
C4 (normal 200–550 mg/l)	<60	100
Cryocrit, % (cryo-type)	0.5 (IgG-IgM)	2 (IgG-IgM)
Hepatitis virus markers*	Negative	Negative

\*HBsAg, anti-HBs, anti-HBc-IgM, anti-HBc; anti-HCV by ELISA and RIBA; anti-EBV IgM; anti-HIV.

as CV with severe neurological involvement; and the difficulty of making a timely diagnosis of IE by routine investigations. In both cases, the clinically prevalent CV symptoms, together with their transient favourable response to corticosteroids (case 2), further delayed the detection of IE responsible for the fatal outcome. Previous reports (Medline) show that the association of IE with “asymptomatic” cryoglobulinaemia is not uncommon,<sup>9,10</sup> but only a few studies report IE clinically presenting as CV.<sup>2,3</sup> This latter presentation can mean a misdiagnosis; moreover, steroid treatment can contribute to masking and worsening of the underlying infectious disorder.<sup>4</sup>

In our patients we can reasonably exclude the possibility that IE represented a complication of the CV. In over 300 of our patients with CV, bacterial manifestations have rarely been seen, even in subjects undergoing steroid or immunosuppressive treatments, or both. Moreover, the CV seen in our two patients had quite unusual clinical and virological characteristics: absence of HCV or other hepatotropic viruses<sup>3,8</sup>; the presence of particularly severe skin purpura; and the presence of neuropathy as important organ involvement. The peripheral neuropathy, in one case associated with central nervous system vasculitis, was the only prevalent organ manifestation seen in our patients. This is one of the most common clinical manifestations in patients with CV,<sup>3,6,11</sup> the aetiopathogenesis of which is still unclear. In a considerable number of patients with IE negative blood cultures have also been recorded,<sup>1,4</sup> often when Gram negative bacteria are involved.<sup>1</sup>

In patient 1, the lack of timely recognition of *Kingella* by repeated blood cultures was probably due to different reasons, including slow growing of the agent, low microbial charge in the blood samples, and/or inappropriate use of growth media. However, the negative cultures together with clinical symptoms suggestive for CV, in the absence of relevant features at transthoracic echocardiography at the onset, were sufficient reasonably to exclude a suspicion of IE presenting as CV.

In conclusion, CV may represent the presenting manifestation of IE, a life threatening condition for which a timely correct diagnosis

and adequate treatment are essential. In patients with CV unrelated to HCV infection and with fever unresponsive to steroids it is strongly recommended that other less common, infectious factors are excluded. IE, for example, should be excluded by repeated blood cultures and careful clinicomicrobiological evaluation, including transoesophageal echocardiography.

#### L La Civita, P Fadda, I Olivieri

Rheumatology Department of Lucania, S Carlo Hospital, Contrada Macchia Romana, 85100 Potenza, Italy

#### C Ferri

Rheumatology Unit, Department of Internal Medicine, University of Pisa, Pisa, Italy

Correspondence to: Dr Luca La Civita, Rheumatology Department of Lucania, Azienda Ospedaliera S Carlo, Contrada Macchia Romana, 85100 Potenza, Italy

#### References

- 1 **Kaye D**. Infective endocarditis. In: Fauci AS, *et al*, eds. *Harrison's principles of internal medicine*. 14th ed. New York: McGraw-Hill, 1998:785–91.
- 2 **Enzenauer RJ**, Arend WP, Emlen JW. Mixed cryoglobulinemia associated with chronic Q fever. *J Rheumatol* 1991;18:76–8.
- 3 **Agarwal A**, Clements J, Sedmak DD, Imler D, Nahman NS Jr, Orsinelli DA, *et al*. Subacute bacterial endocarditis masquerading as type III essential mixed cryoglobulinemia. *J Am Soc Nephrol* 1997;8:1971–6.
- 4 **Garcia-Porrúa C**, González-Gay MA. Bacterial infection presenting as cutaneous vasculitis in adults. *Clin Exp Rheumatol* 1999;17:471–3.
- 5 **Lampracht P**, Gause A, Gross WL. Cryoglobulinemic vasculitis. *Arthritis Rheum* 1999;42:2507–16.
- 6 **Ferri C**, La Civita L, Longombardo G, Zignego AL, Pasero G. Mixed cryoglobulinaemia: a crossroad between autoimmune and lymphoproliferative disorders. *Lupus* 1998;7:275–9.
- 7 **Ferri C**, Greco F, Longombardo G, Palla P, Marzo E, Moretti A. Hepatitis C virus antibodies in mixed cryoglobulinemia patients. *Arthritis Rheum* 1991;34:1606–10.
- 8 **Agnello V**, Chung RT, Kaplan LM. A role for hepatitis C virus infection in type II cryoglobulinemia. *N Engl J Med* 1992;327:1490–5.

- 9 **Singer DR**, Venning MC, Lockwood CM, Pusey CD. Cryoglobulinaemia: clinical features and response to treatment. *Ann Med Interne (Paris)* 1986;137:251–3.
- 10 **Blanco R**, Martinez-Taboada VM, Rodriguez-Valverde V, Garcia-Fuentes M. Cutaneous vasculitis in children and adults. Associated diseases and etiologic factors in 303 patients. *Medicine (Baltimore)* 1998;77:403–18.
- 11 **Ferri C**, La Civita L, Cirafisi C, Siciliano G, Longombardo G, Bombardieri S, *et al*. Peripheral neuropathy in mixed cryoglobulinemia: clinical and electrophysiologic investigations. *J Rheumatol* 1992;19:889–95.

#### ANCA antibodies in Graves' disease

Several drugs have been associated with antineutrophil cytoplasmic antibodies (ANCA) positivity—namely, hydralazine, penicillamine, allopurinol, and propylthiouracil.<sup>1</sup>

Although propylthiouracil is often implicated in the induction of ANCA positive vasculitis,<sup>2,3</sup> other antithyroid drugs, such as carbimazole and thiamazole, have been linked.<sup>4,5</sup> Furthermore, ANCA positivity has been described in the course of Graves' disease without vasculitis.<sup>6</sup>

This study aimed at determining the frequency and specificity of ANCA in a series of patients with Graves' disease.

We retrospectively examined 35 serum samples from patients with Graves' disease. Diagnosis of the disease was based on typical signs and symptoms of hyperthyroidism, raised serum triiodothyronine and thyroxine, very low or undetectable thyroid stimulating hormone, and increased thyroid radioactive iodine uptake. All patients had been receiving treatment with carbimazole (30–45 mg) for at least two months. None of the patients were treated with propylthiouracil or any drug affecting the immune function. ANCA antibodies were determined by indirect immunofluorescence (IIF) on ethanol fixed granulocytes, as described elsewhere.<sup>7</sup> Staining patterns were described as cANCA, when a diffuse granular cytoplasmic staining with central accentuation was seen, as pANCA, when a perinuclear pattern was observed, and as xANCA when a distinct, homogeneous, non-granular cytoplasmic staining pattern was seen. Autoantibodies against proteinase 3 and myeloperoxidase (MPO) were detected by enzyme linked immunosorbent assay (ELISA; Orgentec) as described elsewhere.<sup>8</sup> Hospital Universitari Germans Trias i Pujol is a 553 bed hospital situated on the outskirts of Barcelona. It is a referral hospital serving a population of 700 000 inhabitants. The immunology laboratory is a reference centre.

ANCA (IIF) were detected in 21 (60%) of the serum samples. The titre ranged from 1/40 to 1/2560. The immunofluorescence staining pattern was as follows: nine (26%) pANCA, seven (20%) xANCA, and five (14%) cANCA. ELISA was positive in just one case (for MPO)—in the patient with an IIF titre of 1/2560.

Our results are very similar to those of Afeltra *et al*, who reported ANCA positivity by IIF in 6/21 (29%) patients with Graves' disease.<sup>6</sup> The IIF staining pattern was aANCA in five cases and cANCA in one case. Anti-MPO antibodies were detected only in one (5%) of the patients. In our study ANCA were detected in 21 (60%) serum samples. The IIF staining patterns were more heterogeneous, but the ELISA results were similar.

Human MPO and human thyroid peroxidase (TPO) share global similarities which indicate that MPO and TPO are members of the same gene family. Therefore, it seems conceivable that MPO autoantibodies may cross react with TPO. Findings suggesting such a relationship were reported by Haapala *et al.*, who found antibodies against both TPO and MPO in 19 patients, three with vasculitis and 16 with thyroid disorders.<sup>9</sup>

There is a need to determine the aetiopathogenetic role of ANCA antibodies in Graves' disease, the precise relation between ANCA and antithyroid drugs and, lastly, the antigens which are responsible for the ANCA positivity.

ANCA positivity in Graves' disease may be attributable to either antithyroid drugs (thiamazole or propylthiouracil) or to the disease itself.

**M Gumà, A Olivé**

Rheumatology Section, Hospital Universitari Germans Trias i Pujol, Crta del Canyet s/n Badalona, 08916 Barcelona, Spain; aolive@ns.hugtip.scs.es

**M Juan**

Immunology Section, Hospital Universitari Germans Trias i Pujol

**I Salinas**

Endocrinology Section, Hospital Universitari Germans Trias i Pujol

Correspondence to: Dr A Olivé

**Acknowledgment**

This study was sponsored by a grant from the Catalan Society for Rheumatology.

**References**

- 1 Choi HK, Merkel PA, Walker AM, Niles JL. Drug-associated antineutrophil cytoplasmic antibody-positive vasculitis. *Arthritis Rheum* 2000;43:405-13.
- 2 Pillinger M, Staud R. Wegener's granulomatosis in a patients receiving propylthiouracil for Graves' disease. *Semin Arthritis Rheum* 1998;28:124-9.
- 3 Kitahara T, Hiromura K, Maezawa A, Ono K, Narahara N, Yano S, *et al.* Case of propylthiouracil-induced vasculitis associated with anti-neutrophil cytoplasmic antibody (ANCA); review of literature. *Clin Nephrol* 1997;47:336-40.
- 4 D'Cruz D, Chesser AMS, Lightowler C, Comer M, Hurst MJ, Baker LRI, *et al.* Antineutrophil cytoplasmic antibody-positive crescentic glomerulonephritis associated with anti-thyroid drug treatment. *Br J Rheumatol* 1995;34:1090-1.
- 5 Hori Y, Arizono K, Hara S, Kawai R, Hara M, Yamada A. Antineutrophil cytoplasmic autoantibody-positive crescentic glomerulonephritis associated with thiamazole therapy. *Nephron* 1996;74:734-5.
- 6 Afeltra A, Paggi A, De Rosa FG, Manfredini P, Addressi MA, Amoroso A. Antineutrophil cytoplasmic antibodies in autoimmune thyroid disorders. *Endocrinol Res* 1998;24:185-7.
- 7 Wiik A. Delineation of a standard procedure for indirect immunofluorescence detection of ANCA. *APMIS* 1989;97(suppl):12-13.
- 8 Niles JL, Pan GL, Collins AB, Shannon T, Skates S, Fienberg R, *et al.* Antigen-specific radioimmunoassay for anti-neutrophil cytoplasmic antibodies in the diagnosis of rapidly progressive glomerulonephritis. *J Am Soc Nephrol* 1991;2:27-36.
- 9 Haapala AM, Hyoty H, Soppo E, Parkkonen P, Mustonen J, Pasternack A. Cross-reactivity between antibodies to thyroid microsomal antigens and myeloperoxidase. *Adv Exp Med Biol* 1993;336:81-5.

**Lupus relapse after prostaglandin E<sub>1</sub> administration: activation of a cytokine cascade?**

A variety of abnormalities in cytokine production occur in human and murine lupus, but their specific role in lupus pathogenesis is unknown.<sup>1</sup> Recent *in vitro* studies emphasise the role of prostaglandins in the cytokine induction and modulation of the humoral immune response.<sup>2,3</sup> We present a patient with systemic lupus erythematosus (SLE) who had a relapse after prostaglandin E<sub>1</sub> (PGE<sub>1</sub>) administration, which to our knowledge has not been previously reported.

A 25 year old woman was admitted to hospital to receive treatment with IV PGE<sub>1</sub> owing to severe Raynaud's phenomenon. Fifteen years previously SLE had been diagnosed according to American Rheumatism Association (ARA) criteria, with renal biopsy proven diffuse proliferative lupus glomerulonephritis (WHO class IV). A physical examination showed only painful, violaceous, and atrophic finger pads with no signs of systemic inflammatory disease. The chest x ray films were normal and laboratory investigations showed antinuclear antibodies (ANA; titre 1/160) and hypocomplementaemia (C3 0.6 g/l, C4 0.1 g/l), with normal liver, renal, and haematological parameters. Treatment with 40 mg/12 h IV PGE<sub>1</sub> was started. On the sixth day of treatment the patient began to have chest pain, fever, dyspnoea, and pericardial friction rub. The laboratory showed anaemia, modest thrombocytopenia, and ANA 1/320, with no changes in the rest of the biochemical serum parameters. Echocardiography and chest x ray examination showed moderate pericardial and bilateral pleural effusions. PGE<sub>1</sub> was withdrawn and oral prednisone, 60 mg/day, was started with prompt improvement in the symptoms.

We investigated the possibility that PGE<sub>1</sub> mediated cytokine production might be the cause of the relapse of SLE in this patient. Intracellular expression of cytokines in the patient's T lymphocytes after specific PGE<sub>1</sub> stimuli (10 ng/ml) was determined by flow cytometry using anticytokine conjugates in combination with surface anti-CD3 (Pharmin-gen, San Diego, CA), as previously described.<sup>4</sup> The test performed eight months after the PGE<sub>1</sub> treatment showed a dramatic rise in interleukin 4 (IL4) production (table 1).

It has been suggested that cytokines have an important role in the immune dysregulation seen in lupus prone mice and in patients with SLE. Increasing evidence supports a role for T helper cell type 2 (Th2) cytokines, such as IL4, in promoting and perpetuating B cell hyperactivity and autoantibody formation.<sup>5,6</sup> A change in the proportion of Th2 cytokines

might be associated with the polyclonal B cell activation seen in SLE.<sup>7-9</sup> Restoration of Th1 and Th2 cytokines to levels similar to those seen in healthy mice results in amelioration of the clinical manifestations of an already established experimental SLE.<sup>10</sup>

On the other hand, in some studies it has been suggested that PGE<sub>1</sub> alters the Th1/Th2 balance of T cells to a dominant Th2 response.<sup>11</sup> We suggest that the rise in IL4 production induced by the PGE<sub>1</sub>, as shown *in vitro* in this patient, may be a marker of dysregulation of the Th1/Th2 profile and might have been the cause of her lupus relapse.

**M de la Torre, R Alcázar, D Sánchez de la Nieta, J Nieta, I Ferreras**

Nephrology and Services, Complejo Hospitalario Ciudad Real, Spain

**J M Urrea**

Immunology Service, Complejo Hospitalario Ciudad Real, Spain

Correspondence to: Dr M de la Torre, Servicio de Nefrología, Complejo Hospitalario de Ciudad Real, 13002 Ciudad Real, Spain; mtorref@nexo.es

**References**

- 1 Hartwell D, Levine J, Fenton M, Francis C, Leslie C, Beller D. Cytokine dysregulation and the initiation of systemic autoimmunity. *Immunol Letters* 1994;43:15-21.
- 2 Shreedar V, Giese T, Sung VW, Ullrich SE. A cytokine cascade including prostaglandin E<sub>2</sub>, IL-4, and IL-10 is responsible for UV-induced systemic immune suppression. *J Immunol* 1998;160:3783-9.
- 3 Gold KN, Weyand CM, Goronzy JJ. Modulation of helper T cell function by prostaglandins. *Arthritis Rheum* 1994;37:925-33.
- 4 Picker LJ, Singh MK, Zdraveski Z, Treer JR, Waldrop SL, Bergstresser P R, *et al.* Direct demonstration of cytokine synthesis heterogeneity among human memory/effector T cells by flow cytometry. *Blood* 1995;86:1408-19.
- 5 Via CS, Handwerker BS. B-cell and T-cell function in systemic lupus erythematosus. *Curr Opin Rheumatol* 1993;5:570-4.
- 6 Stanford L, Javid Moslehi, Joe Craft. Roles of interferon- $\gamma$  and interleukin-4 in murine lupus. *J Clin Invest* 1997;99:1936-7.
- 7 Funachi M, Ikoma S, Enomoto H, Horiuchi A. Decreased Th1-like and increased Th2-like cells in systemic lupus erythematosus. *Scand J Rheumatol* 1998;27:219-24.
- 8 Richaud-Patin Y, Alcocer-Varela J, Llorente L. High levels of Th2 cytokine gene expression in systemic lupus erythematosus. *Rev Invest Clin* 1995;47:267-72.
- 9 Horwitz DA, Gray JD, Behrendsen SC, Kubin M, Rengaraju M, Ohtsuka K, *et al.* Decreased production of interleukin-12 and other Th1-type cytokines in patients with recent-onset systemic lupus erythematosus. *Arthritis Rheum* 1998;41:838-44.

**Table 1** Intracellular cytokine production after PGE<sub>1</sub> stimulation in the patient and in an asymptomatic lupus patient who served as a control. Results are shown as the percentage of T lymphocytes with cytokine synthesis

	IL2		INF $\gamma$		IL4	
	Basal	PGE <sub>1</sub>	Basal	PGE <sub>1</sub>	Basal	PGE <sub>1</sub>
Control	1.2	1.1	0.4	0.2	1.1	0.7
Patient	1.1	0.8	1.6	1.8	0.6	10.8

IL, interleukin; INF $\gamma$ , interferon  $\gamma$ . Whole blood was incubated with or without PGE<sub>1</sub>, 10 ng/ml, for six hours in the presence of Brefeldin-A. Cells were stained with FITC-anti-CD3 and, after erythrocyte lysis and permeabilisation, with the phycoerythrin conjugated anticytokines. Samples were analysed by flow cytometry.

- 10 **Eilat E**, Dayan M, Zinger H, Mozes E. The mechanism by which a peptide based on complementarity-determining region-1 of a pathogenic anti-DNA auto-Ab ameliorates experimental systemic lupus erythematosus. *Proc Natl Acad Sci USA* 2001;98:1148–53.
- 11 **Makuno Y**, Takano M, Matsuguchi T, Nishimura H, Washizu J, Naiki Y, *et al*. Prostaglandin E(1) protects against liver injury induced by *Escherichia coli* infection via dominant Th2-like response on liver T cells in mice. *Hepatology* 1999;30:1464–72

### Osteocalcin: a marker of disease activity in ankylosing spondylitis?

In rheumatic diseases the synovial concentration of osteocalcin, which represents osteoblast activity, is inversely correlated with the extent of joint inflammation.<sup>1</sup> Synovial and serum osteocalcin correlate positively.<sup>1</sup> In ankylosing spondylitis (AS) the serum concentration of osteocalcin has been reported to be low<sup>2,3</sup> or normal.<sup>4–7</sup> Cross sectional studies have shown no significant correlation between osteocalcin serum concentration and erythrocyte sedimentation rate (ESR) or C reactive protein.<sup>3,7</sup>

To answer the question whether serum osteocalcin is a useful marker of disease activity in AS, longitudinal studies may be more sensitive and specific. For this reason changes in serum osteocalcin were correlated with changes in ESR, which is probably still the best marker of inflammation in AS.<sup>8</sup>

In 89 patients with ankylosing spondylitis (modified New York criteria; 75 male, 14 female; age 43 (11) years; disease duration 14 (9) years) venous blood was taken at the start and the end of a three week rehabilitation course consisting of physical exercise, physiotherapy, massage therapy, electrotherapy, underwater exercises, and radon treatment as prescribed by the patient's doctor. Patients were advised not to change their drug treatment. The ESR was determined according to Westergren, the result at one hour being used for calculation. Serum was frozen at –18°C until further analysis. Osteocalcin was measured in one batch with a commercially available test kit (IRMA, Biocis, Vienna; normal range according to the manufacturer 7.5–31.5 ng/ml in men, 3.7–31.7 ng/ml in women). Results are given as median (25th, 75th centile). The Mann-Whitney rank sum test and Spearman rank order correlation test were used to test significance.

Values at the first measurement were ESR 18 (8, 28) mm/1st h, serum osteocalcin 25 (20.5, 32.8) ng/ml. The osteocalcin serum concentration was within the normal range in 66 of the 89 patients, and 23 patients had increased serum concentrations. Values at the end of treatment were ESR 16 (8, 26.5) mm/1st h, osteocalcin 26.1 (18.9, 32.7) ng/ml (no significant changes). The ESR and osteocalcin at the first examination did not correlate significantly ( $r_s=0.07$ ;  $p=0.5$ ). The changes in ESR (1 (–4, 6) mm/1st h) and changes in osteocalcin (–0.5 (–2.6, 5.7) ng/ml) showed a significant correlation ( $r_s=0.28$ ;  $p<0.01$ ).

The results confirm previous findings showing no significant correlation between serum osteocalcin and ESR in cross sectional studies. Changes in osteocalcin after three weeks, however, correlated significantly with changes in ESR, but in view of the weak correlation ( $r_s=0.28$ ) the clinical relevance of serum osteocalcin determination for assessing disease activity seems limited.

### A Falkenbach

Gasteiner Heilstollen Hospital and Research Institute  
Gastein, A-5645 Bad Gastein, Austria

### M Herold

University Hospital, Innsbruck Austria

Correspondence to: Dr Falkenbach

### References

- 1 **Mattei JP**, Ferrera V, Boutsen Y, Franceschi JP, Botti D, De Boissezon C, *et al*. Serum and synovial fluid osteocalcin in rheumatic diseases. *Int J Clin Pharmacol Res* 1992;13:103–7.
- 2 **Franck H**, Keck E. Serum osteocalcin and vitamin D metabolites in patients with ankylosing spondylitis. *Ann Rheum Dis* 1993;52:343–6.
- 3 **Mitra D**, Elvins DM, Collins AJ. Biochemical markers of bone metabolism in mild ankylosing spondylitis and their relationship with bone mineral density and vertebral fractures. *J Rheumatol* 1999;26:2201–4
- 4 **Lee JS**, Schlotzhauer T, Ott SM, van Vollenhoven RF, Hunter J, Shapiro J, *et al*. Skeletal status of men with early and late ankylosing spondylitis. *Am J Med* 1997;103:233–41
- 5 **Marhofer W**, Stracke H, Masoud I, Scheja M, Graef V, Bolten W, *et al*. Evidence of impaired cartilage/bone turnover in patients with active ankylosing spondylitis. *Ann Rheum Dis* 1995;54:556–9.
- 6 **Toussiot E**, Ricard-Blum S, Dumoulin G, Cedoz JP, Wendling D. Relationship between urinary pyridinium cross-links, disease activity and disease subsets of ankylosing spondylitis. *Rheumatology (Oxford)* 1999;38:21–7.
- 7 **Yilmaz N**, Ozaslan J. Biochemical bone turnover markers in patients with ankylosing spondylitis. *Clin Rheumatol* 2000;19:92–8.
- 8 **van der Heijde D**, Calin A, Dougados M, Khan MA, van der Linden S, Bellamy N, on behalf of the ASAS Working Group. Selection of instruments in the core set for DC-ART, SMARD, physical therapy, and clinical record keeping ankylosing spondylitis. Progress report of the ASAS Working Group. *J Rheumatol* 1999;26:951–95.

### Takayasu arteritis

Takayasu arteritis is a chronic inflammatory vasculitis that occurs primarily in young women. It occurs world wide, with greatest prevalence in Asian people. It mainly affects the aorta and its major branches.<sup>1</sup> The Centres for Disease Control and Prevention have broadly defined idiopathic CD4+ T lymphocytopenia as a reproducible depletion of CD4 lymphocytes below  $0.3 \times 10^9/l$  in the absence of HIV infection or other known causes of immunodeficiency.<sup>2</sup> We report a case of Takayasu arteritis with low CD4+ T lymphopenia without evidence of HIV infection in a boy from Turkey.

A 9 year old boy was admitted with a history of dyspnoea, malaise, and cough for four

months. Before admission the patient had been prescribed treatment for pneumonia. He had no history of recurrent infection until four months before his admission. There was no parental consanguinity or any immunocompromised person in his family. Physical examination showed a temperature of 36°C, pulse rate of 140 beats/min, respiratory rate of 50/min, and a blood pressure of 110/70 mm Hg. His weight and height were below the fifth centile. He had a gallop rhythm, grade 3/6 pansystolic murmur at the 4th–5th left intercostal space and hepatomegaly. A chest x ray examination showed cardiomegaly and pulmonary oedema. The following laboratory values were obtained: haemoglobin 113 g/l, packed cell volume 0.35, leucocyte count  $8.3 \times 10^9/l$ , platelet count  $371 \times 10^9/l$ , erythrocyte sedimentation rate 71 mm/1st h. Other test findings, including serum electrolytes, blood urea nitrogen, and creatinine, were all normal. Echocardiography showed a dilated cardiomyopathy associated with severe mitral and aortic insufficiency. The patient was treated for heart failure with inotropic agents and furosemide (frusemide) and improved greatly.

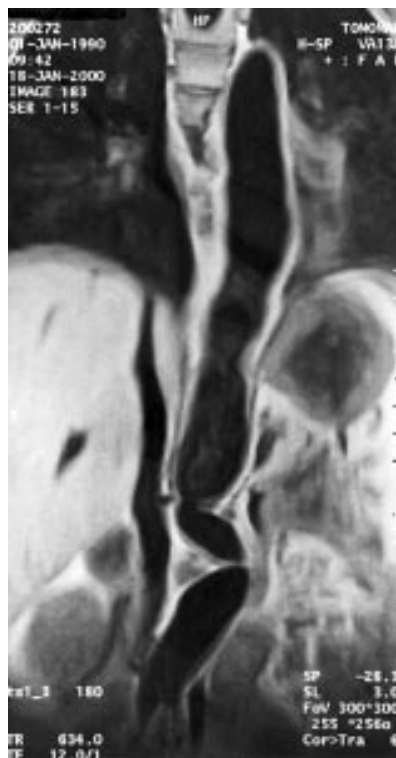
At the fourth month of follow up a physical examination showed hypertension and decreased left radial and brachial pulses. A systolic blood pressure difference greater than 10 mm Hg between both arms appeared (right arm, 140/100 mm Hg; left arm, 110/70 mm Hg). Laboratory findings showed increased blood urea nitrogen and creatinine levels. Urine analyses disclosed microscopic haematuria and mild proteinuria. Antinuclear antibodies were positive (1/20). Protein electrophoresis showed a decreased serum albumin level, hypergammaglobulinaemia, and increased  $\alpha_2$  globulin. Serum C3 and C4 levels were normal. HLA-B52 was negative. Table 1 shows the immunological findings of this patient. A lymphocyte proliferation test was not carried out on the patient. Enzyme linked immunosorbent assay (ELISA) and polymerase chain reaction tests for HIV-1 and HIV-2 were repeatedly negative, but we did not look for HTLV-1 and HTLV-2. Echocardiography disclosed dilatation of the thoracic aorta and stenosis of the left subclavian artery. Magnetic resonance imaging showed dilatation and irregular contour of the ascending and descending aorta, and narrowing of the abdominal aorta (fig 1). The patient underwent cardiac catheterisation and aortography. Angiographic examination showed narrowing of the left subclavian artery, dilatation of the thoracic aorta, and occlusion of the superior mesenteric and renal arteries. Moreover, the patient's left kidney could not be visualised. Takayasu arteritis was diagnosed and the patient received prednisone treatment (2 mg/kg/day), but he died in the initial steroid treatment period owing to severe cardiac failure.

Takayasu arteritis may be the third most common form of childhood vasculitis after

**Table 1** Immunological data of the patient

Values	Patient	Normal
Lymphocyte count ( $\times 10^9/l$ )	1.5	>2
IgG (g/l)	23.3	(8.4–19.4)
IgA (mg/l)	6290	(620–3980)
IgM (mg/l)	531	(540–3920)
CD3 ( $\times 10^9/l$ )	1.2	0.7–4.2
CD4 ( $\times 10^9/l$ )	2.0	0.3–2.0
CD8 ( $\times 10^9/l$ )	1.0	0.3–1.8
CD19 ( $\times 10^9/l$ )	0.3	0.2–1.6
CD3–/CD16+CD56 ( $\times 10^9/l$ )	0.2	0.1–0.9





**Figure 1** Magnetic resonance imaging shows dilatation and irregular contour of the descending aorta and narrowing of the abdominal aorta.

Henoch-Schönlein purpura and Kawasaki disease. Raised immunoglobulin levels and the finding of anti-aorta antibodies in the serum of some patients with this condition have suggested an immunological cause and, possibly, an autoimmune process.<sup>3</sup>

Low CD4+ T lymphocyte counts are rare in the absence of immunodeficiency, most commonly infection with HIV.<sup>2</sup> In our patient, major histocompatibility complex class II deficiency was excluded by the expression of HLA-DR on peripheral blood lymphocytes. Serological testing for HIV infection was negative and, additionally, the patient had no risk factor for transmission of HIV infection or recent immunosuppressive treatment.

All patients with idiopathic CD4+ T lymphocytopenia need to be observed prospectively and tested after their opportunistic infections, or after their first CD4+ cell count less than  $0.4 \times 10^9/l$ , to determine the natural history of their infections and lymphocytopenia. Two recent preliminary reports suggest the presence of a retrovirus in affected patients, but conclusive evidence is lacking.<sup>4-7</sup> The investigations of cases of idiopathic depletion of CD4+ T lymphocytes indicate that they probably represent various disorders, and that in some cases, low CD4+ T lymphocyte counts may reflect transient responses to infections or other conditions such as autoimmune disorders.<sup>4</sup> In patients with aorta arteritis, immunological investigations have shown a decrease in the titre of complement and phagocytic activity of neutrophil granulocytes, deep depression of T cell immunity, and hypergammaglobulinaemia.<sup>8</sup> Wiskott-Aldrich and Takayasu arteritis have been reported previously.<sup>9</sup> It is rare for patients to have both disorders and with this case report, we draw attention to this association. This case report suggests that low

CD4+ lymphopenia may cause dysgammaglobulinaemia and autoimmunity syndromes such as Takayasu arteritis.

**S Sebnem Kilic, Ö Bostan, E Çil**

Uludağ University Medical Faculty, Department of Paediatrics, Görükle, Bursa 16059, Turkey

Correspondence to: Dr Sebnem Kilic; sebnemk@uludag.edu.tr

## References

- Morales E, Pineda C, Martinez-Lavin M. Takayasu arteritis in children. *J Rheumatol* 1991;18:1081-4.
- Update: CD4+ T lymphocytopenia in persons without evident HIV infection-US. *MMWR Morb Mortal Wkly Rep* 1992;41:578-9.
- Rennebohm RM. Inflammatory 'noninfectious' cardiovascular diseases. In: Allen HD, Clark EB, Gutgesell HP, Driscoll DJ, eds. *Heart disease in infants, children, and adolescents*. 6th ed. Vol 2. Philadelphia: Lippincott Williams and Wilkins, 2001:1242-53.
- Spira TJ, Jones BM, Nicholson JKA, Lal RB, Rowe T, Mawle AC, et al. Idiopathic CD4+ T lymphocytopenia—an analysis of five patients with unexplained opportunistic infections. *N Engl J Med* 1993;328:386-92.
- Duncan RA, von Reyn CF, Alliegrò GM, Toossi Z, Sugar AM, Levitz SM. Idiopathic CD4+ T lymphocytopenia—four patients with opportunistic infections and no evidence of HIV infection. *N Engl J Med* 1993;328:393-8.
- Smith DK, Neal JJ, Holmberg SD and the centers for disease control idiopathic CD4+ T lymphocytopenia task force. Unexplained opportunistic infections and CD4+ T-lymphocytopenia without HIV infection. *N Engl J Med* 1993;328:373-9.
- Ho DD, Cao Y, Zhu T, Farthing C, Wang N, Gu G, et al. Idiopathic CD4+ T lymphocytopenia-immunodeficiency without evidence of HIV infection. *N Engl J Med* 1993;328:380-5.
- Kulinskaia LA, Sharapov NU, Bakhriddinov FS, Abdurakhmanov MM. Immunologic reactivity in patients with nonspecific aortoarteritis. *Klin Khir* 1991;7:38-40.
- Lau YL, Wong SN, Lawton WM. Takayasu's arteritis associated with Wiskott-Aldrich syndrome. *J Paediatr Child Health* 1992;28:407-9.

## Recurrent orbital pain and diplopia in a 12 year old boy

A previously healthy 12 year old boy was referred to our unit in May 2000, with a history of persistent ocular pain and recurrent diplopia. The first disease manifestation had started three years before, when the patient suddenly presented with diplopia and painful peri-orbital and eyelid oedema. Limited abduction of the right eye was present. The treating ophthalmologist, after a thorough investigation that excluded brain tumours, orbital masses, and myasthenia gravis, prescribed naproxen (20 mg/kg/day) and systemic corticosteroid treatment (prednisone 1 mg/kg/day, tapered and withdrawn after 15 days); symptoms recovered completely in two weeks. A first magnetic resonance imaging (MRI) scan of the orbit had shown first degree exophthalmus of the right eye and oedema and thickening of the right rectus lateralis muscle (fig 1). Since then the boy had many episodes of ocular pain and diplopia, lasting from two to four weeks, affecting both eyes or alternatively the right and the left, at intervals of two to three months. No sequelae were detected after each relapse.

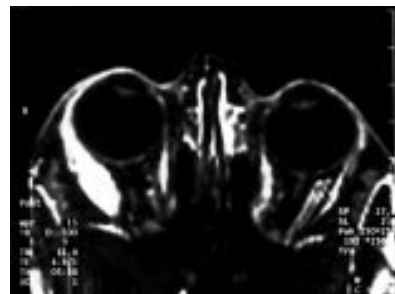
During the last relapse in October 1999, naproxen and high dose oral corticosteroid treatment (prednisone 2 mg/kg/day) were required to control the disease activity, which

subsided over a period of two months. After a short period of wellbeing, the disease flared up again, and recurrence of orbital pain and diplopia was observed when steroids were reduced to 0.5 mg/kg/day. The boy was then admitted to our unit. He appeared well, with no constitutional symptoms. Ocular examination showed mild right exophthalmus and limited motion of both eyes.

Laboratory tests including muscle enzymes (alanine aminotransferase, aspartate aminotransferase, creatine kinase, lactate dehydrogenase, aldolase) values, complement levels, and thyroid function were all within the normal range. Serological tests were negative for viral and bacterial infections, and antibodies against *Borrelia burgdorferi* were absent. Autoantibodies (antinuclear antibodies, anti-dsDNA, anticardiolipin, antiextractable nuclear antigens, perinuclear antineutrophil cytoplasmic antibodies) were undetectable. Other markers that are considered measures of disease activity in juvenile inflammatory myopathies were evaluated: factor VIII related antigen levels were raised, while neopterin levels and the number of circulating B lymphocytes (CD19 positive cells) were normal. Electrocardiography and two dimensional echocardiography excluded a concurrent myocarditis. On the basis of clinical manifestations and immunological parameters systemic lupus erythematosus (SLE), scleroderma (Scl), Crohn's disease, and thyroiditis were excluded. Orbital MRI showed significant oedema and thickening of the left extrinsic and of the right medial rectus muscles. Electromyography showed increased insertional activity, fibrillations, and positive sharp waves. Ocular myositis was diagnosed. The oral prednisone dose was raised to 30 mg/day, and rapidly tapered after improvement of signs and symptoms. In November 2000, cyclosporin (3 mg/kg/day) was introduced; no relapse of the ocular findings has been seen so far, and prednisone has been progressively reduced to the current dose of 5 mg/day.

The group of idiopathic inflammatory myopathies encompasses a variety of common and uncommon syndromes. The uncommon variants of myositis include orbital myositis, a condition that is rare in adults and even rarer in children.<sup>1-4</sup> Orbital muscle inflammation may be seen in association with other autoimmune diseases, such as SLE, Scl, giant cell myocarditis, and Crohn's disease. Primary conditions that it is important to distinguish from orbital myositis include thyroid eye disease; ocular myopathies, such as mitochondrial disorders and ocular dystrophies; and orbital pseudotumours. Cellulitis, neoplasms, arteriovenous malformations, and cavernous sinus thrombosis are also included in the differential diagnosis.

Orbital myositis implies orbital inflammation confined to one or more of the extraocular



**Figure 1** Orbital MRI (T<sub>1</sub> weighted image with contrast) that shows increased signal and size of the right rectus lateralis muscle.

muscles. MRI shows muscle oedema of the affected muscle(s), and is useful for monitoring disease activity. Non-steroidal anti-inflammatory drugs are recommended as first line treatment, but systemic steroids are required in most cases. When steroids fail to control muscle inflammation, methotrexate and cyclosporin have been used with success.<sup>5</sup> In our patient, cyclosporin was successful as a steroid sparing agent, because a rapid recurrence of symptoms had always occurred in the past when the corticosteroid dose was reduced, and at present, after six months of cyclosporin treatment, the boy is still asymptomatic and receiving a low dose of steroids.

Despite the rarity of this disorder, our case suggests that diplopia in a child requires rapid and extensive investigation that must include isolated ocular myositis in the differential diagnosis.

**F Falcini, G Simonini, M Resti**

Department of Paediatrics, University of Florence, Italy

**R Cimaz**

Paediatric Department, Via Commedia 9, 20122 Milan, Italy; Rolando.Cimaz@unimi.it

Correspondence to: Dr Cimaz

## References

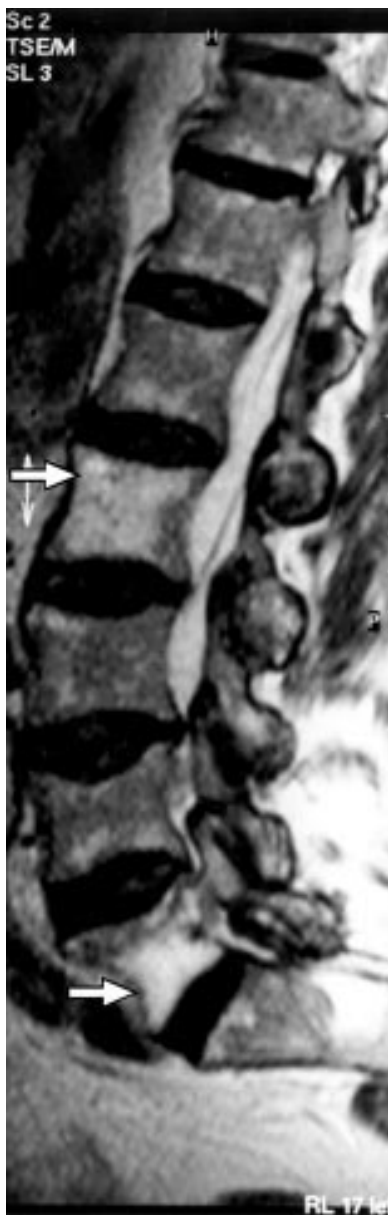- 1 **Rider LG**, Miller FW. Classification and treatment of the juvenile idiopathic inflammatory myopathies. *Rheum Dis Clin North Am* 1997;23:619–55.
- 2 **Rider LG**, Miller FW. Idiopathic inflammatory muscle disease: clinical aspects. *Ballieres Clin Rheumatol* 2000;14:37–54.
- 3 **Scott IU**, Siatkowski RM. Idiopathic orbital myositis. *Curr Opin Rheumatol* 1997;9:504–12.
- 4 **Oddis CV**. Idiopathic inflammatory diseases. In: Wortmann RL, ed. *Diseases of skeletal muscle*. New York: Lippincott Williams & Wilkins, 2000:45–85.
- 5 **Rider LG**, Targoff IN. Muscle diseases. In: Lahita RG, Chiorazzi N, Reeves WH, eds. *Textbook of the autoimmune diseases*. Philadelphia: Lippincott Williams & Wilkins, 2000:429–74.

## Sciatica or spinal lymphoma

The involvement of the central nervous system and vertebrae by low grade non-Hodgkin's lymphoma is rare.<sup>1</sup> In a previous "lesson of the month"<sup>2</sup> in this journal, it was implied that there is always a bad prognosis for patients with spinal lymphoma; however, milder cases may also occur.

A 71 year old man presented to us in January 2000 with a three month history of severe low back pain affecting mainly the left lumbar area and buttock, radiating to the outer aspect of the left thigh and calf. He did not have bladder symptoms or history of recent falls. On examination, he looked well; there was no lymphadenopathy. He had restricted back movement with tenderness of lower lumbar spinal processes. Straight leg raising test was restricted to 45° bilaterally, and produced lumbar pain. Neurological examination of the legs showed normal tone, power, and coordination. Knee jerks were reduced, ankle jerks were absent, both plantars were down going, and there was no sensory deficit.

He had a past history of epilepsy, which was controlled by phenytoin and phenobarbitone. In 1993 he was admitted with abdominal pain, splenomegaly, and pancytopenia; this was diagnosed as low grade B cell lymphoma and hypersplenism. Splenectomy was performed in 1994, his blood count returned to normal, and repeated full blood counts were



**Figure 1** Sagittal MR scan of the spine showing vertebral infiltration, being most intense in L2 and L5, which is biconcave (arrows).

stable. In 1995 the patient had a fall and severe back pain. A magnetic resonance imaging (MRI) scan showed collapse of T7 and wedging of T4, with evidence of osteoporosis but no infiltration. Treatment was started with etidronate and calcium.

Investigations showed normal serum biochemistry apart from a mild increase of alkaline phosphatase, which was 242 IU/l (normal 60–220). The total white cell count was  $24.7 \times 10^9/l$ , differential count showed neutrophils  $3.5 \times 10^9/l$  (14%), lymphocytes  $17 \times 10^9/l$  (69%), monocytes  $4.0 \times 10^9/l$  (16.0%), eosinophils  $0.2 \times 10^9/l$  (1.0%), basophils  $0.0 \times 10^9/l$  (0.0%), and occasional atypical lymphocytes were seen in blood film. The erythrocyte sedimentation rate was 4 mm/1st h, a myeloma screen was negative, and prostate specific antigen was normal.

A lumbosacral spine x ray examination showed biconcave L5 with diffuse osteopenia.

Abdominal ultrasound confirmed splenectomy, but no enlarged lymph nodes were detected. A bone isotopic scan showed increased focal activity in the upper lumbar spine and lumbosacral junction, which was compatible with osteoporosis and degenerative changes.

An MRI scan showed extensive infiltration involving vertebral bodies and appendages throughout the lumbosacral spine, being most intense at the biconcave L5; the appearance was consistent with lymphoma or myeloma (fig 1).

During his stay in hospital, the patient's pain resolved completely after treatment with non-steroidal anti-inflammatory drugs, analgesics, and physiotherapy. His haematologist started treatment of the patient with chlorambucil 10 mg/day for 10 days to be repeated every three weeks, these cycles to be continued for 12 months.

Eight months after the diagnosis of spinal lymphoma, the patient has remained well and active; his back pain is minimal.

In rheumatology, it is essential to differentiate between malignant disease and the more common causes of back pain. Our patient was in a good physical condition, which is unusual for someone with malignancy, his presentation with low back pain appeared to be a typical case of sciatica, and the pain settled down with conventional treatment. Clinically there was no evidence of recurrence of lymphoma—for example, enlarged lymph nodes, weight loss, or fever. However, because of his age at presentation and significant past history thorough investigations were mandatory.

**F Morcos**

Hope Hospital, Salford, UK

**E Smith**

Birch Hill Hospital, Rochdale, UK

Correspondence to: Dr F Morcos, Ward C2, Hope Hospital, Salford M6 8HD, UK

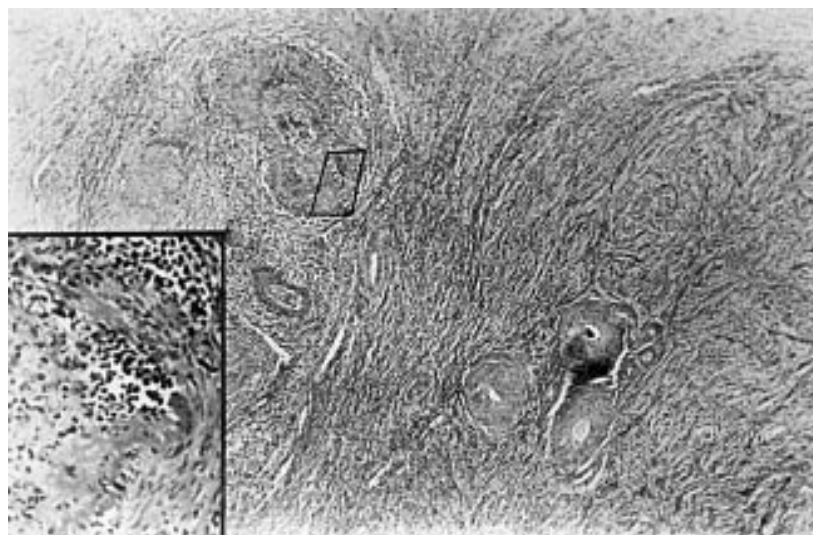
## References

- 1 **Keldsen N**, Michalski W, Bentzen SM, Hansen KB, Thorling K. Risk factors for central nervous system involvement in non-Hodgkin's lymphoma—a multivariate analysis. *Acta Oncol* 1996;35:703–8.
- 2 **Vanneville B**, Janssens A, Lemmerling M, de Valm K, Mielants H, Veys EM. Non-Hodgkin's lymphoma presenting with spinal involvement. *Ann Rheum Dis* 2000;59:12–14.

## Unusual complications in the Churg-Strauss syndrome

Although abdominal complications are occasionally reported in the Churg-Strauss syndrome (CSS), bowel perforations, cholecystitis, eosinophilic peritonitis, and oophoritis are very unusual<sup>1–8</sup> and normally resolve after immunosuppressive treatment. We report the case of a patient with CSS with these complications, which was fatal despite proper treatment.

A 64 year old woman with a 13 year history of urticaria, recurrent rhinitis, and asthma was admitted for abdominal pain. An increasing peripheral eosinophilia rising from 1% to 22% in the past five years was detected. Two years before hospital admission an extensive urticariform erythema developed. An abdominal ultrasonography performed during an asthmatic exacerbation when she had no abdominal pain disclosed a thick-walled gall bladder with no echogenic contents. An excised nasal polyp showed polypoid hyperplasia with many eosinophils.



**Figure 1** Ovarian eosinophilic infiltration is located in the hilum area, where eosinophilic arteritis is found (haematoxylin and eosin  $\times 25$ , and left lower quadrant  $\times 200$ ).

Two and six weeks later she was readmitted owing to right upper quadrant pain. The leucocyte count was  $1 \times 10^{10}/l$  with 34% eosinophils. Abdominal ultrasonography and computed tomography (CT) scan showed acalculous cholecystitis. A laparotomy disclosed a purulent peritoneal collection and enlarged inflamed gall bladder and right ovarium. A cholecystectomy and right annectomy were performed.

One month after surgery she was readmitted with severe abdominal pain, diarrhoea, and fever. The leucocyte count was  $4.49 \times 10^7/l$  with 22% eosinophils, erythrocyte sedimentation rate (ESR, Westergren) 39 mm/1st h, rheumatoid factor (RF) 765 IU/ml (normal  $< 80$ ), and total IgE 769 IU/ml (normal  $< 100$ ), and serum urea and creatinine, complement C3 and C4, antinuclear antibody and antineutrophil cytoplasmic antibody values were normal or negative. The urine contained 300 mg/l proteins and the sediment 6–8 red cells/low power field, 3–5 leucocytes, and hyalin and hyalinogranular casts. An abdomen CT scan showed moderate ascites. The ascitic fluid was serofibrinous with a protein concentration of 55 g/l, a leucocyte count of  $1.05 \times 10^9/l$  with 44% eosinophils, and negative standard and Lowenstein cultures. A diagnosis of CSS was made after reviewing the previous gallbladder and ovary histopathological specimens (fig 1) and considering the history of asthma, eosinophilia, and nasal polyposis.<sup>9</sup>

Oral methylprednisolone 60 mg/day and cyclophosphamide 100 mg/day were started, with initial clinical improvement. However, the abdominal pain recurred and the patient underwent a second laparotomy after three weeks of treatment. Peripheral blood leucocytes were  $18.1 \times 10^9/l$  with 1% eosinophils. Blood urea, creatinine, and urinary sediment were normal, the ESR fell to 15 mm/1st h and the RF to 435 IU/ml. Purulent fluid in the peritoneal cavity and two perforations in the ileal wall were found. Bowel histology showed wall ulcerations, vascular thrombosis with fibrinoid necrosis, and eosinophilic infiltrates. Granulomas were not found. *E coli* grew from the peritoneal fluid. Intravenous metronidazole and gentamicin were started. Four days later a new perforation was suspected and a third laparotomy was done, showing a perforated necrotic small bowel plaque. A broad

bowel resection was performed but the patient's evolution was complicated with high fever, ileus, and vomiting, and she died 48 hours later. A necropsy was not allowed.

Abdominal pain is reported in up to 29–59% of cases of CSS, although many times the cause is unknown. Gastric and colonic ulcers, intestinal fistulas, and small bowel perforations have been described,<sup>1–5, 8</sup> the last of these being responsible for up to 10% of the CSS deaths.<sup>3</sup> Acalculous cholecystitis, although very rare, may be the first and sometimes the unique manifestation of the CSS.<sup>3, 6</sup> Its evolution is usually torpid, and sometimes only diagnosed at necropsy. Abdominal ultrasonography should be included in the routine screening of patients with CSS.

The right oophoritis was due to vasculitis, with an eosinophilic infiltrate suggestive of CSS (fig 1). As far as we know, this is the first reported case of CSS with confirmed ovary involvement.

The ascitic fluid, rich in eosinophils, the eosinophilic infiltration of major omentum samples and the clinical evolution suggest that the peritoneal involvement was due to the CSS, an extremely rare complication of this disease. Eosinophilic peritonitis was suggested by Lanham owing to serosal involvement in the CSS,<sup>2</sup> but has only been confirmed in one case so far.<sup>8</sup>

The poor response to steroids and cyclophosphamide is striking. Despite the reduction of the peripheral eosinophilia and ESR there was widespread eosinophilic bowel infiltration and vascular fibrinoid necrosis in the laparotomy samples. The evolution of the disease in our patient was catastrophic, especially as she had only one of the five Guillevin CSS mortality associated factors—namely, gastrointestinal involvement.<sup>10</sup>

In summary, CSS abdominal complications should be promptly suspected and treated. In addition, CSS ovarian involvement, although rare, should be included in the differential diagnosis of ovary vasculitis.

**C Alvarez, V Asensi,**

**A Rodriguez-Guardado, L Casado**

Department of Internal Medicine, Covadonga Hospital-HCA, Oviedo University Medical School, Oviedo, Spain

**P Ablanado**

Department of Pathology, Covadonga Hospital-HCA

**C Alvarez-Navascués**

Department of Gastroenterology, Covadonga Hospital-HCA

Correspondence to: Dr V Asensi, Infectious Diseases Unit, Covadonga Hospital-HCA, Oviedo University Medical School, c/Celestino Villamil s/n, 33006 Oviedo, Spain; vasensi@medynet.com

## References

- 1 **Chumbley LC**, Harrison EG Jr, Dereme J. Allergic granulomatosis and angiitis (Churg-Strauss syndrome): report and analysis of 30 cases. *Mayo Clinic Proc* 1977;52:477–84.
- 2 **Lanham JG**, Elkon KB, Pusey CD, Hughes GR. Systemic vasculitis with asthma and eosinophilia: a clinical approach to the Churg-Strauss syndrome. *Medicine (Baltimore)* 1984;63:65–81.
- 3 **Guillevin L**, Cohen P, Gayraud M, Lhote F, Jarrousse B, Casassus P. Churg-Strauss syndrome. Clinical study and long-term follow-up of 96 patients. *Medicine (Baltimore)* 1999;78:26–37.
- 4 **Schoetersanitis GN**, Wakely DM, Maddox T, Wastell C. A case of Churg-Strauss vasculitis complicated by small bowel necrosis. *Postgrad Med J* 1993;69:828.
- 5 **Matsuo K**, Tomioka K, Tayima Y, Takayama K, Tamura H, Higami Y, et al. Allergic granulomatous angiitis (Churg-Strauss syndrome) with multiple intestinal fistulas. *Am J Gastroenterol* 1997;92:1937–8.
- 6 **Lasser A**, Ghofrani S. Necrotizing granulomatous vasculitis (allergic granulomatosis) of the gallbladder. *Gastroenterology* 1976;71:660–2.
- 7 **Imai H**, Nakamoto Y, Nakajima Y, Sugawara T, Miura A. Allergic granulomatosis and angiitis (Churg-Strauss syndrome) presenting as acute cholecystitis. *J Rheumatol* 1990;17:247–9.
- 8 **Modigliani R**, Muschart JM, Galan A, Clauvel JP, Piel-Desruisseaux JL. Allergic granulomatous vasculitis (Churg-Strauss syndrome). Report of a case with widespread digestive involvement. *Dig Dis Sci* 1981;26:264–70.
- 9 **Masi AT**, Gunder GG, Lie JT, Michel BA, Bloch DA, Arend WP, et al. The American College of Rheumatology 1990 criteria for the classification of Churg-Strauss syndrome (allergic granulomatosis and angiitis). *Arthritis Rheum* 1990;33:1094–100.
- 10 **Guillevin L**, Lhote F, Gayraud M, Cohen P, Larrousse B, Lortholary O, et al. Prognostic factors in polyarteritis nodosa and Churg-Strauss syndrome. *Medicine (Baltimore)* 1996;75:17–28.

## NOTICE

### Dr Barbara Ansell CBE

A service of thanksgiving for the life and work of Dr Barbara Ansell will be held on Saturday 16 February 2002 at 11 00 am at Southwark Cathedral, London Bridge. Tickets may be obtained by sending a stamped self addressed envelope to: Memorial Service, British Society for Rheumatology, 41 Eagle Street, London WC1R 4AR. All are welcome to attend.

## FORTHCOMING EVENTS

### 3rd International Congress on Autoimmunity

20–24 Feb 2002; Geneva, Switzerland  
 Contact: Professor Yehuda Shoenfeld, 3rd International Congress on Autoimmunity, PO Box 50006, Tel Aviv 61500, Israel  
 Tel: 9723 514 0018  
 Fax: 9723 517 5674  
 Email: autoim02@kenes.com

## 22nd European Workshop for Rheumatology Research

28 Feb–3 Mar 2002; Leiden, The Netherlands  
*Contact:* Professor F C Breedveld, Leiden University Medical Centre, Department of Rheumatology, PO Box 9600, 2300 RC Leiden, The Netherlands  
 Tel: +31 (0)71 526 3598  
 Fax: +31 (0)71 526 6752  
 Email: F.C.Breedveld@lumc.nl  
 Website: www.ewrr.org

## Tenth Intensive Applied Epidemiology Course for Rheumatologists

11–15 Mar 2002; Manchester, UK  
 No previous experience in epidemiology is needed. The course is residential and limited to 25 places  
*Contact:* Ms Lisa McClair, ARC Epidemiology Unit, University of Manchester, Oxford Road, Manchester M13 9PT, UK  
 Tel: +44 (0)161 275 5993  
 Fax: +44 (0)161 275 5043  
 Email: Lisa@fs1.ser.man.ac.uk

## OMERACT VI

11–14 Apr 2002; Bali  
 Includes two modules: MRI and economics; and four workshops: patients' perceptions, imaging (healing), progressive systemic sclerosis, minimally important clinical difference and osteoarthritis  
*Contact:* Conference Organisers Q2Q, 7 Swann Street, Old Isleworth, Middlesex TW7 6RJ, UK; or Peter Brooks, Faculty of Health Sciences, Level 1, Edith Cavell Building, Royal Brisbane Hospital, Herston 4029, Australia  
 Fax +44 208569 9555  
 Email: tony@q2q.co.uk or p.brooks@mailbox.uq.edu.au

## British Society for Rheumatology XIXth AGM

23–26 Apr 2002; Brighton, UK  
*Contact:* BSR, 41 Eagle Street, London WC1R 4TL, UK  
 Website: www.rheumatology.org.uk

## 4th EULAR Sonography Course

25–28 April 2002; Madrid, Spain  
 The course is entitled "Practical use of musculoskeletal ultrasonography"  
*Contact:* Esperanzo Naredo  
 Email: enaredo@eresmas.com  
 Website: www.eular.org/courses and www.sameint.it/eular

## 10th International Vasculitis and ANCA Workshop

25–28 Apr 2002; Cleveland, Ohio, USA  
*Contact:* Debora J Bork, The Cleveland Clinic Foundation, Desk A50, Center for Vasculitis Care and Research, 9500 Euclid Avenue, Cleveland, OH 44195, USA  
 Tel: 216 445 8533  
 Fax: 216 445 7569  
 Email: borkd@ccf.org  
 Website for registration and abstract submission: www.clevelandclinicmeded.com/courses/Vasculitis2002.asp

## International Congress: New Trends in Osteoarthritis

9–11 May 2002; Milan, Italy  
*Contact:* Organising Secretariat, O.I.C. S.r.l., Via Fatebenefratelli 19, 20121 Milan, Italy  
 Tel: +39 02 65 71 200  
 Fax: +39 02 65 71 270  
 Email: osteoarthritis@oic.it

## IOF World Congress on Osteoporosis

10–14 May 2002; Lisbon, Portugal  
*Contact:* IOF Secretariat, 71 cours Albert Thomas, F-69003 Lyon, France  
 Tel: +33 472 91 41 77  
 Fax: +33 472 36 90 52  
 Email: info@iofyon.org  
 Website: www.osteofound.org

## 5th European Conference on Systemic Lupus Erythematosus

26–30 May 2002; Athens, Greece  
 Chairman Professor HM Moutsopoulos  
 Secretariat: Amphitriion Congress Organising Bureau  
 Email: hmoutsop@med.uoa.gr  
 Email: congress@amphitriion.gr

## Annual European Congress of Rheumatology

12–15 June 2002; Stockholm, Sweden  
*Contact:* Fred Wyss, Executive Secretary EULAR, Witikonstrasse 15, CH-8032, Zurich, Switzerland  
 Tel: +41 1 383 9690  
 Fax: +41 1 383 9810  
 Email: eular@bluewin.ch  
 Website: www.eular.org

## 10th International Congress on Behçet's Disease

27–29 June 2002; Berlin, Germany  
 Under the auspices of the International Society for Behçet's Disease  
 Up to eight young investigator awards, each of \$500, will be awarded on the basis of abstracts submitted  
*Contact:* Professor Ch C Zouboulis, Department of Dermatology, University Medical Centre Benjamin Franklin, The Free University of Berlin, Fabeckstrasse 60–62, 14195 Berlin, Germany  
 Fax: 49 30 84456908  
 Email: zoubbere@zedat.fu-berlin.de  
 Website: www.userpages.fu-berlin.de/~zoubbere  
 ISBD website: www.behcet.ws

## 29th Scandinavian Congress of Rheumatology

15–18 Aug 2002; Tromsø, Norway  
*Contact:* Hans Nossent, Department of Rheumatology, University Hospital Tromsø, Norway  
 Tel: 47 776 27294  
 Fax: 47 776 27258  
 Email: 29scr2002@rito.no or revhan@rito.no

## Translational Research in Autoimmunity

21–22 Sep 2002; Pavia, Italy  
*Contact:* Organising secretariat: eventi S.R.L., Corso Cavour, 18/20 - 27100 Pavia, Italy  
 Email: tra@e20pr.com  
 Website: www.e20pr.com  
 Congress website: www.medicine.ucsd.edu/albani/2001 meeting

## OsteoArthritis Research Society International (OARSI) World Congress

22–25 Sep 2002; Sydney, Australia  
*Contact:* OsteoArthritis Research Society International (OARSI), 2025 M Street, NW, Suite 800, Washington DC 20036, USA  
 Tel: +1 202 367 1177  
 Fax: +1 202 367 2177  
 Email: oarsi@oarsi.org  
 Website: www.oarsi.org

## 10th International Congress on Antiphospholipid Antibodies

29 Sep–3 Oct 2002; Sicily, Italy  
 Deadline for abstracts 1 April 2002  
*Contact:* Secretariat, 10th International Congress on Antiphospholipid Antibodies, c/o Kenes International, PO Box 50006, Tel Aviv 61500, Israel  
 Tel: 972 3 5140018/9  
 Fax: 972 3 5140077 or 972 3 5172484  
 Email: aps@kenes.com  
 Website: www.kenes.com/aps

## 7th International Conference on Eicosanoids and Other Bioactive Lipids in Cancer, Inflammation and Related Diseases

14–17 Oct 2002; Nashville, Tennessee, USA  
*Contact:* Lawrence J Marnett, Biochemistry Department, Vanderbilt University, School of Medicine, Nashville TN 37232-0146, USA  
 Tel: (615) 343 7329  
 Fax: (615) 343 7534  
 Website: www.eicosanoids.science.eayne.edu

## 66th American College of Rheumatology AGM

25–29 Oct 2002; New Orleans, USA  
*Contact:* ACR, Ronald F Olejko, Director of Conferences and Meetings, 1800 Century Place, Suite 250, Atlanta, Georgia 30045-4300, USA  
 Tel: +1 404 633 3777  
 Fax: +1 404 633 1870  
 Email: acr@rheumatology.org  
 Website: www.rheumatology.org

## Third International Meeting on Social and Economic Aspects of Osteoporosis and Osteoarthritis

7–9 November, 2002; Barcelona, Spain  
*Contact:* Yolande Piette Communication, Boulevard Kleyer 108, 4000 Liège, Belgium  
 Tel: 32 4 254 12 25  
 Fax: 32 4 254 12 90  
 Email: ypc@compuserve.com

## Certifying Examination in Pediatric Rheumatology

18 Nov 2002  
*Contact:* American Board of Pediatrics, 111 Silver Cedar Court, Chapel Hill, NC 27514-1513, USA  
 Tel: 919 929 0461  
 Fax: 919 918 7114 or 919 929 9255  
 Website: www.abp.org

## Future EULAR congresses

18–21 June 2003; EULAR 2003 Lisbon, Portugal  
 9–12 June 2004; EULAR 2004 Berlin, Germany  
 8–11 June 2005; EULAR 2005 Vienna, Austria  
 21–24 June 2006; EULAR 2006 Amsterdam, The Netherlands