

This is the peer reviewed version of the following article:

Pulmonary neuroendocrine (carcinoid) tumors: European Neuroendocrine Tumor Society expert consensus and recommendations for best practice for typical and atypical pulmonary carcinoids / Caplin, Martyn E; Baudin, E.; Ferolla, P.; Filosso, Pier Luigi; Garcia Yuste, M.; Lim, E.; Oberg, K.; Pelosi, Giuliano; Perren, A.; Rossi, R. E.; Travis, W. D.; Bartsch, Detlief; Capdevila, Jaume; Costa, Frederico; Cwikla, Jaroslaw; Herder, Wouter de; Fave, Gianfranco Delle; Eriksson, Barbro; Falconi, Massimo; Ferone, Diego; Gross, David; Grossman, Ashley; Ito, Tetsuhide; Jensen, Robert; Kaltsas, Gregory; Kelestimur, Fahrettin; Kianmanesh, Reza; Knigge, Ulrich; Kos Kudla, Beata; Krenning, Eric; Mitry, Emmanuel; Nicolson, Marianne; O'Connor, Juan; O'Toole, Dermot; Pape, Ulrich Frank; Pavel, Marianne; Ramage, John; Raymond, Eric; Rindi, Guido; Rockall, Andrea; Ruzniewski, Philippe; Salazar, Ramon; Scarpa, Aldo; Sedlackova, Eva; Sundin, Anders; Toumpanakis, Christos; Vullierme, Marie Pierre; Weber, Wolfgang; Wiedenmann, Bertram; Zheng Pei, Zeng - In: ANNALS OF ONCOLOGY. - ISSN 0923-7534. - 26:8(2015), pp. 1604-1620.
Terms of use
[10.1093/annonc/mdv041]

The terms and conditions for the reuse of this version of the manuscript are specified in the publishing policy. For all terms of use and more information see the publisher's website.

21/05/2024 08:03

(Article begins on next page)

21/05/2024 08:03

Pulmonary Neuroendocrine (Carcinoid) Tumors: European Neuroendocrine Tumor Society Expert Consensus and Recommendations for Best Practice for Typical and Atypical Pulmonary Carcinoid

M.E. Caplin¹, E. Baudin², P. Ferolla³, P. Filosso⁴, M. Garcia-Yuste⁵, E. Lim⁶, K. Oberg⁷, G. Pelosi⁸, A. Perren⁹, R. Elisa Rossi^{1,10}, W.D. Travis¹¹, and the ENETS consensus conference participants*

¹Neuroendocrine Tumour Unit, Royal Free Hospital, London, UK

²Department of Nuclear Medicine, Endocrine Cancer and Interventional Radiology Institut Gustave Roussy, 39 Bis, Rue Camille Desmoulins, Villejuif Cedex, Université Paris Sud, Paris, France

³NET Center, Umbria Regional Cancer Network and, Università degli Studi di Perugia, Italy

⁴University of Torino, Department of Thoracic Surgery, Via Genova, Torino, Italy

⁵Department of Thoracic Surgery, University Clinic Hospital, Avda. Ramón y Cajal, Valladolid, Spain

⁶Imperial College and The Academic Division of Thoracic Surgery, The Royal Brompton Hospital, London, UK

⁷Endocrine Oncology Unit, Department of Medicine, University Hospital, Uppsala, Sweden

⁸Foundation IRCCS National Tumor Institute and Department of Biological Sciences and Surgery, "Luigi Sacco", Università degli Studi, Milan, Italy

⁹Institute of Pathology, University of Bern, Switzerland

¹⁰Department of Pathophysiology and Organ Transplant, Università degli Studi di Milano and Department of Gastroenterology and Endoscopy, Fondazione IRCCS Ca' Granda, Ospedale Maggiore Policlinico, Milan, Italy

¹¹Dept. of Pathology, Memorial Sloan Kettering Cancer Center, New York, NY

Corresponding author: Professor Martyn Caplin, Neuroendocrine Tumour Unit, Royal Free Hospital, London, UK. Telephone: 00 44 20 7830 2867, Facsimile: 00 44 20 7472 6728, Email: m.caplin@ucl.ac.uk

Abstract

Background and aims: Pulmonary carcinoids (PCs) are rare tumors. As there is a paucity of randomized studies, this expert consensus document represents an initiative by the European Neuroendocrine Tumor Society to provide guidance on their management. **Methods:** Bibliographical searches were performed in PubMed for the terms "pulmonary neuroendocrine tumors", "bronchial neuroendocrine tumors", "bronchial carcinoid tumors", "pulmonary carcinoid", "pulmonary typical/atypical carcinoid", "pulmonary carcinoid and diagnosis/treatment/epidemiology/prognosis". A systematic review of the relevant literature was performed, followed by expert review. **Results:** PCs are well-differentiated neuroendocrine tumors and include low- and intermediate-grade malignant tumors i.e. typical (TC) and atypical carcinoid (AC), respectively. Contrast CT scan is the diagnostic gold standard for PCs, but pathology examination is mandatory for their correct classification. Somatostatin receptor imaging may visualize nearly 80% of the primary tumors and is most sensitive for metastatic disease. Plasma chromogranin A can be raised in PCs. Surgery is the treatment of choice for PCs with the aim of removing the tumor and preserving as much lung tissue as possible. Resection of metastases should be considered whenever possible with curative intent. Somatostatin analogues (*SSAs*) are the first-line treatment for carcinoid syndrome and may be considered as first-line systemic antiproliferative treatment in unresectable PCs, particularly of low-grade TC and AC. Locoregional or radiotargeted therapies should be considered for metastatic disease. Systemic chemotherapy is used for progressive PCs although cytotoxic regimens have demonstrated limited effects with etoposide and platinum combination the most commonly used, however, temozolomide has shown most clinical benefit. **Conclusions:** PCs are complex tumors which require a multidisciplinary approach and long-term follow-up.

Key words:

pulmonary; carcinoid; bronchial; typical carcinoid; atypical carcinoid; neuroendocrine tumor

Key Message: "This is an expert consensus document under the auspices of the European Neuroendocrine Tumor Society with recommendations for best practice for management of pulmonary neuroendocrine tumors including typical and atypical carcinoid. It highlights the latest discussion on nomenclature as well as advances and utility of new diagnostic techniques. It also demonstrates the limited evidence and difficulties in determining the optimal therapeutic strategy."

Introduction:

This expert consensus document represents an initiative by the European Neuroendocrine Tumor Society (ENETS) to provide guidance on the management of pulmonary carcinoid/well differentiated neuroendocrine tumors (NETs) taking into account advances in the characterisation of NETs as well as improvements in both diagnosis and treatment. This "expert" consensus opinion arises from two meetings of the ENETS Advisory Board held in 2012 and 2013. There is a paucity of randomized studies and as the disease is relatively uncommon the level of evidence is limited compared to more common cancers. All agree that the management of such patients should involve a multidisciplinary tumor board with a specific interest/expertise in NETs. The terminology used reflects the current practice of the term "carcinoid" in pulmonary disease specifically typical and atypical carcinoid. At this stage there has not been a move to change towards the WHO terminology for gastroenteropancreatic NETs. A systematic review of the relevant literature was performed and this was followed by appraisal and expert review.

Literature search methods:

The Oxford Centre for Evidence-based Medicine's Levels of Evidence (2011) (Centre for Evidence Based Medicine. Levels of Evidence. <http://www.cebm.net/index.aspx?o¼1025>) were used to evaluate the evidence cited in this consensus document and outcomes were additionally graded according to the modified Grading of Recommendations Assessment Development and Evaluation Working Group 2007 (<http://www.gradeworkinggroup.org/>).

Bibliographical searches were performed in PubMed for the terms "pulmonary neuroendocrine tumors", "bronchial neuroendocrine tumors", "bronchial carcinoid tumors", "pulmonary carcinoid", "pulmonary typical carcinoid", "pulmonary atypical carcinoid", "pulmonary carcinoid and diagnosis", "pulmonary carcinoid and treatment", "pulmonary carcinoid and epidemiology", "pulmonary carcinoid and prognosis". For each term the search was performed without any filter in first instance, thereafter applying filters for publication type [Randomized controlled trials (RCT), Case

Reports] and using the Mesh Terms "Case-control Studies" and "cohort studies". No language restriction was applied.

Literature search results

For the term "pulmonary neuroendocrine tumors", we found 11302 articles in total, 2669 case reports, 1028 cohort studies, 580 case-control studies and 36 RCT. For the term "bronchial neuroendocrine tumors", we found 1834 articles in total, 761 case reports, 233 cohort studies, 124 case-control studies, whilst no RCT were available. For the term "bronchial carcinoid tumors", we found 1611 articles in total, 661 case reports, 224 cohort studies, 119 case-control studies, whilst no RCT were available. For the term "pulmonary carcinoid", we found 3080 articles in total, 1027 case reports, 454 cohort studies, 274 case-control studies, and 5 RCT. For the term "pulmonary typical carcinoid", we found 575 articles in total, 135 case reports, 131 cohort studies, 85 case-control studies, and 1 RCT. For the term "pulmonary atypical carcinoid", we found 576 articles in total, 137 case reports, 123 cohort studies, 87 case-control studies, whilst no RCT were available. For the terms "pulmonary carcinoid and diagnosis", we found 2554 articles in total, 895 case reports, 421 cohort studies, 257 case-control studies, and 4 RCT. For the terms "pulmonary carcinoid and treatment", we found 1420 articles in total, 539 case reports, 331 cohort studies, 185 case-control studies, and 3 RCT. For the terms "pulmonary carcinoid and epidemiology", we found 339 articles in total, 17 case reports, 158 cohort studies, 109 case-control studies, and 1 RCT. Finally, for the terms "pulmonary carcinoid and prognosis", we found 192 articles in total, 7 case reports, 96 cohort studies, 70 case-control studies, whilst no RCT were available.

We excluded *in vitro* and animal studies and prioritised meta-analyses, systematic reviews and randomized controlled trials where available. We finally identified a total of 178 pertinent articles with the strongest level of evidence. In more detail, we considered 54 articles for "Epidemiology paragraph", 36 articles for "Pathology paragraph", 35 articles for "Diagnosis paragraph", 17 articles for "Surgery paragraph", and 36 articles for "Medical therapy paragraph".

TERMINOLOGY ISSUE

The term neuroendocrine (NE) neoplasm encompasses the whole spectrum of lung tumors characterized by NE morphology and differentiation (1, 2), including well differentiated and poorly differentiated tumors. The historical term carcinoid, either typical (TC) or atypical (AC) for the subgroups of well differentiated NET, is preferable over other proposed alternative names derived from the concept of either tumor grading (3-5), tumor extension (localized vs. metastatic) (6)REF? or tumor behavior (7, 8). This is because TC and AC are identified as unique clinico-pathological traits that separate it clearly from the remaining (poorly differentiated) NET which include the high grade large cell neuroendocrine carcinoma (LCNEC) and small cell lung carcinoma (SCLC) (2). In the following text, the terms pulmonary carcinoid (PC) and pulmonary NET will be used.

EPIDEMIOLOGY

Pulmonary carcinoids (PCs) are rare tumors with an age-adjusted incidence rate ranging from 0.2 to 2/100,000 population/year in both US and European countries (9-23). There has been an increasing prevalence over the last 30 years, about 6% per year, regardless of confounding demographic factors, such as age, gender, race, and stage distribution (16, 24). This tendency of PCs to increase over time is likely due to improved awareness (25, 26) and increased use of special immunohistochemistry stains (14, 16, 21, 27). PCs prevail slightly in women over men, in whites over blacks or other ethnicities including Hispanic and Asian people (10-14, 16, 18-23, 28-31). They occur in the fourth to sixth decades of life, with a younger mean age (45 years) for TC and one decade later for AC (20, 30-33). PCs are the most common primary lung neoplasm in children (34, 35) and late adolescents (35-38), with TC prevailing by far over AC.

The prevalence of pulmonary NETs compared to the main subtypes of lung cancer has remained relatively unchanged except for small cell carcinoma (SCLC), which has shown decreasing incidence, at least in men (10), probably due to major changes in smoking habits (27). Currently, PCs account for 1-2% of all invasive lung malignancies, roughly corresponding to one fourth to one third of all well-differentiated NETs throughout the body. The large majority of poorly

differentiated NE carcinomas (NECs), accounting for about 90%, develop in the lung (16, 17, 20, 39, 40) likely due to their strong association with smoking.

The majority of PC patients develop in never or current light smokers (31, 41-45), although more AC patients are current or former smokers than TC patients (11, 30, 41, 44). In contrast, SCLC and large cell neuroendocrine carcinoma (LCNEC) are associated with heavy smokers (2). PCs may also develop in patients with a previous history of cancer (especially skin, urogenital and respiratory tract) (30), although the frequency of these tumors in the population may account for this association and PC may be detected due to increased surveillance. PCs are usually sporadic lesions however rare familial cases have been reported (46, 47). Up to 5% of patients with Multiple Endocrine Neoplasia type 1 (MEN-1) harbor PCs, usually TC with a smaller number of AC (22, 48-51). Clinical evolution of these familial tumors is generally favorable, but life-threatening tumors are also on record (46).

The ratio between TC and AC is about 8-10:1, so AC is the most uncommon of the lung NETs (2, 27-29, 52), even though some recent studies have described a relative excess of AC diagnoses (17, 20, 30). Due to inconsistency in AC reporting or coding, data from cancer registries are not generally reliable for information about TC versus AC including data from the National Cancer Institute (NCI) Surveillance, Epidemiology, and End Results (SEER) program because peer review of the histological slides is not possible (53).

The decreased survival of PCs observed over the last 30 years is likely due to an increased recognition of AC over TC (27). This distribution is closely in keeping with the current histological classification, as TC are metastatic in up to 15% of cases, usually to regional lymph nodes, with a median time to recurrence of 4 years, whereas AC are regionally or distantly metastatic in up to one half of tumors with a median time to recurrence of 1.8 years. However for both TC and AC recurrence may not occur until many years later hence the need for long term surveillance (2, 18, 21, 54).

PCs are also detected in lung cancer screening low-dose computed tomography (CT) trials, especially at the baseline with a prevalence of TC over AC (25, 26). On annual repeat controls, AC

tends to prevail probably because of its inherent greater malignant potential (25).

PATHOLOGY

Classification.

PCs are classified according to the widely agreed WHO 2004 scheme (2), i.e. TC and AC. The term of carcinoid has been maintained during all WHO classifications published since 1967, even though the diagnostic criteria separating TC from AC was only introduced in the 1999 WHO classification and subsequently maintained in the 2004 WHO classification (2, 55). Many other classification schemes and terminologies have been proposed over time, either introducing a concept of tumor grading, (3-5, 56) applying different thresholds to current diagnostic criteria (7, 57) or generalizing the taxonomy used in gastroenteropancreatic (GEP) NETs (6, 58, 59). These different proposals have not gained general acceptance yet because of the lack of clear clinical evidence for significant advantages over the current WHO classification. The recent proposal of tumor grading based on a combination of KI-67 labeling index, mitotic rate and necrosis may be of clinical importance if it can be validated (56).

PCs are tumors with NE morphology and differentiation, which are deemed to derive from, or differentiate toward, the mature NE cells of the pulmonary diffuse NE system (60-62). They encompass low (TC) to intermediate (AC) malignant lesions, which do not have any causative relationship or common genetic/epidemiologic/clinic traits with SCLC and LCNEC (2, 63). In particular, PCs as a whole are well-differentiated tumors as opposed to SCLC and LCNEC, with TC sharing some homologies with Grade 1 NETs and AC some homologies with Grade 2 NETs of the GEP tract. SCLC and LCNEC widely correspond to the Grade 3 NEC category of GEP tract (2, 64).

TC has fewer than 2 mitoses/2 mm² and absence of necrosis and AC has 2-10 mitoses/2 mm² and/or foci of punctate necrosis. SCLC and LCNEC have more than 10 mitoses/2 mm² (usually greater than 50/2 mm²) and extensive geographic necrosis (2, 55, 65). Mitotic count should be performed in hotspot areas. A report that immunohistochemistry (IHC) methods may be useful to highlight mitotic figures needs further confirmation (66). Diagnostic criteria regarding the

assessment of cell features (dimension of tumor cells, prominence of nucleoli and chromatin pattern) are used to better classify poorly differentiated NECs (SCLC and LCNEC), whereas they do not serve to distinguish TC and AC. Molecular studies have shown differences between TC and AC and high grade neuroendocrine carcinomas (67). There are limitations regarding reproducibility in differences of counting mitosis / area. Since the difference of one mitoses (e.g. from 10 to 11) makes an arbitrary difference in diagnostic category from AC to LCNEC further studies are mandatory.

Combined tumors have been described for both SCLC and LCNEC (2), whereas the association of PC with conventional NSCLC is extremely rare.

Grading system.

Grading of NE lung tumors is inherently present in the current classification scheme (2). Considerable clinical and epidemiologic data exist to validate this grading system resulting in a pathologic four-tier and clinical three-tier spectrum of NE-differentiated tumors characterized by aggressiveness: TC are low-grade malignant; AC intermediate-grade malignant; and LCNEC and SCLC are high-grade malignant NETs (2-5). SCLC is so common to the lung to make it a distinctive entity with its own epidemiologic, genetic, clinical and pathologic traits. However, establishing a grading system in lung NETs independent of histology could be clinically useful, although the criteria for grading lung NET may be different from those used for GEP NETs (68). Such a grading system could include Ki-67, mitotic rate and necrosis as recently proposed, however there is significant need for further validation studies (56).

Ki-67 immunoreactivity.

Ki-67 antigen IHC (the product of *MKI67* gene mapping to 10q26.2 gene involved in cell proliferation), which is generally performed by using the clone Mib-1 and mostly expressed as labeling index (percentage of positive tumor cells or labeling index), has value in distinguishing PCs from high-grade NET in small crushed biopsies (69). However, Ki-67 expression does not

reliably separate TC from AC, much less SCLC from LCNEC, better than the existing 2004 WHO histological criteria (2). Ki-67 may play a role in predicting prognosis on resected specimens of PCs, however more data are needed to determine the utility in lung NETs (56, 68, 70-72) as opposed to GEP NETs where Ki-67 labeling index is an integral part of the current grading system (1, 73-75). Consensus regarding the optimal methods to adopt for assessing Ki-67 labeling index (digital image analysis, manual counting, eyeball estimation, number of cells) is still lacking (75), even though some studies pointed to consider manual counting of at least 2000 cells in hot spot histological fields (52, 71, 72, 76, 77). A high overall agreement of manual Ki-67 labeling index evaluation and an automated assessment method upon scanned slides has recently substantiated the value, reproducibility and ease of Ki-67 labeling index upon manual mitotic counting (56, 78).

Tumor staging.

Tumor staging of PCs is recommended according to *Union Internationale Contre le Cancer* /American Joint Committee on Cancer (UICC/AJCC) 7th ed. TNM system (53, 73), although it will be necessary to refine descriptive categories according to tumor size, multicentricity or other components of T, N, and M factors to be meaningful also in PCs [International Association for the Study of Lung Cancer (IASLC) Lung Cancer Perspective Staging Project]. Resection margins should be indicated, measuring the distance from the tumor edge to guarantee radical excision on surgical specimens (79). Long-term studies, however, are needed to assess the risk and rate of relapse for R1 resection. Most cases of multiple carcinoids are synchronous primaries rather than intrapulmonary metastases, particularly in the setting of Diffuse Idiopathic NeuroEndocrine Cell Hyperplasia (DIPNECH) (53).

Other pathology information.

The occurrence of NE cell hyperplasia in the surrounding lung tissue should be accurately

documented (2). This may require representative sampling of the non-neoplastic lung surrounding resected carcinoid tumors. Most cases of NE hyperplasia represent an incidental finding in the non-neoplastic lung tissue adjacent to approximately 25% of excised carcinoid tumors (80). It is defined by the growth of NE cells proliferating in single cells and clusters within the bronchial epithelium. Nodular NE cell proliferations measuring less than 0.5 cm are termed "tumorlets" and they typically show no mitoses, no necrosis and a low Ki-67 labeling index (2) but may be detected on CT scan as sub-centimeter multiple lung nodules. Incidental NE cell hyperplasia is relatively common, but DIPNECH is extremely rare and is characterized by widespread NE cell hyperplasia and tumorlets. It is regarded as a pre-invasive lesion associated with some risk of developing TC or AC, which can be multiple (51, 81-84). In DIPNECH a high resolution CT scan with an expiration study may show not only multiple nodules due to the tumorlets and carcinoid tumors, but it may show ground glass attenuation, bronchiectasis and air trapping due to small airway obstruction (85).

Immunohistochemistry (IHC) demonstration of few selected markers [chromogranin A, synaptophysin and/or CD56, cytokeratins and thyroid transcription factor-1 (TTF1)] may help to confirm NE and epithelial differentiation especially in limited diagnostic material (2). These immunostains do not distinguish TC from AC, even though the latter may present with more irregular distribution of NE markers. TTF1 is more commonly found in peripheral PC and cytokeratins may assist in the diagnostic recognition of pulmonary paraganglioma (2). The separation of PC from poorly differentiated NET, especially in limited diagnostic material, may be reliably made exploiting Ki-67 labeling index (68). Immunostains for CDX-2, Islet1, TTF1 or specific hormones and biogenic amines might be used to separate pulmonary NET from lung metastases of well differentiated NET of other organs usually GEP in origin (86, 87). Breast or prostate cancer may exhibit NE differentiation, which may lead to diagnostic confusion with PC, when they are metastatic to the lung but can be reliably diagnosed by additional immunohistochemical assessment (88, 89). Histological variants of PCs (spindle cell, oncocytic, and melanocytic) may

impact on differential diagnosis, but do not have clinical relevance. No molecular tests should currently be routinely performed in PCs samples. If clinically needed, somatostatin receptors (SSTR) can be examined (90).

Small biopsy and/or cytology samples.

A correct diagnosis in small biopsies and/or cytology samples requires careful attention to morphologic and IHC features. TC and AC cannot be distinguished in biopsy and cytology, while AC may be suspected if mitoses or necrosis are present. If a low proliferation activity is seen by Ki-67 labeling index, this may be helpful to exclude high-grade NECs even in small biopsy specimens (69). Likewise, Ki-67 antigen IHC can be effectively used in cytology preparations to avoid misdiagnosis of poorly differentiated NET (69), whereas this procedure is not reliable for distinguishing TC from AC on conventional smears. Immunostains for pan-endocrine markers to confirm the NE nature of tumor cells are useful in limited diagnostic material, whether biopsy or cytology. Cytokeratins (pool AE1/AE3) may be negative in up to 25% of PCs, but are consistently positive in SCLC and LCNEC.

PATHOLOGY RECOMMENDATIONS FOR THE BEST PRACTICE

- Pathology is the gold standard in the assessment of any pulmonary NET diagnosis. Problem cases may benefit from review by expert pathologists (*Level of Evidence 3; Grade of recommendation B*).

- Current standard for classification and nomenclature is the 2004 WHO classification. Relevant information also derives from the UICC/AJCC 7th edition TNM staging. Other classifications are not recommended (*Level of Evidence 3; Grade of recommendation B*).

- Pathology report on pulmonary NETs should be shared by the multidisciplinary team along with oncologists, radiologists, nuclear medicine physicians, surgeons, pneumologists and endocrinologists, where pathologists contribute to the clinical decision-making process (*Level of*

Evidence 5; Grade of recommendation C).

- PCs as a whole are well-differentiated NETs as opposed to poorly differentiated SCLC and LCNEC, and include low-grade malignant tumors, i.e. TC, and intermediate-grade malignant tumors, i.e. AC. TC is closest to the G1 GEP NETs and AC is closest to the G2 GEP NETs. SCLC and LCNEC generally correspond to the NEC category of gastrointestinal tract according to the current WHO classification. Diagnostic criteria, however, still rely primarily on histology (*Level of Evidence 3; Grade of recommendation B*).

- Separation of TC from AC requires a surgical specimen. TC and AC cannot be reliably distinguished from each other in small biopsy and cytology (*Level of Evidence 3; Grade of recommendation C*).

- Mitotic count, necrosis and Ki-67 labeling index should be indicated in the pathology reports of surgical specimens or biopsy samples for at least two reasons: a) mitoses and necrosis are part of the classification criteria and permit cross-study comparisons; b) since the mitotic rate and Ki-67 proliferation index impact on survival even within AC (*Level of Evidence 3; Grade of recommendation C*).

- There are at least four major issues regarding Ki-67 labeling index assessment in NE lung tumors: a) Ki-67 is useful in biopsy for distinguishing TC and AC from SCLC cytology (*Level of Evidence 4; Grade of recommendation C*); b) Ki-67 does not reliably distinguish TC from AC in any material (*Level of Evidence 4; Grade of recommendation C*); c) Ki-67 has been shown to predict prognosis of TC and AC (*Level of Evidence 4; Grade of recommendation C*); d) The optimal procedure for performing Ki-67 ICH and the criteria for performing the relevant labeling index (digital image analysis, manual counting, eyeball evaluation, hotspot areas vs. randomly selected field vs. entire tumor area, number of cells) remains to be settled (*Level of Evidence 4/5; Grade of recommendation C*).

- A few NE immunomarkers (chromogranin A, synaptophysin and/or CD56/NCAM) may be used to confirm NE nature of tumors especially in biopsy/cytology specimens or surgical specimens, if needed. In case of metastatic PC presentation, positive TTF1 staining is suggestive

of a lung or thyroid origin (*Level of Evidence 3; Grade of recommendation C*).

- NE cell hyperplasia, tumorlets, DIPNECH and multiple tumors should be carefully documented and most often pertain to PCs. DIPNECH is a pre-invasive lesion able to progress to TC or AC. Histological evaluation may provide information to decide if multiple PCs are intrapulmonary seeding or multiple primaries, as an association with NE cell hyperplasia, tumorlets or DIPNECH favors multiple NET (*Level of Evidence 4; Grade of recommendation C*).

- No proof has been provided that different histological tumor cell features may have clinical significance, although they may seriously impact differential diagnosis. Cell atypia or pleomorphism is not useful to classify PCs (*Level of Evidence 4; Grade of recommendation C*).

- No molecular tests should currently be routinely performed in PCs, unless specifically required by study protocols (*Level of Evidence 4; Grade of recommendation C*).

DIAGNOSIS

PCs are traditionally subdivided into central and peripheral on the basis of their origin in respect of the bronchial tree however, they can occur throughout the lung parenchyma. Respiratory symptoms are generally present only in central forms whilst peripheral forms are generally discovered as an incidental finding in the course of radiological procedure performed for other reasons. The most frequent respiratory symptoms are recurrent chest infections, cough, hemoptysis, chest pain, dyspnea and wheezing. In rare cases hormonal hypersecretion reveals the underlying tumor.

There are some difficulties in the generation of recommendations for imaging and surgery for PC because many patients present with a "lung mass" rather than a preoperative diagnosis of a PC, thus preoperative workup and imaging needs to be pragmatic and add value to justify any additional cost and delay to definitive surgical treatment.

Needless to say all patients should be discussed within a multidisciplinary tumour board with a specialist interest in PCs in order to establish the most appropriate management for patients.

Biochemical assessment

The baseline tests should be limited to renal function, calcium, glucose and plasma chromogranin A measurements (91-93). In syndromic patients specific markers are measured, e.g. 24 hour urine 5-hydroxyindoleacetic acid measurement in carcinoid syndrome (94-96). Carcinoid syndrome is found in 2-5% of PC most often when liver metastases are present. Cushing's syndrome is found in 1-6% of patients and measurements recommended include serum cortisol, 24 hour urine free cortisol and adrenocorticotrophic hormone (ACTH). Up to 40% of patients presenting with ectopic Cushings are found to have a PC. Acromegaly due to ectopic growth-hormone-releasing hormone (GHRH) or insulin-like growth factor 1 (IGF-1) is a rare association and serum growth-hormone (GH), GHRH and IGF-1 can be measured when clinically indicated. Extremely rarely ectopic insulin secretion may be associated in patients presenting with recurrent hypoglycemic episodes. The syndrome of inappropriate antidiuretic hormone (ADH) secretion is found in 5% of patients with SCLC and rarely in PC (94, 96, 97).

MEN1 associated forms

PC may be rarely associated with MEN1 syndrome (<5% of patients) and should not be confused with a metastatic spread or a second cancer. MEN-1 is investigated by family history, clinical examination and minimal laboratory screening including ionized calcium, intact parathyroid hormone (PTH) and prolactin (98). If the familial history is suggestive of a MEN1

syndrome or a second MEN1 feature is present e.g. hyperparathyroidism, screening for MEN1 mutational analysis should be performed (96, 99).

Radiological imaging at diagnosis

More than 40% of the cases may be incidentally detectable on a standard chest x-ray (100). The gold standard is contrast CT scan. A standard lung CT acquisition technique is used. A delay of about 20 seconds between the injection of contrast and images acquisition is required to obtain a good contrast enhancement of mediastinal structures. In patients in whom contrast is contraindicated high resolution CT may be used (81, 94, 95, 101, 102).

The CT imaging features of a PC is often non-specific and may have similar appearances to adenocarcinoma or an epidermoid lung carcinoma. The most common appearance is a round or ovoid shape peripheral lung nodule with smooth or lobular margins (101). PCs however are often highly vascular and typically enhance following intravenous contrast administration (102). They tend to grow very slowly when compared to other types of lung cancer.

In central forms, PCs are most often associated with indirect signs of obstruction on CT such as atelectasis, air trapping, obstructive pneumonitis or rarely, bronchiectasis or lung abscess.

For DIPNECH, high resolution CT with an expiration study is useful as it shows mosaic attenuation or air trapping in addition to multiple nodules due to the tumorlets and carcinoid tumors.

TNM Staging

Patients should be staged according to the UICC 7th TNM classification. Both conventional and scintigraphic imaging are used to stage PC patients. N2 staging does not represent an absolute contraindication for surgery due to the indolent course of a significant number of patients.

Controversy exists on the optimum mode of preoperative staging in the mediastinum. This is because of the lack of information and consensus on surgery for patients with mediastinal lymph node involvement, for example in a recent survey by the European Society of Thoracic Surgeons, many surgeons across Europe would offer upfront surgery for patients with clinical N2 disease as long as the primary tumor was deemed to be resectable (32). If that is the case, then it could be argued that no further invasive staging is required if initial nuclear imaging suggests N2 disease. However, there are few studies which have analyzed in depth the reasons for the impact of the presence of lymph node involvement in the prognosis of PCs. In the EMETNE 's experience most patients with TC who presented metastasis or local recurrence in follow-up were in stage I and more than 55% are alive after treatment. Among the AC cases with this evolution, however, 66% had lymph node metastases, and 80% of them died after treatment because of the recurrence. The analysis of these results enables us to confirm that nodal invasion demonstrates an obvious influence in the prognosis of AC (103).

Imaging is also crucial for determining distant metastases. The most common sites of PC metastases are the liver, bones and mediastinal lymph nodes (104). Multiphase CT including arterial and portal phase or magnetic resonance imaging (MRI) with dynamic acquisition and diffusion weighted sequences of the liver should be used for the detection of liver metastases (105).

CT with appropriate window setting may be useful to reveal bone metastases however MRI is the technique of choice for detection and characterization of bone metastases, especially of the spine. Somatostatin receptor scintigraphy (SRS) and most recently somatostatin receptor Positron Emission Tomography (PET) imaging may have a higher grade of sensitivity for bone metastases (106, 107) (see below).

Nuclear Medicine techniques

Nuclear medicine techniques may play a role in the diagnosis since they are more specific than conventional imaging for TC and "lower grade" AC and enable whole body imaging for staging, and help to predict the response to Peptide Receptor Radiotargeted Therapy (PRRT).

Whole body SRS with thorax single-photon emission computed tomography (SPECT)/CT may be useful to determine the N and M stage at diagnosis in the preoperative phase. Nearly 80% of the primary tumors, predominantly TC, may be visualized with this technique (79, 94, 106, 108). The SUV at Fludeoxyglucose (FDG) PET is generally higher in AC with higher proliferation index thus demonstrating that FDG PET is helpful in determining the biology of PC (109). FDG PET is the most sensitive technique for poorly differentiated forms (SCLC, LCLC) (110, 111).

A study by Pattenden *et al.* reported the sensitivity and specificity of ^{18}F -FDG PET/CT for the diagnosis of mediastinal lymph node disease in 207 patients with TC and AC as 33% and 94%, respectively, suggesting that lymph node metastases cannot accurately be ruled out with a negative PET-CT in TC (112). If treatment decisions are based on the N2 status, further mediastinal staging using either endobronchial ultrasound/endoscopy ultrasound fine needle aspiration or mediastinoscopy and lymph node biopsies will be required.

Whenever available, Gallium⁶⁸-DOTA somatostatin analogue (either Octreotate, Octreotide or NOC) PET is more sensitive and preferable to SRS (95, 107, 113-116). C^{11} -5-hydroxy-tryptophan (HTP) PET and ^{64}Cu DOTATATE are promising techniques for lung NET but experience is limited to single centers (117, 118).

Other diagnostic techniques

Other techniques are required to reach the definitive diagnosis, to perform the WHO classification and staging. These include:

Bronchoscopy

Bronchoscopy is indicated in all the central forms. It also enables biopsy. Flexible bronchoscopy is preferable, however the clinician should be aware of the possibility of bleeding. In patients at high risk for bleeding rigid bronchoscopy may be preferred, both for obtaining biopsy specimens but also for performing ablation procedures (94, 96, 119).

There is currently limited evidence regarding the added value of new bronchoscopic techniques (echo-endoscopy, fluorescence bronchoscopy, microbronchoscopy) in order to increase the sensitivity of detection of primary tumors, recurrence or mediastinum lymph node staging and to determine endobronchial tumor margins before surgical resection (120, 121).

For peripheral lesions biopsy specimen may be obtained by either endoscopic transbronchial biopsy or more frequently a transthoracic CT guided biopsy. It should be highlighted that the small biopsies may make it difficult to differentiate between TC and AC (69, 94, 96, 119, 120).

Functional respiratory tests

Functional respiratory tests should always be performed to assess the surgical risk and to screen for bronchostenosis and to assess for the not infrequent association with chronic obstructive airways disease (122).

Echocardiography

Echocardiography should be performed at diagnosis and in the course of follow-up in order to evaluate the presence and evolution of carcinoid heart disease (123). In PC, left as well as right side valves should be screened (123, 124). Accurate echocardiographic evaluation should always be performed before surgical procedures.

It should be remembered that the carcinoid syndrome may be diagnosed in pulmonary NET even in the absence of liver metastases and therefore carcinoid heart disease may

be present, particularly on the left side. Furthermore the association with atypical carcinoid syndrome with bronchospasm may additionally impact on the heart function.

Cerebral CT or MRI

Cerebral metastases are a common event in poorly differentiated neuroendocrine tumors but are anecdotal in pulmonary carcinoid more often with higher grade AC. Cerebral CT or MR is not routinely recommended but should be performed in the staging phase and during the follow-up when there is clinical suspicion or indication of disease. For the same reasons prophylactic cerebral radiotherapy (PCI) which is recommended in small cell carcinoma is not justified in these tumors.

DIAGNOSIS: RECOMMENDATIONS FOR THE BEST PRACTICE

- Biochemical baseline tests should be limited to renal function, liver function, calcium, glucose and plasma chromogranin A measurements (*Level of Evidence 4, Grade of recommendation D*).
- Paraneoplastic syndrome might occur in the setting of PC. Biochemical testing should be performed in consideration of clinical symptoms and features including as appropriate 24 hour urine 5 HIAA, ACTH and GHRH (*Level of Evidence 4, Grade of recommendation A*).
- PC may be associated with MEN1 syndrome in <5% of patients. MEN-1 is investigated by family history, clinical examination and minimal laboratory screening (*Level of Evidence 4, Grade of recommendation C*). If the familial history is suggestive of a MEN1 syndrome or a second MEN1 feature is present, screening for MEN1 gene mutation should be performed (*Level of Evidence 5, Grade of recommendation C*).
- More than 40% of the cases may be incidentally detectable on a standard chest x-ray (*Level of Evidence 3/4, Grade of recommendation C*).

- The gold standard is contrast CT (*Level of Evidence 3, Grade of recommendation B*). In patients in whom contrast is contraindicated high resolution CT may be used (*Level of Evidence 4, Grade of recommendation C*).
- Multiphase CT including arterial and portal phase or MRI with dynamic acquisition and diffusion weighted sequences of the liver should be used for the detection of liver metastases (*Level of Evidence 4, Grade of recommendation C*).
- A CT chest and abdomen should be undertaken for preoperative staging (*Level of Evidence 4, Grade of recommendation A, strong recommendation for good practice*).
- Bronchoscopy may be required for the staging and assessment of central airway tumours preoperatively (*Level of Evidence 4, Grade of recommendation A*).
- Flexible bronchoscopy is preferable, however in patients at high risk for bleeding rigid bronchoscopy may be preferred for obtaining biopsy specimens (*Level of Evidence 4, Grade of recommendation B*).
- There is currently limited evidence regarding the added value of new bronchoscopic techniques to increase the sensitivity of detection of primary tumors or recurrence (*Level of Evidence 4, Grade of recommendation D*).
- Small biopsies may make it difficult to differentiate between TC and AC (*Level of Evidence 4, Grade of recommendation C*).
- Whole body SRS with thorax single-photon emission computed tomography (SPECT)/CT may be useful to visualize nearly 80% of the primary tumors (*Level of Evidence 4, Grade of recommendation B*).
- SRS and somatostatin receptor PET imaging may have a higher grade of sensitivity for bone metastases. (*Level of evidence 4, Grade of recommendation D*).

- Gallium⁶⁸-DOTA Somatostatin analogue PET is more sensitive and preferable to SRS if available (*Level of Evidence 4, Grade of recommendation C*).
- Most TC have low or no uptake on FDG PET whereas AC may have higher uptake. FDG PET is most useful for poorly differentiated forms (SCLC, LCLC) (*Level of Evidence 4, Grade of recommendation C*).
- Functional respiratory tests should always be performed to assess the surgical risk and the association with chronic obstructive airways disease and to screen for bronchostenosis (*Level of Evidence 4, Grade of Recommendation A*).
- Echocardiography is always indicated in patients with carcinoid syndrome before surgery (*Level of Evidence 4, Grade of recommendation B, strong recommendation for good practice*). In PC, left as well as right side valves should be screened (*Level of Evidence 4, Grade of recommendation B*).

SURGERY

Surgical removal is the treatment of choice for PCs. The aim is to remove the tumor and to preserve as much lung tissue as possible. The surgical approach is dependent on the size, location and tissue type.

Surgery for localized disease

Complete anatomic resection and systematic nodal dissection

For patients with peripheral lung tumors, the surgical extent of choice is complete anatomic resection (lobectomy, segmentectomy). The extent of lymph node management should conform to the IASLC recommendations for the certainty factor in the designation of R0 resection; this

involves a minimum of 6 nodes/stations, 3 of which should be mediastinal including the subcarinal station (125).

In patients with limited pulmonary function the practice of a standard segment resection achieves better results than a broad wedge resection. For peripheral AC, if only a limited sublobar resection is performed, there may be increased probability of local recurrence postoperatively.

Lung parenchymal sparing surgery and systematic nodal dissection

For patients with central airway tumors, lung parenchymal sparing surgery is the favored surgical objective. This is in view of the low malignant and recurrence potential (almost exclusively TC). Where possible, bronchial sleeve resection (no lung tissue is removed) or a sleeve lobectomy should be performed in preference to pneumonectomy (ideally with intra-operative frozen section of the resection margins) (126). If necessary, patients should be referred to regional or national centres of excellence if such services are not available locally. In the presence of distant pneumonitis and destroyed lung parenchyma, an initial local endobronchial resection to disobliterate the airway may be undertaken for drainage prior to re-assessment for lung parenchymal sparing surgery (126).

Systemic nodal dissection should be performed since lymph node metastases may be present in up to 25% of cases in TC and >50% in AC (96, 127).

Local resection

Endobronchial (e.g. local diathermy resection, laser resection) or peripheral (e.g. radiofrequency ablation) local ablation techniques may be employed with palliative intent (126).

Surgery for metastatic disease

There is little evidence to guide on surgery as part of multimodality management of patients with metastatic disease. If pulmonary surgery is considered, then consensus would be to reserve surgery for patients with limited sites of disease with "curative intent" where radical

treatment is possible for all sites. Such surgery is usually applied to TC and perhaps AC with low mitotic counts.

Liver Resection

Surgical resection of liver metastases can be considered with curative intent, to aid symptom control or for debulking when >90% of tumour can be removed. Complete resection of liver metastases has increased 5 year overall survival rates to over 70% (128). Thus, where possible, metastases should be resected. The minimal requirements for curative intent are (1) resectable G1-G2 liver disease with acceptable morbidity and < 5% mortality; (2) absence of right heart insufficiency; (3) absence of unresectable lymph node and extra-abdominal metastases; and (4) absence of diffuse or unresectable peritoneal carcinomatosis (129).

Surgery for recurrent disease

In general recurrent disease is uncommon, and surgery may be offered on the same premise of peri-operative risk and stage selection as primary surgery. Cases of regional recurrences have been noted up to and beyond 30 years from the original resection of the primary tumour (130, 131). Other studies have reported recurrences more than ten years from the initial resection (132-134). Sometimes it is possible to treat local recurrences with further surgery (134).

Survey of Surgical Management.

In June 2012, the European Society for Thoracic Surgery (ESTS) <http://www.ests.org/default.aspx> launched the Neuroendocrine Tumors of the Lung Working-Group (NETs-WG) and included an electronic survey on PCs (135). The questionnaire included 19 questions, organized in 4 sections:

1. Preoperative patient assessment
2. Surgical approach to particular clinical NET scenarios
3. Follow-up organization

4. Treatment of tumor recurrences/metastases.

One hundred seventy-two Institutions worldwide replied to this survey. Concerning the surgical approach to well-differentiated lung NETs, an anatomic resection (either segmentectomy or lobectomy) was suggested for a peripheral PC by more than 88% of responders, while only 19 (11%) considered a wedge resection as an adequate surgical option. 164 (95%) responded that pneumonectomy should be avoided whenever feasible in case of centrally located PC, performing parenchymal-sparing resections, with preference for performing parenchymal-sparing resections, nevertheless 8 (5%) still believed that pneumonectomy was the treatment of choice.

Lymphadenectomy, and in particular systematic hilar and mediastinal lymphadenectomy according to the ESTS recommendations for intraoperative lymph node assessment (112) was suggested by the majority of responders (64%); lymph node sampling was considered adequate by 34% of Institutions, whilst 4 Centers replied that they did not perform lymphadenectomy in any patient with PC.

In the case of a fit patient with resectable N2 PC, upfront surgery was suggested by more than half of responders, whilst induction chemotherapy was proposed by 71 Centers (41%).

Furthermore, another unusual but sometimes described (136-138) clinical scenario is represented by the multifocal PCs (bilateral synchronous/metachronous ones). Currently there's no consensus concerning their treatment, and a therapeutic strategy must be designed on case by case basis. Looking at the ESTS survey results, the lack of guidelines is confirmed by the fact that 36% of responders replied suggesting an anatomic resection, but the other answers were split between a non-anatomic resection and the resection of the larger lesion, only.

Finally, all but 1 of responders stated that surgery (if feasible) should be proposed in the case of recurrent TC, while other therapeutic options (biological therapy, conventional chemotherapy) were also suggested in the case of recurrent AC.

Local Bronchoscopic Therapy

PCs without an extraluminal component can be treated at bronchoscopy resulting in excellent long-term outcome with more tissue-sparing than immediate surgical resection. For successful tumor eradication with initial bronchoscopic treatment the assessment of intraluminal versus extraluminal growth may be of much more importance than histologic division between TC and AC (139). In order to decrease the risk of local recurrence, cryotherapy is a safe and effective adjunct to endobronchial mechanical resection of TC and tends not to be associated with long-term complications such as bronchial stenosis (140). In endoluminal PCs, laser bronchoscopy may be a curative option and offers many advantages as it is rapid, immediately effective and repeatable. Laser bronchoscopy may also be used in association with other therapies (i.e. radiotherapy) in cases of widespread intramural infiltration with an extraluminal component (141). If the local treatment is not radical, surgical resection can follow bronchoscopic treatment. This treatment strategy represents a minimally invasive and parenchyma sparing alternative or a postponement of lobectomy to the moment of recurrence after endobronchial treatment. Such local therapies need to be considered in the context of patient medical status, type of PC, robust imaging including functional imaging to exclude nodal spread.

SURGERY: RECOMMENDATIONS FOR THE BEST PRACTICE

- In the case of localised disease, the surgical techniques of choice are lobectomy or sleeve resection (*Level of evidence 5, Grade of recommendation A*).
- Complete anatomic resection and systematic nodal dissection is recommended as the resection extent of choice of patients with peripheral tumours (*Level of Evidence 5, Grade of recommendation D*).

- Lung parenchymal sparing surgery should be preferred over pneumonectomy (*Level of Evidence 5, Grade of recommendation C*).
- Local resection should be reserved for patients who are considered unacceptably high risk for broncho-pulmonary surgery (*Level of Evidence 5, Grade of recommendation D*).
- Endoluminal bronchoscopic therapy, more appropriately for TC, should be reserved for patients who are considered unacceptably high risk for broncho-pulmonary surgery or occasionally as a possible bridge to surgery (*Level of Evidence 5, Grade of recommendation D*).
- Resection of liver metastases should be performed whenever possible if curative intent is considered and in syndromic patients when >90% of tumor burden can be removed. The minimal requirements for curative intent include resectable TC and low grade AC; < 5% mortality; absence of right heart insufficiency; absence of unresectable lymph node and extra-abdominal metastases; and absence of unresectable peritoneal carcinomatosis (*Level of Evidence 4, Grade of recommendation C*).

MEDICAL THERAPY

Advanced AC is more aggressive than TC (127, 142) and the medical management must incorporate multidisciplinary meeting review. The goals are to control both hormone-related symptoms and tumor growth (79, 94, 143). The prognostic heterogeneity and absence of curative therapeutic options at the metastatic stage make quality of life a core issue. The key factors to take into account for medical management are the spontaneous slope without treatment, the metastatic spread of the primary tumor, SRS grade of uptake and quality of control of hormone-related symptoms. Based on the limited number of studies available in patients with primary PC, these recommendations also rely on data available for well differentiated digestive NETs. However, several significant parameters that differ from digestive NETs need to be stressed: a higher diversity of hormone-related symptoms, a bronchial – specific carcinoid syndrome which may exist even in patients free of liver metastases, low number of patients with distant metastases at

diagnosis, higher prevalence of bone, cutaneous and brain metastases and lower frequency of MEN1 syndrome.

Control of hormonal secretion

Symptoms related to hormone secretion are present in up to 30% of advanced PCs. Carcinoid syndrome is the most frequent functioning syndrome in PC. Somatostatin analogues (SSA) constitute the gold standard for symptomatic control. A >50% improvement in the frequency of flushing symptoms and diarrhoea has been reported after SSA in GEP NETs (144, 145). A study specifically looking at the management of carcinoid syndrome in 7 patients with AC showed complete control of symptoms with short-acting octreotide injections (146). Presence of carcinoid heart disease should be carefully monitored.

Symptoms of Cushing syndrome are seen in 1 to 2% of patients with a PC and may be the initial reason for seeking medical attention. Cushing syndrome could be treated with commonly available agents such as ketoconazole, metyrapone, etomidate or mifepristone. Ketoconazole, given at a daily dose of 600 to 800 mg, is the most popular and effective. Metyrapone is also often used in this setting and therapy starts at 1 g/d divided into 4 doses and increased to a maximum dose of 4.5 g/d. For ectopic GHRH secretion and acromegaly, SSAs can be of value. Some patients with ectopic ACTH syndrome might respond to SSA as well (79). In the absence of hormonal control other antitumor options need to be considered and these include: loco-regional therapies [i.e. liver palliative surgery, transarterial chemoembolization (TACE), radiofrequency ablation], combination of SSA with Interferon (IFN) and PRRT in selected patients (79, 95). Prophylaxis against carcinoid crisis should be performed prior to surgical or loco-regional interventions using adequate dosage of SSA. For major procedures, a pre-operative intravenous bolus of 100-200 mcg, followed by a continuous infusion of 50 mcg/h during the procedure, is recommended and the dose can be increased if required. The infusion should continue for 24 hour postoperatively before being slowly weaned over the next 48 hours. In such cases it is likely that patients will require long-acting SSA (79).

Adjuvant tumor control

Currently, there is no consensus on adjuvant therapy in PCs after complete resection. Indeed, both prognostic studies and trials in the adjuvant setting are lacking. Only patients with AC with positive lymph nodes, especially if there is a high proliferative index, should be considered for adjuvant therapy and discussed on an individual patient basis in the context of multidisciplinary tumor board meeting. Clinical trials are needed in this setting.

Palliative tumor control

There are no prospective trials dedicated to PC that may guide treatment and most literature consists of case series or studies that deal with mixed population of primary NET patients. Prognostic behaviour and safety should be the first parameter to guide the therapeutic decision making process.

In asymptomatic patients mainly with advanced TC or AC of low proliferative index as well as low tumor burden, a watch and see policy might be considered and explained to the patients on the basis of regular cross-sectional imaging initially three to six monthly.

SSA can induce stabilization in 30-70% of patients with well differentiated NET as demonstrated in multiple prospective and retrospective studies that included PCs (147-149). There are no dedicated trials, available for lung primary. The randomized placebo controlled PROMID study of Octreotide LAR 30 mg versus placebo in midgut NET (n=85) demonstrated antitumor control with median time to progression significantly longer in octreotide LAR 30 mg group than placebo, 14.3 months versus 6 months respectively (150). The phase III randomized placebo controlled (CLARINET) study in 204 patients with nonfunctional enteropancreatic NETs allocated either lanreotide Autogel (120 mg/28 days) or placebo and showed significantly prolonged progression free survival over placebo ($p=0.0002$) with 62% of lanreotide treated patients vs. 22% of placebo treated having not progressed at 96 weeks (151).

The most commonly used long-acting SSAs are octreotide LAR by deep i.m. injection and lanreotide Autogel given s.c., both administered every 28 days. Due to their excellent safety profile, SSA should be considered as first line systemic treatment for patients with advanced PCs of low proliferation index and positive SRS. Caution should be exercised in patients with high tumor burden, high mitotic index or rapidly progressive tumor and a first imaging performed at two to three months.

In patients with slowly progressive tumors, multiple loco-regional therapies aiming at reducing the tumor burden and targeting the bronchial primary and liver, bone or bronchial metastases should be considered (79, 95). In contrast with digestive NETs, in whom mainly liver directed therapies are used, extra-liver metastases are frequently found in case of PCs and should also be considered as therapeutic targets. Surgical resection can be considered with intent of resection of macroscopic metastases as outlined above mainly in slowly progressive TC and low proliferative AC or in case of symptoms related to the primary location (129, 152, 153).

Loco-regional therapies

Radiofrequency ablation (RF) or cryoablation of the primary tumor are occasionally considered as an adjunct to surgery or whenever resection is not possible. Liver but also bone or lung metastases constitute potential targets of RF ablation. The size and anatomical locations constitute major predictors of efficacy. Liver metastases derive the majority of their blood supply from the hepatic arteries, therefore selective embolisation with either bland particles (transarterial embolisation, TAE) or cytotoxics such as doxorubicin (TACE) are found to be effective in improving symptoms and radiological response particularly in GEP NETs. Radiological response rates between 33-73% have been reported. There is no evidence suggesting beneficial response of chemoembolisation over particle embolisation alone. There is emerging evidence of using radioactive microspheres such as Yttrium 90 in liver metastases. The added value of combination of loco-regional therapies as an adjunct to surgery or systemic therapy in case of progressive disease should be kept in mind (129, 152).

Peptide Receptor Radiotargeted Therapy

Well differentiated PC frequently express subtype 2 of the SSTR family and this can be identified by Indium-111 somatostatin analogue scintigraphy or Gallium-68 somatostatin analogue PET scans which constitute predictors of response. PRRT may be used to treat metastases of TC and AC, with currently 90 Yttrium-DOTA Octreotide and 177 Lutetium DOTA Octreotide showing particular promise in selected patients with high uptake at SRS. Prospective and randomized trial results are warranted. Early Phase II studies of Yttrium 90 Octreotide found the response rate to be as high as 29% in 7 PCs (154). Although most studies are limited to single centres, a large retrospective study looking at 1109 metastatic NETs included 84 PCs, of which 28% showed a morphological response as estimated by RECIST criteria and 38.1% showed a clinical response with a mean survival of 40 months. Grade 3-4 toxicity is reported in 10 to 33% of patients, mainly renal or hematological toxicities including irreversible renal toxicity (9.2%) (155). Lutetium 177 DOTA Octreotate (DOTATATE) is a combination of the beta emitting Lutetium coupled to Octreotate (156). A study looking at foregut NETs with response to Lutetium 177 included 9 PCs, of which 5 showed a partial response and just one had progressive disease (157). The number of bone metastases and baseline glomerular filtration rate correlated with toxicity.

Systemic chemotherapy

Systemic chemotherapy should be considered in patients with advanced unresectable progressive PC. In general, results with chemotherapy have been largely disappointing and survival data has to be interpreted with caution due to the small numbers of patients, the mixed population of primary tumors, the absence of progression prior to the study enrolment and the old standard criteria. Overall response rate (ORR) below 30% has been described with 5 Fluorouracil, Dacarbazine, Temozolomide (TMZ) alone or in combination but also combinations of Fluorouracil (5-FU) with streptozotocin (STZ) or oxaliplatin (158-160). Their value in the management of

advanced PCs remains unclear but their level of G3-4 toxicity is expected above 10%. TMZ is advocated as palliative treatment in PCs as it has been the most widely studied in the subgroup of lung NET and has an acceptable safety profile. TMZ could also be considered in case of brain metastases (161). Analysis of methylguanine DNA methyltransferase (MGMT) expression in NETs may help to select responders (162). In lung NETs a STZ-based regimen showed disappointing results with 7 out of 7 patients progressing on STZ and 5-FU (163). In a randomized trial analyzing 5-FU-STZ vs. 5-FU-doxorubicin in symptomatic carcinoids including 22 PCs, 16% ORR was found with a duration of 5 months and a survival advantage of the Fu-STZ combination suggesting that Doxorubicin does not confer any benefit in these patients (158). A retrospective analysis of 5FU-STZ and cisplatin included 79 patients with progressive NET of which 8 were PC. The response rate in this study for non-pancreatic primary sites was 25% with overall median TTP 9.1 months. One PC patient had a partial response enabling surgery and resection of primary and nodal disease (164). The combination of 5FU and STZ plus or minus Cisplatin (FCist) was recently re-examined in a randomized phase II trial of 85 consecutive NETs treated with this regimen and no added value of Cisplatin was found (165). A 20% response rate to Cisplatin or Carboplatin was reported in two studies specifically dedicated to well differentiated PCs (163, 166). Due to its significant rate of toxicity, cisplatin should only be considered in patients with more aggressive, advanced PCs.

mtor Inhibitors

Everolimus may be a therapeutic option after failure of other treatments in TC and AC. Mammalian target of Rapamycin (mtor) has been identified as a kinase activated in the PI3K signalling pathway of lung NETs (167). Recently, mutations of PI3CA were reported in TC and AC. The randomised phase III RADIANT 2 trial assessed Everolimus 10mg + Octreotide LAR VS. placebo + Octreotide LAR in 429 patients in non-pancreatic functioning (carcinoid syndrome) NETs. The study demonstrated a clinically significant 5.1 month increase in median progression free survival (168). Within this RADIANT 2 trial, 44 primaries were of bronchial origin (169). The PAZONET study of pazopanib as a sequencing treatment in progressive metastatic NET showed a

clinical benefit in 85% of patients treated with pazopanib, including patients with lung carcinoids (170). The RAMSETE study analyzed the antitumor benefit of everolimus in 19 foregut-derived NETs with RECIST progression over a year. A progression free survival of 189 days was reported (171). The LUNA study is a 3 arm phase II trial assessing Everolimus alone vs. Pasireotide (a pan-somatostatin receptor analogue) vs. combination and started recruiting in 2013 (LUNA study, see www.clinicaltrials.gov/ct2/show/NCT01563354). The randomised phase III RADIANT 4 trial, which assessed Everolimus 10 mg versus placebo in 279 patients in non-functioning NETs including lung PCs, has been closed for enrollment and the results are expected in 2015.

Antiangiogenesis Agents

The place of antiangiogenic agents in PC remains uncertain. Sunitinib is an orally administered kinase inhibitor small molecule with activity against a number of tyrosine kinase inhibitors including VEGFR-1, -2, -3, PDGFR-a, -b (172). A phase II study evaluated the activity of sunitinib in 109 NE patients including 41 with carcinoids, of whom 14 were foregut including PC. In the carcinoid patients, ORR was 2.4%, with stable disease in 83%, with a TTP of 10.2 months and 1-year survival rate of 83.4 (173). Bevacizumab is an anti vascular endothelial growth factor (VEGF) monoclonal antibody and in a phase II study patients were randomised to either Bevacuzimab or pegylated IFN and 21 out of 22 patients demonstrated a partial response in the Bevacuzimab group where four patients were PC (174). One phase II study analyzed the antitumor efficacy of Sorafenib plus Bevacizumab combination in 44 NET including 19 foregut NETs. A 10% ORR was reported in digestive NETs (175). More studies looking at antiangiogenic activity in PC are required. Promising results have been published with the combination of Bevacizumab and chemotherapy (176)

Erlotinib and EGFR Inhibitors

The Epidermal Growth factor pathway (EGF) has been found to be expressed in PC but no mutation has been reported to date. In vitro and in vivo studies using the EGF receptor inhibitor Erlotinib suggested a potential role and currently Phase II studies are ongoing (www.clinicaltrials.gov. NCT0084 3531 RAD001 and erlotinib in patients with NETs. 2012; Available from: <http://www.clinicaltrials.gov/ct2/results?term=NCT00843531>). Other pathways being investigated are fibroblast growth factor (FGF) and MET pathways, with a range of new molecules being developed for the VEGF and platelet derived growth factor (PDGF) pathways (177).

Follow-up

After primary surgery, patients with TC and AC should be followed initially at least yearly. However, the follow-up needs to be long term even if less frequent to detect surgically manageable recurrences. Liver, mediastinum and abdomen lymph nodes, lung, cutaneous and or bone metastases are routinely evaluated by appropriate means. In case of high tumor burden or specific symptoms, brain metastases should be considered. Conventional imaging is performed at 3 and 6 months and then every 12 months in TC together with chromogranin A measurements for the first 2 years. Then annual chest x-ray and biochemistry profile and a CT every 3 years long-term. The frequency may be more frequent in R1 or node positive patients. SRS should be performed at 12 months and then only on suspicion of recurrence for TC. For AC closer monitoring is recommended. CT imaging should be performed 3 months post-surgery and then 6 monthly for 5 years with biochemical markers. SRS imaging is performed at 1 year and then on suspicion of recurrence. After 5 years, annual CT should be performed. In selected patients with high proliferative index, FDG PET may be more informative and replace SRS imaging.

At the time of a therapeutic intervention, patients should be routinely monitored every 3 months. Fiberoptic bronchoscopy is performed for any symptoms suggestive of local progression and on a

routine basis every 5-10 years for TC or 1-3 years in case of AC. The type of surgery, the R status, and the size of the primary will also be taken into account to define the most appropriate interval (79, 95, 178).

MEDICAL THERAPY: RECOMMENDATIONS FOR THE BEST PRACTICE

- A Watch and see policy may be considered in a subgroup of asymptomatic patients mainly with TC or AC of low proliferative index (*Level of Evidence 5; Grade of recommendation D*).
- SSAs are the first line treatment for Carcinoid Syndrome and Acromegaly (*Level of Evidence 3; Grade of recommendation B*).
- In patients with Cushing syndrome, control of cortisol secretion is needed (*Level of Evidence 3; Grade of recommendation B*).
- Bilateral adrenalectomy is a therapeutic option for refractory Cushing syndrome (*Level of Evidence 5; Grade of recommendation D*).
- SSA may be considered as first-line systemic antiproliferative treatment of patients with advanced unresectable PC of good prognosis particularly TC and AC with low proliferative index, and slowly progressive provided that SRI is positive, (*Level of Evidence 3; Grade of recommendation B*).
- Locoregional options including surgery (for primary and metastases), TAE, radiofrequency ablation should always be considered for slow progressive PC (*Level of Evidence 4; Grade of recommendation C*).
- Cytotoxic treatment has been the standard for aggressive metastatic PCs, although the available chemotherapy regimens demonstrate a limited effect (*Level of Evidence 3; Grade of recommendation B*).

- Temozolomide alone has demonstrated clinical benefit (*Level of Evidence 3; Grade of recommendation C*). A combination of cisplatin and etoposide is mainly used in high proliferating PC (*Level of Evidence 3; Grade of recommendation B*).
- PRRT is an option in patients with tumors that demonstrate strong expression of SSTRs (*Level of Evidence 3; Grade of recommendation C, strong recommendation for good practice*).
- There is evidence of preliminary efficacy for everolimus in the treatment of progressive PC. The ongoing randomised phase III LUNA study will determine future management (*Level of Evidence 4; Grade of recommendation D*).
- There is no consensus on adjuvant therapy in PCs after complete resection. There might be consideration in patient with AC of high proliferative index. (*Level of Evidence 4; Grade of recommendation D*).
- After primary surgery patients with TC and AC should be followed long-term (*Level of Evidence 4; Grade of recommendation B*).

Declared Interests

M E Caplin: advisory board and research funding from Novartis, Ipsen and Lexicon.

E. Baudin: advisory board and consultancy from Novartis, Ipsen, HRA Pharma, Roche, Pfizer and AAA

P. Ferolla: advisory boards and consultancy for Novartis, Ipsen, Lexicon and Italfarmaco

E. Lim: personal fees from Abbott Molecular, Glaxo Smith Kline, Pfizer, Novartis, Covidien, Roche, Lily Oncology, Boehringer Ingelheim, Medela, grants and personal fees from ScreenCell.

REFERENCES

1. Klimstra DS, Modlin IR, Coppola D, et al. The pathologic classification of neuroendocrine tumors: a review of nomenclature, grading, and staging systems. *Pancreas* 2010;39:707-12.
2. Travis W, Brambilla E, Muller-Hermelink H, et al. *Tumours of the lung, pleura, thymus and heart*. Lyon: IARC Press; 2004.
3. Cerilli LA, Ritter JH, Mills SE, et al. Neuroendocrine neoplasms of the lung. *Am J Clin Pathol* 2001;116 Suppl:S65-96.
4. Moran CA, Suster S, Coppola D, et al. Neuroendocrine carcinomas of the lung: a critical analysis. *Am J Clin Pathol* 2009;131:206-21.
5. Wick MR. Neuroendocrine neoplasia. Current concepts. *Am J Clin Pathol* 2000;113:331-5.
6. Capella C, Heitz PU, Hofler H, et al. Revised classification of neuroendocrine tumors of the lung, pancreas and gut. *Digestion* 1994;55 Suppl 3:11-23.
7. Huang Q, Muzitansky A, Mark EJ. Pulmonary neuroendocrine carcinomas. A review of 234 cases and a statistical analysis of 50 cases treated at one institution using a simple clinicopathologic classification. *Arch Pathol Lab Med* 2002;126:545-53.
8. Skov BG, Krasnik M, Lantuejoul S, et al. Reclassification of neuroendocrine tumors improves the separation of carcinoids and the prediction of survival. *J Thorac Oncol* 2008;3:1410-5.
9. Alsina M, Marcos-Gragera R, Capdevila J, et al. Neuroendocrine tumors: a population-based study of incidence and survival in Girona Province, 1994-2004. *Cancer Epidemiol* 2011;35:e49-54.
10. de Jong WK, Schaapveld M, Blaauwgeers JL, et al. Pulmonary tumors in the Netherlands: focus on temporal trends in histology and stage and on rare tumors. *Thorax* 2008;63:1096-102.

11. Fink G, Krelbaum T, Yellin A, et al. Pulmonary carcinoid: presentation, diagnosis, and outcome in 142 cases in Israel and review of 640 cases from the literature. *Chest* 2001;119:1647-51.
12. Hallgrimsson JG, Jonsson T, Johannsson JH. Bronchopulmonary carcinoids in Iceland 1955-1984. A retrospective clinical and histopathologic study. *Scand J Thorac Cardiovasc Surg* 1989;23:275-8.
13. Hauso O, Gustafsson BI, Kidd M, et al. Neuroendocrine tumor epidemiology: contrasting Norway and North America. *Cancer* 2008;113:2655-64.
14. Hemminki K, Li X. Incidence trends and risk factors of carcinoid tumors: a nationwide epidemiologic study from Sweden. *Cancer* 2001;92:2204-10.
15. Levi F, Te VC, Randimbison L, Rindi G, et al. Epidemiology of carcinoid neoplasms in Vaud, Switzerland, 1974-97. *Br J Cancer* 2000;83:952-5.
16. Modlin IM, Lye KD, Kidd M. A 5-decade analysis of 13,715 carcinoid tumors. *Cancer* 2003;97:934-59.
17. Naalsund A, Rostad H, Strom EH, et al. Carcinoid lung tumors--incidence, treatment and outcomes: a population-based study. *Eur J Cardiothorac Surg* 2011;39:565-9.
18. Perez EA, Koniaris LG, Snell SE, et al. 7201 carcinoids: increasing incidence overall and disproportionate mortality in the elderly. *World J Surg* 2007;31:1022-30.
19. Quaedvlieg PF, Visser O, Lamers CB, et al. Epidemiology and survival in patients with carcinoid disease in The Netherlands. An epidemiological study with 2391 patients. *Ann Oncol* 2001;12:1295-300.
20. Skuladottir H, Hirsch FR, Hansen HH, et al. Pulmonary neuroendocrine tumors: incidence and prognosis of histological subtypes. A population-based study in Denmark. *Lung Cancer* 2002;37:127-35.
21. Yao JC, Hassan M, Phan A, et al. One hundred years after "carcinoid": epidemiology of and prognostic factors for neuroendocrine tumors in 35,825 cases in the United States. *J Clin Oncol* 2008;26:3063-72.

22. Hemminki K, Li X. Familial carcinoid tumors and subsequent cancers: a nation-wide epidemiologic study from Sweden. *Int J Cancer* 2001;94:444-8.
23. Gatta G, Ciccolallo L, Kunkler I, et al. Survival from rare cancer in adults: a population-based study. *Lancet Oncol* 2006;7:132-40.
24. Travis WD, Travis LB, Devesa SS. Lung cancer. *Cancer* 1995;75:191-202.
25. Carter D, Vazquez M, Flieder DB, et al. Comparison of pathologic findings of baseline and annual repeat cancers diagnosed on CT screening. *Lung Cancer* 2007;56:193-9.
26. Pelosi G, Sonzogni A, Veronesi G, et al. Pathologic and molecular features of screening low-dose computed tomography (LDCT)-detected lung cancer: a baseline and two-year repeat study. *Lung Cancer* 2008; 62:202-14
27. Gustafsson BI, Kidd M, Chan A, et al. Bronchopulmonary neuroendocrine tumors. *Cancer* 2008;113:5-21.
28. Greenberg RS, Baumgarten DA, Clark WS, et al. Prognostic factors for gastrointestinal and bronchopulmonary carcinoid tumors. *Cancer* 1987;60:2476-83.
29. Soga J, Yakuwa Y. Bronchopulmonary carcinoids: An analysis of 1,875 reported cases with special reference to a comparison between typical carcinoids and atypical varieties. *Ann Thorac Cardiovasc Surg* 1999;5:211-9.
30. Faggiano A, Ferolla P, Grimaldi F, et al. Natural history of gastro-entero-pancreatic and thoracic neuroendocrine tumors. Data from a large prospective and retrospective Italian Epidemiological study: THE NET MANAGEMENT STUDY. *J Endocrinol Invest* 2011
31. Hassan MM, Phan A, Li D, et al. Risk factors associated with neuroendocrine tumors: A U.S.-based case-control study. *Int J Cancer* 2008;123:867-73.
32. Filosso PL, Rena O, Donati G, et al. Bronchial carcinoid tumors: surgical management and long-term outcome. *J Thorac Cardiovasc Surg* 2002;123:303-9.
33. Zuetenhorst JM, Taal BG. Metastatic carcinoid tumors: a clinical review. *Oncologist* 2005;10:123-31.

34. Broaddus RR, Herzog CE, Hicks MJ. Neuroendocrine tumors (carcinoid and neuroendocrine carcinoma) presenting at extra-appendiceal sites in childhood and adolescence. *Arch Pathol Lab Med* 2003;127:1200-3.
35. Dishop MK, Kuruvilla S. Primary and metastatic lung tumors in the pediatric population: a review and 25-year experience at a large children's hospital. *Arch Pathol Lab Med* 2008;132:1079-103.
36. Lal DR, Clark I, Shalkow J, et al. Primary epithelial lung malignancies in the pediatric population. *Pediatr Blood Cancer* 2005;45:683-6.
37. Rizzardi G, Marulli G, Calabrese F, et al. Bronchial carcinoid tumors in children: surgical treatment and outcome in a single institution. *Eur J Pediatr Surg* 2009;19:228-31.
38. Yu DC, Grabowski MJ, Kozakewich HP, et al. Primary lung tumors in children and adolescents: a 90-year experience. *J Pediatr Surg* 2010;45:1090-5.
39. Rekhtman N. Neuroendocrine tumors of the lung: an update. *Arch Pathol Lab Med* 2010;134:1628-38.
40. Travis W, Brambilla E, Noguchi M, et al. International association for the study of lung cancer/american thoracic society/european respiratory society international multidisciplinary classification of lung adenocarcinoma. *J Thorac Oncol* 2011;6:244-85.
41. Beasley MB, Thunnissen FB, Brambilla E, et al. Pulmonary atypical carcinoid: predictors of survival in 106 cases. *Hum Pathol* 2000;31:1255-65.
42. Brokx HA, Risse EK, Paul MA, et al. Initial bronchoscopic treatment for patients with intraluminal bronchial carcinoids. *J Thorac Cardiovasc Surg* 2007;133:973-8.
43. Erasmus JJ, McAdams HP, Patz EF, Jr., et al. Evaluation of primary pulmonary carcinoid tumors using FDG PET. *AJR Am J Roentgenol* 1998;170:1369-73.
44. Froudarakis M, Fournel P, Burgard G, et al. Bronchial carcinoids. A review of 22 cases. *Oncology* 1996;53:153-8.

45. Kayser K, Kayser C, Rahn W, et al. Carcinoid tumors of the lung: immuno- and ligandohistochemistry, analysis of integrated optical density, syntactic structure analysis, clinical data, and prognosis of patients treated surgically. *J Surg Oncol* 1996;63:99-106.
46. De Giorgi U, Fanini F, Amadori D, et al. Tumorlets in familial history of bronchopulmonary carcinoid. *J Thorac Oncol* 2011;6:1613-4.
47. Oliveira AM, Tazelaar HD, Wentzlaff KA, et al. Familial pulmonary carcinoid tumors. *Cancer* 2001;91:2104-9.
48. Leotlela PD, Jauch A, Holtgreve-Grez H, et al. Genetics of neuroendocrine and carcinoid tumors. *Endocr Relat Cancer* 2003;10:437-50.
49. Matsuda KM, Nobrega R, Quezado M, et al. Melanocytic bronchopulmonary carcinoid tumor in a patient with multiple endocrine neoplasia syndrome type 1: a case report with emphasis on intraoperative cytological findings. *Diagn Cytopathol* 2010;38:669-74.
50. Sachithanandan N, Harle RA, Burgess JR. Bronchopulmonary carcinoid in multiple endocrine neoplasia type 1. *Cancer* 2005;103:509-15.
51. Ferolla P, Daddi N, Urbani M, et al. Tumorlets, multicentric carcinoids, lymph-nodal metastases, and long-term behavior in bronchial carcinoids. *J Thorac Oncol* 2009;4:383-7.
52. Ruge M, Fassan M, Clemente R, et al. Bronchopulmonary carcinoid: phenotype and long-term outcome in a single-institution series of Italian patients. *Clin Cancer Res* 2008;14:149-54.
53. Travis WD, Giroux DJ, Chansky K, et al. The IASLC Lung Cancer Staging Project: proposals for the inclusion of broncho-pulmonary carcinoid tumors in the forthcoming (seventh) edition of the TNM Classification for Lung Cancer. *J Thorac Oncol* 2008;3:1213-23.
54. Lou F, Sarkaria I, Pietanza C, et al. Recurrence of Pulmonary Carcinoid Tumors After Resection: Implications for Postoperative Surveillance. *Ann Thorac Surg* 2013

55. Travis W, Colby T, Corrin B, et al. *Hystological typing of lung and pleural tumors*. Berlin Heidelberg New York: Springer Verlag; 1999.
56. Rindi G, Klersy C, Inzani F, et al. Grading the neuroendocrine tumors of the lung: an evidence-based proposal. *Endocr Relat Cancer*. 2013;21:1-16.
57. Axiotis C. The neuroendocrine lung. In: Li Volsi V, Asa S, editors. *Endocrine Pathology*. New York Edinburgh: Churchill Livingstone; 2002. p. 261-96.
58. Capella C, Heitz PU, Hofler H, et al. Revised classification of neuroendocrine tumors of the lung, pancreas and gut. *Virchows Arch* 1995;425:547-60.
59. Solcia E, Klöppel G, Sobin L. *Histological typing of endocrine tumors*. Heidelberg: Springer; 2000.
60. Li Y, Linnoila I. Multi-Directional Differentiation of Ascl1-Defined Progenitors in Lung Development and Injury Repair. *Am J Respir Cell Mol Biol* 2012
61. Linnoila RI. Functional facets of the pulmonary neuroendocrine system. *Lab Invest* 2006;86:425-44.
62. Warburton D, Schwarz M, Tefft D, et al. The molecular basis of lung morphogenesis. *Mech Dev* 2000;92:55-81.
63. Godwin JD, 2nd, Brown CC. Comparative epidemiology of carcinoid and oat-cell tumors of the lung. *Cancer* 1977;40:1671-3.
64. Bosman F, Carneiro F, Hruban R, et al. *WHO classification of tumors of the digestive system*. Lyon: International Agency for Research on Cncer (IARC); 2010.
65. Travis WD, Gal AA, Colby TV, et al. Reproducibility of neuroendocrine lung tumor classification. *Hum Pathol* 1998;29:272-9.
66. Tsuta K, Liu DC, Kalhor N, et al. Using the mitosis-specific marker anti-phosphohistone H3 to assess mitosis in pulmonary neuroendocrine carcinomas. *Am J Clin Pathol* 2011;136:252-9.
67. Clinical Lung Cancer Genome Project (CLCGP); Network Genomic Medicine (NGM). A genomics-based classification of human lung tumors. *Sci Transl Med*. 2013;5:209ra153

68. Zahel T, Krysa S, Herpel E, et al. Phenotyping of pulmonary carcinoids and a Ki-67-based grading approach. *Virchows Arch* 2012;460:299-308.
69. Pelosi G, Rodriguez J, Viale G, et al. Typical and atypical pulmonary carcinoid tumor overdiagnosed as small-cell carcinoma on biopsy specimens: a major pitfall in the management of lung cancer patients. *Am J Surg Pathol* 2005;29:179-87.
70. Skov BG, Holm B, Erreboe A, et al. ERCC1 and Ki67 in small cell lung carcinoma and other neuroendocrine tumors of the lung: distribution and impact on survival. *J Thorac Oncol* 2010;5:453-9.
71. Walts AE, Ines D, Marchevsky AM. Limited role of Ki-67 proliferative index in predicting overall short-term survival in patients with typical and atypical pulmonary carcinoid tumors. *Mod Pathol* 2012;25:1258-64.
72. Grimaldi F, Muser D, Beltrami CA, et al. Partitioning of bronchopulmonary carcinoids in two different prognostic categories by ki-67 score. *Front Endocrinol (Lausanne)* 2011;2:20. Epub 2011 Aug 19.
73. Sobin L, Gospodarowicz M, Wittekind C. *TNM Classification of Malignant Tumours*. New York: Wiley-Blackwell; 2010.
74. Rindi G, Kloppel G, Alhman H, et al. TNM staging of foregut (neuro)endocrine tumors: a consensus proposal including a grading system. *Virchows Arch* 2006;449:395-401.
75. Tang LH, Gonen M, Hedvat C, et al. Objective quantification of the Ki67 proliferative index in neuroendocrine tumors of the gastroenteropancreatic system: a comparison of digital image analysis with manual methods. *Am J Surg Pathol* 2012;36:1761-70.
76. Costes V, Marty-Ane C, Picot MC, et al. Typical and atypical bronchopulmonary carcinoid tumors: a clinicopathologic and KI-67-labeling study. *Hum Pathol* 1995;26:740-5.
77. Tsuta K, Kalhor N, Raso MG, et al. Oncocytic neuroendocrine tumors of the lung: histopathologic spectrum and immunohistochemical analysis of 15 cases. *Hum Pathol* 2011;42:578-85.

78. Warth A, Fink L, Fisseler-Eckhoff A, et al. Interobserver agreement of proliferation index (Ki-67) outperforms mitotic count in pulmonary carcinoids. *Virchows Arch* 2013;462:507-13.
79. Phan AT, Oberg K, Choi J, et al. NANETS consensus guideline for the diagnosis and management of neuroendocrine tumors: well-differentiated neuroendocrine tumors of the thorax (includes lung and thymus). *Pancreas* 2010;39:784-98.
80. Miller RR, Muller NL. Neuroendocrine cell hyperplasia and obliterative bronchiolitis in patients with peripheral carcinoid tumors. *Am J Surg Pathol* 1995;19:653-8.
81. Gosney JR, Williams IJ, Dodson AR, et al. Morphology and antigen expression profile of pulmonary neuroendocrine cells in reactive proliferations and diffuse idiopathic pulmonary neuroendocrine cell hyperplasia (DIPNECH). *Histopathology* 2011;59:751-62.
82. Rossi G, Cavazza A, Graziano P, et al. mTOR/p70S6K in diffuse idiopathic pulmonary neuroendocrine cell hyperplasia. *Am J Respir Crit Care Med* 2012;185:341; author reply -2.
83. Nassar AA, Jaroszewski DE, Helmers RA, et al. Diffuse idiopathic pulmonary neuroendocrine cell hyperplasia: a systematic overview. *Am J Respir Crit Care med*. 2011 1;184:8-16
84. Walker CM, Vummidi D, Benditt JO, et al. What is DIPNECH? *Clin Imaging* 2012;36:647-9
85. Koo CW, Baliff JP, Torigian DA, et al. Spectrum of pulmonary neuroendocrine cell proliferation: diffuse idiopathic pulmonary neuroendocrine cell hyperplasia, tumorlet, and carcinoids. *AJR Am J Roentgenol* 2010;195:661-8.
86. Schmitt AM, Riniker F, Anlauf M, et al. Islet 1 (Isl1) expression is a reliable marker for pancreatic endocrine tumors and their metastases. *Am J Surg Pathol*. 2008;32:420-5.
87. Hermann G, Konukiewitz B, Schmitt A et al. Hormonally defined pancreatic and duodenal neuroendocrine tumors differ in their transcription factor signatures: expression of ISL1, PDX1, NGN3, and CDX2. *Virchows Arch*. 2011;459:147-54.

88. Miremadi A, Pinder SE, Lee AH, et al. Neuroendocrine differentiation and prognosis in breast adenocarcinoma. *Histopathology* 2002;40:215-22.
89. Sapino A, Papotti M, Righi L, et al. Clinical significance of neuroendocrine carcinoma of the breast. *Ann Oncol* 2001;12 Suppl 2:S115-7.
90. Righi L, Volante M, Tavaglione V, et al. Somatostatin receptor tissue distribution in lung neuroendocrine tumors: a clinicopathologic and immunohistochemical study of 218 'clinically aggressive' cases. *Ann Oncol* 2010;21:548-55.
91. Ferolla, Faggiano A, Mansueto G et al, Biological Characterization of Neuroendocrine tumors: the role of Neuroendocrine markers *Journal of Endocrinological Investigation*. 2008; 31:277-86.
92. Bajetta E, Ferrari L, Martinetti A et al. Chromogranin A, neuron specific enolase, carcinoembryonic antigen, and hydroxyindole acetic acid evaluation in patients with neuroendocrine tumors. *Cancer*. 1999;86:858-865. 31
93. Baudin E, Gigliotti A, Ducreux M, et al. Neuron-specific enolase and chromogranin A as markers of neuroendocrine tumours. *Br J Cancer*. 1998;78:1102-7.
94. Lim E, Goldstraw P, Nicholson AG, et al. Proceedings of the IASLC International Workshop on Advances in Pulmonary Neuroendocrine Tumors 2007. *J Thorac Oncol*. 2008;3:1194-201
95. Öberg K, Hellman P, Ferolla P et al.; ESMO Guidelines Working Group. Neuroendocrine bronchial and thymic tumors: ESMO Clinical Practice Guidelines for diagnosis, treatment and follow-up. *Ann Oncol*. 2012;23 (S7):vii120-3
96. Daddi N, Ferolla P, Urbani M et al. Surgical treatment of neuroendocrine tumors of the lung. *Eur J Cardiothorac Surg* 2004; 26(4): 813–817.
97. Kaltsas G, Androulakis II, de Herder WW, et al Paraneoplastic syndromes secondary to neuroendocrine tumours. *Endocr Relat Cancer*. 2010;17:R173-93.

98. Thakker RV, Newey PJ, Walls GV et al. Clinical Practice Guidelines for Multiple Endocrine Neoplasia Type 1 (MEN1). *J Clin Endocrinol Metab.* 2012;97:2990-3011 .
99. Brandi ML, Gagel RF, Angeli A, et al. Guidelines for diagnosis and therapy of MEN type 1 and type 2, *J Clin Endocrinol Metab.* 2001;86:5658-71.
100. Jeung MY, Gasser B, Gangi A, et al. Bronchial carcinoid tumors of the thorax: spectrum of radiologic findings. *Radiographics.* 2002;22:351-65.
101. Meisinger QC, Klein JS, Butnor KJ et al. CT features of peripheral pulmonary carcinoid tumors. *AJR Am J Roentgenol.* 2011;197:1073-80
102. Schrevels L, Vansteenkiste J, Deneffe G et al. Clinical-radiological presentation and outcome of surgically treated pulmonary carcinoid tumors: a long-term single institution experience. *Lung Cancer.* 2004;43:39-45
103. García-Yuste M, Matilla JM, Cueto A, et al, and Members of the Spanish Multicenter Study of Neuroendocrine Tumors of the Lung by the Spanish Society of Pneumology and Thoracic Surgery (EMETNE-SEPAR). Typical and atypical carcinoid: analysis of the experience of the Spanish multicenter study of neuroendocrine tumors of the lung. *Eur J Cardio Thorac Surg* 2007; 31:192-197
104. Bhosale P, Shah A, Wei W et al. Carcinoid tumours: predicting the location of the primary neoplasm based on the sites of metastases. *Eur Radiol.* 2013;23:400-7.
105. Anders Sundin, Vullierme MP, Kaltsas G et al. ENETS Consensus Guidelines for the Standards of Care in Neuroendocrine Tumors: Radiological Examinations. *Neuroendocrinology* 2009;90:167–183.
106. Leboulleux S, Dromain C, Vataire AL et al, Prediction and diagnosis of bone metastases in well-differentiated gastro-entero-pancreatic endocrine cancer: a prospective

- comparison of whole body magnetic resonance imaging and somatostatin receptor scintigraphy. *J Clin Endocrinol Metab.* 2008;93:3021
107. Ambrosini V, Nanni C, Zompatori M et al (68)Ga-DOTA-NOC PET/CT in comparison with CT for the detection of bone metastasis in patients with neuroendocrine tumours. *Eur J Nucl Med Mol Imaging.* 2010;37:722-7
108. Granberg D, Sundin A, Janson ET et al Octreoscan in patients with bronchial carcinoid tumors. *Clin Endocrinol (Oxf).* 2003;59:793-799.
109. Abgral R, Leboulleux S, Déandreis D, et al Performance of (18)fluorodeoxyglucose-positron emission tomography and somatostatin receptor scintigraphy for high Ki67 ($\geq 10\%$) well-differentiated endocrine carcinoma staging. *J Clin Endocrinol Metab.* 2011;96:665-71.
110. Park CM, Goo JM, Lee HJ, et al. Tumors in the tracheobronchial tree: CT and FDG PET features. *Radiographics.* 2009;29:55-71;
111. Daniels CE, Lowe VJ, Aubry MC et al. The utility of fluorodeoxyglucose positron emission tomography in the evaluation of carcinoid tumors presenting as pulmonary nodules. *Chest.* 2007;131:255-60.
112. Pattenden H, Beddow E, Dusmet M, et al. Test performance of PET-CT for mediastinal lymph node staging of pulmonary carcinoid tumors. *J Clin Oncol* 2013;31:(suppl; abstr 7544).
113. Ambrosini V, Castellucci P, Rubello D, et al 68Ga-DOTA-NOC: a new PET tracer for evaluating patients with bronchial carcinoid. *Nucl Med Commun.* 2009;30:281-6
114. Gabriel M, Decristoforo C, Kendler D et al, 68Ga-DOTA-Tyr3-octreotide PET in neuroendocrine tumors: comparison with somatostatin receptor scintigraphy and CT. *J Nucl Med* 2007; 48: 508–518;

115. Kayani I, Conry BG, Groves AM et al. A comparison of 68Ga-DOTATATE and 18F-FDG PET/CT in pulmonary neuroendocrine tumors. *J Nucl Med.* 2009;50:1927-32
116. Srirajakanthan R, Kayani I, Quigley AM, et al The role of 68Ga-DOTATATE PET in patients with neuroendocrine tumors and negative or equivocal findings on 111In-DTPA-octreotide scintigraphy *J Nucl Med.* 2010;51:875-82.
117. Pfeifer A, Knigge U, Mortensen J, et al. Clinical PET of Neuroendocrine Tumors Using 64Cu-DOTATATE: First-in-Humans Study. *J Nucl Med.* 2012;53:1207-15;
118. Orlefors H, Sundin A, Garske U, et al Whole-body (11)C-5-hydroxytryptophan positron emission tomography as a universal imaging technique for neuroendocrine tumors: comparison with somatostatin receptor scintigraphy and computed tomography. *J Clin Endocrinol Metab.* 2005;90:3392-400
119. Rivera MP, Detterbeck F, Mehta AC; American College of Chest Physicians. Diagnosis of lung cancer: the guidelines. *Chest* 2003; 123(1 Suppl.): 129S–136S
120. Steinfort DP, Finlay M, Irving LB. Diagnosis of peripheral pulmonary carcinoid tumor using endobronchial ultrasound. *Ann Thorac Med.* 2008;3:146-8;
121. Sarraf KM, Belcher E, Price S, et al Clinical application of direct bronchial ultrasound to visualize and determine endobronchial tumor margins for surgical resection. *Ann Thorac Surg.* 2008;86:1339-41.
122. Banki F. Pulmonary assessment for general thoracic surgery. *Surg Clin North Am.* 2010;90:969-84.
123. Plockinger U, Gustafsson B, Ivan D, et al ENETS Consensus Guidelines for the Standards of Care in Neuroendocrine Tumors: Echocardiography *Neuroendocrinology* 2009;90:190–193.

124. . Cheitlin MD, Armstrong WF, Aurigemma GP et al. ACC/AHA/ASE 2003 guidelines uptake for the clinical application of echocardiograph: summary article. A report of the American College of Cardiology/American Heart Association Task Force on Practice Guidelines (ACC/AHA/ASE Committee to Update the 1997 Guidelines for the Clinical Application of Echocardiography). *J Am Soc Echocardiogr* 2003; 16:1091–1110.
125. Goldstraw P. International Association for the Study of Lung Cancer Staging Manual in Thoracic Oncology. Florida, USA: Editorial Rx Press; 2009.
126. Detterbeck, F.C., Management of carcinoid tumors. *Ann Thorac Surg*, 2010. 89:998-1005.
127. Lim E, Yap YK, De Stavola BL et al. The impact of stage and cell type on the prognosis of pulmonary neuroendocrine tumors. *J Thorac Cardiovasc Surg* 2005; 130: 969–972
128. Glazer, E.S., Tseng JF, Al-Refaie W et al., Long-term survival after surgical management of neuroendocrine hepatic metastases. *HPB (Oxford)*, 2010. 12:427-33.
129. Pavel, M., Baudin E, Couvelard A et al., ENETS Consensus Guidelines for the management of patients with liver and other distant metastases from neuroendocrine neoplasms of foregut, midgut, hindgut, and unknown primary. *Neuroendocrinology*, 2012. 95:157-76.
130. Okike, N., P.E. Bernatz, and L.B. Woolner, Carcinoid tumors of the lung. *Ann Thorac Surg*, 1976. 22:270-7.
131. Vadasz, P., Palffy G, Egervary M et al., Diagnosis and treatment of bronchial carcinoid tumors: clinical and pathological review of 120 operated patients. *Eur J Cardiothorac Surg*, 1993. 7: 8-11.
132. Hurt, R. and M. Bates, Carcinoid tumours of the bronchus: a 33 year experience. *Thorax*, 1984. 39:617-23.

133. Francioni, F., Rendina EA, Venuta F et al., Low grade neuroendocrine tumors of the lung (bronchial carcinoids)--25 years experience. *Eur J Cardiothorac Surg*, 1990. 4: p. 472-6.
134. Stamatis, G., L. Freitag, and D. Greschuchna, Limited and radical resection for tracheal and bronchopulmonary carcinoid tumour. Report on 227 cases. *Eur J Cardiothorac Surg*, 1990. 4:527-32; discussion 533.
135. Lim E, personal communication 2013
136. M. Beshay, T. Roth, R. Stein, R.A. Schmid: Synchronous bilateral typical pulmonary carcinoid tumors. *Eur.J.Cardiothorac.Surg*.2003;23:251–253
137. L. Spaggiari, G. Veronesi, R. Gasparri, et al.: Synchronous bilateral lung carcinoid tumors: a rare entity? *Eur.J.Cardiothorac.Surg*. 2003;24:334-337
138. Rea F, Rizzardi G, Marulli G, et al.: Metachronous bronchial carcinoid tumor. *Eur.J.Cardiothorac.Surg*. 2006;30:394-6
139. Brokx HA, Risse EK, Paul MA, et al. Initial bronchoscopic treatment for patients with intraluminal bronchial carcinoids. *J Thorac Cardiovasc Surg*. 2007;133: 973-8
140. Bertoletti L, Elleuch R, Kaczmarek D, et al. Bronchoscopic cryotherapy treatment of isolated endoluminal typical carcinoid tumor. *Chest*. 2006;130:1405-11.
141. Cavaliere S, Focoli P, Farina PL. Nd:YAG laser bronchoscopy. A five-year experience with 1,396 applications in 1,000 patients. *Chest*. 1988;94:15-21.
142. Cao, C., Yan TD, Kennedy C et al., Bronchopulmonary carcinoid tumors: long-term outcomes after resection. *Ann Thorac Surg*, 2011. 91:339-43139
143. Bertino, E.M., Confer PD, Colonna JE et al., pulmonaryeuroendocrine/carcinoid tumors: a review article. *Cancer*, 2009. 115:4434-41.

144. Oberg, K., Ferone D, Kaltsas G et al., ENETS Consensus Guidelines for the Standards of Care in Neuroendocrine Tumors: biotherapy. *Neuroendocrinology*, 2009. 90:209-13
145. Modlin, I.M., Pavel M, Kidd M et al., Review article: somatostatin analogues in the treatment of gastroenteropancreatic neuroendocrine (carcinoid) tumours. *Aliment Pharmacol Ther*, 2010. 31:169-88.
146. Filosso, P.L., Ruffini E, Oliaro A et al., Long-term survival of atypical bronchial carcinoids with liver metastases, treated with octreotide. *Eur J Cardiothorac Surg*, 2002. 21: 913-7.
147. Aparicio T, Ducreux M, Baudin E, et al. Antitumour activity of somatostatin analogues in progressive metastatic neuroendocrine tumours. *Eur J Cancer*. 2001;37:1014–9
148. Ducreux M, Ruzsniowski P, Chayvialle JA, et al. The antitumoral effect of the long-acting somatostatin analog lanreotide in neuroendocrine tumors. *Am J Gastroenterol*. 2000;95:3276–81.
149. Faiss S, Pape UF, Böhmig M, et al. Prospective, randomized, multicenter trial on the antiproliferative effect of lanreotide, interferon alfa, and their combination for therapy of metastatic neuroendocrine gastroenteropancreatic tumors—the International Lanreotide and Interferon Alfa Study Group. *J Clin Oncol*. 2003;21:2689–96
150. Rinke, A., Müller HH, Schade-Brittinger C et al., Placebo-controlled, double-blind, prospective, randomized study on the effect of octreotide LAR in the control of tumor growth in patients with metastatic neuroendocrine midgut tumors: a report from the PROMID Study Group. *J Clin Oncol*, 2009. 27: 4656-63.

151. Caplin M, Ruzsniowski P, Pavel M, et al. A randomized, double-blind, placebo-Controlled study of Lanreotide Antiproliferative Response in patients with gastroenteropancreatic NeuroEndocrine Tumors (CLARINET) . Paper presented at The European Cancer Congress, Amsterdam, Netherlands, 27 Sept-1 Oct 2013.
152. Steinmüller T, Kianmanesh R, Falconi M, et al. Consensus guidelines for the management of patients with liver metastases from digestive (neuro)endocrine tumors: foregut, midgut, hindgut, and unknown primary. *Neuroendocrinology* 2008;87:47-62.
153. Kos-Kudla B, O'Toole D, Falconi M, et al. ENETS Consensus Guidelines for the Management of Bone and Bronchial Metastases from Neuroendocrine Tumors. *Neuroendocrinology* 2010; 91 341-350.
154. Waldherr, C., Pless M, Maecke HR, et al., The clinical value of [90Y-DOTA]-D-Phe1-Tyr3-octreotide (90Y-DOTATOC) in the treatment of neuroendocrine tumours: a clinical phase II study. *Ann Oncol*, 2001. 12:941-5.
155. Imhof, A., Brunner P, Marincek N, et al., Response, survival, and long-term toxicity after therapy with the radiolabeled somatostatin analogue [90Y-DOTA]-TOC in metastasized neuroendocrine cancers. *J Clin Oncol*, 2011. 29:2416-23.
156. Kwekkeboom, D.J., de Herder WW, Kam BL, et al., Treatment with the radiolabeled somatostatin analog [177 Lu-DOTA 0,Tyr3]octreotate: toxicity, efficacy, and survival. *J Clin Oncol*, 2008. 26:2124-30.
157. van Essen, M., Krenning EP, Bakker WH, et al., Peptide receptor radionuclide therapy with 177Lu-octreotate in patients with foregut carcinoid tumours of bronchial, gastric and thymic origin. *Eur J Nucl Med Mol Imaging*, 2007. 34:1219-27.
158. Sun W, Lipsitz S, Catalano P, et al. Phase II/III study of doxorubicin with fluorouracil compared with streptozocin with fluorouracil or dacarbazine in the treatment of advanced carcinoid tumors: Eastern Cooperative Oncology Group Study E1281. *J Clin Oncol* 2005; 23 4897-4904.

159. Brizzi MP, Berruti A, Ferrero A, et al. Continuous 5-fluorouracil infusion plus long acting octreotide in advanced well-differentiated neuroendocrine carcinomas. A phase II trial of the Piemonte oncology network. *BMC Cancer* 2009; 9: 388.
160. Bajetta E, Catena L, Procopio G, et al. Are capecitabine and oxaliplatin (XELOX) suitable treatments for progressing lowgrade and high-grade neuroendocrine tumors? *Cancer Chemother Pharmacol* 2007; 59: 637-642.
161. Pavel, M., Grossman A, Arnold R et al., ENETS consensus guidelines for the management of brain, cardiac and ovarian metastases from neuroendocrine tumors. *Neuroendocrinology*, 2010. 91:326-32.
162. Kulke, M.H. and H. Scherubl, Accomplishments in 2008 in the management of gastrointestinal neuroendocrine tumors. *Gastrointest Cancer Res*, 2009. 3(5 Supplement 2): p. S62-6.
163. Granberg, D., Eriksson B, Wilander E et al., Experience in treatment of metastatic pulmonary carcinoid tumors. *Ann Oncol*, 2001. 12(10): p. 1383-91.
164. Turner NC, Strauss SJ, Sarker D, et al. Chemotherapy with 5-fluorouracil, cisplatin and streptozocin for neuroendocrine tumours. *Br J Cancer*. 2010;102:1106-12.
165. Meyer T, Qian W, Caplin ME, et al. Capecitabine and streptozocin ± cisplatin in advanced gastroenteropancreatic neuroendocrine tumours. *Eur J Cancer*. 2014 Jan 17. pii: S0959-8049(13)01105-2. doi: 10.1016/j.ejca.2013.12.011. [Epub ahead of print]
166. Wirth, L.J., Carter MR, Jänne PA et al., Outcome of patients with pulmonary carcinoid tumors receiving chemotherapy or chemoradiotherapy. *Bronchial Cancer*, 2004. 44:213-20.
167. Hay, N., The Akt-mTOR tango and its relevance to cancer. *Cancer Cell*, 2005. 8:179-83.

168. Yao, J.C., Shah MH, Ito T et al., Everolimus for advanced pancreatic neuroendocrine tumors. *N Engl J Med*, 2011. 364(6): p. 514-23.
169. Pavel, M.E., Hainsworth JD, Baudin E et al., Everolimus plus octreotide long-acting repeatable for the treatment of advanced neuroendocrine tumours associated with carcinoid syndrome (RADIANT-2): a randomised, placebo-controlled, phase 3 study. *Lancet*, 2011. 378:2005-12.
170. Enrique Grande, Daniel Castellano, Roc ío García-Carbonero, et al. PAZONET: A phase II trial of pazopanib as a sequencing treatment in progressive metastatic neuroendocrine tumors (NETs) patients (pts), on behalf of the Spanish Task Force for NETs (GETNE). Paper presented at ESMO, Vienna, 2012. Abstract 11570.
171. Pavel ME, Wiedenmann B, Capdevila J o, et al. RAMSETE: A single-arm, multicenter, single-stage phase II trial of RAD001 (everolimus) in advanced and metastatic silent neuroendocrine tumours in Europe. *J Clin Oncol* 30, 2012 (suppl; abstr 4122)
172. Raymond, E., Dahan L, Raoul JL et al., Sunitinib malate for the treatment of pancreatic neuroendocrine tumors. *N Engl J Med*, 2011. 364:501-13.
173. Kulke, M.H., Lenz HJ, Meropol NJ, et al., Activity of sunitinib in patients with advanced neuroendocrine tumors. *J Clin Oncol*, 2008. 26:3403-10.
174. Yao, J.C., Phan A, Hoff PM, et al., Targeting vascular endothelial growth factor in advanced carcinoid tumor: a random assignment phase II study of depot octreotide with bevacizumab and pegylated interferon alpha-2b. *J Clin Oncol*, 2008. 26:1316-23.
175. Castellano D, Capdevila J, Sastre J, et al. Sorafenib and bevacizumab combination targeted therapy in advanced neuroendocrine tumour: a phase II study of Spanish Neuroendocrine Tumour Group (GETNE0801). *Eur J Cancer*. 2013;49:3780-7.
176. Chan JA, Stuart K, Earle CC, et al. Prospective study of bevacizumab plus temozolomide in patients with advanced neuroendocrine tumors. *J Clin Oncol*. 2012;30:2963-8.

177. Karpathakis, A., M. Caplin, and C. Thirlwell, Hitting the target: where do molecularly targeted therapies fit in the treatment scheduling of neuroendocrine tumours? *Endocr Relat Cancer*, 2012. 19:R73-92.
178. Warren WH, Gould VE. Long-term follow-up of classical bronchial carcinoid tumors. Clinicopathologic observations. *Scand J Thorac Cardiovasc Surg* 1990; 24:125–130.

ENETS Consensus Group

* Detlief Bartsch, University of Marburg, Germany; Jaume Capdevila, Vall d'Hebron University Hospital, Spain; Frederico Costa, Hospital Sírio Libanês, Brazil; Jaroslaw Cwikla, Central Clinical Hospital of Ministry of Internal Affairs and Administration, Warsaw, Poland; Wouter de Herder, Erasmus University, Netherlands; Gianfranco Delle Fave, University of Roma, Italy; Barbro Eriksson, University of Uppsala, Sweden; Massimo Falconi, University of Milano, Italy; Diego Ferone, University of Genova, Italy; David Gross, Hadassah Hospital, Israel; Ashley Grossman, Churchill Hospital, Oxford, UK; Tetsuhide Ito, Kyushu University, Japan; Robert Jensen, National Institute of Health, Bethesda, USA; Gregory Kaltsas, National University of Athens, Greece; Fahrettin Kelestimur, Department of Endocrinology & Metabolism, School of Medicine, Kayseri, Turkey; Reza Kianmanesh, University of Reims, France; Ulrich Knigge, Rigshospitalet, Copenhagen, Denmark; Beata Kos-Kudla, Department of Pathophysiology and Endocrinology, Medical University of Silesia, Katowice, Poland; Eric Krenning, University of Erasmus, Netherlands; Emmanuel Mitry, Institut Curie, Paris, France; Marianne Nicolson, Aberdeen Royal Infirmary, Aberdeen, UK; Juan O'Connor, Alexander Fleming Institute, Buenos Aires, Argentina; Dermot O'Toole, St James's Hospital, St Vincent's University Hospital & Trinity College Dublin, Ireland; Ulrich-Frank Pape, Charite Hospital, Berlin, Germany; Marianne Pavel, Charite Hospital, Berlin, Germany; John Ramage, Basingstoke Hospital, UK; Eric Raymond, Beaujon University Hospital, Clichy, France, France; Guido Rindi, Università Cattolica-Policlinico A.Gemelli, Rome, Italy; Andrea Rockall, Imperial Hospital Trust, London, UK; Philippe Ruzniewski, Beaujon Hospital, France; Ramon Salazar, Institut Català D'Oncologia (IDIBELL), Barcelona, Spain; Aldo Scarpa, University and Hospital Trust of Verona, Italy; Eva Sedlackova, First Faculty of Medicine and General Teaching Hospital, Prague, Czech Republic; Anders Sundin, Uppsala University Hospital, Sweden; Christos Toumpanakis, Royal Free Hospital, London, UK; Marie-Pierre Vullierme, Beaujon Hospital, France; Wolfgang Weber, University Freiburg, Germany; Bertram Wiedenmann, Charite Hospital, Berlin, Germany; Zeng Zheng-Pei, Chinese Academy of Medical Sciences & Peking Union Medical College, Beijing, China.

Fig. 1 Algorithm for diagnosis of Pulmonary Neuroendocrine Tumor

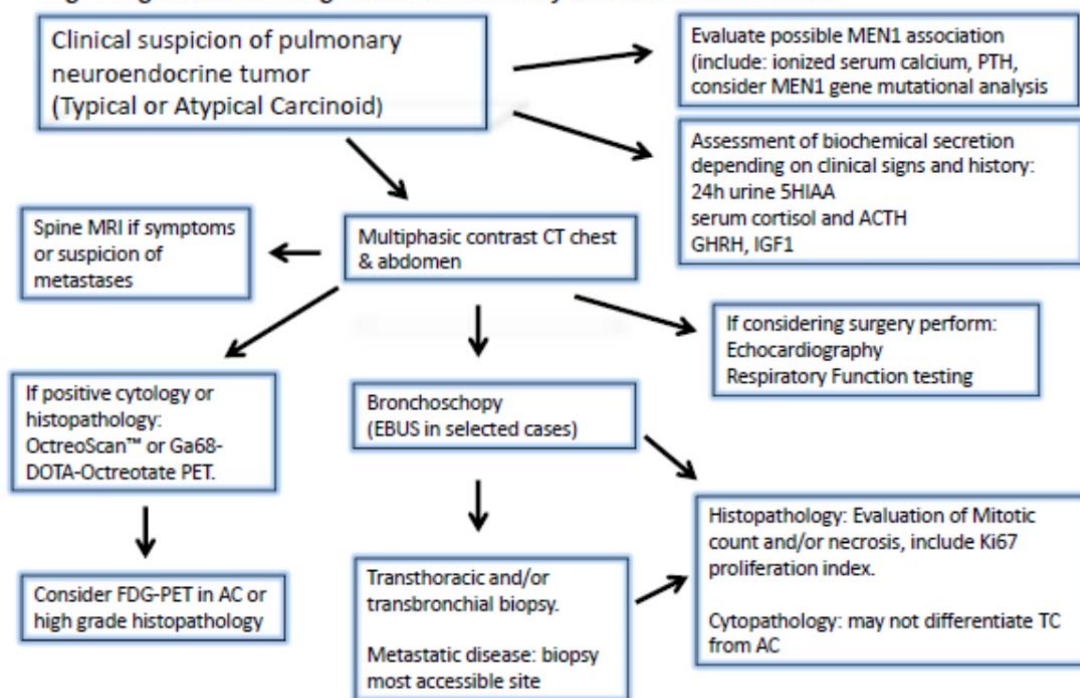


Fig. 2a ENETS recommendations for the control of hormone-related symptoms

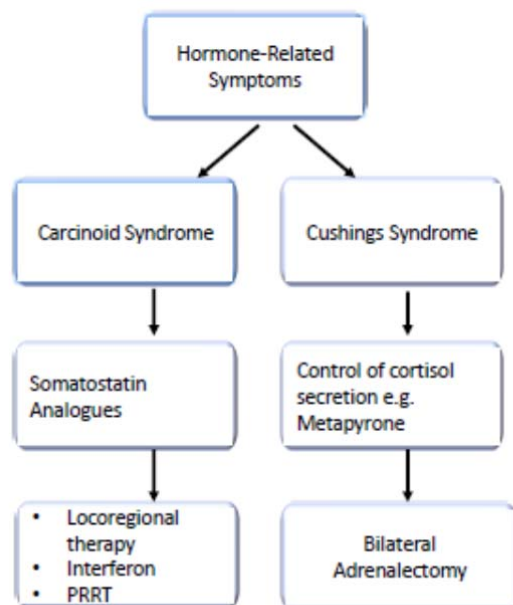


Fig. 2b ENETS recommendations for the control of hormone-related symptoms and tumor-growth.

*Progression is defined according to RECIST criteria

PRRT : peptide radiolabeled receptor radiotherapy

