

# Atrial septal aneurysm as a cardioembolic source in adult patients with stroke and normal carotid arteries

## A multicentre study

A. V. Mattioli<sup>1</sup>, M. Aquilina<sup>2</sup>, A. Oldani<sup>2</sup>, C. Longhini<sup>3</sup> and G. Mattioli<sup>1</sup> on behalf of the Investigators\*

<sup>1</sup>Department of Cardiology, University of Modena, Modena, Italy; <sup>2</sup>Department of Cardiology, Pierantoni Hospital, Forlì, Italy; <sup>3</sup>School of Medicine, University of Ferrara, Ferrara, Italy

**Background** Atrial septal aneurysm has been considered a potential source of cardiogenic embolism for many years. The present study evaluated the prevalence and characteristics of atrial septal aneurysm in a patient population with stroke and normal carotid arteries compared to a control population without stroke.

**Methods** A total of 606 patients were enrolled between November 1990 and December 1996. The study group included 245 patients who had experienced cerebral ischaemic attack but had normal carotid arteries. The control group included 316 age- and sex-matched patients undergoing transoesophageal echocardiography for indications other than a search for a cardiac source of embolism. The prevalence and morphological characteristics of atrial septal aneurysm were evaluated and compared.

**Results** We reported a higher prevalence of atrial septal aneurysm in the group with cerebral ischaemia; 68 patients (27.7%) vs 36 patients (9.9%) from the control group;  $P < 0.001$ . A patent foramen ovale was detected with contrast injection in 69.2% of the patients with atrial septal aneurysm. Atrial septal aneurysm predicted the presence of

a patent foramen ovale (odds ratio of patent foramen ovale 4.2; 95% CI 1.03–9.8). Multivariate analysis showed that atrial septal aneurysm was an independent predictor of an embolic event. In the 95% of patients with atrial septal aneurysm and cerebral ischaemia aged less than 45 years, transoesophageal echocardiography did not detect a source of embolism other than an associated patent foramen ovale.

**Conclusions** The prevalence of atrial septal aneurysm in patients with cerebral ischaemia and normal carotid arteries was 27.7%, higher than the control group. Atrial septal aneurysm was frequently associated with patent foramen ovale. In patients less than 45 years old, atrial septal aneurysm was the only potential cardiac source of embolism detected with transoesophageal echocardiography. (Eur Heart J 2001; 22, 261–268, doi:10.1053/ehj.2000.2293) © 2001 The European Society of Cardiology

**Key Words:** Stroke, atrial septal aneurysm, transoesophageal echocardiography, carotid ultrasound.

See page 198 for the Editorial comment on this article

## Introduction

Atrial septal aneurysm has been considered a potential cardiac source of embolism in recent years, but the role of atrial septal aneurysm as a risk factor is poorly defined<sup>[1–4]</sup>. Contrasting data have been recently pub-

lished. In a multicentre study Mugge and co-workers reevaluated the clinical significance of atrial septal aneurysm in a large series of patients using transoesophageal echocardiography. The authors concluded that atrial septal aneurysm could be considered a risk factor for cardiogenic embolism in a significant subgroup of patients<sup>[5]</sup>. A paper from the Mayo Clinic underlined the higher frequency of atrial septal aneurysm in patients evaluated with transoesophageal echocardiography after a cerebral ischaemic event<sup>[6]</sup>. In contrast Burger and co-workers, in a prospective long-term study, suggested that the risk of cerebrovascular events is low in a patient population with incidental atrial septal aneurysm<sup>[7]</sup>.

Revision submitted 21 April 2000, and accepted 24 May 2000.

\*The list of investigators is in [Appendix 1](#).

Correspondence: Anna Vittoria Mattioli, MD, Department of Cardiology, University of Modena, Via del pozzo, 71, 41100 Modena, Italy.

**Table 1 Clinical indications for transoesophageal echocardiography in Group B patients**

	Group B no patients (%)
Endocarditis	90 (25)
Aortic disease	50 (14)
Valve function (except mitral stenosis)	108 (30)
Tumour and mass	36 (10)
Lack of thoracic windows	18 (5)
Miscellaneous	59 (16)

These conflicting data are probably the result of the different selection of patients.

In the present prospective study, adult patients with normal carotid arteries affected by cerebral ischaemia underwent transoesophageal echocardiography in order to evaluate possible cardioembolic causes. The purpose of this study was to assess the frequency and morphology of atrial septal aneurysm in patients undergoing transoesophageal echocardiography after an unexplained cerebral ischaemia. The possible mechanisms of cardioembolism are considered.

## Methods

### *Patient population*

Between November 1990 and December 1996, 245 of 458 patients referred to the three institutions with a clinical and instrumental diagnosis of cerebral ischaemic attack were included in the study if they had normal carotid arteries (group A).

Inclusion criteria were: echocardiographic images of sufficient quality to allow measurements of morphological characteristics of atrial septal aneurysm, a previous cerebral ischaemic attack, carotid stenosis of less than 15%. Exclusion criteria were: chronic atrial fibrillation, mitral prosthesis and mitral stenosis, evidence of mass or haemorrhage on a CT scan of the head. These patients were compared with 316 age- and sex-matched patients (246 males, mean age  $59.7 \pm 23$  years, range 19–86) who underwent transoesophageal echocardiography examination during the same period for indications other than cerebral ischaemia (group B). The two groups were similar (Table 1).

### *Neurological evaluation*

In the study population (group A), a trained neurologist established a definite clinical diagnosis of transient ischaemic attack or stroke<sup>[8,9]</sup>. A computed tomographic scan (CT) was performed in all patients and was evaluated by a trained neuroradiologist (P.C.). Magnetic resonance imaging was performed in selected cases (100 of the 245 patients). Cerebral ischaemia was defined as

follows<sup>[10]</sup>: stroke: sudden development of a permanent focal neurological deficit after which a brain CT scan establishes a cerebrovascular accident as a cause; reversible ischaemic attack with complete or almost complete recovery without the need for therapeutic rehabilitation; transient ischaemic attack, which is completely resolved in 24 h; reversible ischaemic neurological deficit in which there is full clinical recovery within 7 days.

A cardioembolic source was suspected on clinical findings, brain imaging and on normal duplex carotid ultrasound examination.

### *Echocardiography*

All patients underwent complete transthoracic and transoesophageal echocardiography studies. In group A patients the examinations were performed 1 to 7 days after the cerebral ischaemic event. A commercial Hewlett Packard system with 2.5 and 3.5 MHz probes and a 5 MHz multiplane frequency probe with colour Doppler and spectral pulsed Doppler was used. Standard views from the gastric and lower oesophageal windows were obtained in every patient. All patients who underwent transoesophageal echocardiography were given diazepam and pharyngeal xilocaine.

### *Echocardiographic criteria for cardiac embolic source*

Thrombus in the left atrium or appendage was defined as the presence of a clearly defined intracavitary mass acoustically distinct from the underlying endocardium. It was not caused by the pectinate ridges of the left atrial appendage.

Spontaneous echo contrast was defined as dynamic, smokelike echoes with a characteristic swirling motion, distinct from the echoes caused by excessive gain.

Patent foramen ovale was defined as the presence of 'echo-dropout' in the atrial septum, visualized in at least two different planes. Inter-atrial shunts were diagnosed by contrast echocardiography using a rapid hand injection of a 5 cc solution of emagel injected through an antecubital vein. Injection was repeated for each patient during a Valsalva manoeuvre. The appearance of microbubbles in the left atrium was considered diagnostic of right to left shunt.

Complex aortic atherosclerosis was defined as a thickening of the intima with marked irregularities and disruption<sup>[11]</sup>.

### *Criteria and classifications for atrial septal aneurysm*

Atrial septal aneurysm was defined as a bulging >15 mm beyond the plane of the atrial septum as measured by transoesophageal echocardiography. Atrial septal

**Table 2** Clinical characteristics of patients comparison between the 2 groups

	Group A 245 patients	Group B 361 patients	P
Mean age (years)	65.7 ± 21	62.7 ± 23	ns
Male/female	168/77	246/115	ns
Hypertension	31.8%	29.9%	ns
Heart disease	14.2%	13.8%	ns
Previous episodes of atrial fibrillation	17.1%	12.1%	ns
Echocardiographic EF (%)	61.1 ± 18	59 ± 20	ns
Doppler A wave velocity (m . s <sup>-1</sup> )	0.63 ± 0.21	0.61 ± 0.17	ns
Doppler E wave velocity (m . s <sup>-1</sup> )	0.54 ± 0.19	0.57 ± 0.23	ns
LA size (mm)	38 ± 0.9	39 ± 0.8	ns

ASA=atrial septal aneurysms; EF=ejection fraction; LA=left atrial.

aneurysm was classified according to Hanley's diagnostic criteria, modified by Pearson to include type 1C<sup>[12,13]</sup>.

The type of aneurysm was determined according to morphology and bulging:

- type 1A: constant protrusion towards the right atrium
- type 1B: protrusion predominantly to the right with movement towards the left atrium in systole
- type 1C: protrusion towards the left atrium with Valsalva
- type 2C: fixed protrusion towards the left atrium

The following parameters were also evaluated: length of the atrial septal aneurysm (>15 mm), maximal protrusion of the atrial septal aneurysm beyond the plane of the atrial septum, direction of the maximal protrusion, oscillation of the atrial septal aneurysm during a normal respiratory cycle, thickening of the atrial septal aneurysm.

### Carotid ultrasonography

Carotid ultrasonography was performed using a 7.5 MHz linear array probe. Transversal and longitudinal images were obtained with 2D, colour and pulsed Doppler imaging. Categories of carotid disease were based on published criteria: normal (<1% stenosis), 1% to 15% stenosis, 16% to 49% stenosis, 50% to 79% stenosis, 80% to 99% stenosis, and complete occlusion<sup>[14]</sup>. Patients were excluded from the study if they presented with a stenosis in excess of 15%.

### Statistical analysis

Continuous variables are presented as means ± SD. The prevalence of transoesophageal echocardiographic findings between groups was accomplished using chi-square analysis. A comparison of continuous variables was performed using unpaired t-tests. Echocardiographic variables were screened by the log-rank test to identify those associated with stroke. Variables with significant independent predictive values were identified. A hazard ratio is defined as the relative likelihood of developing

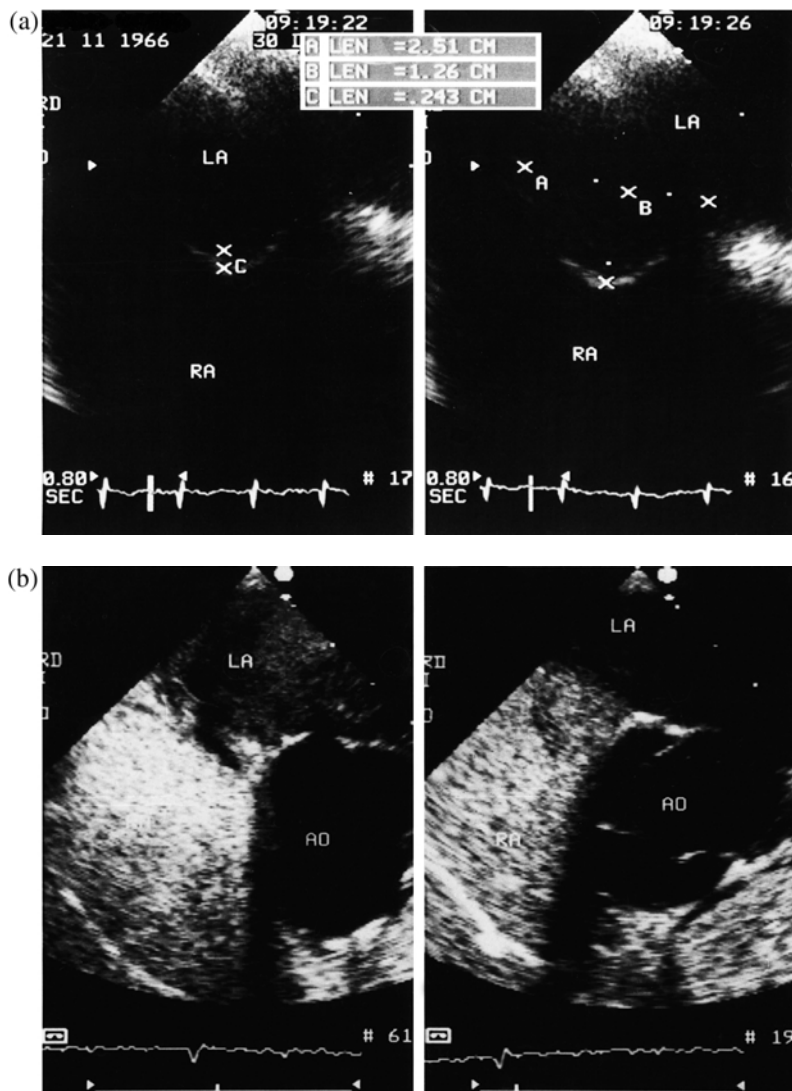
ischaemic events. Multivariate regression analysis, performed with the Cox proportional-hazards model, was applied to all variables that had at least a marginal univariate predictive value ( $P < 0.10$ ). Variables with significant independent predictive values ( $P < 0.05$ ) were identified.

The Ethical Committee study of our university approved the study protocol and informed consent was obtained from all participants.

## Results

The study population included 168 men and 77 women, of mean age 65.7 ± 21 years, range 35–86 years. Of the 245 patients of group A, 130 had transient ischaemic attack and 115 had stroke. A computed tomographic scan was performed in all patients and was evaluated by a trained neuroradiologist (P.C.) All patients had a negative head CT scan for a haemorrhagic event. A CT scan was considered diagnostic for an ischaemic event in 97% of patients. The ischaemic event involved the carotid circulation in 164 patients (69%) and the vertebro-basilar territory in 81 patients (33%). All patients had a Doppler carotid study that excluded significant carotid artery stenosis (>50%). The control group included 316 patients, 246 males and 115 females, with a mean age of 62.7 ± 23 years, who had undergone transoesophageal echocardiography for reasons other than evaluation of cardioembolic stroke (Table 1). The clinical characteristics of patients are shown in Table 2.

A transthoracic examination was performed in all 561 patients (study group and controls) and demonstrated an atrial septal aneurysm in 61 patients (10.8%); 45 patients (18.3%) were from group A and 16 patients (5.06%) from group B ( $P < 0.001$ ). Transoesophageal echocardiography revealed an atrial septal aneurysm in 104 patients ( $P < 0.05$  compared to transthoracic study); 68 patients (27.7%) were from group A and 36 (9.9%) from group B ( $P < 0.001$ ). The prevalence of patent foramen ovale was 22.8% in patients of group A and 9.8% in patients of group B ( $P < 0.001$ ). Of the 58 patients of group A with patent foramen ovale, 33 patients (58.9%) had shunts at rest and the remaining



**Figure 1** (a) Transoesophageal echocardiogram from a 19 years old patient from group B with an atrial septal aneurysm (type 1A). (b) The same patient during contrast injection after Valsalva release. There is a massive shunt (on the left).

patients had shunt during Valsalva (Fig. 1(a, b)). Patent foramen ovale was found in 72 patients (69.2) with atrial septal aneurysm. The prevalence of aortic atherosclerosis increased with age and was highest in the descending aorta (Table 3).

With respect to atrial septal aneurysm characteristics: length of atrial septal aneurysm, maximal extent of protrusion, predominant side of bulging and incidence of spontaneous oscillation, we did not observe any difference between the two groups (Table 4).

The variables that were significantly different between the two groups were the thickness of the aneurysmatic wall ( $3.88 \pm 1.4$  mm in group A vs  $2.78 \pm 1$  mm in group B;  $P < 0.01$ ) (Fig. 2) and the association with interatrial shunts (Table 4, Fig. 2). The presence of atrial septal aneurysm predicted the presence of patent foramen ovale (odds ratio of patent foramen ovale 4.2;

95% CI 1.03–9.8). The other potential sources of embolism in the two groups are shown in Table 2. Group A showed a higher prevalence of left atrial thrombi and spontaneous echocontrast. Mitral annulus calcifications were more frequent in group A.

Statistical analysis revealed that the presence of thrombus in the left atrium (odds ratio 4.2, 95% CI 2.7–7.8,  $P < 0.01$ ), mitral annulus calcification (odds ratio 2.8, 95% CI 3.3–12.5,  $P < 0.05$ ), paradoxical shunt (odds ratio 3.3, 95% CI 1.8–6.5,  $P < 0.05$ ) and atrial septal aneurysm (odds ratio 3.0, 95% CI 1.8–4.8,  $P < 0.05$ ) were independent predictors of ischaemic events.

In the 50 patients younger than 45 years with ischaemic cerebral events, atrial septal aneurysm was the only possible cardioembolic source in 43 subjects (86%). In 42 patients (97%) with atrial septal aneurysm and cerebral ischaemia we found an associated patent foramen

**Table 3** Prevalence of potential cardioembolic sources in the transoesophageal echocardiography study in the two groups of patients

Cardioembolic source	Group A no patients (%)	Group B no patients (%)	P
Without cardiac source	30 (12.2)	123 (38.9)	<0.01
Thrombus in LA or AU	25 (10)	9 (2.8)	<0.01
Spontaneous echo contrast	40 (16)	29 (9.2)	<0.05
Ascending aorta atherosclerosis	13 (5.3)	17 (4.7)	ns
Aortic arch atherosclerosis	43 (17.5)	58 (16)	ns
Descending aorta atherosclerosis	61 (25)	90 (25)	ns
Vegetations	3 (1.2)	8 (2.5)	ns
Mitral valve disease	27 (11)	48 (15)	ns
Mitral annulus calcifications	24 (9.7)	5 (1.6)	0.05
Atrial septal aneurysm	68 (27.7)	36 (9.9)	0.001
Patient foramen ovale	56 (22.8)	31 (9.8)	0.001
Inter-atrial shunt	60 (24.4)	63 (17.4)	ns

LA=left atrium, AU=appendage.

**Table 4** Characteristics of atrial septal aneurysms as determined by transoesophageal echocardiography

	Group A 68 patients	Group B 36 patients	P
Length of ASA (mm)	26.3 ± 7.4	21.3 ± 6.8	ns
Extent of protrusion (mm)	13.3 ± 2.1	14.1 ± 3.2	ns
Oscillation present (n)	32	21	ns
Type 1A, n (%)	10 (14.7)	5 (13.8)	ns
Type 1B, n (%)	42 (61.7)	24 (66.6)	ns
Type 1C, n (%)	12 (17.6)	5 (13.8)	ns
Type II, n (%)	4 (5.8)	2 (5.5)	ns
Thickness (mm)	3.88 ± 1.4	2.78 ± 1.0	<0.01
Association with PFO, n (%)	50 (73.5)	22 (61.1)	<0.05
Association with mitral valve prolapse, n (%)	19 (27.9)	9 (25)	ns

ASA=atrial septal aneurysm; PFO=patent foramen ovale.

ovale. Mitral valve prolapse was common in this subgroup of patients; it was found in 30 patients (60%), and was associated with atrial septal aneurysm in 10 subjects (33%).

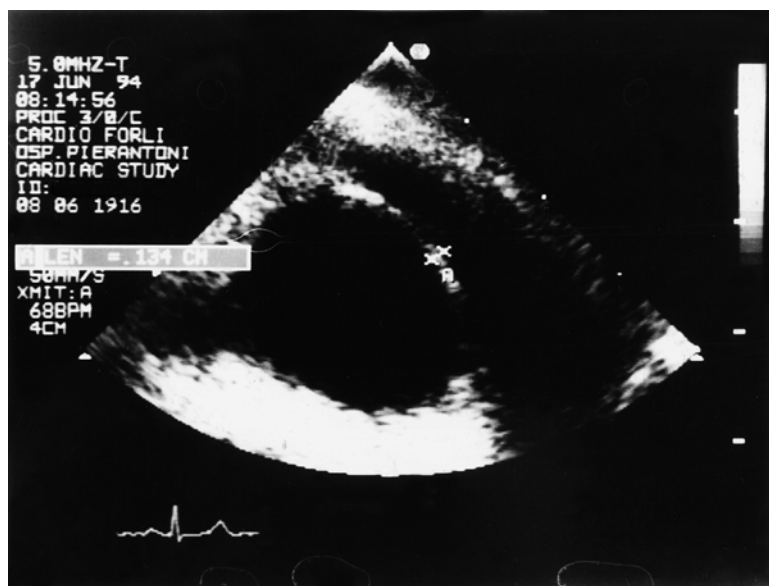
## Discussion

The present study evaluated the prevalence of atrial septal aneurysm in a population with stroke and normal carotid arteries. We wanted to evaluate the role of atrial septal aneurysm in cerebral ischaemia without other cardiac source. Patients were compared with an age- and sex-matched control population that underwent transoesophageal echocardiography examination for different indications. The first conclusion is that cardioembolic sources are more common in patients with previous stroke, and atrial septal aneurysm was more frequent in the studied population. Multivariate analysis showed that atrial septal aneurysm was an independent predictor of embolic events. The second conclusion is that atrial septal aneurysm was the only potential

cardiac embolic source in the 86% of patients younger than 45 years.

Aneurysm of the inter-atrial septum is a rare finding in adult populations. The clinical impact of this cardiac anomaly is uncertain, but several papers suggest a potential role in cardioembolic stroke<sup>[5,6]</sup>. Many authors observed that a number of patients with atrial septal aneurysm presented cerebral ischaemic events, which were otherwise unexplained<sup>[2,4,15]</sup>. A study from Nighoghossian *et al.* found atrial septal aneurysm in the 34.5% of the 79 patients who had an unexplained stroke<sup>[15]</sup>. The incidence of atrial septal aneurysm in the normal population is controversial. Many reasons explain this difference: different diagnostic criteria, methodology used, age of patients and lack of recognition. A recent study on stroke prevention in a community found that the prevalence of atrial septal aneurysm in a population without previous ischaemic events was 2.2%<sup>[6,16]</sup>. These data are in agreement with the estimated incidence of atrial septal aneurysm in transoesophageal cohorts that varied from 2 to 10%<sup>[2,17,19]</sup>. We found a significantly higher proportion of atrial septal aneurysm in





**Figure 2** Transoesophageal echocardiogram of a 26-year-old patient from group A with an atrial septal aneurysm bulging into the left atrium during inspiration (type 1B). The thickness of the aneurysmatic membrane is 0.65 cm.

patients with cerebral ischaemia than in the control population. This finding supports the hypotheses that atrial septal aneurysm is an independent risk factor for cerebral ischaemia. In patients aged less than 45 years atrial septal aneurysm was more frequent and was the only cardiac embolic source in a large proportion of subjects.

#### *Relationship between atrial septal aneurysm and cerebral ischaemia*

A link between atrial septal aneurysm and cerebral ischaemic events was first suggested by a retrospective study on the basis of anecdotal data<sup>[18]</sup>. Subsequent multicentre studies confirmed this relationship<sup>[5,19]</sup>. These studies lack an adequate non-selected control group. The SPARC study assessed the frequency of atrial septal aneurysm in a general population and compared the results with a selected population undergoing transoesophageal echocardiography in search of cardiac sources of embolism<sup>[6]</sup>. This study supports the relationship between atrial septal aneurysm and cerebral ischaemia, and the authors suggested a mechanism of right to left shunting through a patent foramen ovale<sup>[5,6,16]</sup>.

#### *Morphological types of atrial septal aneurysm*

The prevalence of the different types vary in the different studies; type 1A aneurysm was found in 40% of the cases

studied at the Mayo Clinic, but in only 6% of Pearson's cases<sup>[11,12]</sup>. In the present study, type 1B was the most frequent type of aneurysm and occurred in 59%. There was no significant difference between the study group and controls. These data are consistent with the literature<sup>[12]</sup>.

A potential embolic mechanism is related to thrombus stratification on the aneurysmatic membrane; Schneider *et al.* reported that a thickness of >5 mm was associated with a significantly higher embolic risk<sup>[20]</sup>. The increased thickening suggests that atrial aneurysm can be a nidus for thrombus formation<sup>[1]</sup>. In contrast, Pearson found that thickness was greater in the group of patients without stroke<sup>[13]</sup>. Mugge and co-workers did not exclude the possibility that micro-thrombi can be attached to the atrial septal aneurysm<sup>[5]</sup>. We found that thickness was increased in the stroke group. This verifies one of the most reliable pathogenetic hypotheses which has been supported by anecdotal findings demonstrating thrombotic material within the aneurysmal sac in patients during autopsy or surgery<sup>[21,22]</sup>.

#### *Association with other findings*

Many authors have documented an association with patent foramen ovale<sup>[17,18,20,23,24]</sup>. The induction of a paradoxical shunt using the Valsalva manoeuvre during transoesophageal echocardiography must be underlined; it occurred in three of our patients who experienced cerebral embolization during their physiological functions. A patent foramen ovale was detected with contrast injection in 22.8% of patients with atrial septal

aneurysm. The presence of atrial septal aneurysm predicted the presence of patent foramen ovale. The association with mitral valve prolapse has a high frequency<sup>[5,15,24]</sup>. Nevertheless, it was not significantly prevalent in the study group. This is possibly explained by the high incidence of such a condition in elderly patients, who were not included in this study, since they had a plaque in the ipsilateral carotid circulation.

### Clinical impact and management

The diagnosis of atrial septal aneurysm by transoesophageal echocardiography in a patient who had experienced an ischaemic attack may alter patient management. Patients with atrial septal aneurysm have a recurrent event rate of 14% to 20% at 3 years<sup>[4,25]</sup>. Preliminary data from Spes and co-workers suggest that patients with atrial septal aneurysm have a lower recurrent stroke rate with warfarin than with antiplatelet agents<sup>[26]</sup>. In contrast Burger *et al.* suggested that aspirin appears to be effective therapy in patients with atrial septal aneurysm without previous cerebral events<sup>[7]</sup>. The association with patent foramen ovale strongly increases the risk of recurrent episodes<sup>[26]</sup>. Preliminary studies suggest that the recurrence rate can be reduced by mechanical closure of the patent foramen ovale<sup>[27,28]</sup>. There are no data on atrial septal aneurysm and surgical intervention or even if this technique has been suggested for young patients with no other reason for stroke.

### Conclusion

Transoesophageal echocardiography is a useful and reliable technique in the evaluation of patients with stroke with normal carotid arteries. An important cardioembolic source appears to be atrial septal aneurysm, due to its overwhelming prevalence in the group of patients with stroke. The increase in thickness of the aneurysmal membrane, which should, in theory, be thinner than normal, was evident in patients with stroke, strengthening the theory of the stratified thrombus with increased embolic risk. The clinical management of patients with stroke and normal carotid vessels presenting atrial septal aneurysm will include anticoagulant or antiplatelet therapy. In addition, in young patients subject to transient ischaemic attack relapse, surgical intervention should be considered. Further studies are needed not only to determine the natural history of ecocardiographically detected abnormalities but also to evaluate treatment options.

### References

[1] Manning WJ. Role of transoesophageal echocardiography in the management of thromboembolic stroke. *Am J Cardiol* 1997; 80 (4C): 19D–28D.

- [2] Pearson AC, Labovitz AJ, Tatiene S, Gomez CR. Superiority of transoesophageal echocardiography in detecting cardiac source of embolism in patients with cerebral ischemia of uncertain etiology. *J Am Coll Cardiol* 1991; 17: 66–72.
- [3] Labovitz AJ for the STEPS Investigators. Transoesophageal Echocardiography and unexplained cerebral ischemia: a multicenter follow-up study. *Am Heart J* 1999; 137: 1082–7.
- [4] Rahmatullah AF, Rahko PS, Stein JH. Transoesophageal echocardiography for the evaluation and management of patients with cerebral ischemia. *Clin Cardiol* 1999; 22: 391–6.
- [5] Mugge A, Daniel WG, Angermann C *et al.* Atrial septal aneurysm in adult patients: a multicenter study using transthoracic and transoesophageal echocardiography. *Circulation* 1995; 91: 2785–92.
- [6] Agmon Y, Khandheria BK, Meissner I *et al.* Frequency of Atrial Septal Aneurysms in Patients with Cerebral Ischemic Events. *Circulation* 1999; 99: 1942–4.
- [7] Burger AJ, Sherman HB, Charlamb MJ. Low incidence of embolic strokes with atrial septal aneurysms: A prospective, long term study. *Am Heart J* 2000; 139: 149–52.
- [8] Mattioli AV, Tarabini Castellani E, Carpeggiani P, Mattioli G. Heart and brain. *Cardiologia* 1994; 39: 487–95.
- [9] Mattioli AV, Tarabini Castellani E, Mattioli G. Stroke in paced patients with sick sinus syndrome: influence of left atrial function and size. *Cardiology* 1999; 91: 150–5
- [10] Cerebral Embolism Task Force. Cardiogenic brain embolism: the second report of Cerebral Embolism Task Force. *Arch Neurol* 1989; 46: 727–43.
- [11] Seward JB, Khandheria BK, Oh JK *et al.* Transoesophageal echocardiography: technique, anatomic correlation, implementations and clinical applications. *Mayo Clin Proc* 1988; 63: 649–80.
- [12] Hanley PC, TajiK AJ, Hynes JK *et al.* Diagnosis and classification of atrial septal aneurysm by two-dimensional echocardiography: report of 80 consecutive cases. *J Am Coll Cardiol* 1985; 6: 1370–82.
- [13] Pearson A, Nagelhout D, Castello R, Gomez CR, Labovitz AJ. Atrial septal aneurysm and stroke: a transoesophageal echocardiographic study. *J Am Coll Cardiol* 199; 18: 1223–9.
- [14] Strandness DE. Duplex Scanning in Vascular Disorders. New York, NY: Raven Press, 1990: 92–120.
- [15] Nighoghossian N, Perinetti M, Barthelet M, Adeleine P, Trouillas P. Potential cardioembolic sources of stroke in patients less than 60 years of age. *Eur Heart J* 1996; 17: 590–4.
- [16] Meissner I, Whisnant JP, Khandheria BK *et al.* Prevalence of Potential Risk Factors for Stroke Assessed by Transoesophageal Echocardiography and Carotid Ultrasonography: The SPARC Study. *Mayo Clin Proc* 1999; 74: 862–9.
- [17] Zabalgoitia M, Herrera C, Gandhi DK, Mehlmán DJ, McPherson D, Talano JV. A possible mechanism for neurologic ischemic events in patients with atrial septal aneurysm. *Am J Cardiol* 1990; 15: 761–4.
- [18] Belkin RN, Hurwitz BJ, Kisslo J. Atrial septal aneurysm: association with cerebrovascular and peripheral embolic events. *Stroke* 1987; 18: 856–62.
- [19] Marazanof M, Roudaut R, Cohen A *et al.* Atrial Septal Aneurysm: morphologic characteristics in a large population: pathological associations: a French multicenter study on 259 patients investigated by transoesophageal echocardiography. *Int J Cardiol* 1995; 52: 59–65.
- [20] Schneider B, Harath P, Vogel P, Meinertz T. Improved morphologic characterization of atrial septal aneurysm by transoesophageal echocardiography: relation to cerebrovascular events. *J Am Coll Cardiol* 1990; 16: 1000–9.
- [21] Silver MD, Dorsey JS. Aneurysms of the septum primum in adults. *Arch Pathol Lab Med* 1978; 102: 62–5.
- [22] Grosgeat Y, Lhermitte F, Carpentier A, Facquet J, Alhomme P, Tran TX. Aneurysme da le cloison interauriculaire revele par une embolie cerebrale. *Arch Mal Coeur* 1973; 66: 169–77.
- [23] Cabanes L, Mas JL, Cohen A *et al.* Atrial septal aneurysm and patent foramen ovale as risk factors for cryptogenic

- stroke in patients less than 55 years of age. *Stroke* 1993; 24: 1865–73.
- [24] Lechat P, Lascault G, Mas JL *et al.* Prevalence of patent foramen ovale in young patients with ischemic cerebral complications. *Arch Mal Coeur* 1989; 82: 847–52.
- [25] Iliceto S, Papa A, Sorino M, Rizzon P. Combined atrial septal aneurysm and mitral valve prolapse: detection by two-dimensional echocardiography. *Am J Cardiol* 1984; 54: 1151–3.
- [26] Spes CH, Mugge A, Daniel WG *et al.* Follow-up of embolic events in patients after diagnosis of atrial septal aneurysm (abstr). *J Am Coll Cardiol* 1996; 27: 161A.
- [27] Stone DA, Godard J, Corretti MC *et al.* Patent foramen ovale: association between the degree of shunt by contrast transesophageal echocardiography and the risk of future ischemic neurologic events. *Am Heart J* 1996; 131: 158–61.
- [28] Ende DJ, Chopra PS, Rao PS. Transcatheter closure of atrial septal defect or patent foramen ovale with the buttoned device for prevention of recurrence of paradoxical embolism. *Am J Cardiol* 1996; 78: 233–6.

## Appendix 1

### *Investigators:*

Patrizia Limonetti, MD; Paola Venturi, MD; Maurizio Milandri, MD (*Forlì*), Emma Tarabini Castellani, MD PhD (*Department of Cardiology, Modena*), Paolo Carpeggiani MD (*Department of Neuroradiology, Modena*).