

Single Case – General Neurology

Intracranial Stenosis Treated with Stenting in Patients with Suspected Cerebral Vasculitis: Two Case Reports

Gabriele Vandelli^{a,b} Laura Giacobazzi^{a,b} Ludovico Ciolli^{a,b}
Maria Luisa Dell'Acqua^{a,b} Laura Vandelli^a Livio Picchetto^a
Francesca Rosafio^a Giuseppe Maria Borzi^a Riccardo Ricceri^a
Stefano Meletti^{a,b} Stefano Vallone^c Carlo Salvarani^{d,e}
Marco Sebastiani^d Federico Sacchetti^c Luca Verganti^c
Stefano Merolla^c Gabriele Zelent^c Guido Bigliardi^a

^aNeurology Clinic, Stroke Unit, Ospedale Civile di Baggiovara, Azienda Ospedaliero-Universitaria di Modena, Modena, Italy; ^bDepartment of Biomedical, Metabolic and Neural Sciences, University of Modena and Reggio Emilia, Modena, Italy; ^cNeuroradiology, Ospedale Civile di Baggiovara, Azienda Ospedaliero-Universitaria di Modena, Modena, Italy; ^dRheumatology Unit, University of Modena and Reggio Emilia, Azienda Ospedaliero-Universitaria di Modena, Modena, Italy; ^eRheumatology Unit, IRCCS Arcispedale Santa Maria Nuova, Azienda Unità Sanitaria Locale-IRCCS di Reggio Emilia, Modena, Italy

Keywords

Stroke · Endovascular treatment · Management of stroke patient · Vasculitis · Angioplasty and stenting

Abstract

Central nervous system vasculitis (CNSV) is an uncommon and poorly understood form of vasculitis. Early recognition is important because medical treatment might improve the outcome. However, randomized clinical trials on CNSV treatment do not exist. Endovascular treatment has been reported in few cases, but no data exist for intracranial stenting. We report 2 cases of patients with suspected CNSV and recurrent clinical episodes, treated with intracranial stenting. A 48-year-old man had relapsing episodes of right hemiparesis. Neuroradiological exams showed severe left carotid terminus stenosis. Despite immunosuppressive therapy, neuroradiological follow-up exams showed a worsening of the aforementioned stenosis with many transient episodes of weakness in the right limbs and aphasia. A 64-year-old woman had a sudden onset of dysarthria and transient aphasia. Neuroradiological exams showed a severe arterial stenosis involving the origin of left anterior cerebral artery and middle cerebral artery (MCA). Despite dual antiplatelet therapy, she presented an acute onset of severe aphasia, due to an occlusion of the left carotid terminus and proximal MCA. In both cases, endovascular

Correspondence to:
Guido Bigliardi, bigliardi.guido@aou.mo.it

procedure and intracranial stenting was performed, with marked improvement of cerebral blood flow. No more clinical episodes were reported. Intracranial stenting may be a valid therapeutic option in selected patients with CNSV and involvement of medium or large size vessels with clinical worsening despite best medical treatment.

© 2023 The Author(s).
Published by S. Karger AG, Basel

Introduction

Central nervous system vasculitis (CNSV) is an uncommon and poorly understood form of vasculitis characterized by inflammation of the arterial vessel wall of the central nervous system, associated with destructive changes in the structure of the vessels, occlusion, and infarction [1]. The median age of onset is 50 years. The neurological manifestations generally consist of headache (the most common symptom), aphasia, altered cognition, seizures, TIA, or stroke. Clinical manifestations at diagnosis are nonspecific, and the onset of disease can be acute-subacute, slowly progressive, or relapsing and remitting [2].

The biopsy of cerebral tissue is the only definitive test for the diagnosis [3]. Because of the invasive nature of biopsy, angiography has often been used for diagnosis of probable SNC vasculitis. Angiographic changes highly suggestive of vasculitis are alternating areas of narrowing and post-stenotic dilatation of cerebral arteries or arterial occlusions in cerebral vessels [4], typically without atherosclerosis in the cervical arteries. Also new neuroimaging techniques, like “black blood” MR sequences, are most frequently used to study intracranial blood vessels in order to detect wall vessels inflammation [5].

Early recognition is important because the treatment with corticosteroids and immunosuppressants can prevent serious outcomes and remain the core of the treatment [6]. However, randomized clinical trials of CNSV treatment do not exist and are needed [7].

Endovascular treatment for intracranial vasculitis has been reported in some cases of giant cell arteritis (GCA) [8, 9] and in a case of a refractory postinfectious vasculitis secondary to pneumococcal meningitis [10]. No data exist for intracranial stenting in isolated CNSV. We report 2 cases of patients with suspected CNSV and recurrent episodes of neurological symptoms, treated with intracranial stenting.

Case 1

A 48-year-old man came to our attention for some relapsing episodes of right hemiparesis. He had also reported many episodes of involuntary movements in the right arm for about 2 weeks before the hospital admission and other episodes of loss of consciousness, without prodromes and with spontaneous recovery. His medical history was unremarkable; in particular, he had no history of headache, hypertension, dyslipidemia, diabetes mellitus, or stroke. He was a current smoker (30 packages/years) and overweight (BMI 33 kg/m²). He did not take any therapy.

During his first hospital access, the non-contrast brain CT (NCCT) and the electroencephalogram showed no abnormalities and he refused the hospitalization. A few days later, for the persistence of the recurrent symptoms, he returned to the hospital. The neurological evaluation showed very mild right hemiparesis and myoclonic-like episodes in the right limbs (probably limb-shaking TIA). Atrial fibrillation was also detected, and

anticoagulant therapy with low-molecular-weight heparin was started, and the patient was admitted to our ward. Neurological examination was completely negative after a few hours.

A transcranial color-coded duplex (TCCD), a CT angiography, and an MR angiography were performed and showed multiple severe intracranial arterial stenosis involving the left carotid terminus, the right carotid terminus, the anterior and the posterior cerebral artery bilaterally, with post-stenotic aneurysmal dilatations (Fig. 1a). Diffusion-weighted images revealed no recent ischemic infarction or signs suggestive of encephalitis. Additional MRI with perfusion sequences showed an area with prolonged mean transit time in the left hemisphere, without evidence of ischemic core. The “black-blood” T1-weighted images showed strong contrast enhancement in the left carotid terminus, particularly in the cavernous and petrous segments.

A brain angiography was subsequently performed, confirming the suspicion of cerebral arteritis, with involvement of the large- and medium-sized cerebral vessels. Further exams were performed, including total-body CT-positron emission tomography scanning, and no findings suggestive for an extracranial vessel inflammatory involvement were detected. Other causes of secondary vasculitis were excluded. The biopsy of the temporal artery was not suggestive for GCA. Blood tests showed no signs of systemic inflammation or coagulopathy; toxicological screening was negative. Transthoracic echocardiography did not reveal any pathological findings, except for a mild left ventricular hypertrophy. Duplex sonography of supra-aortic trunks revealed no significant stenosis in the cervical arteries. Lumbar puncture was performed, analysis of cerebrospinal fluid (CSF) was normal, and isoelectric focusing showed a polyclonal pattern. PCR for HSV 1-2, varicella-zoster virus, Epstein-Barr virus, adenovirus, parvovirus B19, *Enterovirus*, cytomegalovirus, and *Borrelia burgdorferi* was negative. Serological screening for vasculitis like rheumatic factors, complement C3/C4, antinuclear antibody, antineutrophil cytoplasmic antibody, angiotensin-converting enzyme, lymphocyte typing was negative. No neoplasm was found during neoplastic screening (colonoscopy, testicular ultrasound, blood neoplastic markers, abdomen tomography, peripheral blood film). Chest tomography showed only mild emphysema findings, and gastroscopy showed an erosive gastritis with duodenal ulcer, with negative *Helicobacter pylori* research. Biopsy of the lesion was not typical for neoplasm, and PPI therapy was started. The quantiFERON test was positive, but no signs of acute TBC pathology were found. Blood exams revealed mild hyperthyroidism, and a thyrostatic therapy with Tapazole was started.

Neuropsychological tests showed alterations in visual, spatial, and verbal learning skills, with a deficit in language tests, but a limitation related to the significant language barrier was present. The rheumatological evaluation confirmed the suspicion of probable primary angiitis of CNS, and the patient was treated with a high dose of intravenous corticosteroids (with successive prednisone at daily dose 1 mg/kg) and mycophenolate mofetil (2,000 mg/daily). Because of immunosuppressant therapy, for the patient who was positive for the quantiFERON test, a preventive therapy with isoniazid was started.

Despite the immunosuppressant therapy, neurosonological and neuroradiological follow-up exams showed a worsening of the aforementioned stenosis, especially in the left carotid terminus. Brain MRI follow-up showed new small acute ischemic lesions in the left middle cerebral artery (MCA) territory. During the hospitalization, the patient complained of numerous transient episodes of severe weakness in the right limbs and aphasia, many of them evoked by postural changes and arterial hypotension, with spontaneous regression and no paroxysmal activity at the EEGs.

This clinical evolution occurred under combined therapy with a high dose of steroids, immunosuppressant, and antithrombotic therapy, and a new brain CT perfusion exam showed a worsening of the left hemispherical hypoperfusion (Fig. 1b). After a multidisciplinary

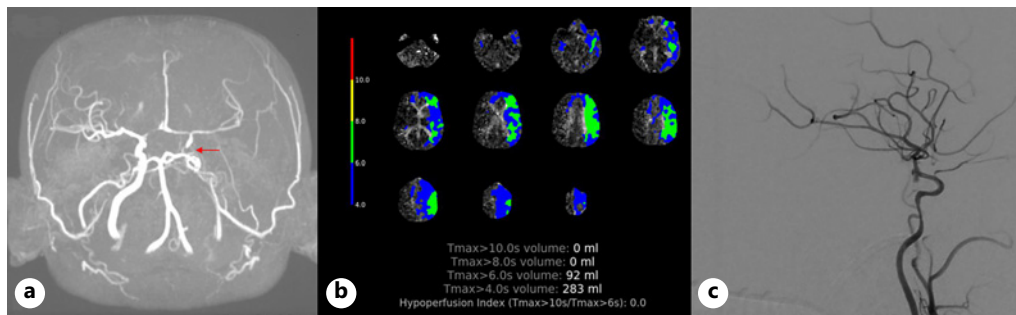


Fig. 1. **a** MR angiography: occlusion of the left intracranial tract of the internal carotid artery and multiple severe intracranial stenosis. **b** CT perfusion: large area of ischemic penumbra in the territory of the left MCA. **c** Angiography: complete recanalization after intracranial stenting in distal carotid siphon-left MCA.

evaluation with an interventional neuroradiologist, a treatment of intracranial stenting of the left carotid siphon was purposed. Dual antiplatelet therapy with Cardioaspirin and clopidogrel was started, and anticoagulant was stopped.

The endovascular procedure was performed 30 days after the first DSA angiography and after the initiation of immunosuppressive therapy, in general anesthesia. First angiographic sequences confirmed the complete occlusion of the carotid terminus on the left side and a marked slowing of the flow on the sylvian branches of the ipsilateral MCA. An intracranial stent, Solitaire[®] (Medtronic), was positioned from the distal tract of the carotid siphon to the first tract of the MCA on the left side, without any procedural complication (Fig. 1c).

After the procedure, CT perfusion showed a marked improvement, with no more hypoperfusion areas in the left hemisphere, and no more clinical episodes of hemiparesis or aphasia were reported. Moreover, transcranial color Doppler ultrasound revealed a strong improvement in left MCA blood flow.

At discharge, neurological evaluation was normal. Anticoagulation therapy with apixaban was started in association with dual antiplatelet therapy.

Case 2

A 64-year-old woman came to our attention, admitted as a stroke code for a sudden onset of dysarthria, aphasia, and mild right facial palsy. In ER, she showed a clear improvement in speech disturbance and a partial improvement in the facial disease (NIHSS: 2). Brain NCCT showed a focal ischemic hypodensity in the left corona radiata, not datable, and a mild chronic ischemic leukoaraiosis. CT angiography showed a segmental severe arterial stenosis involving the origin of A1 and the proximal tract of MCA on the left side. The CTP study revealed an oligoemia in the left frontoparietal regions, without clear ischemic lesions. Because of the non-disabling symptoms and the clinical improvement, thrombolytic treatment was not performed. The patient was admitted to our Stroke Unit, and a double antiplatelet therapy with acetylsalicylic acid and clopidogrel was started. The patient presented a complete regression of the symptoms, and the control brain CT was unmodified.

For the presence of severe stenosis in the left A1 and M1 tracts, TCCD controls were performed and confirmed severe tight stenosis with PSW flow acceleration over 400 cm/s in the middle segment of left M1, proximal flows at low limits of the normal range, and slightly demodulated distal flows. Coagulation screening was negative. Furthermore, antinuclear

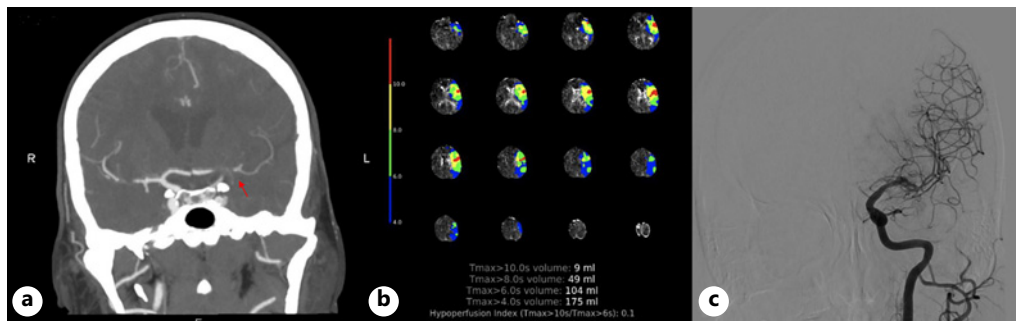


Fig. 2. **a** CT angiography: severe stenosis in the A1 tract of the left ACA and occlusion of the M1 tract of the left MCA. **b** CT perfusion: large area of ischemic penumbra in the territory of the left MCA. **c** Angiography: complete recanalization after intracranial stenting from the distal carotid siphon to the M1 segment of the left MCA. ACA, anterior cerebral artery.

antibody positivity was detected (1:320). In the light of these findings, an angiographic study was performed, which confirmed a marked focal severe stenosis of the M1 segment of the left MCA and showed a focal occlusion of the anterior cerebral artery in its A1 tract, resulting in a slowing of the flow in the parietal and occipital territories on the left side. Afterward, a brain MRI was performed, which revealed cortical and subcortical ischemic lesions at different times of evolution in the frontal and parietal lobe on the left side, one of them showing contrast medium enhancement, referable to barrier damage. In the post-contrast “black-blood” sequence, evidence of modest wall enhancement in the left carotid terminus, in the proximal tract of M1 of the MCA and in the A1 tract of the ipsilateral anterior cerebral artery, referable to inflammatory phenomena, is found.

An extended infectious disease screening showed positive IgM for *Borrelia* (with negative serology on CSF), positive IgG for *Enterovirus*, and reduced level of angiotensin-converting enzyme. Diagnostic lumbar puncture was performed, with evidence of xanthochromic CSF (due to the subarachnoid hemorrhage), mild increased level of proteins in CSF, and hypercellularity with a prevalence of granulocytes (15 cells/ μ L). Viral PCRs on CSF were negative, as well as serologies and immunoblots for herpes virus and *Borrelia*. Isoelectric focusing showed a polyclonal IgG pattern.

Seventeen days after the first CTA, the hospitalization was complicated by an acute onset of production aphasia. A brain CT, a CT angiography, and a CT perfusion study were repeated, with evidence of complete occlusion of the terminal segment of the left ICA and of the proximal M1 segment of the ipsilateral MCA, compatible with occlusion in correspondence with the known pre-occlusive stenosis of the left MCA (Fig. 2a). The CT perfusion documented a large area of ischemic penumbra in the territory of the left MCA (Fig. 2b). The patient was treated with endovascular treatment, and an intracranial stent Solitaire[®] (Medtronic) was positioned in correspondence with the ophthalmic tract of the ICA and the M1 tract of the left MCA (Fig. 2c). The XperCT performed after the procedure showed spontaneous hyperdensity in correspondence with some fronto-temporo-parietal subarachnoid spaces on the left and in correspondence of the sylvian and suprasellar, perimesencephalic, peripontine, and homolateral ambiens cisterns. Post-procedure brain NCCT confirmed the presence of subarachnoid hemorrhage and revealed a left temporal intraparenchymal hematoma, without any neurosurgical indication. For the presence of subarachnoid and intraparenchymal hemorrhage, an electroencephalogram was performed, which showed a slowing of electrogenesis in the left hemisphere, associated with slow irritative activity on the posterior ipsilateral regions; in the NREM sleep phase, epileptic anomalies appear on the same regions. Antiepileptic therapy with lacosamide was then started. The patient showed a progressive clinical improvement

with the persistence of mild aphasia, characterized by phonemic and semantic paraphasias, but with understandable speech.

A brain NCCT showed almost complete resolution of the previously described subarachnoid blood suffusion and a reduction of the left intraparenchymal temporal and temporo-mesial hematoma. Therapy with acetylsalicylic acid was reintroduced and, after the lumbar puncture, also clopidogrel with good response to laboratory tests. Stent controls with TCCD documented regular intrastent flows and turbulences in correspondence with M2 branches. Diagnostic angiography was repeated and showed mild stenosis of two branches of the M2 segment, without any flow reductions. Intra-arterial administration of nimodipine for a suspected vasospasm reaction resulted in a resolution of the stenosis of the superior division branch and residual stenosis of the lower division branch. Oral nimodipine therapy was started, with a progressive improvement of intracranial flows.

Speech therapy evaluation documented the presence of a mild language deficit, gradually improving. Neuropsychological evaluation showed mild multidomain amnesic MCI of vascular etiology.

Rheumatologic evaluation was suggestive for suspected cerebral vasculitis, and azathioprine was started. No further episodes were reported.

Discussion

The diagnosis and the management of CNSV is often arduous and challenging, underlying the importance of a multidisciplinary team that includes a neurologist, rheumatologist, neuroradiologist, and interventional neuroradiologist. No randomized clinical trials of management in CNSV exist. The strategies of treatment are primarily derived from case reports and cohort studies that reported the effectiveness of immunosuppressants and corticosteroids [11].

Empirical corticosteroids therapy is the milestone of first-line treatment. When patients fail to respond, cyclophosphamide or other immunosuppressive agents are usually added [12].

However, large-vessel involvement more than medium- and small-size vessel involvement is significantly associated with a poor response to treatment [13]. No studies about endovascular treatment with stenting in CNSV are reported in the literature. We found a single case report that showed efficacy of bilateral intracranial stenting for refractory postinfectious cerebral vasculitis. Similar treatment with endovascular angioplasty and stenting is also reported to be effective in patients with GCA [14, 15]. In our cases, a diagnosis of GCA was excluded.

In this article, the two cases reported show how endovascular treatment with stenting could be a possible successful therapy also in patients with suspected CNS vasculitis without a clear benefit of first-line medical treatment and with a progression of cerebral hypoperfusion related to severe-subocclusive intracranial stenosis and related to recurrent symptoms. In our cases, endovascular treatment was proposed for hemodynamic instability, recurrent clinical events, and severe worsening of hypoperfusion despite the best medical treatment.

CT perfusion after stenting shows a significant improvement of brain hypoperfusion, and no more recurrent clinical events are reported. Further evaluations are necessary, especially with a long-term follow-up because the progression of inflammatory vessel changes could lead to a potential high risk of stent reocclusion.

Conclusion

Intracranial stenting may be a valid therapeutic option in selected patients with CNSV and with involvement of medium- or large-size vessels. Stenting may be considered in

patients with neuroradiological and clinical worsening despite being the best medical treatment. The CARE Checklist has been completed by the authors for this case report, attached as online supplementary material (for all online suppl. material, see <https://doi.org/10.1159/000529942>).

Statement of Ethics

Ethical approval is not required for this study in accordance with local or national guidelines. Written informed consent was obtained from both patients for publication of these two case reports and any accompanying images.

Conflict of Interest Statement

The authors have no conflicts of interest to declare.

Funding Sources

There are no sources of funding to report.

Author Contributions

Gabriele Vandelli and Laura Giacobazzi (first authors) have made substantial contributions to conception and design, have been involved in drafting the manuscript and revising the manuscript, and have given final approval for the version to be published and share first authorship. Guido Bigliardi, as the corresponding author, takes primary responsibility for communication with the journal during the manuscript submission and publication process. Ludovico Ciolli, Maria Luisa Dell'Acqua, Laura Vandelli, Livio Picchetto, Francesca Rosafio, Giuseppe Maria Borzì, Riccardo Ricceri, Stefano Meletti, Stefano Vallone, Carlo Salvarani, Marco Sebastiani, Federico Sacchetti, Luca Verganti, Stefano Merolla, and Gabriele Zelent have been involved in revising the manuscript and giving the final approval.

Data Availability Statement

All data generated or analyzed during this study are included in this article and the supporting files. Further inquiries can be directed to the corresponding author.

References

- 1 Lie JT. Primary (granulomatous) angiitis of the central nervous system: a clinicopathologic analysis of 15 new cases and a review of the literature. *Hum Pathol*. 1992;23(2):164–71.
- 2 Salvarani C, Brown RD Jr, Hunder GG. Adult primary central nervous system vasculitis. *Lancet*. 2012 Aug 25; 380(9843):767–77.
- 3 Rice CM, Scolding NJ. The diagnosis of primary central nervous system vasculitis. *Pract Neurol*. 2020;20(2): 109–14.
- 4 Chen SH, Sur S, Sedighim S, Kassi A, Yavagal D, Peterson EC, et al. Utility of diagnostic cerebral angiography in the management of suspected central nervous system vasculitis. *J Clin Neurosci*. 2019 Jun;64:98–100.

- 5 Kalashnikova LA, Dobrynina LA, Legenko MS. Primary central nervous system vasculitis. *Zh Nevrol Psikhiatr Im S S Korsakova*. 2019;119(8):113–23.
- 6 Byram K, Hajj-Ali RA, Calabrese L. CNS Vasculitis: an approach to differential diagnosis and management. *Curr Rheumatol Rep*. 2018;20(7):37.
- 7 Kraemer M, Berlit P. Primary central nervous system vasculitis: an update on diagnosis, differential diagnosis and treatment. *J Neurol Sci*. 2021;424:117422.
- 8 Neutel D, Biscoito L, Campos J, e Melo TP, Albuquerque L. Giant cell arteritis with symptomatic intracranial stenosis and endovascular treatment. *Neurol Sci*. 2014;35(4):609–10.
- 9 Togo M, Kono T, Hoshi T, Imamura H, Todo K, Adachi H, et al. Successful endovascular therapy for multiple intracranial arterial stenosis associated with medically intractable giant cell arteritis. *J Neurol Sci*. 2018 Jan 15; 384:104–6.
- 10 Dargazanli C, De la Cruz E, Gaillard N, Costalat V, Arquizan C. Bilateral intracranial stenting for refractory post-infectious cerebral vasculitis secondary to Pneumococcal Meningitis. *J Neuroradiol*. 2021 Mar;48(2):132–6.
- 11 Cupps TR, Moore PM, Fauci AS. Isolated angiitis of the central nervous system. Prospective diagnostic and therapeutic experience. *Am J Med*. 1983 Jan;74(1):97–105.
- 12 Godasi R, Pang G, Chauhan S, Bollu PC. Primary central nervous system vasculitis. 2022 Oct 12. In: [StatPearls \[Internet\]](#). Treasure island (FL): StatPearls Publishing; 2022 Jan.
- 13 Salvarani C, Pipitone N, Hunder GG. Management of primary and secondary central nervous system vasculitis. *Curr Opin Rheumatol*. 2016 Jan;28(1):21–8.
- 14 Dementovych N, Mishra R, Shah Q. Angioplasty and stent placement for complete occlusion of the vertebral artery secondary to giant cell arteritis. *J Neurointerv Surg*. 2012 Mar;4(2):110–3.
- 15 Guerrero AM, Sierra-Hidalgo F, Calleja P, Navia P, Campollo J, Díaz-Guzmán J. Intracranial internal carotid artery angioplasty and stenting in giant cell arteritis. *J Neuroimaging*. 2015 Mar–Apr;25(2):307–9.