

Diving Into the Blue: A Case of Melanoma Arising in a Giant Congenital Blue Nevus During Pregnancy

Alex Curti¹, Simonetta Piana², Maria Banzi³, Fabio Castagnetti⁴, Michela Lai^{1,5,6},
Caterina Longo^{1,5}

1 Department of Dermatology, University of Modena and Reggio Emilia, Modena, Italy

2 Pathology Unit, Azienda Unità Sanitaria Locale - IRCCS di Reggio Emilia, Reggio Emilia, Italy

3 Medical Oncology Unit, Azienda Unità Sanitaria Locale - IRCCS di Reggio Emilia, Italy

4 Breast Surgery Unit, Azienda Unità Sanitaria Locale - IRCCS di Reggio Emilia, Italy

5 Centro Oncologico ad Alta Tecnologia Diagnostica, Azienda Unità Sanitaria Locale - IRCCS di Reggio Emilia, Italy

6 Clinical and Experimental Medicine PhD Program, University of Modena and Reggio Emilia, Modena, Italy

Citation: Curti A, Piana S, Banzi M, Castagnetti F, Lai M, Longo C. Diving Into The Blue: A Case Of Melanoma Arising In A Giant Congenital Blue Nevus During Pregnancy. *Dermatol Pract Concept*. 2023;13(1):e2023059. DOI: <https://doi.org/10.5826/dpc.1301a59>

Accepted: August 23, 2022; **Published:** January 2023

Copyright: ©2023 Curti et al. This is an open-access article distributed under the terms of the Creative Commons Attribution-NonCommercial License (BY-NC-4.0), <https://creativecommons.org/licenses/by-nc/4.0/>, which permits unrestricted noncommercial use, distribution, and reproduction in any medium, provided the original authors and source are credited.

Funding: None.

Competing Interests: None.

Authorship: All authors have contributed significantly to this publication.

Corresponding Author: Caterina Longo, Centro Oncologico ad Alta Tecnologia Diagnostica - Dermatologia, Azienda Unità Sanitaria Locale - IRCCS di Reggio Emilia, Reggio Emilia, Italy. Department of Dermatology, University of Modena and Reggio Emilia, Italy. Phone: +390522295611 E-mail: longo.caterina@gmail.com

Case Presentation

Melanoma is the most frequent malignancy in pregnancy, accounting for 31% of malignant tumors diagnosed during gestation [1].

We report a case of a 28-year-old woman, pregnant at the 34th week of gestation, who had periodical skin check examination for the presence of a congenital blue nevus involving the neck, the scalp and the preauricular region (Figure 1A). During pregnancy, she self-reported the development of a solid subcutaneous 4.2 cm firm mass on her right latero-cervical region (inset).

Histological examination was consistent with melanoma developed on a congenital melanocytic blue nevus (Figure 1B). The marked melanocytic atypia and the high mitotic count allowed the differential diagnosis with a proliferative nodule in congenital nevi. At the molecular

analysis, the melanoma showed no alterations in *BRAF*, *c-Kit* and all *RAS*. *GNAQ* and *GNA11* mutation state was not evaluated since it is not part of our standard of care panel.

After the induction of delivery at the 38th week of gestation, histological examination of the placenta ruled out possible secundarism to the fetus.

A total body CT scan of the patient identified four solid lesions in the liver, histologically confirmed as metastasis. Final diagnosis of stage IV melanoma was made.

After a multidisciplinary discussion of the case, immunotherapy with nivolumab was started at a dosage of 240 mg iv every two weeks.

After one year of systemic treatment, the patient achieved a complete response and since the response is still maintained after four years follow up, immunotherapy has now been discontinued.

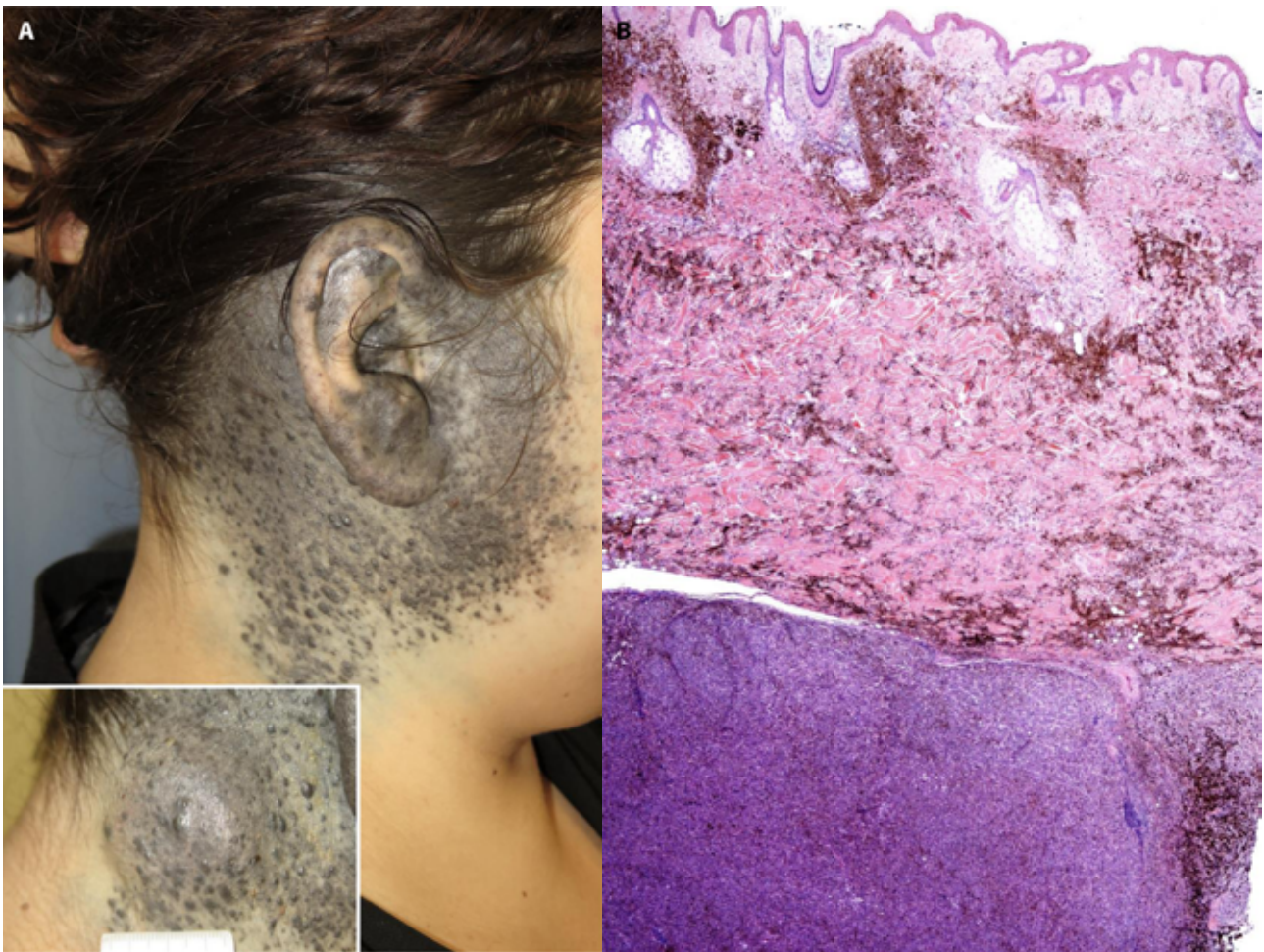


Figure 1. (A) Clinical picture of a giant congenital blue nevus, involving the right latero-cervical region and extending to preauricular skin and to the scalp; (inset) clinical picture showing a firm solid mass, developed during pregnancy on the right latero-cervical region on congenital blue nevus. (B) Skin and soft tissue biopsy specimen showing intensely pigmented fusiform proliferation of melanocytes with mitotic figures and necrosis, finding consistent with melanoma.

Teaching Point

European guidelines for the management of melanoma during pregnancy are still lacking, hence it is extremely challenging to decide the correct diagnostic and therapeutic approach to adopt. A multidisciplinary management is warranted and each case must be discussed on an individual patient-tailored basis [2].

References

1. Kyrgidis A, Lallas A, Moscarella E, Longo C, Alfano R, Argenziano G. Does pregnancy influence melanoma prognosis? A meta-analysis. *Melanoma Res.* 2017;27(4):289–299. DOI: 10.1097/CMR.0000000000000334. PMID: 28430756.
2. Ribero S, Longo C, Dika E, et al. Pregnancy and melanoma: a European-wide survey to assess current management and a critical literature overview. *J Eur Acad Dermatol Venereol.* 2017;31(1):65–69. DOI: 10.1111/jdv.13722. PMID: 27231086.