This is the peer reviewd version of the followng article:

Nivolumab-induced cholangitic liver disease: A novel form of serious liver injury / Gelsomino, Francesco; Vitale, Giovanni; D'Errico, Antonietta; Bertuzzi, Clara; Andreone, Pietro; Ardizzoni, Andrea. - In: ANNALS OF ONCOLOGY. - ISSN 0923-7534. - 28:3(2017), pp. 671-672. [10.1093/annonc/mdw649]

Terms of use:

The terms and conditions for the reuse of this version of the manuscript are specified in the publishing policy. For all terms of use and more information see the publisher's website.

12/10/2024 07:42

(Article begins on next page)

Annals of Oncology Advance Access published December 19, 2016

Letter to the Editor

Nivolumab-induced cholangitic liver disease: a novel form of serious liver injury.

F. Gelsomino[1*§], G. Vitale[2§], A. D'Errico[3], C. Bertuzzi[3], P. Andreone[2], A. Ardizzoni[1]

[1] Medical Oncology Unit, Policlinico S.Orsola-Malpighi, Bologna, Italy

[2] Department of Medicine and Surgery Science, Policlinico S.Orsola-Malpighi, University of Bologna, Bologna, Italy

[3] Addari Institute of Oncology and Transplant Pathology, Policlinico S.Orsola-Malpighi, University of Bologna, Bologna, Italy

[§] Equally contributors

(* E-mail: fgelsomino@ao.pr.it)

Key message

Nivolumab-induced liver injury represents heterogeneous forms of immune-mediated liver damage, from autoimmune hepatitis to forms with prevalent cholangitic liver disease.

Key words: cholangitic liver disease; immune-mediated liver toxicity; autoimmune hepatitis; nivolumab; immunotherapy; non-small cell lung cancer

© The Author 2016. Published by Oxford University Press on behalf of the European Society for Medical Oncology. All rights reserved. For permissions, please email: journals.permissions@oup.com.

Downloaded from http://annonc.oxfordjournals.org/ at University of California, San Diego on December 22, 2016

Introduction

In recent years, immunotherapy has become a landmark for the development of new anticancer agents. Nivolumab, a fully human IgG4 monoclonal antibody, binds to the PD-1 (programmed cell death-1) receptor, blocking the interaction with its ligands (PD-L1 and PD-L2) and restoring immune competence against tumor cells [1].

It was approved for the treatment of advanced non-small cell lung cancer (NSCLC) following the results of two phase III trials [2,3], demonstrating a significant overall survival benefit and a better toxicity profile over standard second-line treatment. Immune checkpoint inhibition can trigger effector T-cells against tumor- and self-antigens, leading to various immune-related toxicities. In studies of nivolumab, severe immune-related hepatic injury was very rare (supplementary Table S1). We present here the first extensively studied case of severe nivolumab-induced cholangitic liver disease.

Case report

A 79-year-old male with metastatic NSCLC (supplementary Figure S1) started Nivolumab, up to 4 courses, after experiencing progressive disease. The patient had no previous reports of elevated liver function tests (LFT), history of liver disease or drug-induced liver injury. Concomitant medications did not include drugs potentially inducing liver toxicity. History of autoimmune disorders was excluded.

On day +62 from the start of nivolumab, the patient was admitted to hospital due to itching and jaundice. Biochemistry showed grade 4 elevation in total bilirubin and gamma-glutamil-transpeptidase (GGT) and grade 3 elevation in alkaline phosphatase (AP) and alanine transaminase (ALT) levels. The time course of ALT-bilirubin and GGT-AP is shown (supplementary Figure S2).

Viral infections and storage diseases were excluded, as were biliary tree distension, liver metastases or portal thrombosis by imaging. No consumption of other drugs or herbal products were reported and gamma-globulin values were normal. All autoantibodies were negative, except for antinuclear

Downloaded from http://annonc.oxfordjournals.org/ at University of California, San Diego on December 22, 2016

antibodies (ANA) having significant titers (1:320), with a homogeneous pattern. Human leukocyte antigens (HLA)-DR11 were detected.

A percutaneous liver biopsy was performed and the final pathology report was consistent with drug-induced liver damage with features of cholangitis (Figure).

Nivolumab was discontinued and on day +2 from hospitalization metil-prednisolone (1 mg/kg) was started and combined with ursodeoxycholic acid (UDCA).

Bilirubin values reached normal range in 14 weeks; grade 3 elevation of GGT and grade 1 elevation of AP/ALT were still present after 16 weeks. Steroid was tapered to 5 mg daily while UDCA was continued at the same doses (15 mg/kg). The patient died 152 days after the start of nivolumab treatment due to progressive disease.

Discussion

Although immune-related liver toxicity has been reported with nivolumab treatment, it is usually transient (supplementary Table S1) and cholestatic forms have not been previously described.

To date, we do not understand specifically the mechanisms of nivolumab-induced liver injury. A comparison between features of nivolumab-induced cholangitis and other autoimmune liver diseases is summarized (supplementary Table S2).

Time to onset was similar to that reported in the registration trials, even though the time to resolution was longer (supplementary Table S1). Treatment with steroids is common to autoimmune hepatitis/cholangitis and nivolumab-induced liver injury, but responses can be very variable [4,5].

It is likely that nivolumab-induced liver injury represents heterogeneous forms of immune-mediated liver damage, ranging from autoimmune hepatitis to forms with prevalent cholangitic liver disease. These distinct patterns differ due to clinical, biochemical and histopathologic features so much that they have different outcomes and require different therapeutic strategies.

Downloaded from http://annonc.oxfordjournals.org/ at University of California, San Diego on December 22, 2016

We believe that nivolumab primarily induced cholangitic liver disease, probably by an immune-mediated mechanism, which caused subsequent hepatocellular damage. Monitoring levels of GGT and AP in addition to transaminases and bilirubin may be helpful for detecting earlier cholestatic liver disease.

Disclosures

The authors have declared no conflicts of interest.

Funding

None declared.

References

1. Pardoll DM. The blockade of immune checkpoints in cancer immunotherapy. Nat Rev Cancer 2012; 12: 252-264
2. Brahmer J, Reckamp KL, Baas P, et al. Nivolumab versus docetaxel in advanced squamous-cell non-small-cell lung cancer. N Engl J Med 2015; 373:123-135
3. Borghaei H, Paz-Ares L, Horn L, et al. Nivolumab versus docetaxel in advanced nonsquamous non-small-cell lung cancer. N Engl J Med 2015; 373: 1627-1639
4. EASL Clinical Practice Guidelines: Autoimmune hepatitis. European Association for the Study of the Liver. J Hepatol 2015; 63: 971-1004
5. EASL Clinical Practice Guidelines: Management of cholestatic liver diseases. European Association for the Study of the Liver. J Hepatol 2009; 51: 237-267

Downloaded from http://annonc.oxfordjournals.org/ at University of California, San Diego on December 22, 2016

Legends

Figure. Liver biopsy (20x magnification). The histological sample (H&E stain-) showed a moderate lymphocytic inflammatory infiltrate, with bile duct injury. Mild periportal necrosis was also present. CD3 immunohistochemistry (IHC) confirmed the prevalence of lymphocytes in the portal tract. CD8 IHC showed a prevalence of CD8(+) lymphocytes. PD-L1 IHC, by using anti-PD-L1/CD274 (clone SP142; Spring), shows a strong granular immunoreactivity in the cytoplasm of some hepatocytes and Kupffer cells. Furthermore, staining for cytokeratin-19 and -7 revealed ductular proliferation. With the exception of some spotty necrosis, other lobular changes, like steatosis or nuclear glicogenation, were absent. Reticulin stain highlighted the absence of sinusoidal fibrosis.

Downloaded from http://annonc.oxfordjournals.org/ at University of California, San Diego on December 22, 2016

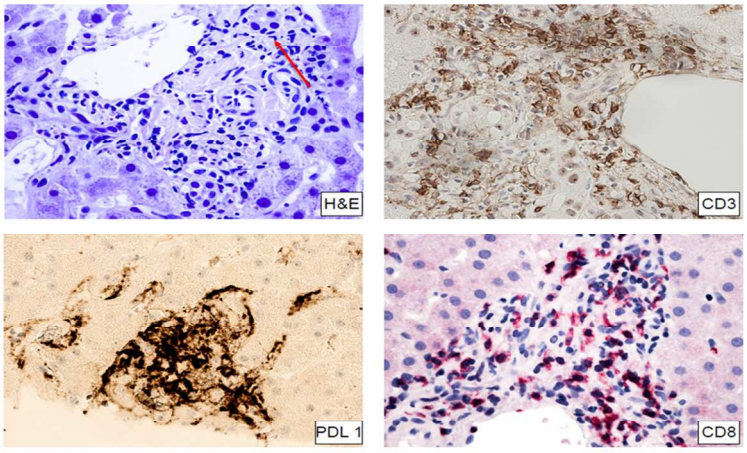

Liver biopsy (20x magnification). The histological sample (H&E stain) showed a moderate lymphocytic inflammatory infiltrate, with bile duct injury. Mild periportal necrosis was also present. CD3 immunohistochemistry (IHC) confirmed the prevalence of lymphocytes in the portal tract. CD8 IHC showed a prevalence of CD8(+) lymphocytes. PD-L1 IHC, by using anti-PD-L1/CD274 (clone SP142; Spring), shows a strong granular immunoreactivity in the cytoplasm of some hepatocytes and Kupffer cells. Furthermore, staining for cytokeratin-19 and -7 revealed ductular proliferation. With the exception of some spotty necrosis, other lobular changes, like steatosis or nuclear glicogenation, were absent. Reticulin stain highlighted the absence of sinusoidal fibrosis.

Figure

338x190mm (96 x 96 DPI)

Downloaded from http://annonc.oxfordjournals.org/ at University of California, San Diego on December 22, 2016

S1. Studies with nivolumab reporting any hepatic event and severity in different solid tumors (a); studies with nivolumab in NSCLC and melanoma reporting resolution data of hepatic irAEs (b)

S2. Patient's cancer history

S3. Time course of ALT-bilirubin and GGT-ALP levels

S4. Differential features of Nivolumab-induced Cholangitis from other resembling autoimmune etiologies

Downloaded from http://annonc.oxfordjournals.org/ at University of California, San Diego on December 22, 2016

	2005	2012	2013	2014	2015	2015/2016
Diagnosis	Primary diagnosis	2nd Lung Cancer NSCLC-NOS stage IV – M1a (lungs)	Renal carcinoma	Pulmonary oligometastatic progression	Pulmonary progression	09/2015 Pulmonary progression
Therapy	RUL lobectomy + nodal dissection Adenosquamous carcinoma pT2N0M0	11/2012 – 02/2013 CBDCA + Gem x 4 → SD	12/2013 Radical nefrectomy + nodal dissection Clear cell carcinoma pT3N0MX	07/2014 Lung Radiotherapy	02 – 04/2015 Vinorelbine x 3 → SD	12/2015 – 01/2016 Nivolumab x 4 Discontinuation 03/2016 PD (lung, soft tissue, peritoneum)

338x190mm (96 x 96 DPI)

Downloaded from http://annonc.oxfordjournals.org/ at University of California, San Diego on December 22, 2016

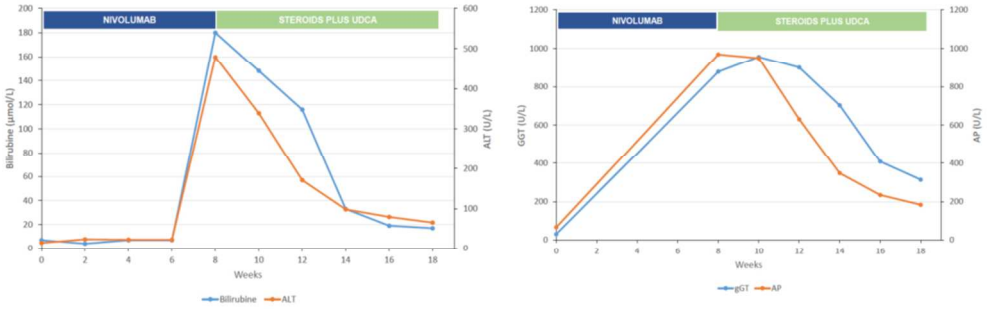

338x190mm (96 x 96 DPI)

Downloaded from http://annonc.oxfordjournals.org/ at University of California, San Diego on December 22, 2016