

This is a pre print version of the following article:

PEG-Asparaginase Single-Agent Rescue in an Advanced Case of Monomorphic Epitheliotropic Intestinal T Cell Lymphoma / Barbieri, E.; Pozzi, S.; Gelmini, R.; Roncati, L.; Maccaferri, M.; Potenza, L.; Marasca, R.; Luppi, M.; Leonardi, G.. - In: JOURNAL OF GASTROINTESTINAL CANCER. - ISSN 1941-6636. - 54:1(2023), pp. 304-308. [10.1007/s12029-022-00808-0]

Terms of use:

The terms and conditions for the reuse of this version of the manuscript are specified in the publishing policy. For all terms of use and more information see the publisher's website.

06/05/2026 13:34

(Article begins on next page)

PEG-Asparaginase Single-Agent Rescue in an Advanced Case of Monomorphic Epitheliotropic Intestinal T-Cell Lymphoma.

Emiliano Barbieri (✉ emilianobarbieri33@gmail.com)

University of Modena and Reggio Emilia: Università degli Studi di Modena e Reggio Emilia
<https://orcid.org/0000-0003-3148-6608>

Stefano Pozzi

University of Modena and Reggio Emilia: Università degli Studi di Modena e Reggio Emilia

Roberta Gelmini

University of Modena and Reggio Emilia: Università degli Studi di Modena e Reggio Emilia

Luca Roncati

University of Modena and Reggio Emilia: Università degli Studi di Modena e Reggio Emilia

Monica Maccaferri

University of Modena and Reggio Emilia: Università degli Studi di Modena e Reggio Emilia

Leonardo Potenza

University of Modena and Reggio Emilia: Università degli Studi di Modena e Reggio Emilia

Roberto Marasca

University of Modena and Reggio Emilia: Università degli Studi di Modena e Reggio Emilia

Mario Luppi

University of Modena and Reggio Emilia: Università degli Studi di Modena e Reggio Emilia

Giovanna Leonardi

University of Modena and Reggio Emilia: Università degli Studi di Modena e Reggio Emilia

Research Article

Keywords: Monomorphic epitheliotropic intestinal T-cell lymphoma, T-cell lymphomas, gastrointestinal lymphomas, extranodal lymphomas, PEG-asparaginase.

Posted Date: November 17th, 2021

DOI: <https://doi.org/10.21203/rs.3.rs-1078661/v1>

License: © ⓘ This work is licensed under a Creative Commons Attribution 4.0 International License.

[Read Full License](#)

Version of Record: A version of this preprint was published at Journal of Gastrointestinal Cancer on March 1st, 2022. See the published version at <https://doi.org/10.1007/s12029-022-00808-0>.

Abstract

MEITL is a very rare and highly aggressive peripheral T-cell lymphoma with poor prognosis and for which there is no standard treatment. Patients with relapsed/refractory disease have few treatment options and many still die of disease progression. Here we report the case of a 65-year-old woman affected by MEITL, progressing after initial treatment with an anthracycline-based chemotherapy and surgery, who received single-agent PEG-asparaginase salvage therapy at our institution. The treatment proved to be rapidly effective in controlling the disease and its associated paraneoplastic features. Nevertheless, toxicity was high and the patient died due to a treatment-related complication. The case we described brings new evidences on the effectiveness of PEG-asparaginase therapy in MEITL patients. Whether PEG-asparaginase should be included in the treatment course of MEITL patients could be the subject of future studies.

Introduction

Monomorphic epitheliotropic intestinal T-cell lymphoma (MEITL), previously known as type II enteropathy-associated T-cell lymphoma [1], is a very rare and highly aggressive peripheral T-cell lymphoma (PTCL). Prognosis is poor, with most studies reporting a median overall survival of less than 1 year [2–9]. There is no standard treatment for MEITL and patients often undergo combination therapies that include surgery and an anthracycline-based chemotherapy, with ASCT consolidation, usually reserved for chemo-sensitive young and fit patients [3, 10–12]. Nevertheless, relapse or refractoriness rates are high and disease progression still represents the main cause of mortality, with few effective treatment options. Here we report the case of a patient with progressive disease after initial treatment, who received single-agent PEG-asparaginase salvage therapy at our institution.

Case Presentation

A 65-year-old woman presented to her general practitioner with a 2-month history of mild abdominal pain, change in bowel habits and unintentional weight loss. She reported no nausea, fever, night sweats or fatigue. Her past medical history was unremarkable, except for past hepatitis B virus infection. She was not taking any medication at that time.

Abdominal examination revealed mild tenderness, without signs of peritonitis. Laboratory studies were significant for mild microcytic anemia and elevated erythrocyte sedimentation rate. Computed tomography (CT) scan of the abdomen revealed the presence of a 13-cm duodenojejunal mass infiltrating adjacent organs (Figure 1a). An endoscopic biopsy was made. On microscopic examination, the mass was composed of monomorphic small lymphocytes positive for CD3, CD8 and CD56 consistent with a diagnosis of MEITL (Figure 2). Staging positron emission tomography (PET) scan revealed increased uptake in multiple abdominal lymph nodes, hepatic flexure, ascending colon and spleen. Bone marrow biopsy showed no signs of disease.

Surgical resection was not performed, due to the aortic wall infiltration. The patient received an anthracycline-containing regimen, inspired to the SNLG protocol [3], achieving partial remission, allowing surgical resection of the residual mass by laparotomy. She was then considered for autologous stem cell transplant (ASCT) consolidation, which was halted due to the development of severe renal insufficiency, with features of acute tubular necrosis and interstitial nephritis, poorly responsive to high-dose corticosteroids.

Thirteen months later CT- and PET-scans revealed recurrence of lymphoma, with multiple lesions, located in the bowel and retroperitoneum (Figure 1b). Relapse was accompanied by renal and cutaneous manifestations (i.e., kidney failure and palpable purpura) suggestive of paraneoplastic vasculitis, with sudden deterioration in patient general conditions. The patient received a first dose of 1500U/m² (2750U total dose) single-agent PEG-asparaginase as salvage therapy. Skin manifestation completely resolved and renal function recovered. Ultra-sound of the abdomen showed significant shrinkage of the biggest lesions, consistent with partial response. However, the patient developed a grade 4 hepatotoxicity, causing treatment delay until resolution to grade 1. A reduced flat dose of 1500U PEG-asparaginase was then resumed. Unfortunately, the subsequent cycle was complicated by a thromboembolic event and she died of massive pulmonary embolism, 3 months after the start of PEG-asparaginase therapy.

Discussion

To the best of our knowledge, this is the second case described in the literature on the use of PEG-asparaginase in relapsed/refractory MEITL, following the first case report by Gentile and colleagues [13]. The use of single-agent PEG-asparaginase salvage therapy resulted in a rapid control of the disease and its associated paraneoplastic features; however, death occurred due to a treatment-related complication. Although schedules of administration were comparable between the two patients (Gentile C., personal communication), toxicities were significantly higher in the case we reported, possibly due to the poor general conditions and the more advanced stage of the disease.

Indeed, the effectiveness of asparaginase therapy in MEITL has also been reported by Tse and colleagues [5], with no apparent differences of outcomes compared to anthracycline-containing regimens, albeit asparaginase was administered in combination with other chemotherapeutic agents and at an earlier treatment phase. Interestingly, a few studies reported similarities between MEITL and other entities that may share a $\gamma\delta$ T-cell origin, especially extranodal NK-/T-cell Lymphoma nasal-type (ENKTCL) [14–16], where guidelines already recommend asparaginase-containing regimens as standard of care [11, 17], and some authors even suggested that these regimens might challenge the role of anthracycline-based regimens in the future of MEITL [7].

It is worth noting that few data on alternative therapies for relapsed/refractory MEITL have been published to date. Although novel agents have emerged in recent years for relapsed/refractory PTCL, data on their effectiveness in MEITL are still lacking. A few authors reported the use of pralatrexate and temozolomide, with favorable outcomes [18, 19] (Table 1). More recently, the Singapore Lymphoma Study

Group has published pre-clinical data on the effectiveness of combination treatment with romidepsin and pimozone [20], but whether this treatment can translate into clinical benefit is still unknown.

Table 1
Published data on single-agent rescue in relapsed/refractory MEITL.

Ref.	Salvage treatment	Case report description
Gentile et al. [13]	PEG-asparaginase	70-year old woman presenting with bowel obstruction and treated with surgery + anthracycline-based chemotherapy (i.e. EPOCH chemotherapy). After refractoriness to 4 cycles of EPOCH chemotherapy, PEG-asparaginase was added to the 5th cycle and then given monthly as single therapy, achieving CR. Disease recurred 15 months after the diagnosis, and the patient was treated again with surgery, EPOCH chemotherapy and PEG-asparaginase, showing no response and dying shortly later.
Tabata et al. [18]	Pralatrexate	72-year-old man presenting with bowel perforation and treated with surgery + chemotherapy (not specified), achieving 1st CR. Disease relapsed 21 months later with bowel obstruction and treatment with surgery + chemotherapy (not specified) was performed achieving 2nd CR. Disease recurred again 11 months later and he was treated again with chemotherapy (not specified), this time with no response. Reduced dose pralatrexate (20mg/m ² /week) was then administered and he obtained 3rd CR. 9 months later, when the case report was published, he was still alive and in CR.
Yip et al. [19]	Temozolomide	67-year-old woman treated with surgery + chemotherapy (i.e., 6 cycles of CHOP), achieving CR. 1 month after completion of the last course of CHOP, CNS progression was detected. Two cycles of HD-MTX, with high-dose cytarabine added during the second cycle, were administered, showing further PD. Temozolomide (150 mg/m ² , 5 days in 28-day cycles) was then initiated as salvage treatment, showing remarkable activity with large resolution of the disease.
EPOCH= etoposide, prednisone, vincristine, cyclophosphamide, and doxorubicin. CR= complete remission. CHOP= prednisone, vincristine, cyclophosphamide, and doxorubicin. CNS= central nervous system. HD-MTX= high-dose methotrexate. PD= progression of disease.		

In conclusion, treatment options for relapsed/refractory MEITL are scarce and the choice of an appropriate rescue for patients with progressive disease still represents an unmet need. The present case adds to the list of studies reporting the effectiveness of asparaginase therapy in MEITL patients. Whether PEG-asparaginase should be included in the treatment course of MEITL and, possibly, considered during earlier treatment phases, is still unknown and should be tested in future studies.

Declarations

STATEMENTS AND DECLARATIONS

Conflict of interest

The authors have no relevant financial or non-financial interests to disclose.

Funding

This research did not receive any specific grant from funding agencies in the public, commercial, or not-for-profit sectors.

Authors' contributions

EB, SP, RG, LR, MM, LP, RM, LM and GL treated the patient and wrote the manuscript. All authors approved the manuscript.

Ethics approval

This study was conducted in accordance with the 1964 Helsinki declaration and its later amendments or comparable ethical standards.

Consent to participate

Patient's family provided informed consent for participation.

Consent for publication

Patient's family provided informed consent for publishing.

References

1. Swerdlow SH, Campo E, Pileri SA, et al (2016) The 2016 revision of the World Health Organization classification of lymphoid neoplasms. *Blood* 127:2375–2390
2. Gale J, Simmonds PD, Mead GM, Sweetenham JW, Wright DH (2000) Enteropathy-Type Intestinal T-Cell Lymphoma: Clinical Features and Treatment of 31 Patients in a Single Center. *J Clin Oncol* 18:795–795
3. Sieniawski M, Angamuthu N, Boyd K, et al (2010) Evaluation of enteropathy-associated T-cell lymphoma comparing standard therapies with a novel regimen including autologous stem cell transplantation. *Blood* 115:3664–3670
4. Delabie J, Holte H, Vose JM, et al (2011) Enteropathy-associated T-cell lymphoma: clinical and histological findings from the International Peripheral T-Cell Lymphoma Project. *Blood* 118:148–155
5. Tse E, Gill H, Loong F, et al (2012) Type II enteropathy-associated T-cell lymphoma: A multicenter analysis from the Asia Lymphoma Study Group. *Am J Hematol* 87:663–668
6. Tan S-Y, Chuang S-S, Tang T, et al (2013) Type II EATL (epitheliotropic intestinal T-cell lymphoma): a neoplasm of intra-epithelial T-cells with predominant CD8αα phenotype. *Leukemia* 27:1688–1696
7. Yi JH, Lee G-W, Do YR, et al (2019) Multicenter retrospective analysis of the clinicopathologic features of monomorphic epitheliotropic intestinal T-cell lymphoma. *Ann Hematol* 98:2541–2550

8. Ondrejka S, Jagadeesh D (2016) Enteropathy-Associated T-Cell Lymphoma. *Curr Hematol Malig Rep* 11:504–513
9. van Vliet C, Spagnolo DV (2020) T- and NK-cell lymphoproliferative disorders of the gastrointestinal tract: review and update. *Pathology (Phila)* 52:128–141
10. d'Amore F, Gaulard P, Trümper L, Corradini P, Kim W-S, Specht L, Pedersen MB, Ladetto M (2015) Peripheral T-cell lymphomas: ESMO Clinical Practice Guidelines for diagnosis, treatment and follow-up †. *Ann Oncol* 26:v108–v115
11. Corradini P, Marchetti M, Barosi G, Billio A, Gallamini A, Pileri S, Pimpinelli N, Rossi G, Zinzani PL, Tura S (2014) SIE-SIES-GITMO Guidelines for the management of adult peripheral T- and NK-cell lymphomas, excluding mature T-cell leukaemias. *Ann Oncol* 25:2339–2350
12. Dearden CE, Johnson R, Pettengell R, Devereux S, Cwynarski K, Whittaker S, McMillan A (2011) Guidelines for the management of mature T-cell and NK-cell neoplasms (excluding cutaneous T-cell lymphoma). *Br J Haematol* 153:451–485
13. Gentile C, Qin Q, Barbieri A, Ravi PS, Iyer S (2017) Use of PEG-asparaginase in monomorphic epitheliotropic intestinal T-cell lymphoma, a disease with diagnostic and therapeutic challenges. *ecancermedicalsecience*. <https://doi.org/10.3332/ecancer.2017.771>
14. Iqbal J, Weisenburger DD, Chowdhury A, et al (2011) Natural killer cell lymphoma shares strikingly similar molecular features with a group of non-hepatosplenic $\gamma\delta$ T-cell lymphoma and is highly sensitive to a novel aurora kinase A inhibitor in vitro. *Leukemia* 25:348–358
15. Pongpruttipan T, Sukpanichnant S, Assanasen T, et al (2012) Extranodal NK/T-cell Lymphoma, Nasal Type, Includes Cases of Natural Killer Cell and $\alpha\beta$, $\gamma\delta$, and $\alpha\beta/\gamma\delta$ T-cell Origin: A Comprehensive Clinicopathologic and Phenotypic Study. *Am J Surg Pathol* 36:481–499
16. Kasinathan G (2021) Monomorphic epitheliotropic intestinal T-cell lymphoma of the duodenum: an aggressive disease. *Hematol Transfus Cell Ther* 43:518–520
17. Horwitz SM, Ansell SM, Ai WZ, et al (2018) NCCN Guidelines Insights: T-Cell Lymphomas, Version 2.2018. *J Natl Compr Canc Netw* 16:123–135
18. Tabata R, Tabata C, Okamura M, Takei Y, Ohshima K (2019) Successful treatment of monomorphic epitheliotropic intestinal T cell lymphoma with pralatrexate. *Ann Hematol* 98:1301–1303
19. Yip P-L, Lam C-P, Lau W-P, Luk T-H, Lau S-MJ (2020) Temozolomide showed rapid activity in a patient with refractory CNS monomorphic epitheliotropic T cell lymphoma. *Ann Hematol*. <https://doi.org/10.1007/s00277-020-04282-1>
20. Huang D, Lim JQ, Cheah DMZ, et al (2020) Whole-genome sequencing reveals potent therapeutic strategy for monomorphic epitheliotropic intestinal T-cell lymphoma. *Blood Adv* 4:4769–4774

Figures

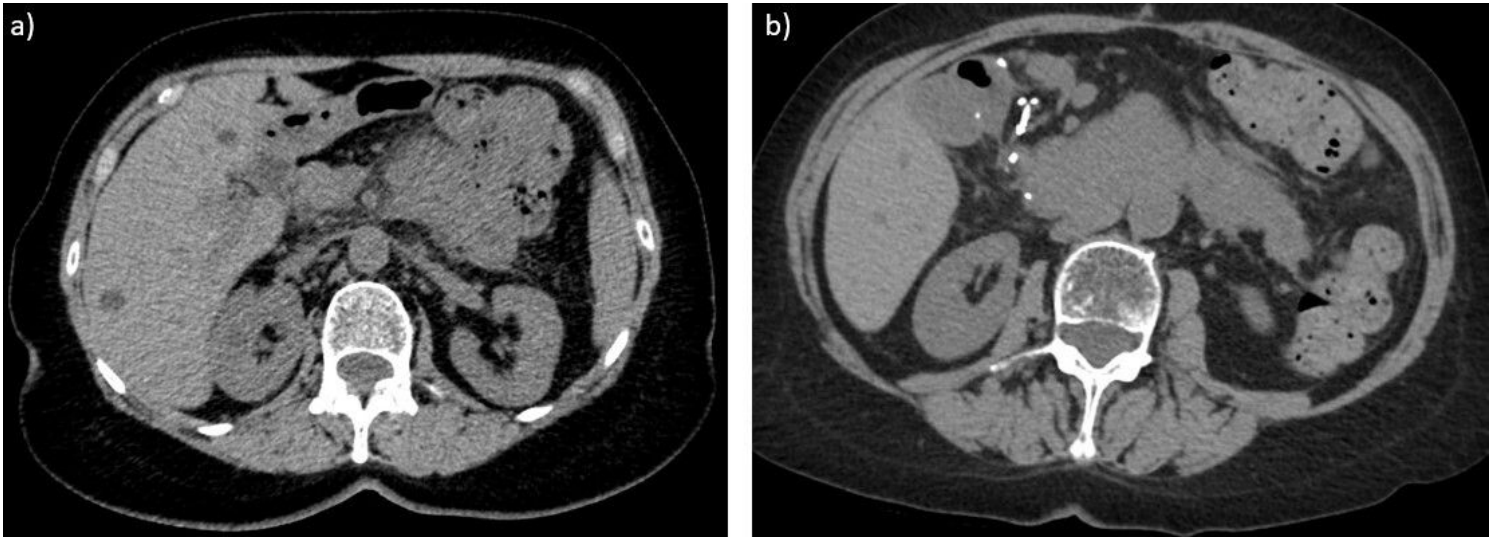

Figure 1

Computed tomography (CT) scans of the abdomen at diagnosis and relapse. 1a. CT scan at diagnosis revealing the presence of a large mass at the duodenojejunal flexure, extending to the proximal jejunum for 12,6 cm in length, characterized by uni-nodular appearance with prominent wall thickening; the mass infiltrated the adjacent organs (i.e., intestinal loops, adipose tissue, anterior wall of the abdominal aorta) and was surrounded by many enlarged lymph nodes. 1b. CT scan at relapse revealing disease recurrence with two solid lesions, located left and right of the aorta in the retroperitoneal space, measuring 5,8 x 3,3 cm and 7,1 x 3,2 cm of diameters, respectively.

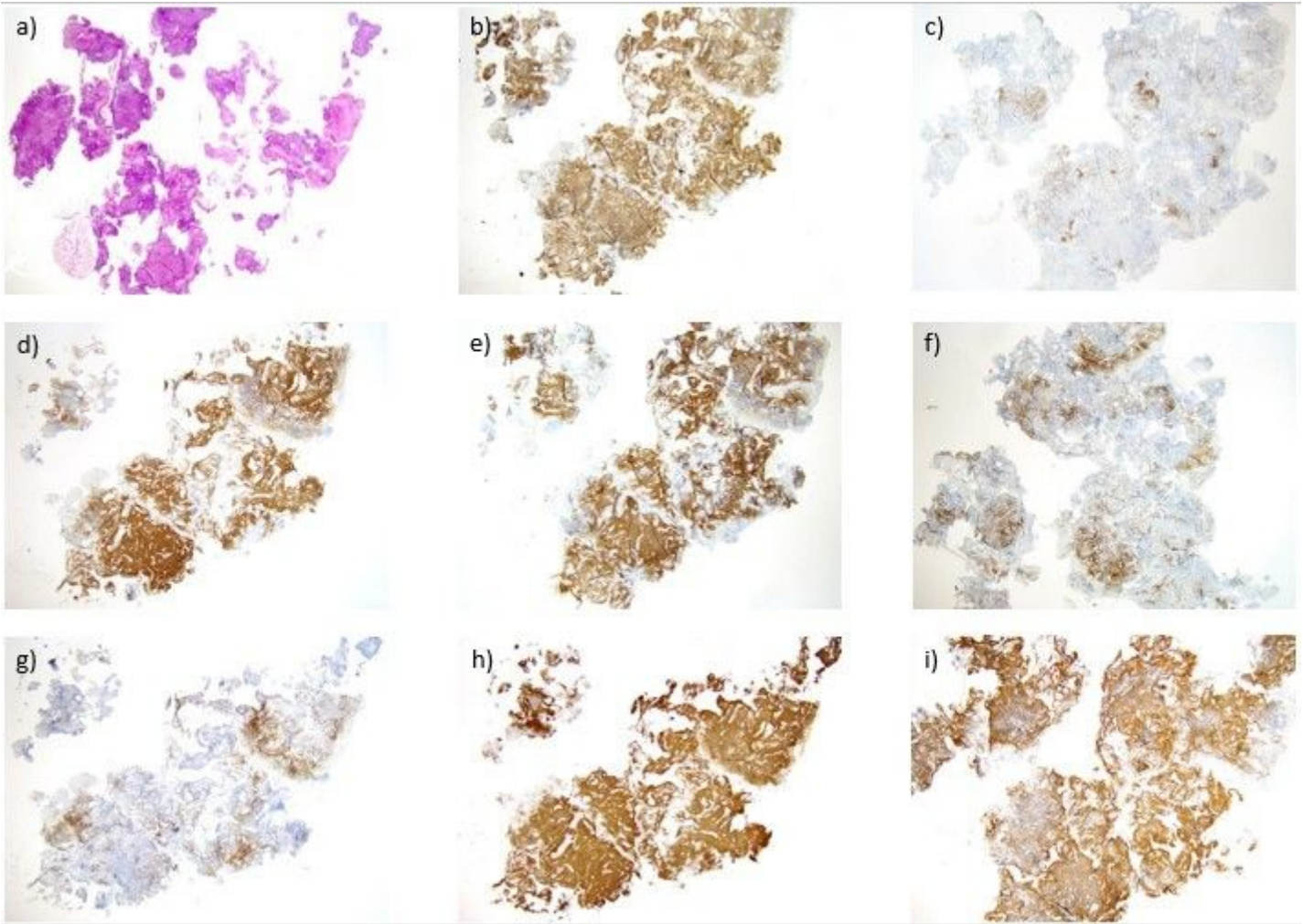


Figure 2

Microscopic examination showing infiltration of the intestinal mucosa at diagnosis. Low magnification (x2.5) images of mucosa fragments from tissue samples at diagnosis showing infiltration of the intestinal mucosa from monomorphic epitheliotropic intestinal T-cell lymphoma cells.

Immunohistochemical staining for: a) H&E, b) CD3 (positive), c) CD20 (negative), d) CD8 (positive), e) CD56 (positive), f) CD5 (negative), g) CD2 (negative), h) CD2 (positive), i) MIB1 > 80%.