

## Vitreoretinal lymphomas misdiagnosed as uveitis: Lessons learned from a case series

Luca Cimino, Marco Coassin<sup>1</sup>, Chi-Chao Chan<sup>2</sup>, Sylvia Marchi, Matteo Belpoliti<sup>1</sup>, Andrea Fanti<sup>1</sup>, Alfonso Iovieno<sup>1</sup>, Luigi Fontana<sup>1</sup>

**Purpose:** To present challenging cases of vitreoretinal lymphoma (VRL) that was misdiagnosed as uveitis because of the apparent intraocular inflammation. At the light of the new classification of intraocular lymphomas, we detail the characteristics that masqueraded the tumors and the clinical aspects that guided us to the correct diagnosis. **Materials and Methods:** We retrospectively reviewed the patients referred to our uveitis service between January 2006 and December 2014. **Results:** Seven patients referred with a presumptive diagnosis of idiopathic uveitis received a final diagnosis of VRL. The median time between the onset of symptoms and definitive diagnosis was 25 months for these complex cases. The median time from presentation at our clinic to final diagnosis was 1 month. The described clinical features including dense vitreous cells and subretinal infiltrates were characteristic and tend to be present in all these chronically ill patients. Vitreous samples were collected, and all demonstrated the pathognomonic tumor cells, the specific immunoglobulin heavy chain gene rearrangements, and an interleukin (IL)-10 to IL-6 ratio >1. **Conclusion:** VRLs are severe diseases with a poor prognosis that may be misdiagnosed as idiopathic inflammatory conditions of the eye. Treatment with steroids may occult the tumors and delay the correct diagnosis. Appropriate evaluation may prompt to a timely vitreous sampling and therefore to a faster diagnosis in these peculiar cases where the correct diagnosis was delayed by several months.

**Key words:** Diagnostic vitrectomy, intraocular inflammation, intraocular lymphoma, subretinal infiltrates, uveitis, vitreoretinal lymphoma

Intraocular lymphomas are one of the most critical entities to take into consideration in the differential diagnosis of patients with apparent ocular inflammation referred to tertiary uveitis clinics.<sup>[1-4]</sup> Presenting rarely to the uveitis specialist,<sup>[3]</sup> diagnosis is often delayed, and prognosis can be very poor in these forms of intraocular lymphomas.<sup>[5-9]</sup>

The traditional classification, distinguishing lymphomas in a primitive subtype arising in the eye (primary intraocular lymphoma) and in a secondary subtype that metastasizes to the eye from a primary site, has been recently updated. Intraocular lymphomas are now divided into vitreoretinal and uveal forms.<sup>[10-14]</sup>

Vitreoretinal lymphomas (VRLs) are aggressive tumors that may interest the central nervous system (CNS).<sup>[10-12]</sup> Often bilateral, they clinically present with vitreous haze and a yellowish tissue infiltrating the subretinal space. Vitreous opacities, retinal infiltrates, and the possible presence of iritis or keratic precipitates may mislead to a diagnosis of uveitis.<sup>[1,15]</sup> VRLs are usually extranodal, non-Hodgkin, diffuse, large B-cell type lymphomas that belong to the family

of primary CNS lymphomas (although also T-cell VRLs have been described).<sup>[10,11,16]</sup> The incidence of these tumors in immunocompetent patients is increasing.<sup>[9]</sup>

Uveal lymphomas include primary and secondary forms.<sup>[4,10]</sup> Primary lymphomas of the choroid were previously called reactive lymphoid hyperplasia because of their low-grade nature. Secondary uveal lymphomas are metastatic localizations to the choroid in patients affected by non-Hodgkin lymphoma in other organs.

Patients with intraocular malignancies are usually referred to the ocular oncology service. We herein describe a number of challenging cases that were not immediately recognized as neoplasm and were referred to our uveitis service for evaluation of the apparent intraocular inflammation.<sup>[13,17]</sup> The purpose is to present the clinical aspects that masqueraded the tumors and delayed the diagnosis, putting at risk the lives of the patients.

### Materials and Methods

We retrospectively reviewed the electronic medical records of all patients referred to the uveitis service of our hospital

Department of Ophthalmology, Uveitis Service, Santa Maria Nuova Hospital-IRCCS, <sup>1</sup>Department of Ophthalmology, Santa Maria Nuova Hospital-IRCCS, Reggio Emilia, Italy, <sup>2</sup>Laboratory of Immunology, National Eye Institute, National Institutes of Health, Bethesda, MD, USA

**Correspondence to:** Dr. Luca Cimino, Department of Ophthalmology, Uveitis Service, Santa Maria Nuova Hospital-IRCCS, Viale Risorgimento, 80 42123 Reggio Emilia, Italy. E-mail: cimino.luca@asmn.re.it

Manuscript received: 20.07.15; Revision accepted: 28.04.16

#### Access this article online

##### Website:

www.ijo.in

##### DOI:

10.4103/0301-4738.185600

#### Quick Response Code:



This is an open access article distributed under the terms of the Creative Commons Attribution-NonCommercial-ShareAlike 3.0 License, which allows others to remix, tweak, and build upon the work non-commercially, as long as the author is credited and the new creations are licensed under the identical terms.

**For reprints contact:** reprints@medknow.com

**Cite this article as:** Cimino L, Coassin M, Chan CC, Marchi S, Belpoliti M, Fanti A, et al. Vitreoretinal lymphomas misdiagnosed as uveitis: Lessons learned from a case series. Indian J Ophthalmol 2016;64:369-75.

between January 1, 2006, and December 31, 2014. All immunocompetent patients with a presumptive diagnosis of uveitis underwent an extensive work-up as previously described<sup>[18]</sup> and were classified according to the criteria of the International Uveitis Study Group.<sup>[19]</sup> The Ethical Committee of our hospital approved this clinical research protocol.

The patients with a final diagnosis of VRL were individuated. We collected from their medical records: Patient demographics including age, gender, and race; previous medical history; symptoms of initial presentation; signs and clinical characteristics of the ocular disease; time between the onset of symptoms to definitive diagnosis of lymphoma; the specific work-up including the surgical procedures; and the methods of histopathologic and molecular diagnosis.

Undiluted vitreous samples were collected and processed as previously recommended.<sup>[17,20-22]</sup> Briefly, vitreous specimen was immediately centrifuged. The supernatant was removed and used for cytokine analysis by ELISA assay. The precipitant was used for cytology; the cells were placed on the coated slides and prepared for Giemsa stain. Supernatants and coated slides were immediately sent to the Laboratory of Immunology of the National Eye Institute (National Institutes of Health, Bethesda, Maryland, USA) for cytology and molecular analysis.<sup>[20-22]</sup> The levels of interleukin (IL) 6 and 10 were measured to differentiate between inflammatory and neoplastic diseases.<sup>[23]</sup> Microdissection techniques with polymerase chain reaction (PCR) amplification were used to detect monoclonality of the malignant B-cells and specifically, the rearrangements of the immunoglobulin heavy chain (IgH) gene, as previously described.<sup>[13,14,17]</sup>

## Results

One thousand and three hundred patients with a presumed new diagnosis of uveitis were seen in our tertiary center between January 2006 and December 2014. Seven cases (0.54%) had a diagnosis of VRL after pars plana vitrectomy (PPV). The age of patients ranged from 45 to 86 years (mean 67.8 years), 4 were males and 3 females, and they were all Caucasian [Table 1].

The median time between the onset of symptoms and definitive diagnosis was 25 months (interquartile range: 8.5–28 months). The median time from presentation at our clinic to final diagnosis was 1 month. Six patients had a confirmed diagnosis of intraocular lymphoma within 1 month from presentation to our institution, whereas it took 13 months for one patient (the first of the series).

At the ophthalmic evaluation, all patients presented with vitreous haze and subretinal lesions in both eyes [Figs. 1 and 2]. Three patients had in addition anterior chamber signs such as flare, cells, fibrin, or keratic precipitates. One patient showed serous retinal detachment and choroidal thickening. Four patients did initially respond to systemic corticosteroids.

The seven patients came to our attention with a presumptive diagnosis of idiopathic uveitis. The final diagnosis was primary VRL in all the cases, and their cellular type was diffuse large B-cell non-Hodgkin lymphoma.

Two patients had a previous CNS lymphoma before the intraocular form. Case 1 had a CNS lymphoma cured 2 years before the diagnosis of the ocular disease. Case 2 was successfully treated for cerebral lymphoma 15 years before the diagnosis of intraocular lymphoma. Both patients had negative brain magnetic resonance imaging (MRI) and were considered in clinical remission from the previous systemic disease when we performed the diagnostic vitrectomy because of the ocular signs.

Case 5 received the diagnosis of cerebral and ocular lymphoma at the same time (7 months after the initial ocular symptoms). The other four patients with VRL did not show any sign of CNS disease.

All patients had the diagnosis of lymphoma confirmed by cytology, showing large atypical lymphoid cells with scant cytoplasm, segmented nuclei, and prominent nucleoli [Figs. 3 and 4]. IgH gene rearrangement was confirmed in all patients. The concentrations of IL-6 and IL-10 in the vitreous are summarized in Table 1. The mean levels of IL-6 and IL-10 were 483.5 pg/ml and 15,977.3 pg/ml, respectively, with an IL-10/IL-6 ratio >1 in 100% of cases.

## Conclusion

The incidence of ocular lymphomas has increased in the past years,<sup>[9]</sup> and patients may be referred to the uveitis specialist because these tumors may mimic inflammatory eye disease.<sup>[1-4]</sup>

Prognosis is severe and diagnosis difficult and often delayed.<sup>[10,11]</sup> In this series, the median time from symptoms to final diagnosis was 25 months. A median time of 1 month was necessary to reach a conclusive diagnosis since they were referred to our institution. Rapid diagnoses of ocular lymphoma may be obtained taking into consideration some characteristics that increase clinical suspicion.

The first of these characteristics is the age of the patient referred for presumed uveitis. In our series, the mean age at diagnosis of ocular lymphoma was 64.4 years. This data are in line with other reports<sup>[15]</sup> and significantly higher than the age of patients diagnosed with uveitis (average 31.1 years at diagnosis in a similar population<sup>[24]</sup>).

Clinical characteristics should also be carefully considered. VRLs usually affect both eyes. Although many diseases have been classically considered in the differential diagnosis of VRLs, the characteristic subretinal deposits are quite striking [Figs. 1 and 2]. All our patients with primary VRL presented with vitreous haze and subretinal yellowish deposits, sometimes rapidly enlarging. Patients usually complain of blurred vision and/or floaters [Figs. 5-8]. Extraocular symptoms are rare, but patients should be questioned for ataxia, dizziness, headaches, or low-grade fever.<sup>[15]</sup>

The standard work-up for infectious and noninfectious uveitis is usually unremarkable. In the majority of the cases, this prompts the diagnosis of idiopathic uveitis and treatment with systemic steroids. As described in previous papers, this might severely delay the final diagnosis.<sup>[10,13,15]</sup> A temporary, intermittent, or incomplete response to steroids should raise

Downloaded from http://journals.lww.com/ijro by BMDM5eP7HkaV1ZEou1r1QIN4a4K4LhEZ6b5tH4dXN10hC4yWwCX1AWVn on 03/10/16. See the Terms and Conditions (http://www.lww.com) on the journal website.

**Table 1: Description of history, clinical findings, molecular analysis, and time to diagnosis in cases with vitreoretinal lymphomas**

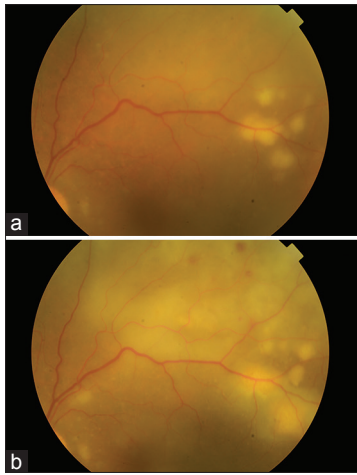
Patient Gender Age	History of uveitis	Laterality	Previous diagnosis of lymphoma	Steroid therapy before definitive diagnosis	Other treatment before definitive diagnosis	Clinical picture at presentation to our uveitis service	CNS lymphoma work-up	PPV	ELISA	IgH gene rearrangements	Final diagnosis	T1*	T2**
1 Male 46	2002: Posterior uveitis 2004: Diagnostic PPV in LE: <i>Bartonella henselae</i> Few months later: Anterior optic neuritis 2005: Recrudescence of bilateral ocular vitritis	Bilateral	2004: Large B-cell non-Hodgkin lymphoma	Yes, systemic	2004: Oral tetracycline chemotherapy, radiotherapy after diagnosis of lymphoma	May 2006: headache and blurred vision, VA=20/200 in RE keratic precipitates, vitritis, and subretinal infiltrates in both eyes	Total body PET scans, brain MRI and LP, all negative	RE	IL-6=182 pg/ml IL-10=10,352 pg/ml IL-10/IL-6=56.9	FR2A, FR3A, CDR3	Vitreoretinal B-cell lymphoma	24	1
2 Male 70	2008-2010: Idiopathic panuveitis	Bilateral	Cerebral B-cell lymphoma	Yes	Chemotherapy	2010: Flare and cells in the AC, moderate vitreous haze and sub-retinal infiltrates in both eyes. May 2011: Severe recrudescence of clinical symptoms	Brain MRI, total body CT scan, PET, and LP, all negative	Bilateral	IL-6=29.2 pg/ml IL-10=1887 pg/ml IL-10/IL-6=64.6	FR3A	Malignant vitreoretinal B-cell lymphoma	24	13
3 Female 45	Posterior uveitis	LE	No	Yes, systemic	No	August 2011: LE was quiet VA=20/20 RE: Vitritis and subretinal infiltrates with light perception vision	Brain MRI, total body PET scans, and lumbar puncture negative	RE	IL-6=95.8 pg/ml IL-10=62,996.5 pg/ml IL-10/IL-6=656.2	FR3A	Vitreoretinal non-Hodgkin lymphoma	57	1
4 Male 86	Suspected infectious uveitis after cataract surgery, not confirmed by diagnostic vitrectomy	RE	No	Yes, oral prednisolone	intraocular antibiotics	August 2007: LE: Mild vitreous haze and yellowish small subretinal lesion RE: 3 large, confluent subretinal infiltrates at the posterior pole	Brain MRI and LP negative	December 2007: LE	IL-6=249.6 pg/ml IL-10=5912 pg/ml IL-10/IL-6=23.7	FR3A, CDR3	Vitreoretinal B-cells lymphoma	24	1

Contd...

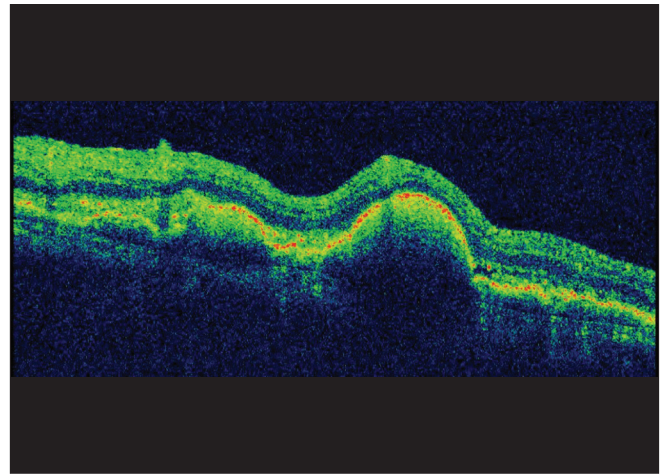
Table 1: Contd...

Patient Gender Age	History of uveitis	Laterality	Previous diagnosis of lymphoma	Steroid therapy before definitive diagnosis	Other treatment before definitive diagnosis	Clinical picture at presentation to our uveitis service	CNS lymphoma work-up	PPV	ELISA	IgH gene rearrangements	Final diagnosis	T1* T2**
5 Male 66	December 2011 suspected multifocal chorioretinitis	Bilateral	No	Yes, systemic for 7 months	No	June 2012: Bilateral vitritis with subretinal infiltrates	Brain MRI, total body PET scans, and LP disclosed a cerebral mass compatible with CNS lymphoma	July 2012: LE	IL-6=15.6 pg/ml IL-10=106.1 pg/ml IL-10/IL-6=6.8	FR3A	Vitreoretinal B-cell lymphoma	7 1
6 Female 76	August 2013: Severe ocular inflammation after cataract surgery, not confirmed by diagnostic vitrectomy	Bilateral	No	Yes, oral and intravenous	No	December 2013: VA was no light perception in RE and light perception in LE RE: Fibrin in the AC, posterior synechiae, severe vitritis with subretinal fluid in and subretinal yellowish infiltrates in both eyes	Brain MRI, total body PET scan and LP, all negative	RE	IL-6=1130.3 pg/ml IL-10=16,961.7 pg/ml IL-10/IL-6=15.0	CDR3	Non-Hodgkin vitreoretinal lymphoma	4 1
7 Female 86	Idiopathic chronic panuveitis	Bilateral	No	Yes, systemic for 5 months	No	October 2014: Vitritis and yellowish subretinal infiltrates in RE. Mild vitreous haze and multiple small chorioretinal scars in LE	Brain MRI, total body PET scans, and LP were negative	RE	IL-6=1682 pg/ml IL-10=13,625.8 pg/ml IL-10/IL-6=8.1	CDR3	Vitreoretinal B-cell lymphoma	5 1

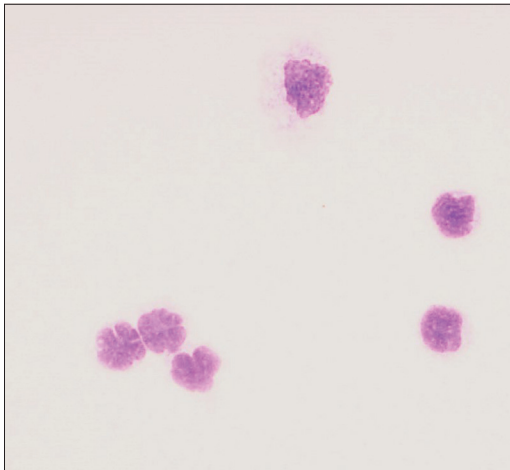
\*Time delay (months) between first diagnosis of "uveitis" and presentation to our institution, \*\*Time (months) necessary to reach a conclusive diagnosis of VRL since they were referred to our institution. LE: Left eye, RE: Right eye, CNS: Central nervous system, MRI: Magnetic resonance imaging, PET: Positron emission tomography, LP: Lumbar puncture, CT: Computed tomography, PPV: Pars plana vitrectomy, VRL: Vitreoretinal lymphomas, IL: Interleukin, VA: Visual acuity, AC: Anterior chamber



**Figure 1:** (a) Clinical fundus picture showing a very aggressive form of vitreoretinal lymphoma: Mild vitreous haze and subretinal yellowish infiltrates. (b) Clinical fundus picture showing a very aggressive form of vitreoretinal lymphoma: 1 week later the lesions are rapidly growing and retinal hemorrhages are present



**Figure 2:** The subretinal pigment epithelium localization of the tumor cells in vitreoretinal lymphoma are well demonstrated by optical coherence tomography



**Figure 3:** Cytology showing vitreoretinal lymphoma cells with large irregular nuclei, prominent nucleoli, and scant basophilic cytoplasm (x400)



**Figure 4:** Primary vitreoretinal lymphoma CD20 positive (x40)

suspicion of intraocular lymphoma. As shown by our series, when chest X-ray, lumbar puncture, brain MRI, or total body positron emission tomography scans are negative, the diagnosis of intraocular lymphoma is still possible. If VRL lymphoma is present, a vitreous sample obtained by pars plana vitrectomy is virtually the only way to confirm the diagnosis.

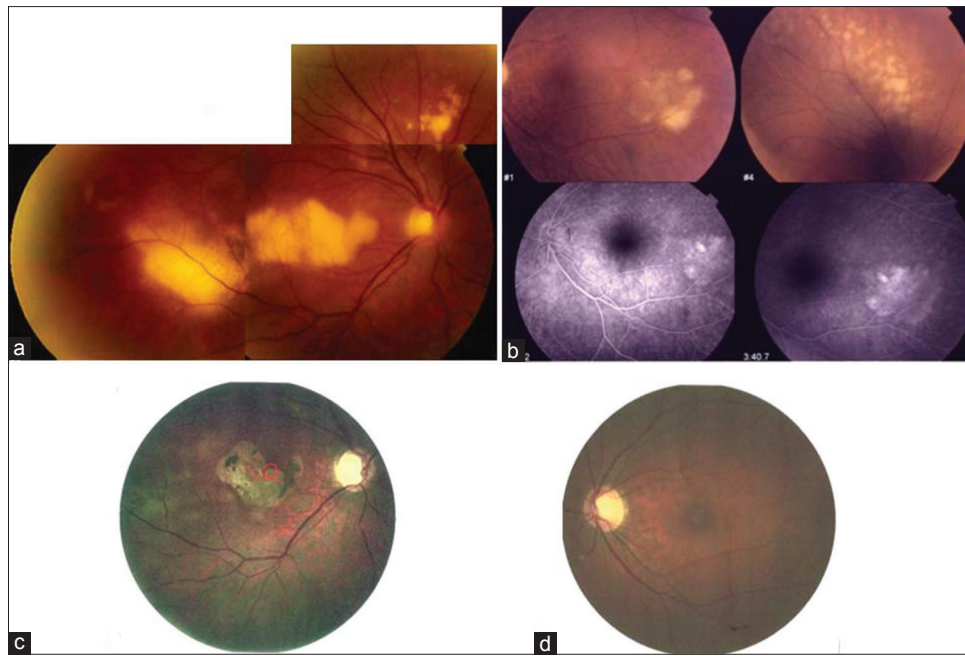
If obtained, vitreous samples should be manipulated and preserved properly.<sup>[17,20-22]</sup> If an expert cytopathologist is not available locally, arrangements should be made before surgery and the material should be safely sent to a specialized laboratory. All the vitreous samples from our patients were shipped as instructed<sup>[11-14]</sup> to the immunopathology Section of the National Eye Institute in the United States, according to a research project with Dr. Chi-Chao Chan.

Cytological examination is considered the gold standard for diagnosis of intraocular lymphoma.<sup>[10,11]</sup> Cytology showed large atypical lymphoid cells with scant cytoplasm, pleomorphic nuclei, and prominent multiple nucleoli [Fig. 3] that showed the classic phenotypic profile by immunohistochemistry.<sup>[12]</sup> Molecular analysis is currently gaining credit as a diagnostic tool, and it is currently debated if cytology is the most sensitive and specific technique for diagnosing intraocular lymphomas.<sup>[15]</sup> All our samples underwent microdissection and PCR analysis demonstrating IgH gene rearrangement.<sup>[13,14]</sup> In this study, all cases of intraocular B-cell lymphoma were identified by molecular analysis using primers FR2A, FR3A, and/or CDR3 that covered the CDR3 region of the IgH gene in B-cell lymphoma.<sup>[13]</sup>

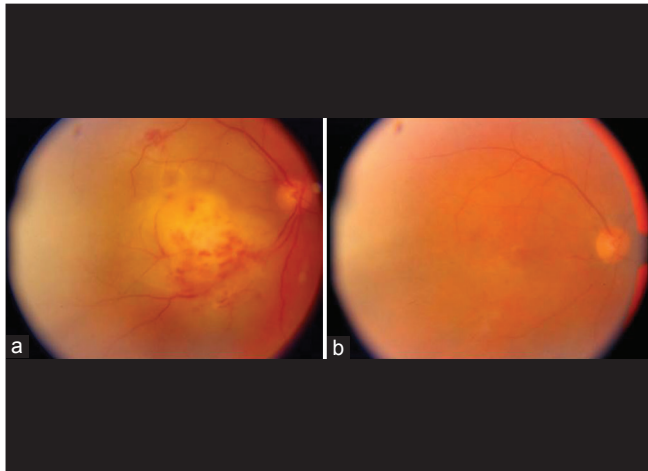
Finally, in all seven cases, the IL-10 to IL-6 ratio was >1, being highly suggestive for VRL.<sup>[22,23]</sup>

VRLs are severe diseases with a poor prognosis, and their incidence is increasing. They may resemble

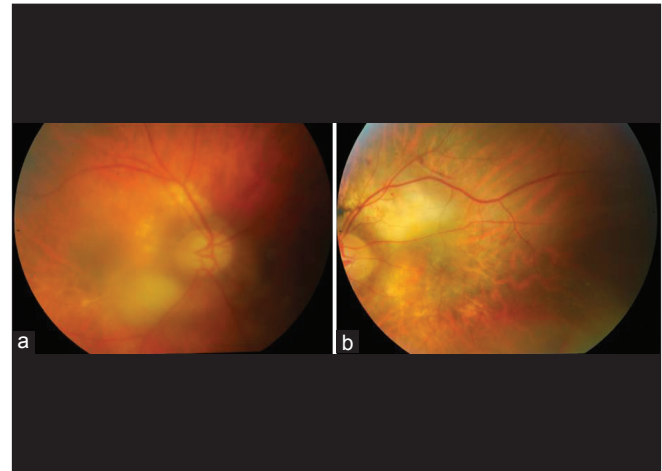
Downloaded from http://journals.lww.com/ijo by BMDM5ePHKav1ZEoum1tQIN4a+kJLhEZgbsHh04XMI0hCywCX1AWn YQpIICrHD3i3D00dRyV7TSF14C3V/C1y0abggZXd9Gj2MwZlei= on 03/22/2023



**Figure 5:** Case 1 right (a) and left (b) eye: vitreoretinal lymphoma, acute phase (diffuse subretinal yellowish lesions). At bottom of (b) we see two left eye fluoroangiography pictures. (c and d) Right and left eye: Convalescent phase



**Figure 6:** (a and b) Case 3: Primary vitreoretinal lymphoma in the right eye, at diagnosis and after 1 month therapy (intravitreal methotrexate and systemic chemotherapy [b])



**Figure 7:** (a and b) Case 4: Bilateral primary vitreoretinal lymphoma (subretinal yellowish lesions at posterior pole and vitreous infiltration more evident in the right eye), at diagnosis (right [a] and left [b] eye)

inflammatory eye diseases and may equivocally respond to systemic corticosteroids. Nevertheless, their clinical appearance – yellowish infiltrates at the retinal pigment epithelium level and vitreous haze – is quite characteristic [Figs.5-8]. When tests for uveitis are not diagnostic in a patient with bilateral subretinal infiltrates, a VRL should be suspected. Because these malignancies have CNS tropism, lumbar puncture, and a brain MRI should be requested. If these last tests are negative, the presence of a VRL is still possible. Therefore, a diagnostic vitrectomy should be considered and followed by adequate cytological and molecular evaluation. Careful ophthalmic examination, appropriate consideration of past medical history, and a diagnostic vitrectomy timely

performed could lead to the correct diagnosis of intraocular lymphoma in less than a month.

#### Acknowledgments

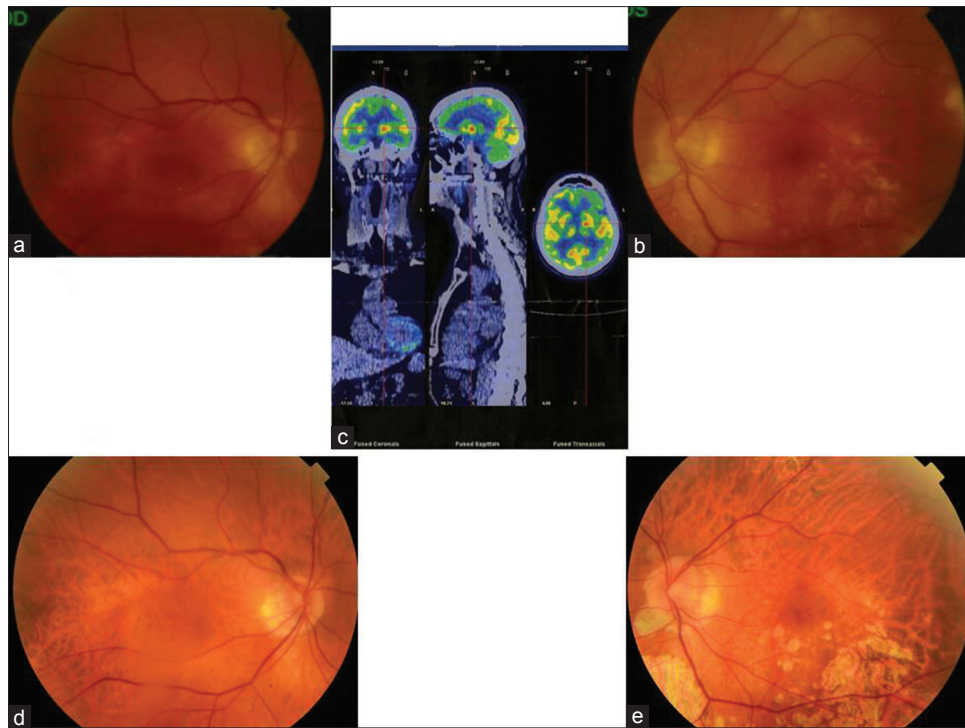
We wish to thank Ione Tamagnini PhD, Davide Niccoli PhD and Raffaella Aldigeri PhD for their contribution in laboratory tests and data management, respectively.

#### Financial support and sponsorship

Nil.

#### Conflicts of interest

There are no conflicts of interest.



**Figure 8:** (a and b) Case 5: Bilateral vitreoretinal lymphoma, faint subretinal infiltrates, mild vitritis (at presentation). (c) Positron emission tomography scan shows brain lesion (at presentation). (d and e) Right and left eye in the convalescent phase

## References

- Grange LK, Kouchouk A, Dalal MD, Vitale S, Nussenblatt RB, Chan CC, *et al.* Neoplastic masquerade syndromes in patients with uveitis. *Am J Ophthalmol* 2014;157:526-31.
- Gill MK, Jampol LM. Variations in the presentation of primary intraocular lymphoma: Case reports and a review. *Surv Ophthalmol* 2001;45:463-71.
- Rothova A, Ooijman F, Kerkhoff F, Van Der Lelij A, Lokhorst HM. Uveitis masquerade syndromes. *Ophthalmology* 2001;108:386-99.
- Read RW, Zamir E, Rao NA. Neoplastic masquerade syndromes. *Surv Ophthalmol* 2002;47:81-124.
- Coupland SE, Foss HD, Hidayat AA, Cockerham GC, Hummel M, Stein H. Extranodal marginal zone B cell lymphomas of the uvea: An analysis of 13 cases. *J Pathol* 2002;197:333-40.
- Cassoux N, Merle-Beral H, Leblond V, Bodaghi B, Miléa D, Gerber S, *et al.* Ocular and central nervous system lymphoma: Clinical features and diagnosis. *Ocul Immunol Inflamm* 2000;8:243-50.
- Chan CC. Primary intraocular lymphoma: Clinical features, diagnosis, and treatment. *Clin Lymphoma* 2003;4:30-1.
- Chan CC, Wallace DJ. Intraocular lymphoma: Update on diagnosis and management. *Cancer Control* 2004;11:285-95.
- Levy-Clarke GA, Chan CC, Nussenblatt RB. Diagnosis and management of primary intraocular lymphoma. *Hematol Oncol Clin North Am* 2005;19:739-49, viii.
- Coupland SE, Damato B. Understanding intraocular lymphomas. *Clin Experiment Ophthalmol* 2008;36:564-78.
- Chan CC, Sen HN. Current concepts in diagnosing and managing primary vitreoretinal (intraocular) lymphoma. *Discov Med* 2013;15:93-100.
- Coupland SE, Chan CC, Smith J. Pathophysiology of retinal lymphoma. *Ocul Immunol Inflamm* 2009;17:227-37.
- Wang Y, Shen D, Wang VM, Sen HN, Chan CC. Molecular biomarkers for the diagnosis of primary vitreoretinal lymphoma. *Int J Mol Sci* 2011;12:5684-97.
- Nagarkatti-Gude N, Wang Y, Ali MJ, Honavar SG, Jager MJ, Chan CC. Genetics of primary intraocular tumors. *Ocul Immunol Inflamm* 2012;20:244-54.
- Kimura K, Usui Y, Goto H; Japanese Intraocular Lymphoma Study Group. Clinical features and diagnostic significance of the intraocular fluid of 217 patients with intraocular lymphoma. *Jpn J Ophthalmol* 2012;56:383-9.
- Levy-Clarke GA, Greenman D, Sieving PC, Byrnes G, Shen D, Nussenblatt R, *et al.* Ophthalmic manifestations, cytology, immunohistochemistry, and molecular analysis of intraocular metastatic T-cell lymphoma: Report of a case and review of the literature. *Surv Ophthalmol* 2008;53:285-95.
- Chan CC. Molecular pathology of primary intraocular lymphoma. *Trans Am Ophthalmol Soc* 2003;101:275-92.
- Cimino L, Aldigeri R, Salvarani C, Zotti CA, Boiardi L, Parmeggiani M, *et al.* The causes of uveitis in a referral centre of Northern Italy. *Int Ophthalmol* 2010;30:521-9.
- Bloch-Michel E, Nussenblatt RB. International Uveitis Study Group recommendations for the evaluation of intraocular inflammatory disease. *Am J Ophthalmol* 1987;103:234-5.
- Dalal M, Casady M, Moriarty E, Faia L, Nussenblatt R, Chan CC, *et al.* Diagnostic procedures in vitreoretinal lymphoma. *Ocul Immunol Inflamm* 2014;22:270-6.
- Rajagopal R, Harbour JW. Diagnostic testing and treatment choices in primary vitreoretinal lymphoma. *Retina* 2011;31:435-40.
- Asencio-Duran M, Vallejo-Garcia JL, Pastora-Salvador N, Fonseca-Sandomingo A, Romano MR. Vitreous diagnosis in neoplastic diseases. *Mediators Inflamm* 2012;2012:930704.
- Damato EM, Angi M, Romano MR, Semeraro F, Costagliola C. Vitreous analysis in the management of uveitis. *Mediators Inflamm* 2012;2012:863418.
- Pivetti-Pezzi P, Accorinti M, La Cava M, Colabelli Gisoldi RA, Abdulaziz MA. Endogenous uveitis: An analysis of 1,417 cases. *Ophthalmologica* 1996;210:234-8.