

# OTOPLAN in Cochlear Implantation for Far-advanced Otosclerosis

\*Andrea Lovato, †Gino Marioni, \*Lisa Gamberini, \*Chiara Bonora, ‡Elisabetta Genovese, and \*Cosimo de Filippis

\*Department of Neuroscience DNS, Audiology Unit at Treviso Hospital, University of Padova, Treviso; †Department of Neuroscience DNS, Otolaryngology Unit, University of Padova, Padova; and ‡Department of Diagnostic, Clinical and Public Health, Audiology Unit, University of Modena and Reggio Emilia, Modena, Italy

**Aim:** To evaluate OTOPLAN software in the surgical planning of far-advanced otosclerosis (FAO) candidates to cochlear implant (CI) were considered. We aimed to preliminarily investigate if this software could influence the electrode length choice, or predict surgical difficulties.

**Methods:** We reviewed the outcome of five consecutive FAO patients that underwent unilateral CI. OTOPLAN was used to evaluate preoperative computed tomography imaging. A comparison was made with historical data (eight FAO patients).

**Results:** The mean cochlear duct length estimated by OTOPLAN was 32.4 mm. Evaluating OTOPLAN reconstructed images, we ruled out cochlear lumen fibrosis/ossification in three FAO patients and the longest electrodes according to cochlear dimensions were preferred. We disclosed fibrosis in the middle and apical turns of two patients. These findings allowed us to change surgical plans, choosing a shorter electrode (24 and 28 mm instead of 31 mm) to avoid incomplete insertion due to cochlear fibrosis. OTOPLAN reconstructed images identified preoper-

atively the two patients with round window niche ossification that required additional drilling during surgery. In the present series, we experienced no incomplete insertion. In two cases out of eight historical FAO patients, array insertion (24 mm) was incomplete. One year after unilateral CI, the mean speech reception threshold and disyllabic word recognition score of the five considered FAO patients were 36 dB and 94%, respectively (39 dB and 84% for the eight historical patients). There was no facial nerve stimulation or any other complication during the 1-year follow-up.

**Conclusion:** According to our preliminary results, OTOPLAN was useful for the appropriate choice of array length. **Key Words:** Cochlear implant—Cochlear ossification—Far advanced otosclerosis—OTOPLAN—Profound hearing loss.

*Otol Neurotol* 41:e1024–e1028, 2020.

---

## OBJECTIVE

In far-advanced otosclerosis (FAO), patients may meet clinical cochlear implantation (CI) criteria when sensorineural hearing loss is profound and word recognition score (WRS) is under 50% at 60 dB with efficient hearing aids (1). The main difficulties in CI for FAO were electrode misplacement, incomplete electrode insertions, changes of surgical approach with high risk of facial nerve stimulation and revision surgery (2). Dumas et al. (3) did not find a significant correlation between the severity of CT findings and the incidence of surgical complications. To our knowledge, previous reports on

FAO patients did not analyze the array length in association with incomplete insertion.

OTOPLAN is a new software for otological surgical planning. It allows computed tomography (CT) imaging-based reconstructions to obtain an accurate cochlear lumen view. OTOPLAN gives an estimation of cochlear turn length. OTOPLAN was already used in CI surgical planning in post-meningitis cochlear ossification (4).

We herein reviewed the audiological outcome of a series of FAO patients who underwent unilateral CI; for all patients OTOPLAN was used to evaluate preoperative CT. We aimed to preliminarily evaluate the potential role of OTOPLAN for electrode length choice, or to predict surgical difficulties in FAO patients.

## PATIENTS

The study was approved by the Institutional Ethical Committee. All patients signed an informed consent. We considered consecutive patients with bilateral FAO who had undergone unilateral CI at our Audiology Unit. Inclusion

---

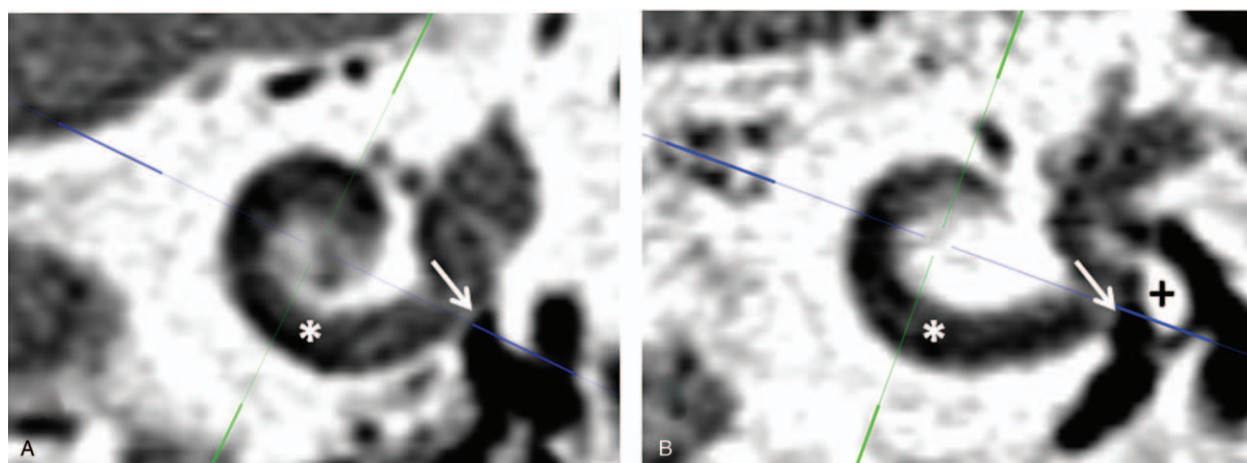
Address correspondence and reprint requests to Andrea Lovato, M.D., Department of Neurosciences, Audiology Unit, Piazzale Ospedale 1, 31100 Treviso, Italy; E-mail: andrea.lovato.3@hotmail.it

The authors have no funding to declare.

The authors disclose no conflicts of interest.

Supplemental digital content is available in the text.

DOI: 10.1097/MAO.0000000000002722



**FIG. 1.** OTOPLAN reconstructed images using axial computed tomography imaging from patients number 3 (A) and 4 (B) left ears with far-advanced otosclerosis. The blue line was traced from the round window (*white arrow*) to the contra-lateral wall passing through the modiolus. The white asterisk identified the basal turn, which was free from fibrosis and ossification in both patients. In (B) OTOPLAN reconstructed image showed important ossification at round window niche (*black plus*).

criteria were: 1) a previous medical history of bilateral slowly progressive hearing loss with audiological and radiological (CT and magnetic resonance imaging [MRI]) findings typical for otosclerosis; 2) severe-to-profound hearing loss (pure-tone average [PTA] >85 dB); 3) WRS less than 50% with efficient hearing aids; 4) CI surgery with MED-EL Synchrony Mi1200; 5) preoperative analysis of CT by OTOPLAN. The software was developed and distributed by MED-EL (Innsbruck, Austria). The present series was compared with historical results of FAO patients that met inclusion criteria apart from OTOPLAN analysis.

### INTERVENTIONS

Hearing thresholds were investigated at 250 to 8000 Hz and mean PTA calculated as previously reported (5,6). For speech audiometry, 10 Italian words for adults (7) were presented for each stimulus intensity, and speech reception threshold (SRT) (50%) was calculated. For disyllabic WRS, a list of 25 disyllabic common Italian words (7) was presented at 70 dB (2). OTOPLAN on patient's CT imaging (temporal bone protocol) was used as previously reported (4). The Electrode Visualization Tool was used to obtain an accurate cochlear view (Figs. 1 and 2). Software gave an estimation of cochlear turn length. Considering both OTOPLAN reconstructed images and the estimation of cochlear turn length, technicians provided a report with a suggested electrode length to use in every patient, however the ear surgeon made the final decision. A facial recess approach was performed to access the round window (RW). Patients followed a standardized follow-up schedule at 1-, 3-, 6-, 12-month post-activation.

### MAIN OUTCOME MEASURES

Surgical difficulties such as RW ossification, or incomplete array insertion were recorded. Adverse effects such

as facial palsy/stimulation, or vertigo were compiled. SRT and WRS were used for audiological outcome.

## RESULTS

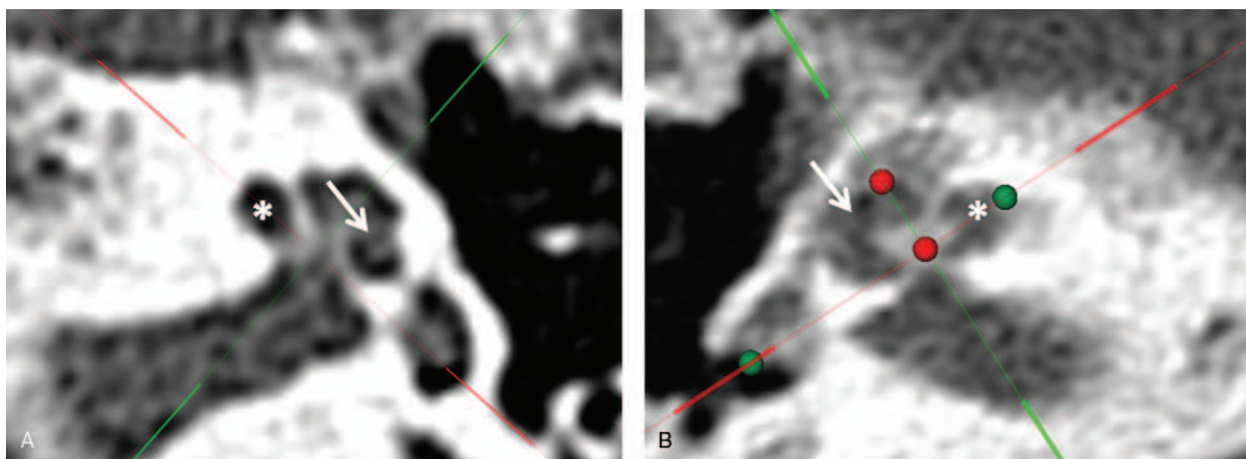
### Patients

In the present exploratory study, the diagnosis of FAO was made according to audiological (a previous history of bilateral conductive hearing loss that slowly progress to severe-to-profound) and radiological (otospongiosis of the labyrinthine bone) data in all patients. Supplemental content 1, <http://links.lww.com/MAO/B46> showed examples of older audiogram and CT scan demonstrating early typical conductive hearing loss and otospongiosis. We considered five consecutive FAO patients (three women and two men, mean age 59.6 yr) who underwent CI. Demographic and preoperative audiological data were reported in Supplemental Content 2, <http://links.lww.com/MAO/B47>. The mean deafness duration was  $28.9 \pm 13.73$  years. Four patients used bilateral hearing aids, patient number 5 used the right hearing aid but not the left one for the lack of benefit since 14 months before CI. Patients number 2 and 5 had undergone contra-lateral stapedotomy in another Institution 20 and 14 years before CI reporting a good outcome.

The present series was compared with historical data from eight consecutive patients (five women and three men, mean age 61.2 yr) with FAO who had undergone CI. Their mean deafness duration was  $26.3 \pm 17.4$  years. Before CI, six patients used bilateral hearing aids, two unilateral. Three patients in the study group and three in the historical group had a familiar history of stapedotomy in first degree relatives.

### Otoplan Analysis

The mean OTOPLAN-estimated cochlear duct length was 32.4 mm (Table 1). In patients 1, 2, and 3 no fibrosis or ossification were found within the cochlear duct



**FIG. 2.** OTOPLAN reconstructed images using axial computed tomography imaging from patients number 4 left ear (A) and from patient 5 right ear (B) with far-advanced otosclerosis. The green dots were positioned in center of the round window and on the opposite lateral cochlear wall and identified a length called A. “A” was used by OTOPLAN to estimate the cochlear duct length. The red dots defined the height of the cochlea (H) as the distance between the cochlear bottom and the apex of the cochlea. The red line was traced parallel to the basal turn and through the modiolus and green line was perpendicular to red one. In (A) OTOPLAN image showed fibrosis in the apical turn (white arrow), but not in the middle turn (white asterisk). In (B) the software disclosed important fibrosis both in apical (white arrow) and in middle (white asterisk) turns.

according to OTOPLAN reconstructions (Fig. 1), thus we chose the longest electrode according to cochlear length estimations (Table 1). In patients 4, the software showed endo-luminal fibrosis at the apical turn (Fig. 2). Despite an estimated cochlear length of 32.9 mm, we chose a 28 mm electrode, to avoid incomplete insertion due to apical turn fibrosis. In patient number 5, the software disclosed middle and apical turn fibrosis and thus a shorter electrode (24 mm) was preferred.

OTOPLAN gave a very clear vision of the RW. Patients number 2 and 4 had a significant RW niche ossification (Fig. 1), and we were prepared for a more extensive drilling at that level. Conventional CT with temporal bone protocol showed no luminal fibrosis or ossification in all patients and offered no suggestions for surgical planning (Supplemental Content 3, <http://links.lww.com/MAO/B48>).

In historical patients, conventional CT ruled out fibrosis/ossification with occlusion of cochlear lumen. A 24 mm electrode was used in all cases.

### Surgery

A posterior tympanotomy approach (three right and two left) was performed in all patients. Surgical difficulties were found in two cases: patients 2 and 4 required RW niche extra drilling until the scala tympani was properly identified. These difficulties were expected accordingly to OTOPLAN preoperative reconstructions. In patients 1, 3, and 4, the insertion of the electrode required a little additional pushing because of resistance, but in all five patients the array insertion was complete. Attention was paid to avoid electrode bending or damaging. In all the cases, electrical impedances were tested on intra-cochlear contacts and were within normal range.

In the eight historical FAO patients, RW niche extra drilling was required in four, while array insertion was incomplete in two (one and two contacts outside cochlear lumen, with abnormal electrical impedances).

**TABLE 1.** Results of OTOPLAN analysis on patient's preoperative CT imaging and surgical findings during unilateral cochlear implantation in far-advanced otosclerosis

Patient No.	OTOPLAN Cochlear Length Estimation (mm)	OTOPLAN View of Fibrosis/Ossification	Chosen Array Length (Type/mm)	Surgical Findings
1	33.3	—	FLEXSOFT/31	Complete insertion
2	30.7	RW <sup>a</sup> niche ossification	SOFT/28	Additional RW drilling; complete insertion
3	32.2	—	FLEXSOFT / 31	Complete insertion
4	32.9	RW niche ossification; apical turn fibrosis	SOFT/28	Additional RW drilling; complete insertion
5	33.1	Middle and apical turns fibrosis	SOFT/24	Complete insertion

<sup>a</sup>Round window.

**TABLE 2.** *Audiological results of unilateral cochlear implant in five far-advanced otosclerosis patients*

Patient No.	3-Months SRT (dB)	3-Months WRS (%)	6-Months SRT (dB)	6-Months WRS (%)	12-Months SRT (dB)	12-Months WRS (%)
1	60	50	45	80	30	100
2	50	60	45	90	40	90
3	50	70	45	80	30	100
4	60	50	40	90	40	90
5	50	60	50	70	40	90

SRT indicates speech reception thresholds; WRS, word recognition score.

### Follow-up

Postoperatively, two patients experienced dizziness without nystagmus (patient number 1 for 7 days, and patient 5 for 10 days). CIs were activated 1 month after surgery. Follow-up controls were performed according to our schedule. Audiological results of the CIs have been reported by Table 2. At 1-year follow-up, mean SRT and WRS were 36 dB and 94%, respectively. There was no facial nerve stimulation or any other complication at the 1-year follow-up.

In the historical series, three patients experienced post-surgical dizziness. CIs were activated 1 month after surgery; contacts outside cochlear lumen were not activated in two patients. At 1-year follow-up, mean SRT and WRS were 39 dB and 84%, respectively. There were no complications at the 1-year follow-up.

### DISCUSSION

Our results confirm that CI is an efficient approach to FAO. One years after unilateral CI, the mean SRT and WRS of the five FAO considered patients were respectively 36 dB and 94%; these results are consistent with those available in the literature (2–3,8–12). The audiological outcome of the present series was slightly superior compared with our historical FAO patients when OTOPLAN was not used to estimate cochlear length.

The aim of the present study was to evaluate OTOPLAN in the surgical planning of FAO candidates to CI. It was preliminarily investigated if this software could influence the electrode length choice, or predict surgical difficulties. Indeed, CI in FAO patients has been associated to frequent surgical problems (2). In Dumas et al. (3) analysis, conventional CT was not able to predict surgical difficulties. Also in our series, conventional CT imaging did not raise any surgical issues. Castillo et al. (12) reported that CT scan had low sensitivity as the presence ossification was frequently found only intraoperatively in their FAO patients. In available literature, the proportion of patients displaying varying degrees of intraoperative ossification requiring drilling to obtain scalar lumen ranged from 5 (12) to 60% (2); it was 40% (2/5 ears) in the current series and 50% (4/8 ears) in our historical patients. OTOPLAN reconstructed images identified preoperatively the two patients with RW niche ossification that required additional drilling. OTOPLAN images provided an efficient view of the RW region (Fig. 1).

Nevertheless, with a diagnosis of FAO a surgeon should be prepared to deal with bone in the RW niche.

Partial electrode insertion in FAO patients has been reported (2–3,8–9,12), with percentages ranging between 5.5 (2) and 30% (3). In addition, the analysis of our historical data disclosed an incomplete array insertion in 25%. In study group, we experienced no incomplete insertions. Interestingly, before this investigation, no authors studied the relation between incomplete insertion and electrode length. OTOPLAN was used to estimate cochlear length. Furthermore, evaluating OTOPLAN reconstructed images, fibrosis within the cochlear lumen in the middle and apical turns was disclosed in two patients. These findings allowed to change surgical plans, choosing a shorter electrode (24 and 28 mm instead of 31 mm) to avoid incomplete insertion.

The main weaknesses of our investigation were the limited number of cases and the lack of a control group. The last was a relative weakness as incomplete insertion represented a significant risk (25%) according to our historical data, when electrode length choice was empirical. Furthermore, we did not compare OTOPLAN with MRI that was thought to be superior at identifying intrascalar fibrosis. FAO patients had a long medical history of slowly progressive hearing loss and all of them underwent an MRI at some point. We did not routinely repeat MRI even if the examinations were performed years earlier. MRI should be requested with signs of ossification at CT, but those were absent in our series. Many groups did not use MRI routinely in FAO (2–3,8,11).

In conclusion, OTOPLAN reconstructed images were helpful in CI surgical planning for FAO patients. This software preliminarily seems useful for the appropriate array length choice. The software could predict the need of additional drilling of RW niche, but this would not significantly modified the surgical plan of FAO patients.

### REFERENCES

1. Merkus P, van Loon MC, Smit CF, et al. Decision making in advanced otosclerosis: an evidence-based strategy. *Laryngoscope* 2011;121:1935–41.
2. Vashishth A, Fulcheri A, Rossi G, et al. Cochlear implantation in otosclerosis: surgical and auditory outcomes with a brief on facial nerve stimulation. *Otol Neurotol* 2017;38:e345–53.

3. Dumas AR, Schwalje AT, Franco-Vidal V, et al. Cochlear implantation in far-advanced otosclerosis: hearing results and complications. *Acta Otorhinolaryngol Ital* 2018;38:445–52.
4. Lovato A, de Filippis C. Utility of OTOPLAN reconstructed images for surgical planning of cochlear implantation in a case of post-meningitis ossification. *Otol Neurotol* 2019;40:e60–1.
5. Lovato A, García Ibañez E, García Ibañez L, et al. Tumor growth rate: a new prognostic indicator of hearing preservation in vestibular schwannoma surgery. *Laryngoscope* 2019;129:2378–83.
6. Lovato A, Kraak J, Hensen EF, et al. A critical look into stapedotomy learning curve: influence of patient characteristics and different criteria defining success. *Ear Nose Throat J* 2019. doi: 10.1177/0145561319866825. [Epub ahead of print].
7. Bocca E, Pellegrini A. [Statistical study of the phonetic composition of the Italian language and its practical application to audiometry of words]. *Arch Ital Otol Rinol Laringol* 1950;61:116–41.
8. Rottoveel LJ, Proops DW, Ramsden RT, et al. Cochlear implants in 53 patients with otosclerosis: demographics, computed tomographic scanning, surgery and complications. *Otol Neurotol* 2004;25:943–52.
9. Sainz M, García-Valdecasas J, Garófano M, et al. Otosclerosis: mid-term results of cochlear implantation. *Audiol Neurootol* 2007;12:401–6.
10. Sainz M, Garcia-Valdecasas J, Ballesteros JM. Complications and pitfalls of cochlear implantation in otosclerosis: a 6-year follow-up cohort study. *Otol Neurotol* 2009;30:1044–8.
11. Semaan MT, Gehani NC, Tummala N, et al. Cochlear implantation outcomes in patients with far advanced otosclerosis. *Am J Otolaryngol* 2012;33:608–14.
12. Castillo F, Polo R, Gutiérrez A, et al. Cochlear implantation outcomes in advanced otosclerosis. *Am J Otolaryngol* 2014;35: 558–64.