



# Positive surgical margin during radical prostatectomy: overview of sampling methods for frozen sections and techniques for the secondary resection of the neurovascular bundles

Maria Chiara Sighinolfi\* , Ahmed Eissa\*<sup>†</sup>, Valentina Spandri\*, Stefano Puliatti\*, Salvatore Micali\*, Luca Reggiani Bonetti<sup>‡</sup>, Laura Bertoni<sup>‡</sup>, Giampaolo Bianchi\* and Bernardo Rocco\* 

\*Department of Urology, University of Modena & Reggio Emilia, Modena, Italy, <sup>†</sup>Urology Department, Faculty of Medicine, Tanta University, Tanta, Egypt, and <sup>‡</sup>Pathology Department, University of Modena & Reggio Emilia, Modena, Italy

## Objective

The aim of the paper is to provide an overview of intraoperative sampling methods for frozen section (FS) analysis and of surgical techniques for a secondary neurovascular bundle (NVB) resection, as the method of surgical margin (SM) sampling and the management of a positive SM (PSM) at the nerve-sparing (NS) area are under evaluated issues. FS analysis during radical prostatectomy (RP) can help to tailor the plane of dissection based on cancer extension and thus extend the indications for NS surgery.

## Evidence Acquisition

We performed a PubMed/Medical Literature Analysis and Retrieval System Online (MEDLINE), Web of Science, Cochrane Library, and Elton B. Stephens Co. (EBSCO)host search to include articles published in the last decade, evaluating FS analysis in the NS area and surgical attempts to convert a PSM to a negative status.

## Evidence Synthesis

Overall, 19 papers met our inclusion criteria. The ways to collect samples for FS analysis included: systematic (analysing the whole posterolateral aspect of the prostate specimen, i.e., neurovascular structure-adjacent frozen-section examination

[NeuroSAFE]); magnetic resonance imaging (MRI)-guided (biopsies from MRI-suspicious areas, retrieved by the surgeon in a cognitive way); and random biopsies from the soft periprostatic tissues. Techniques to address a PSM in the NS area included: full resection of the spared NVB, from its caudal to cranial aspect, often including the rectolateral part of the Denonvilliers' fascia; partial resection of the NVB, in cases where sampling attempts to localise a PSM; incremental approach, meaning a partial or full resection that extends until no prostate tissue is found in the soft periprostatic environment.

## Conclusions

There is no homogeneity in prostate sampling for FS analysis, although most recent evidence is moving toward a systematic sampling of the entire NS area. The management of a PSM is variable and can be affected by the sampling strategy (difficult localisation of the persisting tumour at the NVB). The difficult identification of the exact soft tissue location contiguous to a PSM could be considered as the critical point of FS analysis and of spared-NVB management.

## Keywords

surgical margins, radical prostatectomy, frozen section, sampling

## Introduction

A nerve-sparing (NS) technique during RP represents the 'gold standard' to maintain erectile function in patients with low-risk prostate cancer [1]. Given the limited reliability of nomograms and statistical models in predicting extracapsular extension (ECE) of cancer [2,3], intraoperative pathological analysis with frozen section (FS) has been suggested as an

alternative. The intraoperative detection of a positive surgical margin (PSM) during a NS surgery can be useful to tailor the plane of dissection and to resect more tissue from the periprostatic environment pursuing the complete removal of all neoplastic foci [4].

Actually, surgical Margin (SM) status at the area of NS is of paramount importance, as the dissection should be performed

very close to the prostate at this point (intra- or interfascial plane); furthermore, this area is particularly prone to PSM, which can result from iatrogenic intraprostatic excision into an otherwise organ-confined tumour or failure to completely excise an extraprostatic prostate cancer [5]. Consequently, the knowledge of SM status of the NS zone allows for the correction of the surgical strategy and could possibly change the course of the oncological and functional outcomes of the RP.

In recent years, several techniques have been proposed to assess SM status intraoperatively and to guide a real-time diagnosis of the excised surface [4] including: the neurovascular structure-adjacent frozen-section examination (NeuroSAFE) approach [6], augmented reality [7], and fluorescence confocal microscopy [8]; however, little is known on how to manage the finding of a PSM and how to obtain a safe radical excision of the periprostatic tissue.

The aim of the present systematic review was to provide an overview of the sampling techniques for FS analysis from the neurovascular bundle (NVB) area and the way to achieve a secondary resection of persisting neoplastic tissue.

## Evidence Acquisition

### Methodology and Reporting

This systematic review was performed in accordance with Preferred Reporting Items for Systematic Reviews and Meta-Analysis (PRISMA) statement [9]. Two independent authors (A.E. and M.C.S.) searched the Medical Literature Analysis and Retrieval System Online (MEDLINE), Web of Science, Cochrane Library, and Elton B. Stephens Co. (EBSCO)host databases using a combination of the following keywords: 'frozen section', 'frozen tissue', 'cryosection', 'cryo-section', 'prostatectomy', 'prostate cancer', 'prostatic adenocarcinoma', 'prostatic neoplasm', and 'prostate neoplasm'. All the articles describing the use of FS during RP and reporting the management of a PSM in the NVB zone were included. Moreover, we included articles with FS analysis of the NS area (posterolateral aspect of the prostate) with or without separate assessment of the base and apex, with the exclusion of papers addressing SM only at the urethral stump, at the apex and/or at the base, without considering the NS zone. In the event of any discrepancy between the two authors, a third author helped to resolve the discrepancy. The language filter was used to include only articles published in English. Furthermore, we arbitrarily included reports published since 2010, in an effort to homogenise: (i) patient series (considering the changing trend of patients with prostate cancer undergoing surgery in the last decade, with active surveillance implementation); and (ii) RP technique, since after 2010 robot-assisted laparoscopic RP (RALP) has considerably increased.

## Endpoints

FS is the most commonly used approach for assessment of the SM during RP and it is based on the use of a cryostat to induce rapid freezing of the tissue specimens ( $-16$  to  $-20$  °C for prostatic tissues) and consequently convert the water component of the tissue to ice to allow its cutting into multiple sections. Finally, the tissue is examined under a microscope after haematoxylin and eosin staining [4]. The main aims of the present review were to assess the available sampling techniques at the region of the NVB during RP, the techniques of secondary resection, and the impact of FS on oncological and functional outcomes.

## Data Extraction

The following key aspects were collected from each study and stored in a dedicated database: sample size, approach of RP (open, laparoscopic, or robot-assisted), region of FS, sampling technique, secondary resection technique, PSM rate at FS, PSM at histopathology, biochemical recurrence, and functional outcomes (erectile and continence functions).

## Assessment of the Risk of Bias

The primary aim of the present review was to report the different sampling techniques of FS and not to compare between patients who underwent intraoperative FS and those who did not, thus the Quality Assessment of Diagnostic Accuracy Studies-2 (QUADAS-2) tool was used to assess the risk of bias in the included studies [10]. Two of the authors (M.C.S. and A.E.) independently performed the quality assessment of the included studies and any discrepancies were resolved.

## Evidence Synthesis

### Search Results

Overall, the search identified 523 records. All records were searched to detect and exclude duplicate results (115 studies). Subsequently, the remaining 408 articles were screened using the title and abstract to exclude all the articles irrelevant to the question of the present systematic review (340 studies), leaving 68 manuscripts for full-text review. After the screening, 49 manuscripts were excluded for various reasons detailed in (Fig. 1). Finally, 19 articles met our inclusion criteria and were included in the present systematic review.

## Studies Description

Most of the included studies were retrospective (74%) and only five studies (26%) were prospective in nature. Furthermore, the studies were performed mainly in Germany

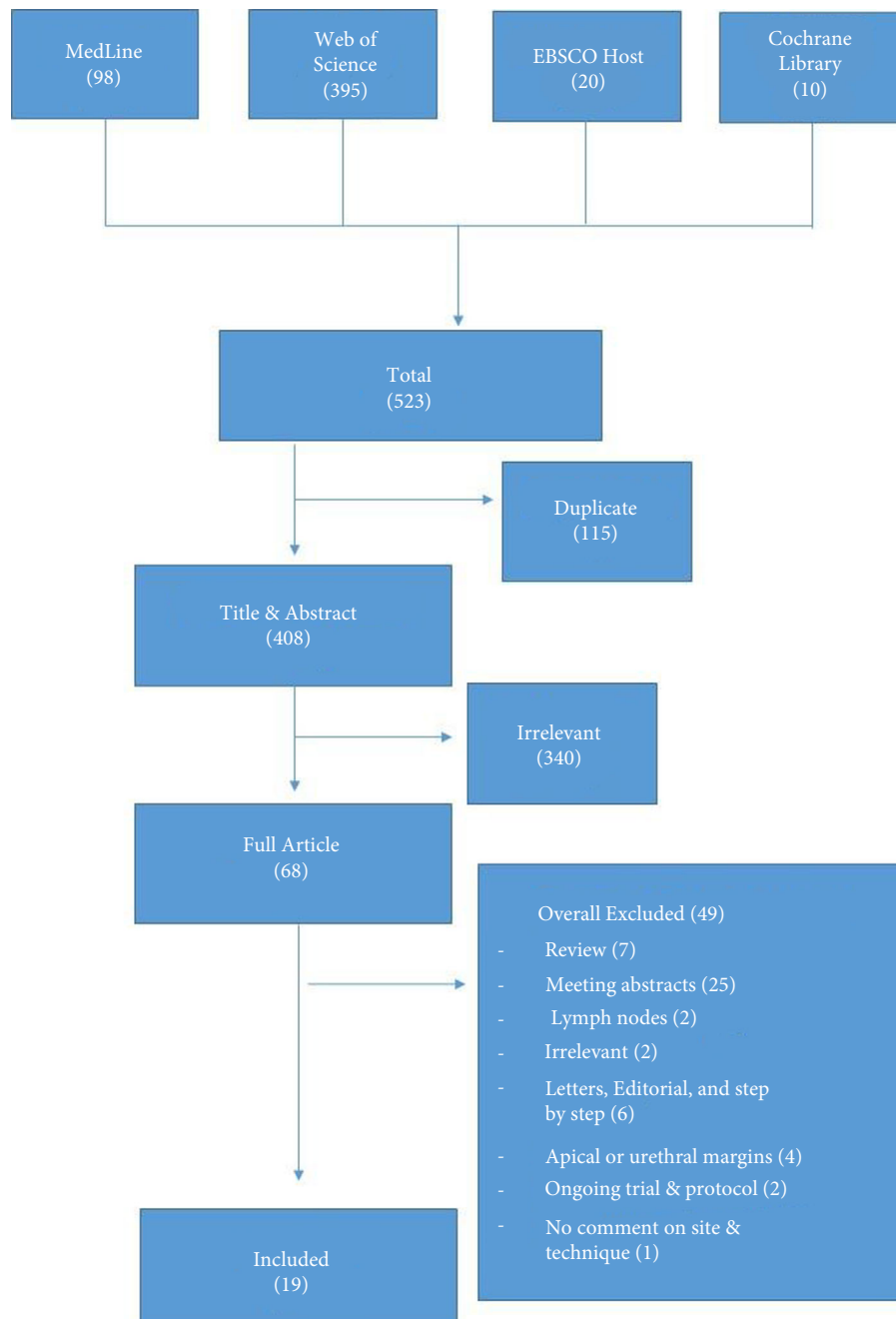
(seven studies) [6,11–16], the UK (four studies) [17–20], USA (three studies) [21–23], Turkey (two studies) [24,25], Italy [26], Romania [27], and Norway [28] (one study each). The sample size (considering only the patients undergoing intraoperative FS) in the included studies ranged from 40 to 5392 patients.

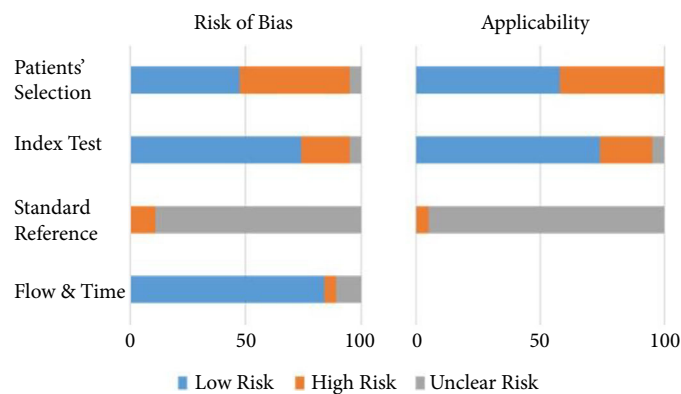
### Assessment of the Risk of Bias

The QUADAS-2 tool outcomes for all the included studies are summarised in (Fig. 2). This tool is mainly used for the

assessment of four territories for any potential risk of bias: patients' selection, index test, standard reference, and time and flow. The patients' selection showed high risk of bias in nearly half of the reports, as most of the authors included patients based on surgeon's preference or the suspicion of the presence of a PSM. Furthermore, the index test showed high risk of bias in a few studies, as the authors did not report the full technique of assessment or did not define PSMs. As regards the reference standard, almost all of the studies showed unclear risk of bias, as none of the authors reported

**Fig. 1** Summary of the search.



**Fig. 2** Summary of the assessment of the risk of bias.

any data about blinding of the pathologists about the patients' characteristics and the results of the FS examination. On the contrary, the time and flow domain showed low risk of bias in most of the studies.

### FS Sampling and NVB Secondary Resection

A total of 19 articles reporting on NS-zone sampling techniques and NVB secondary resection were published between 2010 and 2019 [6,11–28]. Table 1 summarises all the studies reporting FS sampling and secondary resection of a PSM at the NVB. According to this overview, FS assessment of the NS area could be either systematic, MRI-guided or based on random biopsies. The systematic sampling of the NVB zone includes a wedge section of the specimen at the neurovascular structure adjacent prostatic tissue, from the apex to the base on both sides (Fig. 3a); each part is dissected into 10–25 blocks of 3–4 mm, for a lateral circumferential analysis of the inked prostate surface [6,11–14,16,18,20,23–25,28]. The multiparametric MRI (mpMRI)-guided sampling consists of the marking of the area(s) of suspicious ECE at mpMRI on the NVB zone; biopsies were obtained from the suspicious areas and analysed by FS [17,27]. The random approach includes biopsies from periprostatic soft tissues retrieved in cases of suspicious ECE based on an individual surgeon's decision and/or visual suspicion (Fig. 3c) [15,19,21,22,26]. Furthermore, Jeong et al. [29], demonstrated that random biopsies can be obtained from suspicious areas on palpation of the prostatic specimen (bimanual examination); however, this manuscript was not included in the present review as it was just a step-by-step description of the technique without inclusion of any patients or results. Additionally, a single author (Obek et al. [25]) reported the systematic sampling of the entire prostate with whole circumferential assessment (Istanbul preserve).

For the management of a persistent prostate cancer at the SM the techniques employed included: the full secondary resection

of the NVB, its partial resection, or a partial resection with a graded incremental retrieval of additional tissue until a negative SM was obtained. A systematic full resection of the NVB was used by 10 authors [6,11,13,14,16,18,20,25,26,28]. It consists of the identification and separation of the caudal and cranial aspects of the NVBs, separated over clips or Hem-o-Lok; the NVB is then released and excised. The resection often includes the rectolateral part of the Denonvilliers' fascia. It can be performed either before the completion of the anastomosis or afterwards, as the last step of the intervention. A partial resection of the NVBs was performed when the sampling attempted to localise a PSM, traced on the corresponding NS zone [12,17,25,27]. Hatzichristodoulou et al. [12] described in detail his method for performing a partial resection, retrieving a tangential lamella 1–2 cm in length and 3–5 mm in thickness from the point suspicious for PSM contiguity. A mere incremental approach was reported mainly from a few preliminary series, where additionally resected specimens are FS examined until no prostate tissue or carcinoma was identified [15,17,21,23,24]. Finally, two authors reported that secondary resection was performed without reporting any details about its technique [19,22]. The FS time was reported by 10/19 reports and it ranged from 17–30 min for random sampling and 30–35 min for systematic and mpMRI-guided sampling techniques; however, it should be noted that the FS time for the systematic sampling of the entire prostate was prolonged to 57 min [25].

### Oncological and Functional Outcomes after FS

Table 2 [6,11–28] summarises the results of the FS analysis and final histopathology of the included studies as regards the presence of PSM. For oncological outcomes, the rate of PSM reduction was reported by 12/19 authors and ranged from 5% [28] to 19.6% [12] (the reduction in the PSM rates was either reported directly by the authors or calculated based on a comparison with a non-FS group of patients). Furthermore, seven studies reported the histopathological results of the secondary resection specimen, showing that the rate of positivity ranged from 16.1% [12] to 60% [18]. Biochemical recurrence-free survival (BRFS) was assessed by Lavery et al. [23], Schlomm et al. [6], Emiliozzi et al. [26], and Hatzichristopoulou et al. [12], with the main finding of similar BRFS rates between patients with an initial negative SM and those with a PSM converted to negative after secondary resection.

On the other hand, functional outcomes were reported only in five papers where NS and FS were carried out, reporting better continence and erectile functions [12,18,20,23,28]. Interestingly, Hatzichristopoulou et al. [12] compared the continence outcomes (95.8% vs 94.3%) and erectile function (65.7% vs 56.1%) between patients with a primarily negative SM and those with PSM converted to negative, reporting that there was no significant difference between both groups.

**Table 1** Summary of the FS sampling and secondary resection of the included studies.

Sampling	Reference	Country	N	Operative technique	Sampling decision	FS area	Secondary resection	FS time, min
Random	Emiliozzi et al., 2010 [26]	Italy	270	LRP	NA	Multiple	Full	17
	Gillitzer et al., 2011 [15]	Germany	178	RRP	NA	Multiple	Full, incremental	NA
	Kakiuchi et al., 2013 [22]	USA	1128	RALP	Individual decision	Multiple	NA 'additional tissue is often excised'	NA
	Wambi et al., 2013 [21]	USA	335	RALP	Visual suspicion	Multiple	Full, incremental	30
	Nunez et al., 2016 [19]	UK	71	RALP, LRP	NA	Multiple	NA 'yielding additional excisions from positive sites'	NA
	Heinrich et al., 2010 [16]	Germany	130	RRP	Individual decision	NVB	Full	NA
	Lavery et al., 2011 [23]	USA	177	RALP	Visual suspicion	NVB	Incremental	NA
	Schlomm et al., 2012 [6]	Germany	5392	RRP, RALP, LRP	Routine	NVB	Full	35
	Akin et al., 2013 [24]	Turkey	66	RALP	NA	Multiple	Incremental	NA
	Von Bodman et al., 2013 [14]	Germany	236	RRP, RALP	NA	Multiple	Full	35
Beyer et al., 2014 [13]	Germany	1040	RALP	NA	NVB	Full	35	
Hatzichristodoulou et al., 2016 [12]	Germany	471	RRP	NA	NVB	Partial	30	
Vasdev et al., 2016 [18]	UK	40	RALP	NA	NVB	Full	31	
Mirmilstein et al., 2018 [20]	UK	120	RALP	NA	NVB	Full	NA	
Obek et al., 2018 [25]	Turkey	170	RALP	NA	Entire prostate	Full or partial	57	
Fossa et al., 2019 [28]	Norway	95	Mainly RALP	NA	NVB	Full	NA	
Preisser et al., 2019 [11]	Germany	156	RALP, RRP	NA	NVB	Full	NA	
Petralla et al., 2015 [17]	UK	134	RALP	NA	Multiple	Full or partial, incremental	30	
Bianchi et al., 2016 [27]	Romania	254	RALP	NA	NVB	Full or partial	35	

LRP, laparoscopic RP; NA, not available; RRP, retroperitoneal RP.

## Discussion and Clinical Implications

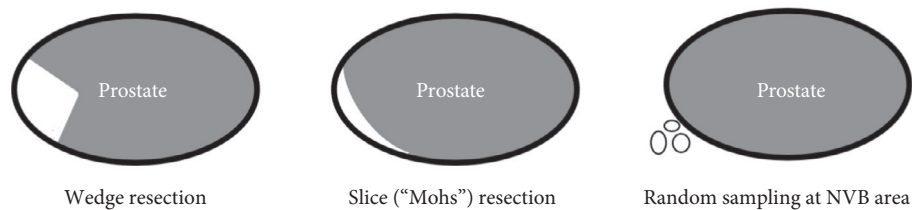
Indications for NS in RP are continuously evolving in accordance with the European Association of Urology guidelines [1], together with the concerns regarding surgical pre-planning based on nomograms and mpMRI [2,3,30] the role of real-time control of surgical dissection has emerged; in such a scenario, the intraoperative analysis of removed tissue is the cornerstone, i.e. FS. As a PSM is an adverse outcome of RP that is associated with worse oncological endpoints [31], knowledge of the SM status during surgery helps in tailoring the next steps of RP based on the individual aggressiveness and extension of the prostate cancer.

FS analysis represents the most consolidated way to have SM status assessed intraoperatively [4]. However, the intrinsic role of FS analysis, with subsequent surgical conversion from PSM to negative SM status, has been recently argued in an editorial from Herlemann and Meng [32]. The authors stated that, especially in the setting of high-risk diseases, the significance of a PSM seems to be overcome by other features of aggressiveness, such as advanced pT or high Gleason Score; in these cases, oncological prognosis seems to be driven mainly by the aforementioned variables rather than a PSM, either converted to a negative status or not.

Given these concerns, the aim of the present review was to report the state-of-the-art of intraoperative SM assessment, addressing separately the method to attain FS and the surgical management of a PSM in the NS zone. Herein, two comments arise.

First, we found variability in the way of sampling of the NS area. A total of 12 studies [6,11–14,16,18,20,23–25,28] described a systematic wedge approach to sample the posterolateral aspect of the specimen, the same (or similar) to the one described by Schlomm et al. [6] in 2012. To reduce time, Oxley et al. [33] suggested a slice ('Mohs') section of the posterolateral aspect of the prostate (Fig. 3b); the article has not been included as it was a 'proof-of-concept' study. Two authors described a focal sampling of the NS area guided by mpMRI; suspicious zones at imaging are manually traced by the surgeon on the specimen, in a cognitive way, and analysed with FS [17,27]. Finally, a random sampling of periprostatic soft tissue including the NVB area was performed in only five series [15,19,21,22,26], where it was mainly driven by 'surgeon's choice'. Remarkably, outcomes from these last trials were the least endorsing of FS, with the authors' concluding that 'FS analysis did not dramatically change SM status' [22], 'FS cannot be used to predict the overall final margin status' [19], 'FS do not significantly affect prognosis' [15], and 'FS is not supported during radical prostatectomy' [26]. The imprecise and subjective identification of the exact soft tissue location contiguous to the PSM, together with a focal sampling, could explain the low effectiveness of FS in these datasets.



**Fig. 3** Methods for posterolateral SM assessment: **a.** wedge; **b.** slice ('Mohs'); **c.** random.**Table 2** Summary of the results of FS and histopathology of the included studies.

Reference	PSM at FS, %	PSM at final pathology, %	Positive SNR at histopathology, %	PSM reduction, %
Emiliozzi et al., 2010 [26]	24.8	12.6	NA	12.2
Gillitzer et al., 2011 [15]	10.7 (3.4 at NVB)	27.5 (14.6 at NVB)	NA	NA
Kakiuchi et al., 2013 [22]	5.3	9.7 (2 at NVB)	NA	NA
Wambi et al., 2013 [21]	3 (at NVB)	9 (at NVB)	NA	NA
Nunez et al., 2016 [19]	15.5	NA	NA	NA
Heinrich et al., 2010 [16]	6.9	3.1 (0.7 at NVB)	NA	NA
Lavery et al., 2011 [23]	6	7	NA	11
Schlomm et al., 2012 [6]	27.2	15	23	7
Akin et al., 2013 [24]	4.5	37.9	NA	NA
Von Bodman et al., 2013 [14]	22	3	25	19
Beyer et al., 2014 [13]	29.6	0.2 (at NVB)	39.8	7.8
Hatzichristodoulou et al., 2016 [12]	29.1	4.9	16.1	19.6
Vasdev et al., 2016 [18]	25	7.8	60	16.9
Mirmilstein et al., 2018 [20]	NA	9.2	42.2	8.6
Obek et al., 2018 [25]	33	7.6	37	14.9
Fossà et al., 2019 [28]	NA	12	NA	5
Preisser et al., 2019 [11]	NA	15.4	NA	14.1
Petralia et al., 2015 [17]	13.4	7.5	NA	11.2
Bianchi et al., 2016 [27]	29.1	15.75	NA	NA

SNR, secondary resection.

This occurrence is consistent with the recent finding from Pak et al. [34] (the paper is not included in the present review as it considers only SM from the apical and basal periprostatic tissue without including the NVB area). In the paper, they failed to find benefits of FS analysis and incremental resection in high-risk patients, concluding that tumour biology is the major determinant of disease recurrence [34]. However, given the constrained value of FS analysis of limited areas, one could argue that systematic sampling of the prostate surface would lead to a higher detection of PSM and thus improve conversion to a negative SM status.

The second comment from the present review deals with the variability we found in surgical techniques to realise the complete excision of the persisting prostatic tissue. A total of 11 studies performed a full resection of the NVB ipsilateral to a PSM [6,11,13–16,18,20,21,26,28]; four reported the attempt of a partial resection, defining with approximation of the site of persisting tumour or resecting the NVB in the area of a PSM targeted on MRI findings [12,17,25,27]. Finally, some authors mentioned an incremental approach to achieve a negative SM: the resection of periprostatic tissue was repeated until the

absence of prostate cancer or benign prostatic tissue in the specimen [15,23,24]. Whether one method is better than another, still remains questionable, given the variability of sampling technique at the very basis; meanwhile, it should be stressed that the preservation of 'as many NVB structures as possible' is crucial to improve both continence and erectile function recovery [35,36].

It should be noted that systematic sampling does not allow precise tracking of the persistent cancer inside the spared bundle; this occurrence may result in an unnecessary and untailed resection of the whole NVB.

Finally, the present review raises concerns about the great heterogeneity of the FS sampling techniques and the management approaches for PSMs, which may be responsible for the different results and the absence of high-level evidence on the actual value of FS analysis of SMs during RP.

There are some limitations that should be considered: the inclusion of open, laparoscopic and robot-assisted procedures; the great heterogeneity of the included studies that limited the performance of a meta-analysis; and the high risk of bias in the included studies. Given these limits, the present review

is the first overview of the literature reporting the state-of-the-art methods for FS analysis and managing a PSM finding intraoperatively.

Future research and endpoints to be pursued should be: (i) Traceability of a PSM on the corresponding spared NVB; (ii) the implementation of NS as the main endpoint, especially in patients otherwise not suitable for NVB preservation; (iii) the assessment of long-term data from both an oncological (BRFS) and functional point of view.

## Conclusion

Intraoperative control of the plane of dissection could help to extend the NS approach to patients currently not eligible for NVB preservation. The present analysis highlighted the great variability and the absence of standardisation in FS sampling methods and secondary resection of the NVB, possibly limiting the oncological benefit of FS analysis throughout the reported series. Similarly, the way to convert a PSM to a negative status is still heterogeneous, with sporadic attempts to perform a partial resection to spare as much NVB tissue as possible.

Consequently, a more standardised approach to prostatic sampling for FS analysis and a more precise localisation of the PSM on the spared NVB could be regarded as future directions to improve intraoperative tailoring of surgical dissection.

## Conflict of Interest

The authors' declare that they have no conflict of interest regarding the publication of this paper.

## References

- Sighinolfi MC, Rocco B. Re: EAU guidelines: prostate cancer 2019. *Eur Urol* 2019; 76: 871.
- Eissa A, Elsherbiny A, Zoerir A et al. Reliability of the different versions of Partin tables in predicting extraprostatic extension of prostate cancer: a systematic review and meta-analysis. *Minerva Urol Nefrol* 2019; 71: 457–78
- Rocco B, Sighinolfi MC, Sandri M et al. Is extraprostatic extension of cancer predictable? A review of predictive tools and an external validation based on a large and a single center cohort of prostate cancer patients. *Urology* 2019; 129: 8–20
- Eissa A, Zoerir A, Sighinolfi MC et al. "Real-time" assessment of surgical margins during radical prostatectomy: state-of-the-art. *Clin Genitourin Cancer* 2019 [Epub ahead of print]. <https://doi.org/10.1016/j.clgc.2019.07.012>
- Yossepowitch O, Briganti A, Eastham JA et al. Positive surgical margins after radical prostatectomy: a systematic review and contemporary update. *Eur Urol* 2014; 65: 303–13
- Schlomm T, Tennstedt P, Huxhold C et al. Neurovascular structure-adjacent frozen-section examination (NeuroSAFE) increases nerve-sparing frequency and reduces positive surgical margins in open and robot-assisted laparoscopic radical prostatectomy: experience after 11,069 consecutive patients. *Eur Urol* 2012; 62: 333–40
- Porpiglia F, Checucci E, Amparore D et al. Three-dimensional elastic augmented-reality robot-assisted radical prostatectomy using hyperaccuracy three-dimensional reconstruction technology: a step further in the identification of capsular involvement. *Eur Urol* 2019; 76: 505–14
- Puliatti S, Bertoni L, Pirola GM et al. Ex vivo fluorescence confocal microscopy: the first application for real-time pathological examination of prostatic tissue. *BJU Int* 2019; 124: 469–76
- Liberati A, Altman DG, Tetzlaff J et al. The PRISMA statement for reporting systematic reviews and meta-analyses of studies that evaluate healthcare interventions: explanation and elaboration. *BMJ* 2009; 339: b2700. <https://doi.org/10.1136/bmj.b2700>
- Whiting PF, Rutjes AW, Westwood ME et al. QUADAS-2: a revised tool for the quality assessment of diagnostic accuracy studies. *Ann Intern Med* 2011; 155: 529–36
- Preisser F, Theissen L, Wild P et al. Implementation of intraoperative frozen section during radical prostatectomy: short-term results from a German tertiary-care center. *Eur Urol Focus* 2019 [Epub ahead of print]. <https://doi.org/10.1016/j.euf.2019.03.007>
- Hatzichristodoulou G, Wagenpfeil S, Weirich G et al. Intraoperative frozen section monitoring during nerve-sparing radical prostatectomy: evaluation of partial secondary resection of neurovascular bundles and its effect on oncologic and functional outcome. *World J Urol* 2016; 34: 229–36
- Beyer B, Schlomm T, Tennstedt P et al. A feasible and time-efficient adaptation of NeuroSAFE for da Vinci robot-assisted radical prostatectomy. *Eur Urol* 2014; 66: 138–44
- von Bodman C, Brock M, Roghmann F et al. Intraoperative frozen section of the prostate decreases positive margin rate while ensuring nerve sparing procedure during radical prostatectomy. *J Urol* 2013; 190: 515–20
- Gillitzer R, Thuroff C, Fandel T et al. Intraoperative peripheral frozen sections do not significantly affect prognosis after nerve-sparing radical prostatectomy for prostate cancer. *BJU Int* 2011; 107: 755–9
- Heinrich E, Schon G, Schiefelbein F, Michel MS, Trojan L. Clinical impact of intraoperative frozen sections during nerve-sparing radical prostatectomy. *World J Urol* 2010; 28: 709–13
- Petralia G, Musi G, Padhani AR et al. Robot-assisted radical prostatectomy: multiparametric MR imaging-directed intraoperative frozen-section analysis to reduce the rate of positive surgical margins. *Radiology* 2015; 274: 434–44
- Vasdev N, Agarwal S, Rai BP et al. Intraoperative frozen section of the prostate reduces the risk of positive margin whilst ensuring nerve sparing in patients with intermediate and high-risk prostate cancer undergoing robotic radical prostatectomy: first reported UK series. *Curr Urol* 2016; 9: 93–103
- Nunez AL, Giannico GA, Mukhtar F, Dailey V, El-Galley R, Hameed O. Frozen section evaluation of margins in radical prostatectomy specimens: a contemporary study and literature review. *Ann Diagn Pathol* 2016; 24: 11–8
- Mirmilstein G, Rai BP, Gbolahan O et al. The neurovascular structure-adjacent frozen-section examination (NeuroSAFE) approach to nerve sparing in robot-assisted laparoscopic radical prostatectomy in a British setting – a prospective observational comparative study. *BJU Int* 2018; 121: 854–62
- Wambi CO, Patel T, Shapiro EY et al. Findings of routine apical margin biopsy during robot-assisted radical prostatectomy. *J Laparoendosc Adv Surg Tech Part B* 2013; 23: 511–5
- Kakiuchi Y, Choy B, Gordetsky J et al. Role of frozen section analysis of surgical margins during robot-assisted laparoscopic radical prostatectomy: a 2608-case experience. *Hum Pathol* 2013; 44: 1556–62
- Lavery HJ, Xiao GQ, Nabizada-Pace F, Mikulasovich M, Unger P, Samadi DB. 'Mohs surgery of the prostate': the utility of in situ frozen section analysis during robotic prostatectomy. *BJU Int* 2011; 107: 975–9

- 24 Akin Y, Avci E, Gulmez H et al. Indications for intraoperative frozen section in robot assisted radical prostatectomy: a pilot study. *Eur Rev Med Pharmacol Sci* 2013; 17: 2523–9
- 25 Obek C, Saglican Y, Ince U et al. Intra-surgical total and re-constructible pathological prostate examination for safer margins and nerve preservation (Istanbul preserve). *Ann Diagn Pathol* 2018; 33: 35–9
- 26 Emiliozzi P, Amini M, Pansadoro A, Martini M, Pansadoro V. Intraoperative frozen section in laparoscopic radical prostatectomy: impact on cancer control. *Arch Ital Urol Androl* 2010; 82: 164–9
- 27 Bianchi R, Cozzi G, Petralia G et al. Multiparametric magnetic resonance imaging and frozen-section analysis efficiently predict upgrading, upstaging, and extraprostatic extension in patients undergoing nerve-sparing robotic-assisted radical prostatectomy. *Medicine (Baltimore)* 2016; 95: e4519. <https://doi.org/10.1097/MD.00000000000004519>
- 28 Fosså SD, Beyer B, Dahl AA et al. Improved patient-reported functional outcomes after nerve-sparing radical prostatectomy by using NeuroSAFE technique. *Scand J Urol* 2019; 53: 385–91
- 29 Jeong W, Sood A, Ghani KR et al. Bimanual examination of the retrieved specimen and regional hypothermia during robot-assisted radical prostatectomy: a novel technique for reducing positive surgical margin and achieving pelvic cooling. *BJU Int* 2014; 114: 955–7
- 30 de Rooij M, Hamoen EH, Witjes JA, Barentsz JO, Rovers MM. Accuracy of magnetic resonance imaging for local staging of prostate cancer: a diagnostic meta-analysis. *Eur Urol* 2016; 70: 233–45
- 31 Zhang L, Wu B, Zha Z, Zhao H, Jiang Y, Yuan J. Positive surgical margin is associated with biochemical recurrence risk following radical prostatectomy: a meta-analysis from high-quality retrospective cohort studies. *World J Surg Oncol* 2018; 16: 124. <https://doi.org/10.1186/s12957-018-1433-3>
- 32 Herlemann A, Meng MV. Editorial: Conversion to negative surgical margin after intraoperative frozen section – (un)necessary effort and relevance in 2019? *BJU Int* 2019; 123: 744–6
- 33 Oxley J, Bray A, Rowe E. Could a Mohs technique make NeuroSAFE a viable option? *BJU Int* 2018; 122: 358–9
- 34 Pak S, Park S, Kim M, Go H, Cho YM, Ahn H. The impact on oncological outcomes after radical prostatectomy for prostate cancer of converting soft tissue margins at the apex and bladder neck from tumour-positive to -negative. *BJU Int* 2019; 123: 811–7
- 35 Novara G, Ficarra V, Mocellin S et al. Systematic review and meta-analysis of studies reporting oncologic outcome after robot-assisted radical prostatectomy. *Eur Urol* 2012; 62: 382–404
- 36 Suardi N, Moschini M, Gallina A et al. Nerve-sparing approach during radical prostatectomy is strongly associated with the rate of postoperative urinary continence recovery. *BJU Int* 2013; 111: 717–22

**Correspondence:** Maria Chiara Sighinolfi, Department of Urology, University of Modena & Reggio Emilia, Via del Pozzo 71, 41100 Modena, Italy.

**e-mail:** [sighinolfic@yahoo.com](mailto:sighinolfic@yahoo.com)

**Abbreviations:** BRFS, biochemical recurrence-free survival; ECE, extracapsular extension; FS, frozen section; mpMRI, multiparametric MRI; NS, nerve-sparing; NVB, neurovascular bundle; PSM, positive surgical margin; QUADAS-2, Quality Assessment of Diagnostic Accuracy Studies-2; RALP, robot-assisted laparoscopic radical prostatectomy; RP, radical prostatectomy; SM, surgical Margin.