Accepted Manuscript

DIBH (Deep Inspiratory Breath Hold)-based radiotherapy – a clinical review

Judit Boda-Heggemann, MD, PhD, Antje-Christin Knopf, PhD, Anna Simeonova, MD, Hansjörg Wertz, PhD, Florian Stieler, PhD, Anika Jahnke, PhD, Lennart Jahnke, PhD, Jens Fleckenstein, PhD, Lena Vogel, MSc, Anna Arns, MSc, Manuel Blessing, PhD, Frederik Wenz, MD, Frank Lohr, MD

PII: S0360-3016(15)26850-2

DOI: 10.1016/j.ijrobp.2015.11.049

Reference: ROB 23311

To appear in: *International Journal of Radiation Oncology • Biology • Physics*

Received Date: 3 July 2015

Revised Date: 3 November 2015

Accepted Date: 29 November 2015

Please cite this article as: Boda-Heggemann J, Knopf A-C, Simeonova A, Wertz H, Stieler F, Jahnke A, Jahnke L, Fleckenstein J, Vogel L, Arns A, Blessing M, Wenz F, Lohr F, DIBH (Deep Inspiratory Breath Hold)-based radiotherapy – a clinical review, *International Journal of Radiation Oncology • Biology • Physics* (2016), doi: 10.1016/j.ijrobp.2015.11.049.

DIBH (Deep Inspiratory Breath Hold)-based radiotherapy – a clinical review

***Running title*: DIBH-based radiotherapy – a clinical review**

[1]Judit Boda-Heggemann MD, PhD*; [2]Antje-Christin Knopf, PhD*; [1]Anna Simeonova MD, [1]Hansjörg Wertz PhD, [1]Florian Stieler PhD, [1]Anika Jahnke PhD, [1]Lennart Jahnke PhD, [1]Jens Fleckenstein PhD, [1]Lena Vogel MSc, [1]Anna Arns MSc, [1]Manuel Blessing PhD, [1]Frederik Wenz MD, [1]Frank Lohr MD

[1]Department of Radiation Oncology, University Medical Center Mannheim, University of Heidelberg, Mannheim, Germany

[2]The Institute of Cancer Research, Royal Cancer Hospital, London, GB

**Authors contributed equally to this publication*

[1]Department of Radiation Oncology

University Medical Center Mannheim

University of Heidelberg

Theodor-Kutzer Ufer 1-3

68167 Mannheim/Germany

Tel: +49-621-383-4960

Fax: +49-621-383-3493

e-mail: judit.boda-heggemann@umm.de (address for correspondence)

COIs:

Dr. Boda-Heggemann reports personal fees from Elekta AB, Sweden, during the conduct of the study; .

Dr. Knopf, J. Fleckenstein, L. Vogel and Dr. Stieler have nothing to disclose.

Dr. Lennart Jahnke reports personal fees from Elekta AB, Sweden, during the conduct of the study; .

Dr. Anika Jahnke, A. Arns and Dr. Manuel Blessing report personal fees from Elekta AB, Sweden, during the conduct of the study; .

Dr. Wenz reports personal fees from Elekta AB, Sweden, during the conduct of the study; .

Dr. Lohr reports grants and personal fees from Elekta AB, grants and personal fees from IBA, personal fees from C-RAD, during the conduct of the study.

Dr. Simeonova reports personal fees from Elekta AB, Sweden, during the conduct of the study; .

DIBH (Deep Inspiratory Breath Hold)-based radiotherapy – a clinical review

***Running title*: DIBH-based radiotherapy – a clinical review**

Abstract:

Several recent developments in linear-accelerator-based radiotherapy such as fast multileaf collimators, accelerated intensity modulation paradigms like VMAT and flattening filter-free (FFF) high-dose-rate therapy have dramatically shortened the duration of treatment fractions. Deliverable photon dose distributions have approached physical complexity limits as a consequence of precise dose calculation algorithms and online 3D-image-guided patient positioning (Image-Guided RadioTherapy, IGRT).

Simultaneously, beam quality and treatment speed have continuously been improved in particle beam therapy, especially for scanned particle beams.

Applying complex treatment plans with steep dose gradients requires strategies to mitigate/compensate for motion effects in general and particularly for breathing motion. Intrafractional breathing-related motion results in uncertainties in dose delivery and thus in target coverage. As a consequence, generous margins have been used, which, in turn, increases organ-at-risk (OAR) exposure. Particle therapy, particularly with scanned beams, poses additional problems such as interplay effects and range uncertainties. Among advanced strategies to compensate breathing motion such as beam gating and tracking, DIBH-gating is particularly advantageous in several respects, not only for hypofractionated, high single-dose Stereotactic Body RadioTherapy (SBRT) of lung-, liver- and upper abdominal lesions but also for normofractionated treatment of thoracic tumors such as lung cancer, mediastinal lymphomas and breast cancer. This review provides an in-depth discussion of the rationale and technical implementation of DIBH-gating for hypo-and normofractionated radiotherapy of intrathoracic and upper abdominal tumors in photon and proton radiation therapy.

Key words: DIBH (Deep Inspiratory Breath Hold), motion management; breathing motion, gating, SBRT (Stereotactic Body Radiotherapy), IGRT (Image-Guided RadioTherapy), Proton therapy, Particle Therapy

Table of contents

Introduction

Several recent developments in linear-accelerator-based photon radiotherapy such as intensity modulated radiotherapy (IMRT, [1]) and volumetric modulated arc therapy (VMAT, [2, 3]) allow the application of highly complex treatment plans with steep dose gradients. Photon dose distributions in rigid treatment volumes have approached physically achievable complexity and accuracy limits as a consequence of the introduction of precise dose calculation algorithms (e.g. [4]), daily online soft-tissue based 3-dimensional image-guided patient/target positioning (IGRT, Image-Guided RadioTherapy, [5, 6]) and continuously improved delivery devices with fast collimators [7]. Flattening-filter-free (FFF) high-dose-rate applications [8-15] have dramatically accelerated small-field delivery, particularly for the SBRT (stereotactic body radiotherapy) paradigm while maintaining biological properties of the beam [16, 17]. It has several further advantages such as less scatter from the treatment source, less leaf transmission and head leakage [1, 18].

The combination of all these technical possibilities has refined and accelerated [8] the therapy of both large stationary targets like head and neck cancer [19, 20] as well as smaller mobile targets, resulting in clinical benefits such as excellent local control rates in the treatment of early NSCLC (Non-Small-Cell-Lung-Cancer) or lung/liver metastases with Stereotactic Body Radiation Therapy (SBRT, [21-26]) with very reasonable total treatment times now in the range of 15 min per treatment fraction.

Proton therapy is now applied with increasing frequency, with new treatment facilities being activated on a regular basis. It has made significant technological progress recently with more widespread use of scanned beams and the introduction of 3D-Image-Guidance. Nine times rescanning of a one liter volume within one minute is now technically feasible, bringing into reach treatment deliveries during the time span of one breath hold [27]. An innovative design for image guidance is the integration of a beams-eye view (BEV) imager at Gantry 2 at PSI (Paul Scherrer Institute) in Switzerland, which is a fast parallel beam

scanning proton therapy unit with small spot size and penumbra, allowing X-ray imaging in fluoroscopy mode during treatment delivery [27, 28]. However, target motion implies a much bigger challenge for proton therapy than for photon therapy, especially for a scanned delivery where interplay effects can significantly disturb the planned dose distribution [29]. Furthermore, image guided approaches are much more advanced in photon radiotherapy and online 3D motion monitoring has not been realized for particle therapy to date [30].

Despite constant efforts to mitigate motion effects [31-33] in both advanced photon and proton therapy of body regions that are affected by breathing motion with motion amplitudes of up to 2-3 cm and potentially including hysteresis and deformations [34] there are still methodical improvements needed. Resolving remaining issues may improve the treatment of several disease entities/clinical situations. Among these are:

- Radiotherapy of locally advanced NSCLC, where escalated doses in combination with chemotherapy may improve local control [35, 36], but are limited by normal lung tolerance and methodical imprecisions. Insufficient target coverage prompted by concerns about lung toxicity may have contributed to a lack of efficacy of dose escalation in the treatment of locally advanced lung cancer in the randomized RTOG trial 0617 [37, 38].
- Exposed lung volume also plays a role in considerations regarding secondary malignancy after radiotherapy of all mediastinal tumors [39, 40]. Exposed heart volume after mediastinal or breast radiotherapy is linked to long-term cardiac toxicity [41-46].
- Treatment of non-static targets with passively scattered proton beams, which currently is not unlocking its full potential due to limitations on image guidance.
- Treatment of non-static targets with scanned proton beams, which has only been performed rarely clinically until to date because of concerns regarding interplay-effects [47].

This review describes the different methods and characteristics of available motion management strategies in photon and proton radiation therapy and then outlines how DIBH can be efficiently performed and where it may resolve or mitigate the issues and unmet methodical needs described above. Table 1 provides a synopsis of the dosimetric and clinical characteristics of DIBH treatments and compares them with other currently available motion management strategies regarding advantages and disadvantages.

1. Breathing-motion management strategies/methods

Even for short beam-on times now achievable with FFF-treatments, motion management strategies are necessary to compensate for intrafractional breathing motion. Different strategies aim at a reduction of margins between clinical target volume (CTV) and planning target volume (PTV) and/or improved geometrical precision of dose delivery:

- Motion amplitude of free breathing can be reduced by *mechanical abdominal compression* [48]. Recently however, it has been shown that it is only beneficial for lower lobe tumors and has no or a negative effect for middle/upper lobe tumors [49]. While the *intra*fractional amplitude of tumor motion can be reduced by abdominal compression, *inter*fraction motion can be even increased [50]. Mechanical abdominal compression has also been evaluated theoretically [51] and used clinically in particle therapy to reduce intrafractional motion [52].
- One of the most widely used strategies is treatment planning with individual determination of CTV-PTV margins *based on a 4D-CT* in free breathing [33, 53]. 4D-planning requires appropriately chosen PTV-margins (Internal Target Volume (ITV) concept) considering the end-expiratory and end-inspiratory position of the tumor. Inclusion of all breathing phases during the actual treatment ensures optimal

treatments for small tumors but results in increasing volumes of healthy lung tissue exposed to high doses with increasing CTVs if CTV-PTV-margins are kept constant [54]. For particle therapy, in addition to geometrical considerations, also changes in tissue densities due to motion that affect the particle range, have to be considered when designing margins [55]. Several publications have recently reported uncertainties in the 4DCT-approach regarding breathing pattern [56], motion uncertainties, dosimetry and verification difficulties. Uncertainties have been shown regarding 4DCT-based motion measurements for lung SBRT. Confirmed by MV (MegaVoltage) imaging during beam-on, Zhang et al. [57] have shown that 4DCT may underestimate the overall maximum tumor motion range during lung SBRT. For liver SBRT, a single 4DCT for planning was not always correctly representing the mean motion amplitude (measured by kV (kilovoltage) and MV marker-based imaging) during treatment [58]. A large variation of intra- and interfractional motion patterns for various targets has been also observed [59], especially in antero-posterior direction and in a fraction-duration dependent manner [60, 61]. Measurements of motion of implanted fiducials with daily orthogonal fluoroscopy have shown that 4DCT overestimates daily 3D motion in 39% and underestimated in 53% of the fractions. Breathing pattern varied from breath to breath and from day to day and intrafractional variation of the amplitude was significantly larger than interfractional variation [61]. Free-breathing CBCT potentially underestimates ITV if the respiratory pattern is characterised by a disparate length of time spent in inspiration vs. expiration, potentially leading to misalignments, depending also on tumor size and localisation [62, 63]. 4D-CBCT is the logical continuation of the 4D-concept through the whole treatment chain. It has become available recently and remedies several of the abovementioned issues but trades image quality for time

resolution [64-66]. In particle therapy, the value of 4D-MR imaging has been explored which enables the capturing of motion variations and drift effects [67].

- While 4D-treatment planning results in an individualized choice of PTV margins that may result in an expansion of margins compared to the population mean, *real-time target tracking* or *continuous patient position adjustment with robotic treatment couches* with 6 degrees of freedom can minimize PTV margins for all individuals [68, 69]. Several tracking technologies have been clinically established and can, for example be found in the Cyberknife concept [70, 71] or the recently released (and already discontinued) Vero System (Vero SBRT, Brainlab, Feldkirchen, Germany; [72, 73]) with steering of the beam application, or, in an experimental system, with steering of the patient couch [74]. Tracking is typically based on an individual motion model created during treatment planning that is frequently verified by planar EPID-imaging of implanted fiducials or the tumor shadow (when detectable) and/or optical surface tracking (ExacTrac: [75, 76]; Cyberknife: [77]). The clinical introduction of online-4D-Magnetic Resonance Imaging (4DMR) during photon treatment [78, 79] may further advance the concept of instantaneous tumor tracking, but significant developments still have to be made. Tracking seems to be the ideal motion mitigation technique for a steerable particle beam [80]. As it relies on real time 3D imaging information of the patient which is not yet available for particle therapy, it has, however, not been implemented clinically yet.
- *Respiratory gating as free-breathing-gating or with voluntary/computer controlled breath hold* minimizes PTV margins across a patient cohort, similar to what is achieved by tracking. Free-breathing-gating strategies have typically been used during end-*expiration,* which occupies the majority of the breathing cycle. This approach therefore allows for the application of large doses during the gating phase. Plan comparison studies, however, demonstrated that IMRT plans for the *inspiration*

phase of the breathing cycle as deep inspiration breath hold (DIBH) resulted in better V10, V20, V40 and mean lung dose when compared to plans for end-expiration also for normofractionated treatments of advanced lung tumors [54, 81-84]. Gating is the most commonly used motion mitigation technique for particle therapy [85].

- A motion mitigation technique that is unique for scanned particles is rescanning, which refers to repeated irradiations during one treatment fraction to statistically smooth out interplay effects [29]. Rescanning is suggested to be combined with other motion mitigation techniques [86].

The characteristics of DIBH-gating were summarized by a review in the framework of the STIC 2003 (*Soutien aux techniques innovantes couteuses de 2003,* [87]), which confirmed feasibility and good reproducibility of various respiratory-gated radiotherapy (RGRT) systems. Improvement of dosimetric parameters predictive of reduced pulmonary, cardiac and esophageal toxicity by RGRT was described already in this manuscript. Since then, additional data have been published that solidify the rationale for the use of DIBH-gating in various clinical situations and are reviewed in this manuscript.

2. Methods for establishing deep inspiration breath hold (DIBH)

DIBH can be achieved by repeated voluntary breath hold or with computer controlled commercially available devices, which can assist DIBH through airway blocking and/or feedback approaches. Breath hold gating signals now automatically trigger treatments across all major treatment device manufacturers.

a) free DIBH/voluntary breath hold

A fully free (non-computer controlled) breath-hold technique can be used during

radiotherapy for breast cancer aiming at heart, lung and liver dose reduction [88-90]. Voluntary breath hold does not require any additional equipment. To monitor breath-hold, the distance moved by the anterior and lateral skin marks away from room lasers and additional light field verification can be used, therefore voluntary breath hold typically is not completely "uncontrolled" [89]. Despite clear dosimetric benefits (heart and lung) for both 3D tangential and VMAT plans in right- and left sided breast cancer [88, 91, 92] and acceptable precision data even in a randomised setting [92], this method is not yet in widespread use [89], though interest is increasing. The UK HeartSpare study [92] has shown comparable EPI (Electronic Portal Imaging)- and CBCT (cone-beam CT) derived precision data (systematic and random error vector of 3-5mm regarding chest wall position) of voluntary breath hold when compared to computer-controlled breath hold (Active Breathing Coordinator, Elekta). Similar CBCT-based precision data were published by Betgen et al. [93] with good intra-fraction reproducibility of chest-wall position and inter-fraction systematic and random error of 2-5mm and 1.56°. However, in these publications, no position information is provided of OARs (heart/lung) and no intra-fraction EPID verification was performed [92, 93]. Patients and staff preferred voluntary breath hold versus computer-controlled breath hold due to easier workflow and reduced cost [92]. The method seems therefore to be acceptable for breast tangential RT. Given that evaluated patient numbers are low and information on heart/lung position with a 3D soft tissue imaging method (e.g. breath-hold CBCT) was lacking in these studies there is a necessity to further evaluate this issue especially if used in the context of lung/liver RT/SBRT.

b) <u>computer-controlled DIBH</u>

Breathing-volume based methods:

Computer-controlled breath-hold systems aim at creating a static geometrical situation

of the body and the GTV within the body during the planning CT. Breathing volume based methods quantify the inspiration volume with a spirometer. Patient feedback can be established/provided with an open airway audiovisually (a “target zone” is projected on a screen or via video-goggles and the patient is instructed to inhale to reach a certain signal position on the screen [94]), as performed with the SDX System (SpiroDynr’X; France; [87, 95]) or by actually closing the airway for a defined time (as performed with the ABC-System (Elekta AB, Sweden)). Intra- and inter-fractional reproducibility for ABC is 1.7 and 3.7mm [96-103]. Brock et al. [104] measured with repeat breath hold CTs consistent intra-fraction tumor position, but inter-fraction variation of mean (range) values of 5.1 (0-25), 3.6 (0-9.7), and 3.5 (0-16.6) mm in SI, RL and AP directions. However, different breathing maneuvers (thoracic vs. chest breathing) can lead to variations in chest wall position even if inspiration volume is the same, which can lead to uncertainities regarding tumor position [105]. Recently, surface/fiducial tracking methods allow the monitoring of breath hold during one fraction. Data derived from additional optical infrared tracking have shown a mean intrafraction variation vector among breath holds of less than 2.8mm [105]. Uncertainties were observed in the anterioposterior direction (maximal 12mm). This had no influence on target coverage but on OAR doses and therefore optical tracking has been recommended for the surveillance of ABC-based breath-hold [105].

Visual feedback/optical surface detection/tracking

Breath hold with visual feedback requires optimal patient compliance and has been shown to be accurate for lung lesions with intra-fraction reproducibility of <3mm [106, 107]. Intra- and inter-FGBH (Feedback Guided Voluntary Breath hold) with computer controlled visual feedback (video goggle) resulted in a reproducibility of GTV centroid

positions of 1.0±0.5mm, 1.3±1.0mm, and 0.6±0.4mm in AP, SI and LR directions, respectively, compared to more than 1cm of tumor motion at free breathing [106].

An indirect approach for breath hold gating is optical surface tracking as it is established with reflectors within the RPM (Varian, Palo Alto, CA, USA [108]), Exac-Trac (Brainlab, Feldkirchen, Germany) or Synchrony (Accuray, Morges, Switzerland) systems or with markerless systems such as alignRT (VisionRT, London, U.K.), or Catalyst (C-RAD, Uppsala, Sweden [109]).

The markerless systems project visible light on the patient and detect the surface and surface movements caused by respiration. This movement detection can be used to verify the tumor position during respiration and to gate the beam during treatment. Several studies with different systems [110-113] compared the agreement of an optical surface tracking system and cone beam computed tomography regarding static targets and found good agreement between both techniques in most situations, indicating the general robustness of this approach. Alderliesten et al. [114] evaluated the accuracy of a 3D surface imaging system compared to CBCT for the guidance of DIBH-RT of left-sided breast cancer and found a good correlation between setup errors detected by both methods. Daily real-time surface monitoring has been shown to ensure accurate inter- and intrafraction repositioning [115, 116], reduced heart dose and acceptable treatment time of left-sided breast cancer patients especially with unfavorable cardiac anatomy [117-120]. Some data indicate that for left breast cancer radiotherapy, surface monitoring systems are superior to spirometer-based systems regarding repositioning of the external surface [121].

3. Characteristics and advantages of DIBH

a) Possibility to image under DIBH

Serpa et al. [122] have shown that markerless EPID tracking is principally suitable for treatment verification of gated SBRT but marker-based EPID imaging is also being used. For Cyberknife SBRT, breath hold imaging was performed after implantation of 2-4 fiducials directly into the tumor and a maximal tumor vector movement of 3.8mm (detected by kV flat-panel detectors) was reported [123].

Linac-mounted CBCTs that are currently on the market provide the possibility to interrupt imaging/image acquisition with reconstruction after the intended imaging angle has been completed. Such a “stop-and-go” approach allows the acquisition of a complete volume dataset under breathhold [124]. While the acquisition time is longer than that of free-breathing CBCT, image quality is significantly improved over imaging in free-breathing-only, free breathing interlaced with 3-4 breathholds [97, 125] or 4D-CBCT at identical imaging doses. The approach provides superior image quality particularly for middle- and lower-lobe lung tumors (**Fig. 1**) [124] and it also improves soft tissue contrast in upper abdominal lesions (**Fig. 2**). First experiences report feasibility, fastness and better inter-observer variability of DIBH CBCT for lung SBRT [126]. Single-breath-hold CBCT has also been implemented [127] but is not yet broadly used.

A development that is currently undergoing final refinement before clinical testing is combined kV-MV imaging [128, 129] that makes use of both kV and MV imaging devices on a linac in combination with faster gantry movement and dedicated reconstruction algorithms [130, 131]. It offers the possibility to acquire a full 3D-dataset during one breath hold (<15 sec) with acceptable imaging doses and excellent positioning precision [132].

Position of target/surrogate structures in breath-hold for liver/upper abdominal SBRT can be also controlled by stereotactic ultrasound systems [101, 133-135]. Surveillance of breath hold with ultrasound-based tracking is also under development [136, 137]. Breath-hold

imaging can be also completed with MRI-based IGRT systems by matching of intra-treatment orthogonal cine-MRI planes to pre-treatment 3D MRI datasets [78, 138].

b) Clinical application and dosimetric features of DIBH

In 1987, the potential for improvement in radiotherapy treatments of mobile targets by reducing respiratory effects has been first reported. An American team noticed that treatment in deep inspiration spared parts of the lungs, and they suggested a need to develop "Radiotherapy Gated to Respiration" [139]. In the following paragraphs we discuss the site-specific advantages of DIBH.

i. SBRT of liver lesions

Intra-breath hold liver motion and intra- and inter-fraction reproducibility of liver/diaphragm position relative to vertebral bodies during ABC-based liver SBRT was assessed by kV fluoroscopy as well as MV EPIs and movies [97]. Average maximal diaphragm motion measured by fluoroscopy during a single ABC breath-hold was 1.4 mm, also confirmed by the MV movies. Repeated CT scans in breath hold have shown a mean difference (intrafractional) in the liver surface position of -0.9 mm, -0.5 mm, and 0.2 mm in the CC, AP, and medial-lateral (ML) directions; average absolute interfraction craniocaudal offset in diaphragm position relative to vertebral bodies was 3.7mm [97].

While SBRT of lung and liver lesions was initiated with stereotactic body frames including devices to limit liver excursion during treatment with the sole objective to improve dose delivery accuracy and thus reduce PTV-margins, DIBH has been introduced soon after the clinical introduction of SBRT to immobilize the diaphragm

movement less invasively. Intrafraction precision was excellent when using fiducial markers and EPID imaging (maximal craniocaudal offset 1,7mm; [97]). Clinical results were comparable to those reported for body-frame fixation. Meanwhile, based on DIBH, a minimally invasive frameless workflow could be established together with ultrasound [101, 134] or CBCT. Results have also been excellent for hepatocellular carcinoma [140, 141], where radiotherapy as a bridging treatment before transplantation or as definitive therapy has seen renewed interest [142].

Particle radiotherapy has seen an increasing role in the treatment of hepatocellular carcinoma due to the potential of increased normal-liver sparing [143]. Often hypofractionated regimens are applied [52, 144, 145]. The combination of high motion sensitivity of particle treatments with the unforgiving character of hypofractionation (little statistical smoothing of interplay effects, sensitivity towards drift effects due to increased fraction duration) makes the application of motion mitigation techniques essential. Clinically, abdominal pressure plates and gating is most commonly used to mitigate motion effects. Especially for scanned proton therapy the combination of rescanning with other motion mitigation techniques like gating or breath-hold have been suggested [28, 47].

ii. SBRT of lung lesions

Theoretical advantages of radiotherapy for lung cancer in deep inspiration breathhold (DIBH) have been already published in 2005 by Underberg et al. [146]: a maximally expanded healthy lung tissue allows minimizing lung dose; complete immobilization of the PTV allows reduction of PTV margins which again reduces lung dose [147, 148], **Fig. 3**. This approach has since increasingly been used for simple and reliable tumor immobilization, reduction of lung exposure [149] and heart

protection [51].

Scotti et al. [150] investigated the impact of ABC-based DIBH on PTV margins and OAR sparing for 3DCRT and SBRT for lung cancer. In comparison to free-breathing CT, PTV margins could be reduced and all dosimetric lung parameters (V20, MLD) were significantly improved using DIBH-gating.

Corresponding with the dosimetric data, clinical results of DIBH-based SBRT are promising (and comparable with results of 4DCT based/mixed SBRT cohorts [24]) for both primary lung tumors and for metastases. Actuarial 1-yr local control rates are between 90-95% (3yr-LC 82-88%;) with very low toxicity [131, 151-154]. Results seem to depend on applied dose and size of PTV [151] and the method seems to be suitable even in the re-irradiation situation [155].

By creating a static situation during treatment, DIBH prevents interplay effects. While these are likely of minor importance in modulated photon radiotherapy (with some exceptions) [156], they can significantly disturb particle treatment plans [157, 158]. Especially for lung indications, non-rigid deformations which relocate high- (ribs) and low-density (soft tissue) regions, can result in severe over- or under-shoots. Therefore, methods to restrict motion or to mitigate motion effects are highly desired.

Georg et al. evaluated passively scattered proton treatments and intensity modulated proton (IMPT) plans for shallow breathing with abdominal compression and DIBH [51]. Irrespective of treatment modality they found that DVH were improved with the DIBH technique. However, the differences between shallow breathing and DIBH did not reach statistical significance. They state that although respiration controlled proton and ion beam therapy with gating and tracking approaches is technically

feasible, shallow breathing with abdominal compression or DIBH are probably more practical for the delivery of high fractional doses. Stuschke et al. showed the robustness of single field uniform dose proton plans and IMPT plans for lung patients in a breath hold scenario [159]. As this was only a planning study, concerns about the feasibility to deliver the dose for one treatment field entirely during one breath hold were raised. As inter-breath hold positional variations during the same fraction tend to be larger than intra-breath hold variations a scan across the whole target volume during one breath hold would be required to ensure robustness. Lin et al. estimated that energy switching times/average spot delivery times of 1s/5ms are required to deliver treatment fields in about 74% of lung SBRT cases within one breath hold [160]. Current commercial systems are mainly slower than that. A system that fulfils these requirements is the Gantry 2 at the Paul Scherrer Institute (PSI) in Switzerland, which is a fast parallel beam scanning proton therapy unit with small spot size and penumbra, which was optimized for the treatment of moving targets [27, 161].

iii. Normofractionated treatments of advanced lung tumors

As discussed above, PTV-margin reduction is essential in radiotherapy of locally advanced NSCLC to maximally exploit normal tissue tolerance in order to escalate tumor doses. Given the fact that methodical insufficiencies may have invalidated the results of RTOG 0617 [37, 38, 162], breathing management, potentially in combination with adaptive strategies as now tested in RTOG 1106 [162]. Potentially particle therapy will be mandatory for any further attempts to improve survival based on better local control.

Hanley et al., [163] as well as Rosenzweig et al. [164] published planning studies comparing dosimetric parameters of FB vs. DIBH reporting the advantages of DIBH

as early as fifteen years ago. Hanley et al. also provided proof of tolerability of breathing maneuvers by the patient [163]. Mah et al. [165] expanded on this, reporting their initial experience of a feasibility study with DIBH for NSCLC.

Since then, dosimetric advantages with reduced lung and cardiac dose have been repeatedly demonstrated for DIBH-RT in the setting of advanced lung cancer treatments [87, 148]. In plan comparison studies, IMRT plans in inspiration were significantly favorable regarding V10, V20, V40 and mean lung dose if compared to expiration plans also for normofractionated treatments of advanced lung tumors [54, 81-84].

Clinical outcome regarding toxicity and economic aspects has also been analyzed by Giraud et al [87] in the framework of the STIC project between 2004 and 2008 in 20 French centres. The reported dosimetric benefits were correlated clinically with a significant reduction of pulmonary acute toxicity, and pulmonary, cardiac, and esophageal late toxicities [87].

iv. DIBH to reduce cardiac and pulmonary toxicity after adjuvant radiotherapy of breast cancer

Cardiac damage has been the main concern in whole-breast radiotherapy. While improved RT-techniques seem to have measurably reduced cardiac toxicity [166], every measure should be taken to minimize cardiac exposure to doses in excess of 30Gy [41]. A very recent review summarizes the advantages of DIBH in breast cancer radiotherapy [167].

Data for DIBH-RT of left-sided breast cancer confirmed good reproducibility [168] and dosimetric advantages such as reduced lung and cardiac dose [169-171] in comparison with free-breathing planning. Sung et al. have shown significant

reduction in irradiated heart volume and V25 using DIBH if compared to plans in free breathing [170]. Verhoeven et al. [172] compared plans or supine FB (free breathing), supine DIBH and prone FB. While target coverage was similar with all modalities, doses to the heart, LAD (left anterior descending coronary artery) and contralateral breast could be most effectively reduced by supine DIBH planning. A prospective trial has shown that ABC-based breath hold can reduce the mean heart dose by 20% and dose to the lung [173]. Reduced cardiopulmonary dose by DIBH was reported by several other groups [46, 174-178] even for nodal irradiation [179]. A possible drawback of the method is the potentially higher dose to the contralateral breast [180], however, second cancer risk estimation was the same for FB and DIBH plans [181].

While the dosimetric benefits of DIBH treatments for breast cancer are striking, a recent manuscript reporting functional imaging results after DIBH- or conventional RT did not find a difference in cardiac muscle perfusion at 6 months after treatment [182]. While the correlation between these imaging changes and clinical late effects is by no means established [41] these results may be explained by too high sensitivity of the chosen imaging method or heart volumes exposed to high doses in this series that were still too large even with DIBH despite low mean heart doses. At this stage there is therefore no clinical proof of DIBH benefits.

A comparative study for whole breast irradiations between IMRT and IMPT by Mast et al. states significant dose reduction to the heart and LAD-region for IMPT even without breath hold [183]. The results showed that a breath-hold technique had no added value when using IMPT. However, using breath hold may improve the robustness of the IMPT technique, since the tissue shift will be less in breath hold.

v. Hodgkin's Disease

In addition to the potential reduction of functional damage to normal tissue, in

patients with Hodgkin's Lymphoma, a supremely curable disease frequently encountered in younger patients, reduction of irradiated tissue may reduce second cancer risk [184], adding a further motivation to perform breath hold treatments in these patients. Involved node radiotherapy in DIBH has been shown to be safe and effective [185]. Dosimetric advantages with reduced lung and cardiac/coronary dose have been demonstrated for supradiaphragmic Hodgkin lymphoma [185] also in a prospective phase II study [186] and especially for tumors of the upper mediastinum [185] and in combination with IMRT [187]. Long-term toxicity data with functional imaging are missing yet.

Protons have been pointed out to theoretically provide both excellent high-dose conformality and reduced integral dose [184]. In combination with breath-hold they could enable superior treatments for involved-field and involved-node treatment of mediastinal Hodgkin lymphoma. Clinical evidence is, however, not yet available.

vi. Other tumor entities:

Dosimetric advantages with reduced lung and cardiac dose have been also demonstrated for thoracic esophageal cancer [188, 189].

The non-invasive ablation of kidney tumors has become an intriguing concept, now that evidence regarding abscopal effects of large radiation doses is mounting [190]. It is already being explored within the framework of clinical studies (NCT02334709: Phase I-II, SBRT+tyrosine kinase inhibitors, Ghent). Both online image guidance with ultrasound [136, 137] and online MR-imaging [78, 138] now provide the technical basis for these treatments that will benefit dramatically from breath hold strategies.

So far only limited experience of particle therapy treatments in combination with breath hold can be found in the literature. Studies are restricted to the above

mentioned indications. The reason for that is that moving targets present a special challenge for particles and are not commonly clinically treated yet. A clinical trial for lung cancer, breast cancer, gastrointestinal indications and lymphomatous malignancies has recently been completed at the Abramson Cancer Centre of the University of Pennsylvania [191]. Outcomes will give more evidence on the benefit of DIBH treatment in the context for proton radiotherapy.

4. Recent developments that have facilitated the use of DIBH and outlook

Quality assurance and workflow for breath hold application is fast and easy [8, 87]. Frequently voiced concerns regarding DIBH have concentrated on the necessity for optimal patient collaboration/compliance with the procedure, sufficient pulmonary reserve and the longer treatment time in comparison to non-gated or tracked treatments [192]. With the advent of fast MLCs, VMAT and particularly the FFF-technology, the prolongation of treatment time of a gated over a non-gated treatment has been dramatically reduced [8]. Patient collaboration is excellent under these conditions if assisted breath hold is used and a minimum of training is provided. DIBH has been shown to be safe and effective [147] and to have positive effects in fractionated therapy of various thoracic and upper abdominal tumor entities (table 1).

In the future, DIBH will likely facilitate the development of new treatment paradigms and the refinement of existing ones.

Therapy with scanned particle beams will likely be more robust and more mobile targets will therefore be accessible to this treatment paradigm.

Online MR-based IGRT will provide the possibility for instant replanning on a daily basis. DIBH in this context increases the similarity of target/body geometry from treatment day to treatment day and thus may facilitate instant replanning using previous knowledge.

Conclusion

DIBH-gating is a precise, reliable technique that is applicable to most patients and, with the advent of fast delivery techniques, no longer results in excessive treatment times (**Fig. 4**). It facilitates the application of complex treatment plans with steep dose gradients to moving targets for both photon and particle therapy by widening the therapeutic window and improving dosimetric accuracy.

Legends to tables and figures:

Table 1. Characteristics of DIBH treatments within the framework of advantages and disadvantages of currently available motion management strategies

Fig.1. Comparison of imaging paradigms for lung lesions: Upper row: CBCT under repeat breath hold, including free breathing phases into the reconstruction. Note the blurring at the tumor surface and diaphragm. Lower row: CBCT stop-and-go (same number of frames in reconstruction but all frames acquired under breath-hold conditions). Note the improved image quality and reduction of blurring.

Fig.2. A-C: Helical treatment planning CT for comparison, D-F: Excellent CBCT-image quality in the upper abdomen with stop-and-go acquisition (all frames acquired under breath hold).

Fig.3. Treatment planning for lung SBRT: A) comparison of PTV and lung DVHs in FB vs. DIBH, coronal and sagittal matched planning CTs in DIBH and FB. B) treatment plan without breathing management (predominantly end-expiration). C) treatment plan in DIBH. Note expanded lung tissue and smaller PTV margins.

Fig. 4. Hallmarks of DIBH workflow. Left, breath curve and patient with Catalyst; right, breathing curve and patient with ABC.

Literature

1. Stieler F, Fleckenstein J, Simeonova A et al. Intensity modulated radiosurgery of brain metastases with flattening filter-free beams. Radiother Oncol 2013; 109: 448-451.
2. Wolff D, Stieler F, Welzel G et al. Volumetric modulated arc therapy (VMAT) vs. serial tomotherapy, step-and-shoot IMRT and 3D-conformal RT for treatment of prostate cancer. Radiother Oncol 2009; 93: 226-233.
3. Stambaugh C, Nelms BE, Dilling T et al. Experimentally studied dynamic dose interplay does not meaningfully affect target dose in VMAT SBRT lung treatments. Med Phys 2013; 40: 091710.
4. Li J, Galvin J, Harrison A et al. Dosimetric verification using monte carlo calculations for tissue heterogeneity-corrected conformal treatment plans following RTOG 0813 dosimetric criteria for lung cancer stereotactic body radiotherapy. Int J Radiat Oncol Biol Phys 2012; 84: 508-513.
5. Glide-Hurst CK, Chetty IJ. Improving radiotherapy planning, delivery accuracy, and normal tissue sparing using cutting edge technologies. J Thorac Dis 2014; 6: 303-318.
6. Boda-Heggemann J, Lohr F, Wenz F et al. kV cone-beam CT-based IGRT: a clinical review. Strahlenther Onkol 2011; 187: 284-291.
7. Sterzing F, Uhl M, Hauswald H et al. Dynamic jaws and dynamic couch in helical tomotherapy. Int J Radiat Oncol Biol Phys 2010; 76: 1266-1273.
8. Boda-Heggemann J, Mai S, Fleckenstein J et al. Flattening-filter-free intensity modulated breath-hold image-guided SABR (Stereotactic ABlative Radiotherapy) can be applied in a 15-min treatment slot. Radiother Oncol 2013; 109: 505-509.
9. Alongi F, Fogliata A, Clerici E et al. Volumetric modulated arc therapy with flattening filter free beams for isolated abdominal/pelvic lymph nodes: report of dosimetric and early clinical results in oligometastatic patients. Radiat Oncol 7: 204.
10. Fu W, Dai J, Hu Y et al. Delivery time comparison for intensity-modulated radiation therapy with/without flattening filter: a planning study. Phys Med Biol 2004; 49: 1535-1547.
11. Stieler F, Fleckenstein J, Simeonova A et al. Intensity modulated radiosurgery of brain metastases with flattening filter-free beams. Radiother Oncol 2013; 109: 448-451.
12. Lang S, Shrestha B, Graydon S et al. Clinical application of flattening filter free beams for extracranial stereotactic radiotherapy. Radiother Oncol 2013; 106: 255-259.
13. Navarria P, Ascolese AM, Mancosu P et al. Volumetric modulated arc therapy with flattening filter free (FFF) beams for stereotactic body radiation therapy (SBRT) in patients with medically inoperable early stage non small cell lung cancer (NSCLC). Radiother Oncol 2013; 107.
14. Lechner W, Kragl G, Georg D. Evaluation of treatment plan quality of IMRT and VMAT with and without flattening filter using Pareto optimal fronts. Radiother Oncol 2013; 109: 437-441.
15. Navarria P, Ascolese AM, Mancosu P et al. Volumetric modulated arc therapy with flattening filter free (FFF) beams for stereotactic body radiation therapy (SBRT) in patients with medically inoperable early stage non small cell lung cancer (NSCLC). Radiother Oncol 2013; 107: 414-418.
16. Verbakel WF, van den Berg J, Slotman BJ, Sminia P. Comparable cell survival between high dose rate flattening filter free and conventional dose rate irradiation. Acta Oncol 52: 652-657.
17. Steenken C, Fleckenstein J, Kegel S et al. Impact of flattening-filter-free radiation on the clonogenic survival of astrocytic cell lines. Strahlenther Onkol 2015.
18. Kragl G, Baier F, Lutz S et al. Flattening filter free beams in SBRT and IMRT: dosimetric assessment of peripheral doses. Z Med Phys 2011; 21 91-101.
19. Blumer N, Scherf C, Kohn J et al. New possibilities for volumetric-modulated arc therapy using the Agility 160-leaf multileaf collimator. Strahlenther Onkol 2014; 190: 1066-1074.
20. Chen AM, Daly ME, Cui J et al. Helical tomotherapy with simultaneous integrated boost dose painting for the treatment of synchronous primary cancers involving the head and neck. Br J Radiol 2014; 87: 20130697.

21. Boda-Heggemann J, Frauenfeld A, Weiss C et al. Clinical outcome of hypofractionated breath-hold image-guided SABR of primary lung tumors and lung metastases. Radiat Oncol 2014; 9.
22. Timmerman R, Papiez L, McGarry R et al. Extracranial stereotactic radioablation: results of a phase I study in medically inoperable stage I non-small cell lung cancer. Chest 2003; 124: 1946-1955.
23. Timmerman R, Paulus R, Galvin J et al. Stereotactic body radiation therapy for inoperable early stage lung cancer. JAMA 303: 1070-1076.
24. Guckenberger M, Allgauer M, Appold S et al. Safety and efficacy of stereotactic body radiotherapy for stage 1 non-small-cell lung cancer in routine clinical practice: a patterns-of-care and outcome analysis. J Thorac Oncol 2013; 8: 1050-1058.
25. Schanne DH, Nestle U, Allgauer M et al. Stereotactic body radiotherapy for centrally located stage I NSCLC : A multicenter analysis. Strahlenther Onkol 2015; 191: 125-132.
26. Sterzing F, Brunner TB, Ernst I et al. Stereotactic body radiotherapy for liver tumors: principles and practical guidelines of the DEGRO Working Group on Stereotactic Radiotherapy. Strahlenther Onkol 2014; 190: 872-881.
27. Pedroni E, Bearpark R, Bohringer T et al. The PSI Gantry 2: a second generation proton scanning gantry. Z Med Phys 2004; 14: 25-34.
28. Zhang Y, Knopf A, Tanner C et al. Deformable motion reconstruction for scanned proton beam therapy using on-line x-ray imaging. Phys Med Biol 2013; 58: 8621-8645.
29. Phillips MH, Pedroni E, Blattmann H et al. Effects of respiratory motion on dose uniformity with a charged particle scanning method. Phys Med Biol 1992; 37: 223-234.
30. Knopf A, Nill S, Yohannes I et al. Challenges of radiotherapy: report on the 4D treatment planning workshop 2013. Phys Med 2014; 30: 809-815.
31. Korreman SS. Motion in radiotherapy: photon therapy. Phys Med Biol 2012; 57: R161-191.
32. Korreman SS. Image-guided radiotherapy and motion management in lung cancer. Br J Radiol 2015; 88: 20150100.
33. Guckenberger M, Richter A, Boda-Heggemann J, Lohr F. Motion compensation in radiotherapy. Crit Rev Biomed Eng 2012; 40: 187-197.
34. Seppenwoolde Y, Shirato H, Kitamura K et al. Precise and real-time measurement of 3D tumor motion in lung due to breathing and heartbeat, measured during radiotherapy. Int J Radiat Oncol Biol Phys 2002; 53: 822-834.
35. Willner J, Baier K, Caragiani E et al. Dose, volume, and tumor control prediction in primary radiotherapy of non-small-cell lung cancer. Int J Radiat Oncol Biol Phys 2002; 52: 382-389.
36. Rengan R, Rosenzweig KE, Venkatraman E et al. Improved local control with higher doses of radiation in large-volume stage III non-small-cell lung cancer. Int J Radiat Oncol Biol Phys 2004; 60: 741-747.
37. Bradley JD, Paulus R, Komaki R et al. A randomized phase III comparison of standard-dose (60 Gy) versus high-dose (74 Gy) conformal chemoradiotherapy with or without cetuximab for stage III non-small cell lung cancer: Results on radiation dose in RTOG 0617. J Clin Oncol 2013; 31: Abstr 7501.
38. Bradley JD, Paulus R, Komaki R et al. Standard-dose versus high-dose conformal radiotherapy with concurrent and consolidation carboplatin plus paclitaxel with or without cetuximab for patients with stage IIIA or IIIB non-small-cell lung cancer (RTOG 0617): a randomised, two-by-two factorial phase 3 study. Lancet Oncol 2015; 16: 187-199.
39. Grantzau T, Overgaard J. Risk of second non-breast cancer after radiotherapy for breast cancer: A systematic review and meta-analysis of 762,468 patients. Radiother Oncol 2015; 114: 56-65.
40. Grantzau T, Thomsen MS, Vaeth M, Overgaard J. Risk of second primary lung cancer in women after radiotherapy for breast cancer. Radiother Oncol 2014; 111: 366-373.
41. Lohr F, Heggemann F, Papavassiliu T et al. [Is cardiotoxicity still an issue after breast-conserving surgery and could it be reduced by multifield IMRT?]. Strahlenther Onkol 2009; 185: 222-230.

42. Lohr F, El-Haddad M, Dobler B et al. Potential effect of robust and simple IMRT approach for left-sided breast cancer on cardiac mortality. Int J Radiat Oncol Biol Phys 2009; 74: 73-80.
43. Remouchamps VM, Letts N, Vicini FA et al. Initial clinical experience with moderate deep-inspiration breath hold using an active breathing control device in the treatment of patients with left-sided breast cancer using external beam radiation therapy. Int J Radiat Oncol Biol Phys 2003; 56: 704-715.
44. Remouchamps VM, Letts N, Yan D et al. Three-dimensional evaluation of intra- and interfraction immobilization of lung and chest wall using active breathing control: a reproducibility study with breast cancer patients. Int J Radiat Oncol Biol Phys 2003; 57: 968-978.
45. Richter A, Sweeney R, Baier K et al. Effect of breathing motion in radiotherapy of breast cancer: 4D dose calculation and motion tracking via EPID. Strahlenther Onkol 2009; 185: 425-430.
46. Sixel KE, Aznar MC, Ung YC. Deep inspiration breath hold to reduce irradiated heart volume in breast cancer patients. Int J Radiat Oncol Biol Phys 2001; 49: 199-204.
47. Knopf AC, Hong TS, Lomax A. Scanned proton radiotherapy for mobile targets-the effectiveness of re-scanning in the context of different treatment planning approaches and for different motion characteristics. Phys Med Biol 2011; 56: 7257-7271.
48. Herfarth KK, Debus J, Lohr F et al. Extracranial stereotactic radiation therapy: set-up accuracy of patients treated for liver metastases. Int J Radiat Oncol Biol Phys 2000; 46: 329-335.
49. Bouilhol G, Ayadi M, Rit S et al. Is abdominal compression useful in lung stereotactic body radiation therapy? A 4DCT and dosimetric lobe-dependent study. Phys Med 2013; 29: 333-340.
50. Mampuya WA, Nakamura M, Matsuo Y et al. Interfraction variation in lung tumor position with abdominal compression during stereotactic body radiotherapy. Med Phys 2013; 40: 091718.
51. Georg D, Hillbrand M, Stock M et al. Can protons improve SBRT for lung lesions? Dosimetric considerations. Radiother Oncol 2008; 88: 368-375.
52. Habermehl D, Debus J, Ganten T et al. Hypofractionated carbon ion therapy delivered with scanned ion beams for patients with hepatocellular carcinoma - feasibility and clinical response. Radiat Oncol 2013; 8: 59.
53. Guckenberger M, Wilbert J, Krieger T et al. Four-dimensional treatment planning for stereotactic body radiotherapy. Int J Radiat Oncol Biol Phys 2007; 69: 276-285.
54. Tahir , Bragg CM, Lawless SE et al. Dosimetric evaluation of inspiration and expiration breath-hold for intensity-modulated radiotherapy planning of non-small cell lung cancer. Phys Med Biol 2010; 55.
55. Knopf AC, Lomax A. In vivo proton range verification: a review. Phys Med Biol 2013; 58: R131-160.
56. Guckenberger M, Wilbert J, Meyer J et al. Is a single respiratory correlated 4D-CT study sufficient for evaluation of breathing motion? Int J Radiat Oncol Biol Phys 2007; 67: 1352-1359.
57. Zhang F, Kelsey CR, Yoo D et al. Uncertainties of 4-dimensional computed tomography-based tumor motion measurement for lung stereotactic body radiation therapy. Pract Radiat Oncol 2014; 4: e59-65.
58. Worm ES, Hoyer M, Fledelius W et al. Variations in magnitude and directionality of respiratory target motion throughout full treatment courses of stereotactic body radiotherapy for tumors in the liver. Acta Oncol 2013; 52: 1437-1444.
59. Park JC, Park SH, Kim JH et al. Liver motion during cone beam computed tomography guided stereotactic body radiation therapy. Med Phys 2012; 39: 6431-6442.
60. Chan MK, Kwong DL, Tam E et al. Quantifying variability of intrafractional target motion in stereotactic body radiotherapy for lung cancers. J Appl Clin Med Phys 2013; 14: 140-152.
61. Ge J, Santanam L, Noel C, Parikh PJ. Planning 4-dimensional computed tomography (4DCT) cannot adequately represent daily intrafractional motion of abdominal tumors. Int J Radiat Oncol Biol Phys 2013; 85: 999-1005.
62. Vergalasova I, Maurer J, Yin FF. Potential underestimation of the internal target volume (ITV) from free-breathing CBCT. Med Phys 2011; 38: 4689-4699.

63. Liu HW, Khan R, D'Ambrosi R et al. The influence of target and patient characteristics on the volume obtained from cone beam CT in lung stereotactic body radiation therapy. Radiother Oncol 2013; 106: 312-316.
64. Yan H, Zhen X, Folkerts M et al. A hybrid reconstruction algorithm for fast and accurate 4D cone-beam CT imaging. Med Phys 2014; 41: 071903.
65. Schmidt ML, Poulsen PR, Toftegaard J et al. Clinical use of iterative 4D-cone beam computed tomography reconstructions to investigate respiratory tumor motion in lung cancer patients. Acta Oncol 2014; 53: 1107-1113.
66. Shieh CC, Kipritidis J, O'Brien RT et al. Image quality in thoracic 4D cone-beam CT: a sensitivity analysis of respiratory signal, binning method, reconstruction algorithm, and projection angular spacing. Med Phys 2014; 41: 041912.
67. Boye D, Lomax T, Knopf A. Mapping motion from 4D-MRI to 3D-CT for use in 4D dose calculations: a technical feasibility study. Med Phys 2013; 40: 061702.
68. Keall PJ, Cattell H, Pokhrel D et al. Geometric accuracy of a real-time target tracking system with dynamic multileaf collimator tracking system. Int J Radiat Oncol Biol Phys 2006; 65: 1579-1584.
69. Guckenberger M, Meyer J, Wilbert J et al. Precision of image-guided radiotherapy (IGRT) in six degrees of freedom and limitations in clinical practice. Strahlenther Onkol 2007; 183: 307-313.
70. Chan MK, Werner R, Ayadi M, Blanck O. Comparison of 3D and 4D Monte Carlo optimization in robotic tracking stereotactic body radiotherapy of lung cancer. Strahlenther Onkol 2014.
71. Bahig H, Campeau MP, Vu T et al. Predictive parameters of CyberKnife fiducial-less (XSight Lung) applicability for treatment of early non-small cell lung cancer: a single-center experience. Int J Radiat Oncol Biol Phys 2013; 87: 583-589.
72. Depuydt T, Poels K, Verellen D et al. Treating patients with real-time tumor tracking using the Vero gimbaled linac system: Implementation and first review. Radiother Oncol 2014; 112: 343-351.
73. Depuydt T, Poels K, Verellen D et al. Initial assessment of tumor tracking with a gimbaled linac system in clinical circumstances: a patient simulation study. Radiother Oncol 2013; 106: 236-240.
74. Wilbert J, Baier K, Hermann C et al. Accuracy of real-time couch tracking during 3-dimensional conformal radiation therapy, intensity modulated radiation therapy, and volumetric modulated arc therapy for prostate cancer. Int J Radiat Oncol Biol Phys 2013; 85: 237-242.
75. Schmidhalter D, Malthaner M, Born EJ et al. Assessment of patient setup errors in IGRT in combination with a six degrees of freedom couch. Z Med Phys 2014; 24: 112-122.
76. Udrescu C, Mornex F, Tanguy R, Chapet O. ExacTrac Snap Verification: a new tool for ensuring quality control for lung stereotactic body radiation therapy. Int J Radiat Oncol Biol Phys 2013; 85: e89-94.
77. Xie Y, Xing L, Gu J, Liu W. Tissue feature-based intra-fractional motion tracking for stereoscopic x-ray image guided radiotherapy. Phys Med Biol 2013; 58: 3615-3630.
78. Bjerre T, Crijns S, af Rosenschold PM et al. Three-dimensional MRI-linac intra-fraction guidance using multiple orthogonal cine-MRI planes. Phys Med Biol 2013; 58: 4943-4950.
79. Raaijmakers AJ, Raaymakers BW, Lagendijk JJ. Magnetic-field-induced dose effects in MR-guided radiotherapy systems: dependence on the magnetic field strength. Phys Med Biol 2008; 53: 909-923.
80. Bert C, Saito N, Schmidt A et al. Target motion tracking with a scanned particle beam. Med Phys 2007; 34: 4768-4771.
81. Saito T, Sakamoto T, Oya N. Comparison of gating around end-expiration and end-inspiration in radiotherapy for lung cancer. Radiother Oncol 2009; 93: 430-435.
82. Kontrisova K, Stock M, Dieckmann K et al. Dosimetric comparison of stereotactic body radiotherapy in different respiration conditions: a modeling study. Radiother Oncol 2006; 81: 97-104.

83. Josipovic M, Persson GF, Håkansson K et al. Deep inspiration breath hold radiotherapy for locally advanced lung cancer: comparison of different treatment techniques on target coverage, lung dose and treatment delivery time. Acta Oncol 2013; 52: 1582-1586.
84. Giraud P, Morvan E, Claude L et al. Respiratory gating techniques for optimization of lung cancer radiotherapy. J Thorac Oncol 2011; 6: 2058-2068.
85. Minohara S, Kanai T, Endo M et al. Respiratory gated irradiation system for heavy-ion radiotherapy. Int J Radiat Oncol Biol Phys 2000; 47: 1097-1103.
86. Schatti A, Zakova M, Meer D, Lomax AJ. The effectiveness of combined gating and re-scanning for treating mobile targets with proton spot scanning. An experimental and simulation-based investigation. Phys Med Biol 2014; 59: 3813-3828.
87. Giraud P, Morvan E, Claude L et al. Respiratory gating techniques for optimization of lung cancer radiotherapy. J Thorac Oncol 2011; 6: 2058-2068.
88. Pedersen AN, Korreman S, Nystrom H, Specht L. Breathing adapted radiotherapy of breast cancer: reduction of cardiac and pulmonary doses using voluntary inspiration breath-hold. Radiother Oncol 2004; 72: 53-60.
89. Bartlett FR, Colgan RM, Donovan EM et al. Voluntary breath-hold technique for reducing heart dose in left breast radiotherapy. J Vis Exp 2014.
90. Prabhakar R, Tharmar G, Julka PK et al. Impact of different breathing conditions on the dose to surrounding normal structures in tangential field breast radiotherapy. J Med Phys 2007; 32: 24-28.
91. Osman SO, Hol S, Poortmans PM, Essers M. Volumetric modulated arc therapy and breath-hold in image-guided locoregional left-sided breast irradiation. Radiother Oncol 2014; 112: 17-22.
92. Bartlett FR, Colgan RM, Carr K et al. The UK HeartSpare Study: randomised evaluation of voluntary deep-inspiratory breath-hold in women undergoing breast radiotherapy. Radiother Oncol 2013; 108: 242-247.
93. Betgen A, Alderliesten T, Sonke JJ et al. Assessment of set-up variability during deep inspiration breath hold radiotherapy for breast cancer patients by 3D-surface imaging. Radiother Oncol 2013; 106: 225-230.
94. Linthout N, Bral S, Van de Vondel I et al. Treatment delivery time optimization of respiratory gated radiation therapy by application of audio-visual feedback. Radiother Oncol 2009; 91: 330-335.
95. Kimura T, Murakami Y, Kenjo M et al. Interbreath-hold reproducibility of lung tumour position and reduction of the internal target volume using a voluntary breath-hold method with spirometer during stereotactic radiotherapy for lung tumours. Br J Radiol 2007; 80: 355-361.
96. Dawson LA, Eccles C, Bissonnette JP, Brock KK. Accuracy of daily image guidance for hypofractionated liver radiotherapy with active breathing control. Int J Radiat Oncol Biol Phys 2005; 62: 1247-1252.
97. Eccles C, Brock KK, Bissonnette JP et al. Reproducibility of liver position using active breathing coordinator for liver cancer radiotherapy. Int J Radiat Oncol Biol Phys 2006; 64: 751-759.
98. Koshani R, Balter JM, Hayman JA et al. Short-term and long-term reproducibility of lung tumor position using active breathing control (ABC). Int J Radiat Oncol Biol Phys 2006; 65: 1553-1559.
99. Panakis N, McNair HA, Christian JA et al. Defining the margins in the radical radiotherapy of non-small cell lung cancer (NSCLC) with active breathing control (ABC) and the effect on physical lung parameters. Radiother Oncol 2008; 87: 65-73.
100. Wong JW, Sharpe MB, Jaffray DA et al. The use of active breathing control (ABC) to reduce margin for breathing motion. Int J Radiat Oncol Biol Phys 1999; 44: 911-919.
101. Boda-Heggemann J, Walter C, Mai S et al. Frameless stereotactic radiosurgery of a solitary liver metastasis using active breathing control and stereotactic ultrasound. Strahlenther Onkol 2006; 182: 216-221.
102. McNair HA, Brock J, Symonds-Tayler JR et al. Feasibility of the use of the Active Breathing Co ordinator (ABC) in patients receiving radical radiotherapy for non-small cell lung cancer (NSCLC). Radiother Oncol 2009; 93: 424-429.

103. Partridge M, Tree A, Brock J et al. Improvement in tumour control probability with active breathing control and dose escalation: a modelling study. Radiother Oncol 2009; 91: 325-329.
104. Brock J, McNair HA, Panakis N et al. The use of the Active Breathing Coordinator throughout radical non-small-cell lung cancer (NSCLC) radiotherapy. Int J Radiat Oncol Biol Phys 2011; 81: 369-375.
105. Mittauer KE, Deraniyagala R, Li JG et al. Monitoring ABC-assisted deep inspiration breath hold for left-sided breast radiotherapy with an optical tracking system. Med Phys 2015; 42: 134.
106. Peng Y, Vedam S, Chang JY et al. Implementation of feedback-guided voluntary breath-hold gating for cone beam CT-based stereotactic body radiotherapy. Int J Radiat Oncol Biol Phys 2011; 80: 909-917.
107. Watanabe M, Onishi H, Kuriyama K et al. Intrafractional setup errors in patients undergoing non-invasive fixation using an immobilization system during hypofractionated stereotactic radiotherapy for lung tumors. J Radiat Res 2013; 54: 762-768.
108. Li R, Mok E, Han B et al. Evaluation of the geometric accuracy of surrogate-based gated VMAT using intrafraction kilovoltage x-ray images. Med Phys 2012; 39: 2686-2693.
109. Pallotta S, Marrazzo L, Ceroti M et al. A phantom evaluation of Sentinel(), a commercial laser/camera surface imaging system for patient setup verification in radiotherapy. Med Phys 2012; 39: 706-712.
110. Stieler F, Wenz F, Shi M, Lohr F. A novel surface imaging system for patient positioning and surveillance during radiotherapy. A phantom study and clinical evaluation. Strahlenther Onkol 2013; 189: 938-944.
111. Stieler F, Wenz F, Scherrer D et al. Clinical evaluation of a commercial surface-imaging system for patient positioning in radiotherapy. Strahlenther Onkol 2012; 188: 1080-1084.
112. Gopan O, Wu Q. Evaluation of the accuracy of a 3D surface imaging system for patient setup in head and neck cancer radiotherapy. Int J Radiat Oncol Biol Phys 2012; 84: 547-552.
113. Moser T, Habl G, Uhl M et al. Clinical evaluation of a laser surface scanning system in 120 patients for improving daily setup accuracy in fractionated radiation therapy. Int J Radiat Oncol Biol Phys 2013; 85: 846-853.
114. Alderliesten T, Sonke JJ, Betgen A et al. Accuracy evaluation of a 3-dimensional surface imaging system for guidance in deep-inspiration breath-hold radiation therapy. Int J Radiat Oncol Biol Phys 2013; 85: 536-542.
115. Rong Y, Walston S, Welliver MX et al. Improving intra-fractional target position accuracy using a 3D surface surrogate for left breast irradiation using the respiratory-gated deep-inspiration breath-hold technique. PLoS One 2014; 9: e97933.
116. Padilla L, Kang H, Washington M et al. Assessment of interfractional variation of the breast surface following conventional patient positioning for whole-breast radiotherapy. J Appl Clin Med Phys 2014; 15: 4921.
117. Gierga DP, Turcotte JC, Sharp GC et al. A voluntary breath-hold treatment technique for the left breast with unfavorable cardiac anatomy using surface imaging. Int J Radiat Oncol Biol Phys 2012; 84: e663-668.
118. Tanguturi SK, Lyatskaya Y, Chen Y et al. Prospective assessment of deep inspiration breath-hold using 3-dimensional surface tracking for irradiation of left-sided breast cancer. Pract Radiat Oncol 2015.
119. Tang X, Zagar TM, Bair E et al. Clinical experience with 3-dimensional surface matching-based deep inspiration breath hold for left-sided breast cancer radiation therapy. Pract Radiat Oncol 2014; 4: e151-158.
120. Tang X, Cullip T, Dooley J et al. Dosimetric effect due to the motion during deep inspiration breath hold for left-sided breast cancer radiotherapy. J Appl Clin Med Phys 2015; 16: 5358.
121. Fassi A, Ivaldi GB, Meaglia I et al. Reproducibility of the external surface position in left-breast DIBH radiotherapy with spirometer-based monitoring. J Appl Clin Med Phys 2014; 15: 4494.
122. Serpa M, Baier K, Cremers F et al. Suitability of markerless EPID tracking for tumor position verification in gated radiotherapy. Med Phys 2014; 41: 031702.

123. Whyte RI, Crownover R, Murphy MJ et al. Stereotactic radiosurgery for lung tumors: preliminary report of a phase I trial. Ann Thorac Surg 2003; 75: 1097-1101.
124. J. Boda-Heggemann AJ, L. Jahnke, A. Simeonova, S.K. Mai, H. Wertz, A. Zimmermann, S. von Swietochowski, F. Wenz, F. Lohr. Breath-Hold Cone Beam CT (CBCT): Improved Image Quality With "Stop-and-Go" Breath Hold–Only Acquisition Versus Repetitive Breath Hold During Continuous Rotation. Int J Radiat Oncol Biol Phys 2014; 90: S826.
125. Boda-Heggemann J, Fleckenstein J, Lohr F et al. Multiple breath-hold CBCT for online image guided radiotherapy of lung tumors: simulation with a dynamic phantom and first patient data. Radiother Oncol 2011; 98: 309-316.
126. Duggan DM, Ding GX, Coffey CW, 2nd et al. Deep-inspiration breath-hold kilovoltage cone-beam CT for setup of stereotactic body radiation therapy for lung tumors: initial experience. Lung Cancer 2007; 56: 77-88.
127. Zhong R, Wang J, Zhou L et al. Implementation of single-breath-hold cone beam CT guided hypofraction radiotherapy for lung cancer. Radiat Oncol 2014; 9: 77.
128. Blessing M, Stsepankou, D., Lohr, F., Wenz, F., Hesser, J. Fast On-board Imaging Based on Combined Kilovoltage Megavoltage Cone-beam Reconstruction Int J Radiat Oncol Biol Phys 2008; Vol. 72 S613.
129. Wertz H, Stsepankou D, Blessing M et al. Fast kilovoltage/megavoltage (kVMV) breathhold cone-beam CT for image-guided radiotherapy of lung cancer. Phys Med Biol 2010; 55: 4203-4217.
130. Jaffray DA, Chawla K, Yu C, Wong JW. Dual-beam imaging for online verification of radiotherapy field placement. Int J Radiat Oncol Biol Phys 1995; 33: 1273-1280.
131. Onishi H, Kuriyama K, Komiyama T et al. Clinical outcomes of stereotactic radiotherapy for stage I non-small cell lung cancer using a novel irradiation technique: patient self-controlled breath-hold and beam switching using a combination of linear accelerator and CT scanner. Lung Cancer 2004; 45: 45-55.
132. Blessing M, Stsepankou D, Wertz H et al. Breath-hold target localization with simultaneous kilovoltage/megavoltage cone-beam computed tomography and fast reconstruction. Int J Radiat Oncol Biol Phys 2010; 78: 1219-1226.
133. Fuss M, Salter BJ, Cavanaugh SX et al. Daily ultrasound-based image-guided targeting for radiotherapy of upper abdominal malignancies. Int J Radiat Oncol Biol Phys 2004; 59: 1245-1256.
134. Bloemen-van Gurp E, van der Meer S, Hendry J et al. Active breathing control in combination with ultrasound imaging: a feasibility study of image guidance in stereotactic body radiation therapy of liver lesions. Int J Radiat Oncol Biol Phys 2013; 85: 1096-1102.
135. Boda-Heggemann J, Dinter D, Weiss C et al. Hypofractionated image-guided breath-hold SABR (stereotactic ablative body radiotherapy) of liver metastases--clinical results. Radiat Oncol 2012; 7: 92.
136. Jacso F, Kouznetsov A, Smith WL. Development and evaluation of an ultrasound-guided tracking and gating system for hepatic radiotherapy. Med Phys 2009; 36: 5633-5640.
137. Zhong Y, Stephans K, Qi P et al. Assessing feasibility of real-time ultrasound monitoring in stereotactic body radiotherapy of liver tumors. Technol Cancer Res Treat 2013; 12: 243-250.
138. Stam MK, van Vulpen M, Barendrecht MM et al. Kidney motion during free breathing and breath hold for MR-guided radiotherapy. Phys Med Biol 2013; 58: 2235-2245.
139. Willett CG, Linggood RM, Stracher MA et al. The effect of the respiratory cycle on mediastinal and lung dimensions in Hodgkin's disease. Implications for radiotherapy gated to respiration. Cancer 1987; 60: 1232-1237.
140. Yoon SM, Lim YS, Park MJ et al. Stereotactic body radiation therapy as an alternative treatment for small hepatocellular carcinoma. PLoS One 2013; 8: e79854.
141. Jang WI, Kim MS, Bae SH et al. High-dose stereotactic body radiotherapy correlates increased local control and overall survival in patients with inoperable hepatocellular carcinoma. Radiat Oncol 2013; 8: 250.
142. Mazloom A, Hezel AF, Katz AW. Stereotactic body radiation therapy as a bridge to transplantation and for recurrent disease in the transplanted liver of a patient with hepatocellular carcinoma. Case Rep Oncol 2014; 7: 18-22.

143. Ling TC, Kang JI, Bush DA et al. Proton therapy for hepatocellular carcinoma. Chin J Cancer Res 2012; 24: 361-367.
144. Chiba T, Tokuuye K, Matsuzaki Y et al. Proton beam therapy for hepatocellular carcinoma: a retrospective review of 162 patients. Clin Cancer Res 2005; 11: 3799-3805.
145. Combs SE, Habermehl D, Ganten T et al. Phase i study evaluating the treatment of patients with hepatocellular carcinoma (HCC) with carbon ion radiotherapy: the PROMETHEUS-01 trial. BMC Cancer 2011; 11: 67.
146. Underberg RW, Lagerwaard FJ, Slotman BJ et al. Benefit of respiration-gated stereotactic radiotherapy for stage I lung cancer: an analysis of 4DCT datasets. Int J Radiat Oncol Biol Phys 2005; 62: 554-560.
147. Paumier A, Crespeau A, Krhili S et al. [Dosimetric study of the different techniques to deal with respiratory motion for lung stereotactic radiotherapy]. Cancer Radiother 2012; 16: 263-271.
148. Marchand V, Zefkili S, Desrousseaux J et al. Dosimetric comparison of free-breathing and deep inspiration breath-hold radiotherapy for lung cancer. Strahlenther Onkol 188: 582-589.
149. Xhaferllari I, Chen JZ, MacFarlane M et al. Dosimetric planning study of respiratory-gated volumetric modulated arc therapy for early-stage lung cancer with stereotactic body radiation therapy. Pract Radiat Oncol 2015; 5: 156-161.
150. Scotti V, Marrazzo L, Saieva C et al. Impact of a breathing-control system on target margins and normal-tissue sparing in the treatment of lung cancer: experience at the radiotherapy unit of Florence University. Radiol Med 2014; 119: 13-19.
151. Boda-Heggemann J, Frauenfeld A, Weiss C et al. Clinical outcome of hypofractionated breath-hold image-guided SABR of primary lung tumors and lung metastases. Radiat Oncol 2014; 9: 10.
152. Singh D, Chen Y, Hare MZ et al. Local control rates with five-fraction stereotactic body radiotherapy for oligometastatic cancer to the lung. J Thorac Dis 2014; 6: 369-374.
153. Nambu A, Onishi H, Aoki S et al. Rib fracture after stereotactic radiotherapy for primary lung cancer: prevalence, degree of clinical symptoms, and risk factors. BMC Cancer 2013; 13: 68.
154. Dhakal S, Corbin KS, Milano MT et al. Stereotactic body radiotherapy for pulmonary metastases from soft-tissue sarcomas: excellent local lesion control and improved patient survival. Int J Radiat Oncol Biol Phys 2012; 82: 940-945.
155. Mantel F, Flentje M, Guckenberger M. Stereotactic body radiation therapy in the re-irradiation situation--a review. Radiat Oncol 2013; 8: 7.
156. Fleckenstein J, Hesser J., Wenz F., Lohr F. Robustness of sweeping-window arc therapy treatment sequences against intrafractional tumor motion. Med Phys 2015; 42: 1538-1545.
157. Engelsman M, Rietzel E, Kooy HM. Four-dimensional proton treatment planning for lung tumors. Int J Radiat Oncol Biol Phys 2006; 64: 1589-1595.
158. Dowdell S, Grassberger C, Sharp GC, Paganetti H. Interplay effects in proton scanning for lung: a 4D Monte Carlo study assessing the impact of tumor and beam delivery parameters. Phys Med Biol 2013; 58: 4137-4156.
159. Stuschke M, Kaiser A, Pottgen C et al. Potentials of robust intensity modulated scanning proton plans for locally advanced lung cancer in comparison to intensity modulated photon plans. Radiother Oncol 2012; 104: 45-51.
160. M. Lin LJ, S.J. Feigenberg, M.P. Mehta, W.D. DSouza, K.M. Langen. Breath-Hold Intensity Modulated Proton Therapy (BH-IMPT) for Lung SBRT: Feasibility Study. Int J Radiat Oncol Biol Phys 2014; 90: S142

.
161. Schatti A, Meer D, Lomax AJ. First experimental results of motion mitigation by continuous line scanning of protons. Phys Med Biol 2014; 59: 5707-5723.
162. Bradley JD, Paulus R, Komaki R et al. Standard-dose versus high-dose conformal radiotherapy with concurrent and consolidation carboplatin plus paclitaxel with or without cetuximab for patients with stage IIIA or IIIB non-small-cell lung cancer (RTOG 0617): a randomised, two-by-two factorial phase 3 study. Lancet Oncol 2015.

163. Hanley J, Debois MM, Mah D et al. Deep inspiration breath-hold technique for lung tumors: the potential value of target immobilization and reduced lung density in dose escalation. Int J Radiat Oncol Biol Phys 1999; 45: 603-611.
164. Rosenzweig KE, Hanley J, Mah D et al. The deep inspiration breath-hold technique in the treatment of inoperable non-small-cell lung cancer. Int J Radiat Oncol Biol Phys 2000; 48: 81-87.
165. Mah D, Hanley J, Rosenzweig KE et al. Technical aspects of the deep inspiration breath-hold technique in the treatment of thoracic cancer. Int J Radiat Oncol Biol Phys 2000; 48: 1175-1185.
166. Darby SC, Ewertz M, McGale P et al. Risk of ischemic heart disease in women after radiotherapy for breast cancer. N Engl J Med 2013; 368: 987-998.
167. Latty D, Stuart KE, Wang W, Ahern V. Review of deep inspiration breath-hold techniques for the treatment of breast cancer. J Med Radiat Sci 2015; 62: 74-81.
168. Jensen C, Urribarri J, Cail D et al. Cine EPID evaluation of two non-commercial techniques for DIBH. Med Phys 2014; 41: 021730.
169. Lee HY, Chang JS, Lee IJ et al. The deep inspiration breath hold technique using Abches reduces cardiac dose in patients undergoing left-sided breast irradiation. Radiat Oncol J 2013; 31: 239-246.
170. Sung K, Lee KC, Lee SH et al. Cardiac dose reduction with breathing adapted radiotherapy using self respiration monitoring system for left-sided breast cancer. Radiat Oncol J 2014; 32: 84-94.
171. Bruzzaniti V, Abate A, Pinnaro P et al. Dosimetric and clinical advantages of deep inspiration breath-hold (DIBH) during radiotherapy of breast cancer. J Exp Clin Cancer Res 2013; 32: 88.
172. Verhoeven K, Sweldens C, Petillion S et al. Breathing adapted radiation therapy in comparison with prone position to reduce the doses to the heart, left anterior descending coronary artery, and contralateral breast in whole breast radiation therapy. Pract Radiat Oncol 2014; 4: 123-129.
173. Eldredge-Hindy H, Lockamy V, Crawford A et al. Active Breathing Coordinator reduces radiation dose to the heart and preserves local control in patients with left breast cancer: Report of a prospective trial. Pract Radiat Oncol 2015; 5: 4-10.
174. Vikstrom J, Hjelstuen MH, Mjaaland I, Dybvik KI. Cardiac and pulmonary dose reduction for tangentially irradiated breast cancer, utilizing deep inspiration breath-hold with audio-visual guidance, without compromising target coverage. Acta Oncol 2011; 50: 42-50.
175. Stranzl H, Zurl B. Postoperative irradiation of left-sided breast cancer patients and cardiac toxicity. Does deep inspiration breath-hold (DIBH) technique protect the heart? Strahlenther Onkol 2008; 184: 354-358.
176. Nissen HD, Appelt AL. Improved heart, lung and target dose with deep inspiration breath hold in a large clinical series of breast cancer patients. Radiother Oncol 2013; 106: 28-32.
177. Hayden AJ, Rains M, Tiver K. Deep inspiration breath hold technique reduces heart dose from radiotherapy for left-sided breast cancer. J Med Imaging Radiat Oncol 2012; 56: 464-472.
178. Shim JG, Kim JK, Park W et al. Dose-Volume Analysis of Lung and Heart according to Respiration in Breast Cancer Patients Treated with Breast Conserving Surgery. J Breast Cancer 2012; 15: 105-110.
179. Hjelstuen MH, Mjaaland I, Vikstrom J, Dybvik KI. Radiation during deep inspiration allows loco-regional treatment of left breast and axillary-, supraclavicular- and internal mammary lymph nodes without compromising target coverage or dose restrictions to organs at risk. Acta Oncol 2012; 51: 333-344.
180. Zurl B, Stranzl H, Winkler P, Kapp KS. Quantification of contralateral breast dose and risk estimate of radiation-induced contralateral breast cancer among young women using tangential fields and different modes of breathing. Int J Radiat Oncol Biol Phys 2013; 85: 500-505.
181. Johansen S, Vikstrom J, Hjelstuen MH et al. Dose evaluation and risk estimation for secondary cancer in contralateral breast and a study of correlation between thorax shape and dose to organs at risk following tangentially breast irradiation during deep inspiration breath-hold and free breathing. Acta Oncol 2011; 50: 563-568.

182. Zellars R, Bravo PE, Tryggestad E et al. SPECT analysis of cardiac perfusion changes after whole-breast/chest wall radiation therapy with or without active breathing coordinator: results of a randomized phase 3 trial. Int J Radiat Oncol Biol Phys 2014; 88: 778-785.
183. Mast ME, Vredeveld EJ, Credoe HM et al. Whole breast proton irradiation for maximal reduction of heart dose in breast cancer patients. Breast Cancer Res Treat 2014; 148: 33-39.
184. Lohr F, Georg D, Cozzi L et al. Novel radiotherapy techniques for involved-field and involved-node treatment of mediastinal Hodgkin lymphoma: when should they be considered and which questions remain open? Strahlenther Onkol 2014; 190: 864-866, 868-871.
185. Paumier A, Bakkour M, Ghalibafian M et al. [Involved-node radiotherapy combined with deep-inspiration breath-hold technique in patients with Hodgkin lymphoma]. Cancer Radiother 2012; 16: 85-90.
186. Petersen PM, Aznar MC, Berthelsen AK et al. Prospective phase II trial of image-guided radiotherapy in Hodgkin lymphoma: Benefit of deep inspiration breath-hold. Acta Oncol 2015; 54: 60-66.
187. Aznar MC, Maraldo MV, Schut DA et al. Minimizing Late Effects for Patients With Mediastinal Hodgkin Lymphoma: Deep Inspiration Breath-Hold, IMRT, or Both? Int J Radiat Oncol Biol Phys 2015.
188. Gong G, Wang R, Guo Y et al. Reduced lung dose during radiotherapy for thoracic esophageal carcinoma: VMAT combined with active breathing control for moderate DIBH. Radiat Oncol 2013; 8: 291.
189. Lorchel F, Dumas JL, Noel A et al. Dosimetric consequences of breath-hold respiration in conformal radiotherapy of esophageal cancer. Phys Med 2006; 22: 119-126.
190. De Meerleer G, Khoo V, Escudier B et al. Radiotherapy for renal-cell carcinoma. Lancet Oncol 2014; 15: e170-177.
191. https://clinicaltrials.gov/ct2/show/NCT01386697.
192. Guckenberger M, Kavanagh A, Webb S, Brada M. A novel respiratory motion compensation strategy combining gated beam delivery and mean target position concept --a compromise between small safety margins and long duty cycles. Radiother Oncol 2011; 98: 317-322.

Table 1. Characteristics of DIBH treatments within the framework of advantages and disadvantages of currently available motion management strategies

Motion compensation method	**DIBH**	**Spontaneus breathing gating**	**Real-time Tracking**	**ITV/individualized margins**
Available techniques	- free DIBH - computer-controlled DIBH (spirometry, surface tracking with markers or markerless)	Spirometry, surface tracking with markers or markerless	- couch tracking - steering of beam	Treatment planning with 4DCT, potentially with abdominal compression
Imaging	All imaging under DIBH: planning-CT, CBCT, ultrasound surveillance in breath hold, simultaneous VMAT-CT during treatment	- Dynamic planar or ultrasound imaging - 4DCBCT immediately before treatment - simultaneous VMAT-CT during treatment	-Dynamic planar or ultrasound imaging and VMAT-CT possible during treatment, depending on platform used	- 4DCT, 4DMR for treatment planning - 4DCBCT immediately before treatment - simultaneous VMAT-CT during treatment
PTV margins	Small (residual motion after breath hold)	Small (residual motion in gating window)	Small (tracking inaccuracy)	Large (end-expiratory-to-end–inspiratory position)
Characteristics of achievable dose distribution	- Reduced lung dose due to lung expansion and smaller PTV - Typically reduced cardiac dose and dose to most other OAR	depends on gating phase (inspiration: favourable; expiration: unfavorable)	-typically high exposure of lung and other OAR because treatment is performed during all breathing phases. Dose ideally has to be accumulated on a dynamic model.	typically high exposure of lung and other OAR due to treatment in all breathing phases and large margins. Dose ideally has to be accumulated on a dynamic model
QA	Standard treatment and imaging QA	Standard treatment and imaging QA	QA of the dynamic treatment process in addition to standard QA	Standard treatment and imaging QA
Patient convenience	- Optimal patient collaboration/ compliance needed - Sufficient pulmonary reserve needed	Patient collaboration and regular breathing pattern needed	Patient collaboration and a sufficiently slow breathing pattern needed	frequently abdominal compression needed to reduce target motion
Treatment time	Longer treatment time	Longer treatment time	Short treatment time	Short treatment time
Scanned Particle Therapy	Minimal risk of interplay effects	Small risk of interplay effects	Small risk of interplay effects	Higher risk of interplay effects
Toxicity	For small lesions low for all techniques, for larger lesions no comparative data available, theoretical benefits for DIBH			

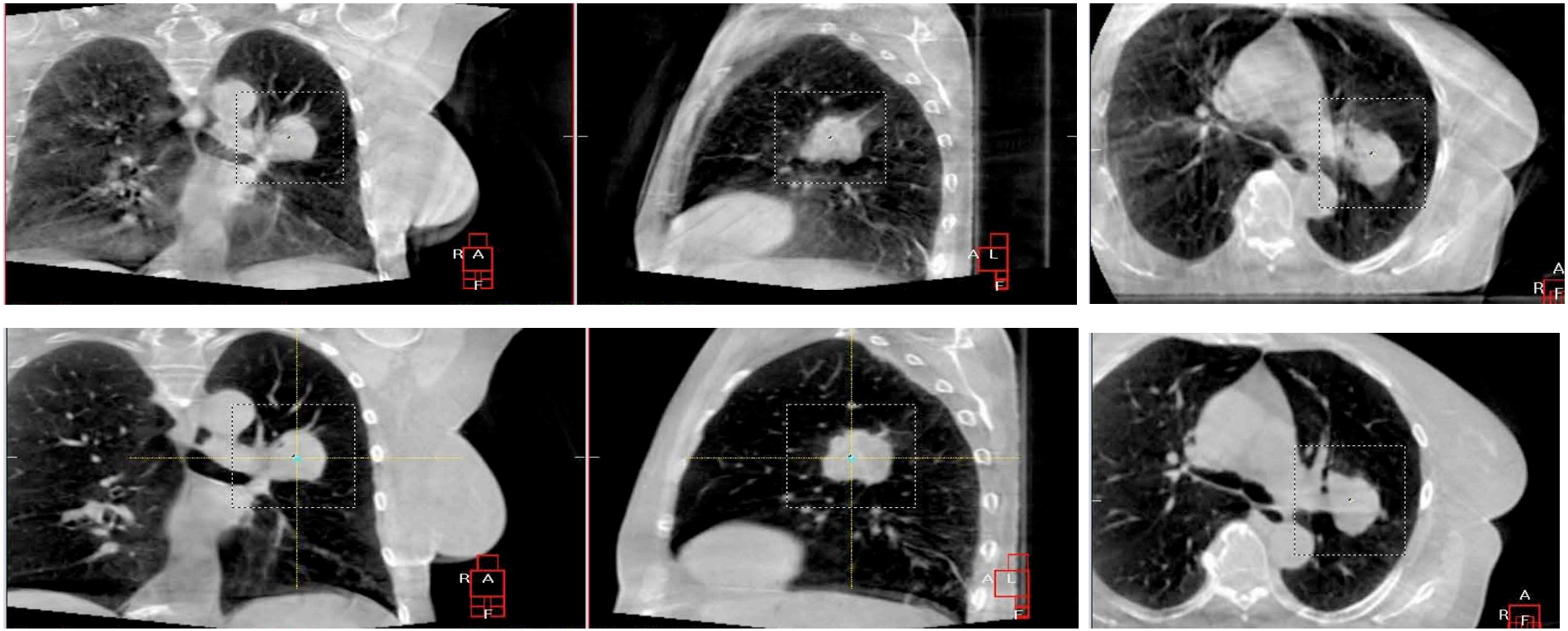
R A
F
A L
F
A
R F
R A
F
A L
F
A
R F

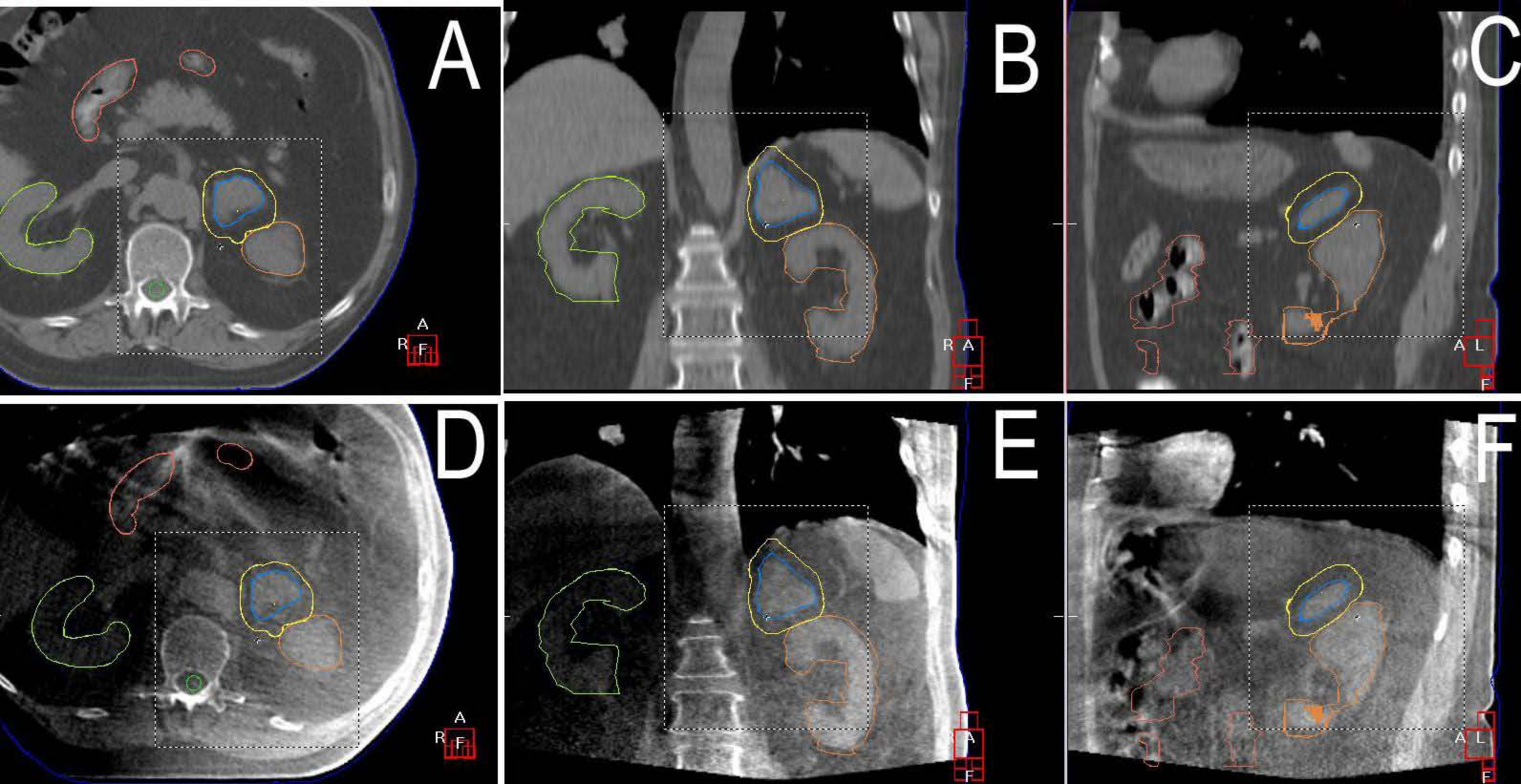
A
B
C
D
E
F
A
R
F
R A
F
A L
F
A
R
F
A
F
A L
F

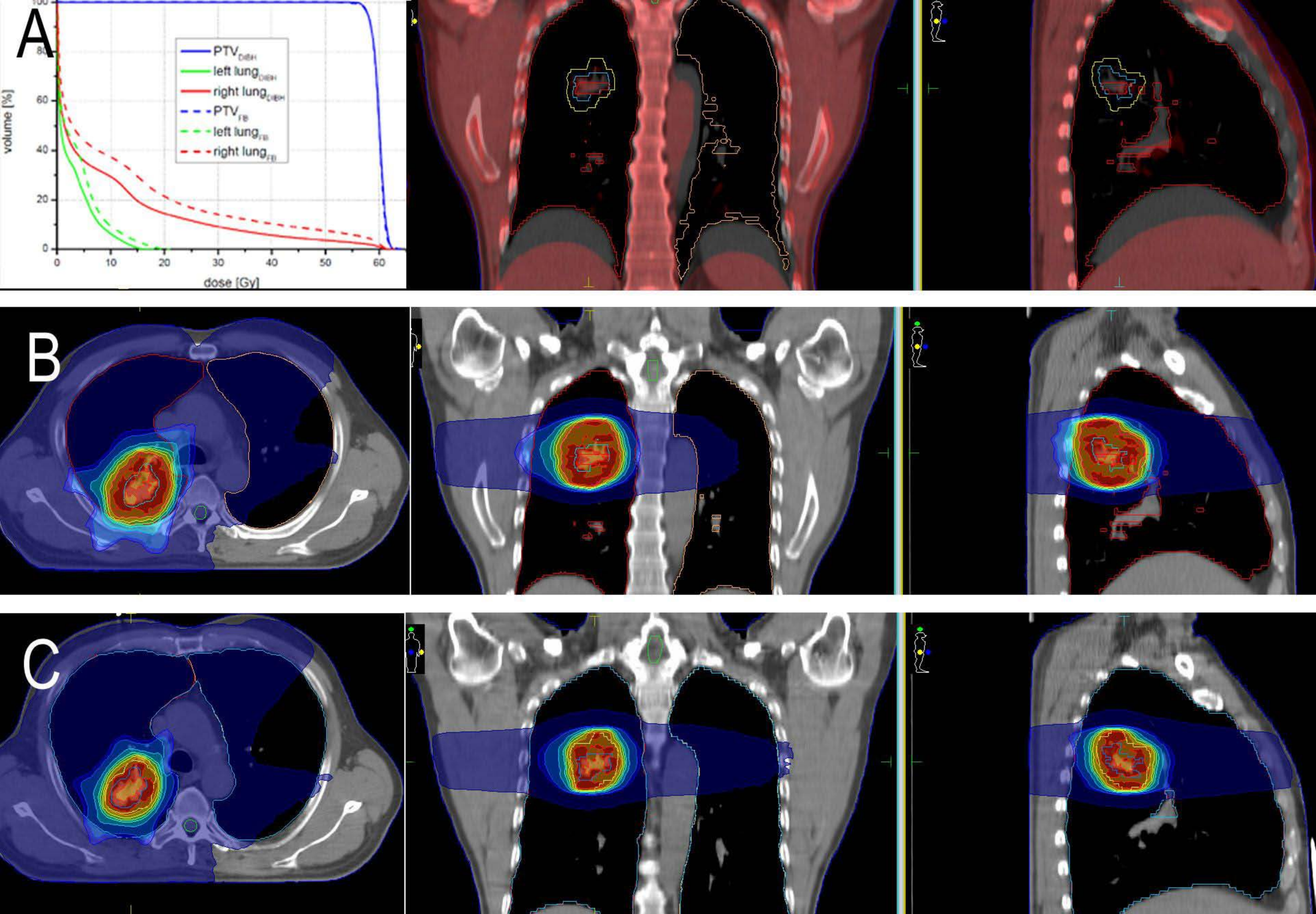
A
PTV DIBH
left lung DIBH
right lung DIBH
PTV FB
left lung FB
right lung FB
volume [%]
dose [Gy]
0
20
40
60
80
100
0
10
20
30
40
50
60
B
C

- Planning CT (DIBH, no frame, no rigid fixation, no abdominal pressure)

- Planning on single phase DIBH dataset.
  No need to contour on multiple breathing phases

- IGRT with CBCT acquired in repetitive DIBH

- Fast Delivery (DIBH, FFF, fast MLC) with static anatomical geometry identical to planning CT