This is the peer reviewd version of the followng article:

International diagnostic guidelines for patients with HCV-related extrahepatic manifestations. A multidisciplinary expert statement / Ferri, Clodoveo; Ramos Casals, Manuel; Zignego, Anna Linda; Arcaini, Luca; Roccatello, Dario; Antonelli, Alessandro; Saadoun, David; Desbois, Anne Claire; Sebastiani, Marco; Casato, Milvia; Lamprecht, Peter; Mangia, Alessandra; Tzioufas, Athanasios G; Younossi, Zobair M; Cacoub, Patrice. - In: AUTOIMMUNITY REVIEWS. - ISSN 1568-9972. - 15:12(2016), pp. 1145-1160. [10.1016/j.autrev.2016.09.006]

Terms of use:

The terms and conditions for the reuse of this version of the manuscript are specified in the publishing policy. For all terms of use and more information see the publisher's website.

12/10/2024 05:23

(Article begins on next page)

IRIS AperTO

UNIVERSITÀ DEGLI STUDI DI TORINO

AperTO - Archivio Istituzionale Open Access dell'Università di Torino

International diagnostic guidelines for patients with HCV-related extrahepatic manifestations. A multidisciplinary expert statement

This is the author's manuscript

Original Citation:

Availability:

This version is available http://hdl.handle.net/2318/1635431 since 2019-02-13T14:50:51Z

Published version:

DOI:10.1016/j.autrev.2016.09.006

Terms of use:

Open Access

Anyone can freely access the full text of works made available as "Open Access". Works made available under a Creative Commons license can be used according to the terms and conditions of said license. Use of all other works requires consent of the right holder (author or publisher) if not exempted from copyright protection by the applicable law.

(Article begins on next page)

07 April 2022

IRIS AperTO

UNIVERSITÀ DEGLI STUDI DI TORINO

This is the author's final version of the contribution published as:

Clodoveo Ferri, Manuel Ramos-Casals, Anna Linda Zignego, Luca Arcaini, Dario Roccatello, Alessandro Antonelli, David Saadoun, Marco Sebastiani, Zobair M Younossi, and Patrice Cacoub on behalf of the ISG-EHCV coauthors, International diagnostic guidelines for patients with HCV-related extrahepatic manifestations. A multidisciplinary expert statement, Autoimmun Rev. 2016 Dec;15(12):1145-1160. doi: 10.1016/j.autrev.2016.09.006

The publisher's version is available at:

https://www.sciencedirect.com/science/article/abs/pii/S1568997216302014?via%3Dihub

When citing, please refer to the published version.

Link to this full text:
http://hdl.handle.net/2318/1635431

iris-AperTO

University of Turin's Institutional Research Information System and Open Access Institutional Repository

International diagnostic guidelines for patients with HCV-related extrahepatic manifestations. A multidisciplinary expert statement.

Clodoveo Ferri, Manuel Ramos-Casals, Anna Linda Zignego, Luca Arcaini, Dario Roccatello, Alessandro Antonelli, David Saadoun, Marco Sebastiani, Zobair M Younossi, and Patrice Cacoub
on behalf of the ISG-EHCV coauthors.

ISG-EHCV (International Study Group of Extrahepatic Manifestations Related to Hepatitis C Virus Infection):
Convenor/coordinator: Patrice Cacoub;
Co-convenors: Clodoveo Ferri, Manuel Ramos-Casals, Anna Linda Zignego;
Members & co-Authors: see Appendix

Authors affiliations:
Clodoveo Ferri, MD, Marco Sebastiani, MD: *Chair and Rheumatology Unit, Medical School, University of Modena and Reggio Emilia, Azienda Ospedaliero- Universitaria, Policlinico di Modena, 41124 Modena, Italy*
Manuel Ramos-Casals, MD: *Department of Autoimmune Diseases, ICMiD Josep Font Autoimmune Lab, CELLEX-IDIBAPS, Hospital Clinic, Barcelona, Spain*
Anna Linda Zignego, MD: *Interdepartmental Center for Systemic Manifestations of Hepatitis Viruses (MaSVE), Department of Experimental and Clinical Medicine, University of Florence, Florence, Italy*
Luca Arcaini, MD: *Department of Molecular Medicine, University of Pavia & Department of Hematology Oncology, Fondazione IRCCS Policlinico San Matteo, Pavia, Italy*
Dario Roccatello, MD: *Center of Research of Immunopathology and Rare Diseases, and Nephrology and Dialysis Unit. San G. Bosco Hospital and University of Turin, Italy*
Alessandro Antonelli, MD: *Department of Clinical and Experimental Medicine, University of Pisa, Via Savi 10, Pisa 56126, Italy.*
Zobair M Younossi, MD: Center for Liver Diseases, Department of Medicine, Inova Fairfax Hospital; Beatty Liver and Obesity Program, Betty and Guy Beatty Center for Integrated Research, Inova Health System, Falls Church, VA, USA
David Saadoun, MD, Patrice Cacoub, MD: *Sorbonne University, UPMC Univ Paris 06, UMR 7211, and Inflammation-Immunopathology-Biotherapy Department (DHU i2B), Paris, France; INSERM, UMR S 959, Paris, France; CNRS, FRE3632, Paris, France; AP-HP, Groupe Hospitalier Pitié-Salpêtrière, Department of Internal Medicine and Clinical Immunology, Paris, France*

Running title: *diagnostic guidelines of HCV extrahepatic disorders*

Key words: *hepatitis C virus, HCV, extrahepatic disorders, diagnostic guidelines, autoimmunity, hepatitis, mixed cyoglobulinemia, lymphoma, neuropathy, sicca syndrome, arthritis, diabetes, thyroid, porphyria*

Words count abstract: 320

Words count text: 6,471

Corresponding author:
Clodoveo Ferri
Azienda Ospedaliero- Universitaria, Policlinico di Modena,
Via del Pozzo 71, 41124 Modena, Italy

iris-AperTO

University of Turin's Institutional Research Information System and Open Access Institutional Repository

Email: clodoveoferri@unimo.it

iris-AperTO

University of Turin's Institutional Research Information System and Open Access Institutional Repository

Abstract

Hepatitis C virus (HCV) infection is responsible for both hepatic and extra-hepatic disorders (HCV-EHDs); these latter are clearly correlated with HCV lymphotropism causing immune-system dysregulation as well as with viral oncogenic potential. The spectrum of HCV-EHDs range from mild-moderate manifestations such as arthralgias, sicca syndrome, peripheral neuropathy, to severe, life-threatening complications, mainly vasculitic and neoplastic complications. Given the clinical heterogeneity of HCV-EHDs, HCV-infected individuals are frequently referred to different specialists according to the presenting/prevalent symptom(s); therefore, comprehensive diagnostic guidelines are necessary for a whole patient's assessment that is decisive for early diagnosis and correct therapeutic approach of various hepatic and HCV-EHDs, regardless the specific competencies of single referral centers.

In this respect, a multidisciplinary network of experts, the International Study Group of Extrahepatic Manifestations Related to Hepatitis C Virus Infection (ISG-EHCV), elaborated diagnostic guidelines of HCV-EHDs based on different proven expertises.

There was a broad consensus among ISG-EHCV members on the proposed guidelines, taking into account two main levels of patients' assessment. At the referral, all patients with HCV infection should be invariably examined by means of first-line diagnostic procedures including virological and hepatic parameter evaluation, as well as the detection of clinical findings suggestive of one or more HCV-EHDs. This preliminary assessment may reveal specific HCV-EHDs, which will be deeper investigated by means of second-line, targeted investigations.

The proposed multidisciplinary expert statement represents the first attempt to draw comprehensive diagnostic guidelines for HCV-infected individuals encompassing the entire spectrum of HCV-related disorders, namely typical hepatic manifestations along with less common, often unpredictable HCV-EHDs. These latter, alone or more often in combination with liver involvement, may unfavorably contribute to the overall disease outcome in a significant number of HCV-infected individuals.

In conclusion, the application of standardized, thorough diagnostic guidelines is greatly advisable since the patient's referral and during the follow-up; the proposed strategy is critical for the whole patient's clinical outcome, as well as for etiopathogenetic studies needing homogeneous disease subsets.

iris-AperTO

University of Turin's Institutional Research Information System and Open Access Institutional Repository

iris-AperTO

University of Turin's Institutional Research Information System and Open Access Institutional Repository

1. Introduction

Hepatitis C virus (HCV) infection represents one of the most challenging health problems considering its large diffusion worldwide and the frequent complication with both hepatic and extra-hepatic disorders (HCV-EHDs) (1-6). In term of morbidity and mortality HCV-infected individuals are at risk of the most harmful hepatic complications, i.e. cirrhosis and liver cancer (7), and less frequently of HCV-EHDs. These latter are the result of immune-system dysregulation due to the lymphotropism of HCV (1-3, 6, 8) responsible for different autoimmune and/or lymphoproliferative disorders that may severely affect the overall patients' outcome (1-6, 9-11). Single HCV-EHDs are characterized by widely variable distribution among patients' populations from different countries (1-6); moreover, the percentage of patients with at least one HCV-EHDs may increase during the natural course of HCV infection (1-6, 10, 11). However, the actual incidence of HCV-EHDs is not systematically investigated worldwide, probably due to their insidious, often subclinical course, and mostly to the lack of uniform diagnostic approach to HCV-infected patients. As consequence, the overall incidence of HCV-EHDs can be underestimated or in some instances overlooked entirely. The present work is the first attempt to draw comprehensive diagnostic guidelines for patients with HCV-EHDs based on international, multidisciplinary expert consensus statement.

1.1. Background

HCV is both hepato- and lymphotropic virus (1-6, 8); these biological characteristics may explain the variety of HCV-related hepatic and extrahepatic disorders (1-6, 8). Following the discovery in 1989 of HCV as the major agent of non-A/non-B chronic hepatitis (12), mixed cryoglobulinemia syndrome (MCs) was the first well-recognized condition that may complicate long-lasting HCV infection (1-6, 13). MCs is a systemic, multifaceted condition mimicking various autoimmune-lymphoproliferative diseases; therefore, initial studies on HCV-related MCs prompted a number of clinico-epidemiological investigations regarding other disorders potentially triggered by the same causative agent. During the last decades an increasing number of clinical investigations on large cohorts of HCV chronically infected individuals focused on different putative HCV-EHDs (1-6, 14). Fig. 1 shows a provisional classification of HCV-EHDs according to the strength of association based on multiple clinico-epidemiological, and laboratory parameters (1-6); in particular, the prominent role of HCV in the large majority of patients with MCs and in a significant percentage of B-cell non-Hodgkin's lymphomas (B-NHL). Both disorders can be regarded as direct consequence of HCV lymphotropism (1-6, 15, 16). The geographical disomogeneous distribution of HCV-EHDs suggests a multifactorial etiopathogenetic mechanism of HCV-EHDs, including environmental and/or predisposing genetic co-factors (1-6). In addition, HCV syndrome encompassing both hepatic and HCV-EHDs is the result of multistep pathogenetic process; the symptom composition may largely modify during the patients' long-term follow-up (Fig. 2; 1,2,4,10). Therefore, a systematic clinical evaluation of possible hepatic and HCV-EHDs is essential for effective HCV-infected patients' management, and not secondarily for valuable etiopathogenetic studies on homogeneous patients' subsets.

1.2. Methods

The International Study Group of Extrahepatic Manifestations Related to Hepatitis C Virus Infection (ISG-EHCV) is a multidisciplinary network of experts formed in order to provide a

iris-AperTO

University of Turin's Institutional Research Information System and Open Access Institutional Repository

homogeneous diagnostic and therapeutic approach to patients with HCV-EHDs. With regards to the production of diagnostic guidelines the ISG-EHCV convenor and co-convenors invited other ISG-EHCV members on the basis of their well-known expertise in the field of HCV-related manifestations. This task force initially gathered via e-mail and successively via teleconference meetings for the discussion of different issues; in addition, a systematic review of the literature was done in order to identify articles in English or in any language with English abstracts correlated to different topics of the study.
When available, disease definitions and validated classification/diagnostic criteria, as well as standardized methodologies for serological investigations and single organ damage detection were followed (1-6, 14, 17, 18), including current classification criteria for well-definite disorders such as MCs, primary Sjögren's syndrome (pSS), rheumatoid arthritis (RA), and autoimmune hepatitis (17-23).

1.3. Results.

1.3.1. General patients' assessment.

In the clinical practice, it is widely demonstrated that different HCV-EHDs (Fig. 1, 2) may potentially develop at any time during the natural course of HCV infection (1-6, 10). Consequently, the ISG-EHCV recommends that all HCV-positive individuals should undergo a comprehensive clinical evaluation at the first visit (Tab. 1) and at regular time intervals during the follow-up for both liver involvement and HCV-EHDs. For a correct clinical monitoring and early detection of HCV-EHDs each patient should be provided with a booklet for symptom recording.
The patient's first evaluation is mainly based on a thorough questionnaire and physical examination able to identify different signs and symptoms of disease (Tab. 1); a core set of laboratory and instrumental investigations is also required in order to reveal the main HCV-related organ- and/or non-organ-specific manifestations (Fig. 2, 3).
Patients with clinical and/or laboratory alterations suggestive of one or more HCV-EHDs should be thoroughly evaluated by means of second-line, targeted clinical investigations (Tab. 1) (Fig. 4).

1.3.2. Diagnosis of single HCV-EHDs.

Clinical characteristics and diagnostic guidelines of different HCV-EHDs are described in detail in the following paragraphs.

Mixed cryoglobulinemia syndrome.

MCs represents the most common and widely investigated condition among different HCV-EHDs (1-6, 24, 25). The disease is generally classified as systemic vasculitis, in the setting of small-vessel vasculitides (1-6); therefore, the terms MCs and cryoglobulinemic vasculitis are generally referred to the same clinico-pathological entity (1-6). Circulating mixed cryoglobulins represent the biological hallmark of MCs, which is characterized by typical clinical triad -purpura, weakness, and arthralgias-, low complement C4 fraction, cutaneous leucocytoclastic vasculitis, and multiple visceral organ involvement (1-6, Fig. 2). With the discovery of the causative role of HCV in the large majority of patients, the term 'essential' is referred to a low percentage of MCs patients (1-6, 13); the association with HCV infection is

iris-AperTO

University of Turin's Institutional Research Information System and Open Access Institutional Repository

particularly frequent in some geographical areas, such as Southern Europe, where the presence of other HCV-EHDs are rather observed (1-6). The HCV is directly involved in the pathogenesis of the disease through the virus-driven 'benign' B-cell lymphoproliferation, which is the pathological substrate of MCs (1-6), and the consequent production of circulating cryo- and non-cryoprecipitable immune complexes responsible for vasculitic manifestations (1-6).

Diagnostic guidelines. Serum cryoglobulins are frequently detected in HCV-infected patients, often without relevant clinical significance (1-6, 24); only a minority of individuals may develop overt MCs, generally after a long-lasting HCV infection. The levels of serum mixed cryoglobulins may largely vary among patients and in the same patients during the natural course of the disease (10). Therefore, in subjects with suspected MCs the detection of serum mixed cryoglobulins may be temporarily negative; in these cases repeated laboratory examinations may be necessary to avoid false-negative determination (1, 4, 10). The MCs is characterized by variable symptom combination; it is not rare to observe in a single patient the entire spectrum of MCs symptoms during the natural course of disease: from mild manifestations, i.e. arthralgias, orthostatic purpura, to multiple organ involvement such as glomerulonephritis, hepatitis/cirrhosis, sensory-motor neuropathy, and/or B-NHL, generally as late disease complication (1, 10). This multifaceted syndrome may frequently overlap with other disorders making particularly difficult the diagnosis in individual patients (1-6, 9, 26). The differential diagnosis with other overlapping conditions, mainly pSS and RA, is shown in Tab. 2 (9, 26, 27). Preliminary classification criteria for MCs have been proposed by an international study group in 2011 and successively validated in a large MCs patients' series showing a good sensitivity and specificity (17-18). Detection of serum mixed cryoglobulins is the prerequisite along with a combination of clinico-anamnestic symptoms and laboratory alterations. In all cases, other possible conditions, mainly infectious or neoplastic disorders, potentially associated with cryoglobulinemia must be excluded; among these the hematological malignancies that represent the most frequent causes of cryoglobulinemia, generally type I, monoclonal cryoglobulinemia (1-6).

Arthritis.

Patients with HCV infection and more frequently those with HCV-related MCs complain of arthralgias and less frequently of overt arthritis (1-6, 9, 25, 26, 28). This latter commonly appears as mono- oligoarthritis with non-erosive, scarcely aggressive joint involvement if compared with classical RA (9, 21). Patients with MCs may develop mild oligoarthritis, while RA-like polyarthritis may be sporadically observed in HCV-infected patients, either as distinct HCV-EHD or as self-limiting adverse affect of alpha-interferon treatment (9, 29). Considering the relatively high prevalence of both HCV infection and classical RA in the general population, it is possible to observe a simple disease association (9). Thus, differential diagnosis between HCV-related arthritis and classical RA is mandatory in patients with recent onset inflammatory joint involvement.

Diagnostic guidelines. Tab. 2 reports the main clinico-radiological and serological parameters able to differentiate between arthritis complicating HCV infection and classical RA (9, 29). In particular, HCV-related arthritis is usually non-erosive and seronegative (absence of anti-cyclic citrullinated peptide antibodies) (see also Fig. 3, and 4). Overall, correct patient's classification is essential for the therapeutic implications: mild-moderate HCV-related arthritis is commonly

iris-AperTO

University of Turin's Institutional Research Information System and Open Access Institutional Repository

responsive to conventional disease-modifying antirheumatic drugs (DMARDs), while patients with concomitant HCV infection and RA may be usefully treated with biological DMARDs; in particular, anti-TNFalpha antibodies are generally well tolerated despite the associated viral infection (30).

Sicca syndrome.

Sicca syndrome, i.e. xerosthomia and xeroftalmia, the clinical hallmark of pSS (19, 20), can be also observed in a variety of clinical conditions including HCV infection, as isolated manifestation or more frequently in association with HCV-related MCs (1-6, 28). Moreover, a role of HCV infection may be hypothesized in a small number of patients with SS (1-6, 31). Following available classification criteria for these conditions it is possible to correctly diagnose the majority of patients (17-20). In very few patients with concomitant HCV infection, MCs, and SS the differential diagnosis may be very difficult; thus, in the clinical practice it is more opportune to classify these patients as HCV-positive MCs/SS overlapping syndrome (9, 19, 20, 31); they should be carefully monitored during the follow-up, considering the high risk of lymphomatous complications that characterize both diseases (1-3, 32-35).
Diagnostic guidelines. On the basis of the above-mentioned diagnostic difficulties, a first line assessment of HCV-infected patients should include the routinely detection of sicca syndrome (Tab. 1). It can be successively classified as HCV-related sicca syndrome, alone or in the setting of MCs/SS (Tab. 2) according to current criteria by means of specific serological and instrumental investigations, namely serum mixed cryoglobulinemia, abnormally low complement C4, orthostatic purpura, anti-SSA/SSB antibodies with definite histopathological pattern of sialoadenitis of minor salivary glands (1-3, 17-20, 31-35).

Porphyria cutanea tarda.

The porphyrias are a clinically and genetically heterogeneous group of relatively rare metabolic disorders due to altered heme biosynthesis pathway (36). Porphyria cutanea tarda (PCT) represents the most common clinical variant of porphyrias; it can be categorized in two different subtypes: familial and sporadic (36). The disease is characterized by low activity of uroporphyrinogen decarboxylase (URO-D), the enzyme involved in the heme synthesis. In the familial variant, the enzyme defect is present in hepatocytes and other cells, such as erythrocytes; whereas in the sporadic PCT (more common) the URO-D activity is decreased to 50%, affecting predominantly the hepatocytes. The URO-D deficiency is necessary but not sufficient for the clinical development of PCT, therefore possible pathogenetic co-factors have been proposed, including hepatotropic virus infection (1, 25, 36, 37). This latter hypothesis was also suggested by the frequent chronic liver involvement in patients with sporadic PCT (36). Since 1992, a pathogenetic role of HCV infection has been demonstrated in patients with sporadic PCT rather evident in some geographical area (38, 39, 40). The HCV-related PCT is particularly intriguing due to its pathogenetic implications (1, 25, 36-40). A direct role of HCV can be excluded considering the absence of altered porphyrine metabolism in HCV-positive patients without PCT; it is supposable a molecular mimicry phenomenon between predisposed host and HCV antigens, while altered genes connected with iron metabolism may enhance the immune-reactivity of PCT patients (36-40).
Diagnostic guidelines. In HCV-infected patients diagnosis of PCT can be adequately suggested

iris-AperTO

University of Turin's Institutional Research Information System and Open Access Institutional Repository

by typical cutaneous lesions, namely bullae, hyperpigmentation, and erosions at sun-exposed areas such as hands and face and definitely ascertained by means of simple laboratory investigations (Tab. 1, Fig. 3, 4). In particular, the presence of URO-D deficiency and elevated levels of serum and urinary porphyrins may confirm the diagnosis of PCT (36). Finally, it is opportune to complete the patient's clinical work-up with the evaluation of liver involvement that is frequently associated with both HCV and PCT (36).

B-cell non-Hodgkin lymphoma

After the first reports of a high prevalence of HCV infection in patients with B-cell non-Hodgkin's lymphomas (B-NHL) (15, 41), during the last 20 years the association between HCV infection and B-cell NHL has been clearly established: in a meta-analysis of case-control studies the pooled relative risk of all NHL among HCV-positive subjects was 2.5 (42). The fraction of NHL attributable to HCV is highly heterogeneous by geographical region and may reach 10% in highly endemic areas (1, 2, 16, 43-45). Marginal zone lymphoma (MZL), lymphoplasmacytic lymphoma and diffuse large B-cell lymphoma (DLBCL) are the histotypes most frequently associated with HCV infection (44). Molecular mechanisms of HCV-associated NHL development are still poorly clarified. Three general mechanisms have been proposed for HCV-related lymphomagenesis: continuous stimulation of lymphocyte B-cell receptors by virus antigens, oncogenic effect mediated by intracellular viral proteins during replication of HCV in B-cells, and B-cell damage for mutation of tumor suppressor genes, caused by a transiently intracellular virus ("hit and run" theory) (16). A subset of HCV-positive DLBCL share molecular features with MZL like mutations affecting the NOCTH pathway (46).
Diagnostic guidelines. In subjects with HCV infection, diagnosis of lymphoma must be suspected on the basis of clinical symptoms (Tab. 1; Fig. 3-4) and confirmed by histological examination of involved tissue (nodal and extranodal) and specific histotype must be defined according to WHO Classification of Tumours of Hematopoietic and Lymphoid Tissues (47). Cytology and flow cytometry analysis are generally not sufficient to establish a definitive diagnosis of NHL; however, in absence of nodal and extranodal disease, a diagnosis of monoclonal B-cell lymphocytosis (MBL) can be achieved in HCV-positive subjects with bone marrow histology coupled with flow cytometry findings in peripheral blood and bone marrow (48, 49). Also in specific situations as in splenic marginal zone lymphoma (SMZL), a reliable diagnosis can be assessed with bone marrow histology and phenotype evaluated by immunohistochemistry and flow cytometry without need of splenectomy 50). Overlapping histological features between HCV-positive and HCV-negative cases have been reported (49) but differential diagnosis between MBL and SMZL can be difficult in cases with a splenomegaly justified by HCV infection (35).
Staging of HCV-associated NHL is to be performed according to Lugano classification (51), MZLs are generally not (FDG)-avid diseases and must be staged by means of computed tomography only; positron emission tomography (PET) is indicated in DLCBL and in indolent NHL in case of suspected transformation (52; Fig. 4).
Specific clinical pictures of lymphomas associated with HCV infection have been reported. Among MZLs SMZL is frequently reported in association with HCV infection but there is a great geographic variability with significant HCV-subsets in some studies (43, 53) and rare cases in others (54). French authors described a form of SMZL associated with HCV infection and type II mixed cryoglobulinemia that affects mostly female subjects; symptomatic cryoglobulinemia

iris-AperTO

University of Turin's Institutional Research Information System and Open Access Institutional Repository

was present in the majority of patients (55). Also extranodal marginal zone lymphomas of MALT lymphomas are frequently associated with HCV infection (45); peculiar sites are reported like liver, salivary glands and ocular adnexa (32, 35, 56, 57, 58). A particular presentation of HCV-associated MALT lymphoma is the subcutaneous 'lipoma-like' MZL: this lymphoma has been described in old women presenting single or multiple soft and mobile subcutaneous nodules. The diagnosis can be postponed for many years for the benign appearance of the lesions and clinical course is usually indolent (59). In some cases MZL appear disseminated in HCV-positive patients and a specific MZL subtype is not identifiable (49). As outlined by epidemiological studies, also aggressive NHL can be HCV-related; in particular, a subset of apparently *de novo* diffuse large B-cell lymphoma emerged as a separate entity associated with HCV infection. HCV-positive DLBCL commonly present with advanced stage, extranodal localizations like spleen and liver and elevated levels of serum lactate dehydrogenase, that can be related also to the concomitant hepatitis (60-63). Recently, a new "HCV Prognostic Score" based on performance status, albumin and HCV-RNA load has been proposed as a specific prognostic tool for HCV-associated DLBCL. Further studies also suggest that HCV-associated DLBCL arises more frequently from a preceding low-grade MZL in comparison to de novo DLBCL (46, 60, 62) and therefore pathologist should be aware of reporting a possible residual part of indolent NHL in the diagnostic sample.

Kidney

Nephropathy may develop in small percentage of HCV infected persons, with significantly higher frequency in patients with overt MCs (1-6, 10, 64). The predisposing factors include older age, longer duration of hepatitis, and genetic background (64).
The prevalence of kidney involvement tends to increase during long-term follow-up, and glomerulonephritis may severely affect the overall prognosis of HCV-infected individuals.
Cryoglobulinemic nephritis. The pathogenesis of HCV-related cryoglobulinemic nephritis is the ultimate result of poly-monoclonal expansion of B cells triggered by HCV through a sequence of immunological alterations, i.e. chronic stimulation by HCV infection sustaining the synthesis of IgM rheumatoid factor and consequently of cryoprecipitable ICs, abnormal kinetics and tissue deposition of the HCV-containing ICs, and ineffective cryoglobulin clearance by monocyte/macrophages, which are implicated in perpetuating glomerular damage (65-71).
Clinically, cryoglobulinemic glomerulonephritis may appear with one or more renal symptoms; namely, isolated proteinuria (<3 g/24 h), usually with microscopic hematuria (30%), nephrotic syndrome (20%), acute nephritic syndrome (15%) (some patients show a mixed nephrotic and nephritic syndrome), macroscopic hematuria (10%), chronic renal insufficiency (10%), acute renal failure (10%), and/or oligoanuria (5%) (64).
Diagnostic guidelines are mainly based on renal biopsy that is mandatory in any patient with urinary abnormalities and/or unexplained renal impairment. Ultrasound kidney examination of patients with glomerulonephritis often reveals bilateral cortical hyperechogenicity, while urinary sediment shows a prevalence of polymorphic erythrocytes. However, quality and entity of histologic features, which affect the therapeutic approach, are unpredictable and required careful examination of renal specimens.
Three main glomerular patterns can be recognized as a result of cryoglobulin glomerular deposition (64): a) d*iffuse membranoproliferative glomerulonephritis that is observed in about 80 % of case*,

iris-AperTO

University of Turin's Institutional Research Information System and Open Access Institutional Repository

b) focal membranoproliferative glomerulonephritis (about 10%)
c) mesangial proliferative glomerulonephritis (10%)
*Interstitial and Vascular Lesions may include i*nterstitial leukocyte infiltration and fibrosis usually focal and almost invariably associated with the membranoproliferative forms. Moreover, arteriolosclerotic lesions are present in one third of cases, while frank arteritis is rare.
At immunofluorescence examination diffuse, pseudolinear peripheral capillary wall and mesangial staining for IgM, IgG, and C3 are usually found with a relatively stronger staining for IgMk compared to lambda light chain. Prominent IgM and IgG staining is detected in thrombi, while fibrinogen is found in vessel walls when vasculitis is present. Moreover, electron-dense deposits (electromicroscopy) are detected in subendothelial and mesangial areas together with interposition of glomerular basement membrane by monocytes. Cryoglobulin deposits often display short, curved, thick-walled tubular structures with a diameter of about 30 nm.
Atypical features can be observed in few cases of membranoproliferative glomerulonephritis showing IgA with prevalent mesangial but also parietal localization. In very low percentage of patients, a pattern of membranous nephropathy can be detected with prevalent subepithelial deposits of IgM, IgG, and C3 with crystalloid structured deposits at the electron microscopy examination.
The patients with diffuse membranoproliferative glomerulonephritis show a more remarkable C4 hypocomplementemia, higher levels of proteinuria and a stronger association with serositis, hepatosplenomegaly, leukopenia, peripheral neuropathy, and cardiac involvement compared to patients with other patterns.
Significant prognostic variables include age, male gender, creatinine and proteinuria at the time of renal biopsy, number of clinical relapses, and poor blood pressure control.
HCV-associated non-cryoglobulinemic glomerulonephritis. Due to the diverse histologic patterns and the specific therapeutic implications, biopsy should be done, if not specifically contraindicated, in every HCV infected patient who presents with urinary abnormalities or otherwise unexplained renal insufficiency. A number of alternative renal manifestations, beside cryoglobulinemic nephritis, can be found, including membranous nephropathy, focal segmental sclerosis, IgA nephropathy and other proliferative glomerulonephritis, non-cryoglobulinemic membranoproliferative glomerulonephritis, fibrillary and immunotactoid glomerulopathies, and anti-cardiolipin-associated thrombotic microangiopathy (71). These all are conditions in which the electron microscopy evaluation is mandatory.
It is not rare that membranoproliferative glomerulonephritis is one of presenting symptoms of HCV-associated MCs, while the overt cryoglobulinemic syndrome can appear as late manifestation (10). Therefore, HCV-positive patients with apparently isolated GN should undergo to careful clinico-serological assessment and follow-up in order to exclude other hepatic and extrahepatic disorders, especially the MCs.

Endocrine disorders

The most frequent endocrinological diseases in the setting of HCV-EHDs are autoimmune thyroid disorders (AITD) (72-77) and type 2 diabetes mellitus (T2DM) (78-85); moreover, an increased prevalence of gonadal dysfunction is reported in male HCV-infected individuals (86-89).
Thyroid disorders. A higher prevalence of thyroid disorders in patients with HCV-associated MCs, not only with respect to controls, but also to HCV patients without cryoglobulinemia was

iris-AperTO
University of Turin's Institutional Research Information System and Open Access Institutional Repository

shown, needing a careful monitoring of thyroid function in these patients (72-74). Furthermore, IFN-α therapy is a well-known risk for the development of AITD and dysfunctions (73).
The presence of higher risk of AT and hypothyroidism, and increased circulating AbTPO levels, in female gender, characterized the pattern of thyroid disorders observed in MCs, similarly to HCV patients without MCs (75). Interestingly, the prevalence of papillary thyroid cancer has been found higher in chronically infected patients than in controls, as in HCV-related MCs patients, particularly in those with AT (73, 76, 77).
Diagnostic guidelines. These findings suggest a careful monitoring of thyroid function and nodules in patients with risk factors (female gender, border line high initial TSH, AbTPO positivity, hypoechoic and small thyroid) for the development of thyroid autoimmunity in HCV-positive patients, with/without MCs (Tab. 1; Fig. 3-4). These patients should undergo to determination of free thyroxine (FT4), TSH, AbTg, AbTPO and thyroid ultrasonography approximately every year. In patients with thyroid nodules, a fine-needle aspiration should be performed, if larger than 1 cm, or in presence of suspected malignancy (Tab. 1; Fig. 3-4).

Diabetes, and metabolic disturbances. Liver plays an important role in the carbohydrate metabolism, thus liver diseases, as chronic hepatitis and cirrhosis, are known to have a higher prevalence of disturbed glucose homeostasis, impaired glucose tolerance or insulin resistance (IR) (78, 79), eventually they can develop overt DM (80).
Several epidemiological studies on the seroprevalence of HCV in diabetic patients have evidenced higher percentages than in controls, while analysis in patients seropositive for HCV without cirrhosis, or with MCs, showed higher prevalence of DM compared to HCV-negative controls or HBV-infected patients (81-83).
Actually, how HCV leads to diabetes is still a matter for debate. The type of diabetes manifested by HCV-infected patients is not the classical T2DM: patients with HCV-associated T2DM were leaner than T2DM controls, and showed significantly lower low density lipoproteine (LDL)-cholesterol, systolic and diastolic blood pressure (82, 83). Furthermore, patients with HCV-related MCs and T2DM had non-organ-specific-autoantibodies more frequently (34% *vs* 18%) than non-diabetic HCV-related MCs patients (82). An immune-mediated mechanism has been postulated for diabetes in HCV-infected patients with/without MCs (82). Moreover, clinical trials on HCV patients report improvement of glucose metabolism after antiviral treatment (84) suggesting a direct role of HCV in beta-cell dysfunction.
In HCV patients the DM itself seems to have a selective impact on hepatocellular carcinoma development (HCC) (85), as well an increased risk to develop renal complications (90).
Diagnostic guidelines. Consequently, a periodic evaluation of glycemia, HbA1c, and lipids in HCV patients is recommended (Tab. 1; Fig. 3).

Gonadal dysfunction. Abnormal serum levels of sex hormones can be observed in HCV-related MCs patients (86), while erectile dysfunction has been reported in some HCV-infected males during interferon-alpha treatment (87, 88). Considering anecdotal clinical observations, the prevalence of gonadal dysfunction has been evaluated in 207 HCV-infected male patients (102 with MCs) compared with 207 age- and sex-matched individuals, after the exclusion of patients aged over 55 years, recent interferon-alpha treatment, presence of renal failure, cardio-vascular and psychiatric disorders, diabetes, and/or hypothyroidism (89). HCV-positive patients showed a higher prevalence of erectile dysfunction compared to controls ($P < 0.001$). In addition, abnormally low plasma levels of testosterone were detected in HCV-infected

iris-AperTO

University of Turin's Institutional Research Information System and Open Access Institutional Repository

individuals with erectile dysfunction. This latter was independent of the severity of hepatic damage.

Diagnostic guidelines. As part of a comprehensive diagnostic approach it is advisable that male patients with HCV infection could be also evaluated for possible erectile dysfunction and hormonal status (Tab. 1; Fig. 3). When necessary, the correction of hormonal deficiency may improve the patient's quality of life; in addition, it may restore the inhibitory activity of androgens on the HCV-related immune-system alterations.

Neurological and psychiatric disorders.

The involvement of peripheral and/or central nervous system (CNS) represents one of the most frequent HCV-EHDs (91-97); the complex pathogenesis may include different mechanisms such as the direct HCV neuroinvasion, the immune-mediated injury due to autoantibodies against nervous tissue autoantigens, the ischemic alterations secondary to either cryo- and non-cryoprecipitable immune-complex-mediated vasculitis or atherosclerotic vasculopathy (91-100). Up to 50% of HCV-infected patients may develop a variable combination of different subclinical or clinical manifestations: a) peripheral sensory, motor or sensorimotor mono-/polyneuropathies, small fiber sensory polyneuropathy (less frequently large fiber sensory neuropathy), and autonomic neuropathy; b) CNS manifestations including primarily immune-mediated nervous tissue injury (encephalopathy syndromes, myelitis, encephalomyelitis) and/or cerebrovascular events; these latter as consequence of vasculitic or vasculopathic ischemic damage; c) neuropsychological/-psychiatric manifestations; d) iatrogenic neurologic manifestations, mainly triggered by alpha-interferon treatment (101-103).

Some important co-factor may contribute to neurological manifestations (long-lasting HCV infection, serum cryoglobulins, mainly clinically overt MCs, concomitant cardiovascular/metabolic disorders) together with some risk factors such as male gender, smoking, and/or other infectious diseases (93-95).

Diagnostic guidelines. The clinical onset of peripheral neuropathy is often subacute with distal, symmetric, sensory or sensorimotor polyneuropathy, and less frequently as asymmetrical sensory/motor impairment. The most common symptoms are the sensory loss, paresthesias, numbness, cramps, burning feet, and tingling (91-97) (Tab. 1; Fig. 3-4). In a minority of cases the peripheral neuropathy may be complicated by severe sensory-motor manifestations, which may appear abruptly, often as asymmetric mononeuritis. HCV-associated restless legs syndrome has also been reported as expression of small fiber sensory polyneuropathy (94, 104, 105). All patients with suspected peripheral nerve involvement should be investigated by means of electromyography with peripheral nerve neurophysiological tests and when opportune by histological peripheral nerve examination (mainly sural), including the intraepidermal nerve fiber density (105) (Tab. 1; Fig. 3-4). The CNS involvement is less frequently reported (92-95, 97); well-documented observations of HCV-associated vasculitic involvement of CNS are quite rare and include mostly cryoglobulin-positive patients (94). Clinically, the CNS involvement may present with different symptoms, such as fatigue, depression, cognitive impairment, stroke episodes, transient ischemic attacks, progressive reversible ischemic neurological deficits, lacunar infarctions, or encephalopathic syndrome, which are generally attributable to ischemic events (vasculitic/vasculopathic) and only exceptionally to hemorrhage (92-95, 97). Patients with suspected or overt CNS involvement should be carefully evaluated by means of detailed neurological examination,

iris-AperTO

University of Turin's Institutional Research Information System and Open Access Institutional Repository

disease duration, previous/ongoing treatment (interferons), laboratory (serum cryoglobulins, monoclonal component), and instrumental investigations (Tab. 1; Fig. 3-4). In particular, the detection of CNS vasculitic/vasculopatic alterations may include: transcranial color-Doppler ultrasonography and magnetic resonance (MR) imaging; this latter plays an important role in the workup of patients with suspected vasculitis, even though the abnormalities found on MR imaging are not diagnostic. Brain MR includes a variety of methodologies able to evidence specific CNS alterations. Computed tomography (CT) is less sensitive than MR imaging in the assessment of cerebral vasculitis, with the exception of large ischemic infarctions and hemorrhage. Functional brain MR imaging studies could be usefully employed for specific CNS manifestations, as well as 18F-fluoro-deoxyglucose positron emission tomography scan. CT presents limited spatial resolution; however, it can show parenchymal brain calcifications found within old ischemic lesions (92-95, 97, 106, 107). CT angiography can be used to evaluate both vessel walls and lumen, and thus it may show vessel wall alterations when the lumen is still unaffected at conventional catheter angiography (106). Neuropsychiatric disorders and neurocognitive dysfunction are reported in nearly 50% of patients with chronic HCV infection, which are independent of the presence/severity of hepatic involvement, HCV genotype and/or viral load (95). Fatigue, sleep disturbance, depression and reduced quality of life are commonly associated with neurocognitive alterations in patients with non-cirrhotic HCV infection (95). These subjects should be evaluated for possible neurocognitive decline over time, including the evaluation of motor activity with sleep-wake-rhythm, question naires for depression and health-related quality of life (108).

Finally, patients with chronic HCV infection often have experience of unfavorable psychological conditions because of low socioeconomic status, concomitance of other infections, such as HBV or HIV, discrimination, and limited access to adequate health care (109). An accurate environmental and individual psychological assessment of these patients is mandatory for comprehensive counseling approach and management of the overall HCV syndrome (109).

Cardiovascular

An increased risk to develop cardiovascular diseases in patient with chronic HCV infection has been reported (110, 111). An independent risk factor for the development of some harmful cardiovascular manifestations such as carotid atherosclerosis, heart failure and above-mentioned stroke has been more recently observed (110, 111, 112). More recently a number of data underlined an excess of cardiovascular mortality during the course of chronic HCV infection (113, 114). It is well-known that atherosclerosis is a chronic inflammatory disease secondary to multifactorial pathogenetic process; its incidence is significantly higher in patients with autoimmune and/or infectious diseases (115, 116). Thus, chronic HCV infection can be reasonably identified as a potential atherogenic condition considering the complex of HCV-driven autoimmune/inflammatory alterations, characterized by increased levels of pro-atherogenic chemokines and cytokines (74, 117) (Fig. 1-2). On the other hand, HCV may be considered a 'metabolic' virus, in particular it can promote insulin resistance and type 2 diabetes, two leading pro-atherogenic conditions (80, 83). Finally, HCV may direct promote atherosclerotic lesions as suggested by HCV detection and replication within carotid plaques (118). Clinical trials with antiviral treatments should indirectly clarify the actual atherogenic role of HCV infection in the near future.

Diagnostic guidelines. Considering the increased prevalence and prognostic relevance of cardiovascular events, it is clearly opportune to include these harmful manifestations among

iris-AperTO

University of Turin's Institutional Research Information System and Open Access Institutional Repository

HCV-EHDs. Therefore, a noninvasive screening (Tab. 1; Fig. 3-4) for cardiovascular alterations (Doppler ultrasound studies, EKG) is recommendable at the first patient's assessment followed by careful monitoring during the follow-up.

Miscellanea.

A number of disorders has been suggested as possible HCV-EHDs on the basis of epidemiological studies, often referred to limited patients series, or simple anecdotal observations (Fig. 1, columns 3 and 4). In particular, various cutaneous manifestations might be correlated with HCV infection (37, 119), mainly the skin vasculitic lesions varying from orthostatic purpura, the cutaneous hallmark of MCs, to severe necrotizing lesions (1-6). Other cutaneous symptoms such as pruritus, chronic urticaria, or psoriasis have been also associated to HCV infection (37, 119, 120, 121). Furthermore, an heterogeneous assortment of diseases, namely lichen planus, Mooren corneal ulcer, osteosclerosis, fibromyalgia, lung alveolitis, autoimmune hepatitis, poly-dermatomyositis, and panarteritis nodosa have been correlated to HCV infection, generally with a low strength of association (1-6, 9, 37, 119, 122-128) (Fig. 1). For each condition the actual causative role of HCV remains still to be definitely ascertained; among these, subclinical lymphocytic alveolitis has been detected in a significantly percentage of HCV-positive patients series, which in rare cases may lead to severe lung fibrosis (1, 123). This intriguing association might represent a model of virus-driven interstitial lung involvement; on the other hand, it suggests the opportunity of including HCV detection in the clinico-laboratory work-up of patients with apparently idiopathic lung fibrosis (129). Comparable diagnostic approach is advisable for other 'idiopathic' autoimmune diseases, namely autoimmune hepatitis, poly-dermatomyositis, and panarteritis nodosa, which although rarely may develop in the context of chronic HCV infection (1, 6, 9). Overall, first-line clinical work-up of HCV-positive patients may evidence signs/symptoms suggestive of the above diseases (Tab. 1). In particular, dyspnea and chest x-ray alterations may reveal an underlying interstitial lung involvement; while, myalgias, proximal muscle weakness, and/or increased creatine phosphokinase serum levels are highly indicative for myositic process (Tab. 1). Conversely, patients affected by one of the above autoimmune disorders should be routinely evaluated for the presence of potential infectious triggering factors, including HCV infection (1, 6, 9, 129). These diseases are generally classified as 'idiopathic' conditions; they often represent clinical syndromes encompassing different phenotypes possibly correlated to different etiological factors (1, 9, 26, 28, 124, 125). Thus, the proposed pathogenetic link between a definite disease and HCV infection cannot be excluded *a priori*; the virus could play a pathogenetic role in a small disease subset or sporadically in individual patients at all. Finally, a coincidental association between HCV and diseases is also possible considering the large diffusion of HCV infection in the general population; in any cases, the presence of simple comorbidity need to be always verified due to the additional implications of HCV infection in the whole patient management.

1.3.3. Monitoring of HCV-infected patients

Patients with apparently isolated HCV infection are commonly referred to tertiary specialized centers according to prevalent clinical manifestations. However, they should undergo to comprehensive clinical evaluation of possible hepatic and/or extrahepatic disorders at baseline and at regular time intervals during the follow-up. Tab. 1 reports the first line clinical work-up of HCV-infected patients that in the large majority of cases may be able to evidence

iris-AperTO

University of Turin's Institutional Research Information System and Open Access Institutional Repository

overt HCV-EHDs or to suggest the subclinical presence of such complications. Moreover, long-term clinical monitoring of patients with chronic HCV infection may be decisive for early diagnosis of different HCV-EHDs and opportune therapeutical decisions. The careful follow-up and timely treatment of HCV-EHDs may affect the patients' quality of life and prognosis, mainly in patients with more severe visceral organ damages and/or malignancies, mainly HCC and B-NHL.

1.4. Discussion

The large diffusion of HCV infection in the general population and its frequent hepatic and extrahepatic manifestations are a serious medical problem that involves transversally different medical subspecialties (1,2, 6, 11, 109). The HCV syndrome is an important model of chronic multisystem disease needing very often a long-term multidisciplinary management (1-6). The necessarily holistic approach to these patients represents a great challenge for the clinicians because of the variety and unpredictability of HCV-EHDs. HCV-infected individuals are often referred to different tertiary centers according to the presenting/prevalent symptom(s) with the potential risk to underestimate the remaining clinical manifestations.

As regards the diagnostic aspects, previously published studies generally analyzed a single manifestation at once in the variegated field of HCV-EHDs (1, 2). The present work represents the first attempt to draw comprehensive diagnostic guidelines for HCV-infected individuals encompassing the entire spectrum of HCV-EHDs, based on the specific expertise of different co-authors. Considering the heterogeneity of HCV syndrome and in particular of HCV-EHDs, the preparation of diagnostic guidelines resulted particularly difficult. They should be sufficiently inclusive and thorough with respect to various symptoms that may complicate the natural course of HCV infection, but in the same time easily manageable in the clinical practice by different specialists dealing with HCV-infected patients. The patient's assessment at the first referral and during the follow-up should be based on the routinely adoption of first-line core set of diagnostic procedures, possibly integrated by deeper clinical investigations focusing on specific clinical manifestations. There was a broad consensus among ISG-EHCV members on item selection of baseline clinical evaluation; while for single HCV-EHDs, i.e. rheumatic, renal, hematological, and endocrine manifestations, targeted second line diagnostic procedures were proposed by the expert team. Moreover, when available classification/diagnostic criteria for single HCV-EHDs such as MCs were properly taken into account (17-23).

THe HCV lymphotropism along with its striking association with MCs were firstly demonstrated in the early nineties soon after the HCV discovery (12, 13, 130, 131). These important findings prompted an increasing number of studies on different autoimmune-lymphoproliferative HCV-EHDs (1-6). Apart from hepatic manifestations, a significant percentage of HCV-infected individuals may remain totally asymptomatic for years or the entire life. While the presence of some immunological alterations as serum rheumatoid factor and/or cryoglobulinemia may be occasionally found (1-7). In particular, circulating cryoglobulins may be detected in almost half of HCV-infected patients but without any clinical significance, while overt MCs may develop in less than 5% of cryoglobulinemic patients (1-6). Some individuals with serum antinuclear antibodies, chronic hepatitis, and one or more mild extrahepatic manifestations such as arthralgias/arthritis, sicca syndrome, and/or thyroiditis, may mimic autoimmune hepatitis; in these cases the differential diagnosis is quite feasible by means of current classification criteria (1-6, 9). Other overlapping conditions may regard HCV-

iris-AperTO

University of Turin's Institutional Research Information System and Open Access Institutional Repository

infected patients with autoimmune features mimicking classical rheumatic diseases, mainly RA and pSS (1-6, 9, 35). In these instances, it is necessary to correctly differentiate patients with true 'primary' autoimmune diseases and concomitant HCV infection from patients with HCV-EHDs (1, 2, 6, 28, 35). Actually, the diagnosis of HCV-related MCs may be controversial in some patients because of the presence of one or more symptoms distinctive of other well-definite autoimmune disorders (9). MCs may be correctly classified following the criteria elaborated by international study group proposed by GISC (Italian Study Group on Cryoglobulinemia) (17, 18) in the majority of cases; while in some patients it is very difficult to distinguish between true HCV-related MCs and other well-known conditions, particularly the pSS (1, 2, 6, 28). For these patients the term of 'overlapping syndrome' may be rather appropriate, mainly in consideration of the concomitant impact of HCV infection *per se* and when present of cryoglobulinemic vasculitis on the worse patients' outcome (1,9).
The spectrum of HCV-EHDs is extremely heterogeneous; it includes immune-mediated, organ- and non-organ specific disorders as well as neoplastic manifestations (1-6, 44). The possible multistep contribution of different pathogenetic cofactors, genetic and environmental, may be decisive for the appearance of novel, specific clinical phenotypes; these latter can be observed at any time during the natural history of HCV infection, variably combined in individual patients (1, 9). Some harmful, life-threatening complications may appear abruptly; thus, careful clinical monitoring of HCV-infected patients is crucial for early diagnosis and treatment of these unpredictable manifestations. It is supposable that recently available direct-acting antiviral treatments leading to HCV eradication in a very high percentage of patients (132, 133) may affect in the near future the natural history of HCV infection, and consequently the overall prevalence and outcome of hepatic and HCV-EHDs. Considering the extrahepatic manifestations, some preliminary studies regarding small patients series demonstrated a marked improvement or disappearance of some symptoms, particularly MCs or lymphomatous complications (1-6). However, it is supposable that profound HCV-driven immune-system alterations may result totally or at least in part irreversible in some patients, mainly in those with long-lasting viral infection. Thus, current antiviral treatments might lead to novel, unforeseeable scenarios. Future clinical trials focusing on patients with sustained virological response might elucidate the above questions; these studies may be decisive in order to quantify the actual percentage of remission of different HCV-EHDs, as well as to identify possible predictive factors of different disease outcomes.
In conclusion, a multidisciplinary approach to HCV-infected patients is greatly advisable since the first patient's evaluation; comprehensive clinical assessment following standardized diagnostic guidelines is critical for the whole patients' management and therapeutic strategies, as well as for pathogenetic studies focusing on homogeneous clinical subsets.

iris-AperTO

University of Turin's Institutional Research Information System and Open Access Institutional Repository

Take-home messages

(for Autoimmunity Reviews)

- Hepatitis C virus (HCV) infection is responsible for both hepatic and extra-hepatic disorders (HCV-EHDs)
- Due to clinical heterogeneity of HCV-EHDs, patients may be referred to different specialists
- Comprehensive diagnostic guidelines are necessary for a whole patient's assessment at the first referral and during the follow-up
- The International Study Group of Extrahepatic Manifestations Related to HCV Infection elaborated diagnostic guidelines of HCV-EHDs
- All HCV-infected patients should undergo first-line diagnostic procedures able to identify one or more HCV-EHDs
- Patients with suspected HCV-EHDs will be deeper investigated by means of second-line, targeted investigations

iris-AperTO

University of Turin's Institutional Research Information System and Open Access Institutional Repository

1. Ferri C, Sebastiani M, Giuggioli D, Colaci M, Fallahi P, Piluso A, Antonelli A, Zignego AL. Hepatitis C virus syndrome: A constellation of organ- and non-organ specific autoimmune disorders, B-cell non-Hodgkin's lymphoma, and cancer. World J Hepatol. 2015 Mar 27;7(3):327-43.
2. Cacoub P, Gragnani L, Comarmond C, Zignego AL. Extrahepatic manifestations of chronic hepatitis C virus infection. Dig Liver Dis. 2014 Dec 15;46 Suppl 5:S165-73.
3. Ramos-Casals M, Stone JH, Cid MC, Bosch X. The cryoglobulinaemias. Lancet. 2012 Jan 28;379(9813):348-60.
4. Ferri C, Zignego AL, Pileri SA. Cryoglobulins. Journal of clinical pathology; 2002; 55: 4-13.
5. Terrier B, Cacoub P. Cryoglobulinemia vasculitis: an update. Curr Opin Rheumatol. 2013 Jan;25(1):10-8.
6. Zignego AL, Ferri C, Pileri SA, Caini P, Bianchi FB; Italian Association of the Study of Liver Commission on Extrahepatic Manifestations of HCV infection. Extrahepatic manifestations of Hepatitis C Virus infection: a general overview and guidelines for a clinical approach. Dig Liver Dis. 2007 Jan;39(1):2-17.
7. Westbrook RH, Dusheiko G. Natural history of hepatitis C. J Hepatol. 2014; 61:S58-68
8. Zignego AL, Gragnani L, Piluso A, Sebastiani M, Giuggioli D, Fallahi P, Antonelli A, Ferri C. Virus-driven autoimmunity and lymphoproliferation: the example of HCV infection. Expert Rev Clin Immunol. 2015 Jan;11(1):15-31.
9. Ferri C, Sebastiani M, Antonelli A, Colaci M, Manfredi A, Giuggioli D. Current treatment of hepatitis C-associated rheumatic diseases. Arthritis Res Ther. 2012; 14: 215.
10. Ferri C, Sebastiani M, Giuggioli D, Cazzato M, Longombardo G, Antonelli A, Puccini R, Michelassi C, Zignego AL. Mixed cryoglobulinemia: demographic, clinical, and serological features, and survival in 231 patients. Semin arthritis rheum. 2004; 33: 355-74.
11. Negro F, Forton D, Craxì A, Sulkowski MS, Feld JJ, Manns MP. Extrahepatic morbidity and mortality of chronic hepatitis C. Gastroenterology. 2015; 149:1345-60
12. Choo GL, Kuo G, Weiner AJ, et al. Isolation of a cDNA clone derived from a blood-borne non-A non-B viral hepatitis genome. Science 1989; 244: 359–61.
13. Ferri C, Greco F, Longombardo G, Palla P, Marzo E, Moretti A, Mazzoni A, Pasero G, Bombardieri S, Highfield P, Corbishley T. Association between hepatitis C virus and mixed cryoglobulinemia. Clinical and experimental rheumatology. 1991; 9: 621-4.
14. Monti G, Galli M, Invernizzi F, Pioltelli P, Saccardo F, Monteverde A, Pietrogrande M, Renoldi P, Bombardieri S, Bordin G, Candela M, Ferri C, Gabrielli A, Mazzaro C, Migliaresi S, Mussini C, Ossi E, Quintiliani L, Tirri G, Vacca A, and GISC. Italian Group for the Study of Cryoglobulinaemias. Cryoglobulinaemias: a multi-centre study of the early clinical and laboratory manifestations of primary and secondary disease. QJM 1995; 88: 115-26.
15. Ferri C, Caracciolo F, Zignego AL, La Civita L, Monti M, Longombardo G, Lombardini F, Greco F, Capochiani E, Mazzoni A, Mazzaro C, Pasero G. Hepatitis C virus infection in patients with non-Hodgkin's lymphoma. British journal of haematology . 1994; 88: 392-4.
16. Peveling-Oberhag J, Arcaini L, Hansmann ML, Zeuzem S. Hepatitis C-associated B-cell non-Hodgkin lymphomas. Epidemiology, molecular signature and clinical management. J Hepatol. 2013; 59: 169-77.
17. De Vita S, Soldano F, Isola M, Monti G, Gabrielli A, Tzioufas A, Ferri C, Ferraccioli GF, Quartuccio L, Corazza L, De Marchi G, Casals MR, Voulgarelis M, Lenzi M, Saccardo F,

iris-AperTO

University of Turin's Institutional Research Information System and Open Access Institutional Repository

Fraticelli P, Mascia MT, Sansonno D, Cacoub P, Tomsic M, Tavoni A, Pietrogrande M, Zignego AL, Scarpato S, Mazzaro C, Pioltelli P, Steinfeld S, Lamprecht P, Bombardieri S, Galli M. Preliminary classification criteria for the cryoglobulinaemic vasculitis. The Annals of the Rheumatic Diseases. 2011; 70: 1183-90.

18. Quartuccio L, Isola M, Corazza L, Ramos-Casals M, Retamozo S, Ragab GM, Zoheir MN, El-Menyawi MA, Salem MN, Sansonno D, Ferraccioli G, Gremese E, Tzioufas A, Voulgarelis M, Vassilopoulos D, Scarpato S, Pipitone N, Salvarani C, Guillevin L, Terrier B, Cacoub P, Filippini D, Saccardo F, Gabrielli A, Fraticelli P, Sebastiani M, Tomsic M, Tavoni A, Mazzaro C, Pioltelli P, Nishimoto N, Scaini P, Zignego AL, Ferri C, Monti G, Pietrogrande M, Bombardieri S, Galli M, De Vita S. Validation of the classification criteria for cryoglobulinaemic vasculitis. Rheumatology (Oxford). 2014 Dec;53(12):2209-13
19. Vitali C, Bombardieri S, Jonsson R, Moutsopoulos HM, Alexander EL, Carsons SE, Daniels TE, Fox PC, Fox RI, Kassan SS, Pillemer SR, Talal N, Weisman MH; European Study Group on Classification Criteria for Sjögren's Syndrome. Classification criteria for Sjögren's syndrome: a revised version of the European criteria proposed by the American-European Consensus Group. Ann Rheum Dis. 2002 Jun;61(6):554-8.
20. Brito-Zerón P, Theander E, Baldini C, Seror R, Retamozo S, Quartuccio L, Bootsma H, Bowman SJ, Dörner T, Gottenberg JE, Mariette X, Bombardieri S, de Vita S, Mandl T, Ng WF, Kruize AA, Tzioufas A, Vitali C, Buyon J, Izmirly P, Fox R, Ramos-Casals M, On Behalf Of The Eular Sjögren Syndrome Task Force. Early diagnosis of primary Sjögren's syndrome: EULAR-SS task force clinical recommendations. Expert Rev Clin Immunol. 2016 Feb;12(2):137-56
21. Aletaha D, Neogi T, Silman AJ, Funovits J, Felson DT, Bingham CO 3rd, Birnbaum NS, Burmester GR, Bykerk VP, Cohen MD, Combe B, Costenbader KH, Dougados M, Emery P, Ferraccioli G, Hazes JM, Hobbs K, Huizinga TW, Kavanaugh A, Kay J, Kvien TK, Laing T, Mease P, Ménard HA, Moreland LW, Naden RL, Pincus T, Smolen JS, Stanislawska-Biernat E, Symmons D, Tak PP, Upchurch KS, Vencovský J, Wolfe F, Hawker G. 2010 Rheumatoid arthritis classification criteria: an American College of Rheumatology/European League Against Rheumatism collaborative initiative. Arthritis Rheum. 2010 Sep;62(9):2569-81
22. Manns MP, Lohse AW, Vergani D. Autoimmune hepatitis--Update 2015. J Hepatol. 2015; 62: S100-11
23. Alvarez F, Berg PA, Bianchi FB, Bianchi L, Burroughs AK, Cancado EL, Chapman RW, Cooksley WG, Czaja AJ, Desmet VJ, Donaldson PT, Eddleston AL, Fainboim L, Heathcote J, Homberg JC, Hoofnagle JH, Kakumu S, Krawitt EL, Mackay IR, MacSween RN, Maddrey WC, Manns MP, McFarlane IG, Meyer zum Büschenfelde KH, Zeniya M, et al. International Autoimmune Hepatitis Group Report: review of criteria for diagnosis of autoimmune hepatitis. J Hepatol. 1999 Nov;31(5):929-38
24. Monti G, Saccardo F, Castelnovo L, Novati P, Sollima S, Riva A, Sarzi-Puttini P, Quartuccio L, De Vita S, Galli M. Prevalence of mixed cryoglobulinaemia syndrome and circulating cryoglobulins in a population-based survey: the Origgio study. Autoimmun Rev. 2014 Jun;13(6):609-14
25. Younossi Z, Park H, Henry L, Adeyemi A, Stepanova M. Extra-Hepatic Manifestations of Hepatitis C-a Meta-Analysis of Prevalence, Quality of Life, and Economic Burden. Gastroenterology. 2016 Feb 25. pii: S0016-5085(16)00230-4. doi: 10.1053/j.gastro.2016.02.039.
26. Lormeau C, Falgarone G, Roulot D, Boissier MC. Rheumatologic manifestations of

chronic hepatitis C infection. Joint Bone Spine. 2006; 73: 633-8.
27. Sebastiani M, Giuggioli D, Colaci M, Fallahi P, Gragnani L, Antonelli A, Zignego AL, Ferri C. HCV-related rheumatic manifestations and therapeutic strategies. Curr Drug Targets. 2015 Sep 6.
28. Ramos-Casals M, Muñoz S, Medina F, Jara LJ, Rosas J, Calvo-Alen J, Brito-Zerón P, Forns X, Sánchez-Tapias JM; HISPAMEC Study Group. Systemic autoimmune diseases in patients with hepatitis C virus infection: characterization of 1020 cases (The HISPAMEC Registry). J Rheumatol. 2009; 36: 1442-8.
29. Palazzi C, D'Angelo S, Olivieri I. Hepatitis C virus-related arthritis. Autoimmun Rev. 2008; 8: 48-51
30. Ferri C, Govoni M, Calabrese L. The A, B, Cs of viral hepatitis in the biologic era. Curr Opin Rheumatol 2010; 22:443-450.
31. Zeron PB, Retamozo S, Bové A, Kostov BA, Sisó A, Ramos-Casals M. Diagnosis of Liver Involvement in Primary Sjögren Syndrome. J Clin Transl Hepatol. 2013 Dec;1(2):94-102.
32. Ramos-Casals M, la Civita L, de Vita S, Solans R, Luppi M, Medina F, Caramaschi P, Fadda P, de Marchi G, Lopez-Guillermo A, Font J; SS-HCV Study Group. Characterization of B cell lymphoma in patients with Sjögren's syndrome and hepatitis C virus infection. Arthritis Rheum. 2007 Feb 15;57(1):161-70.
33. Pozzato G, Mazzaro C, Crovatto M, Modolo ML, Ceselli S, Mazzi G, Sulfaro S, Franzin F, Tulissi P, Moretti M, et al. Low-grade malignant lymphoma, hepatitis C virus infection, and mixed cryoglobulinemia. Blood. 1994 Nov 1;84(9):3047-53.
34. Dammacco F, Sansonno D, Piccoli C, Racanelli V, D'Amore FP, Lauletta G. The lymphoid system in hepatitis C virus infection: autoimmunity, mixed cryoglobulinemia, and Overt B-cell malignancy. Semin liver dis. 2000; 20: 143-57.
35. Retamozo S, Gheitasi H, Quartuccio L, Kostov B, Corazza L, Bové A, Sisó-Almirall A, Gandía M, Ramos-Casals M, De Vita S, Brito-Zerón P. Cryoglobulinaemic vasculitis at diagnosis predicts mortality in primary Sjögren syndrome: analysis of 515 patients. Rheumatology (Oxford). 2016 Apr 23. pii: kew194.
36. Karim Z, Lyoumi S, Nicolas G, Deybach JC, Gouya L, Puy H. Porphyrias: A 2015 update. Clin Res Hepatol Gastroenterol. 2015 Sep;39(4):412-25
37. Dedania B, Wu GY. Dermatologic Extrahepatic Manifestations of Hepatitis C. J Clin Transl Hepatol. 2015 Jun 28;3(2):127-33
38. Fargion S, Piperno A, Cappellini MD, Sampietro M, Fracanzani AL, Romano R, Caldarelli R, Marcelli R, Vecchi L, Fiorelli G. Hepatitis C virus and porphyria cutanea tarda: evidence of a strong association. Hepatology; 1992; 16: 1322-6.
39. Ferri C, Baicchi U, La Civita L, Greco F, Longombardo G, Mazzoni A, Careccia G,Bombardieri S, Pasero G, Zignego AL. Hepatitis C virus-related autoimmunity in patients with porphyria cutanea tarda. European Journal of Clinical Investigation; 1993; 23: 851-5.
40. Gisbert JR Garcla-Buey L, Pajares JM, Moreno-Otero R. Prevalence of hepatitis C virus infection in porphyria cutanea tarda: systematic review and meta-analysis. Journal of Hepatology; 2003; 39: 620-7.
41. Ferri, C., La Civita, L., Caracciolo, F. & Zignego, A.L. (1994) Non-Hodgkin's lymphoma: possible role of hepatitis C virus. JAMA, 272, 355-356.
42. Dal Maso L, Franceschi S. (2006) Hepatitis C virus and risk of lymphoma and other lymphoid neoplasms: a meta-analysis of epidemiologic studies. Cancer Epidemiol Biomarkers Prev, 15, 2078-2085.
43. Chuang, S.S., Liao, Y.L., Chang, S.T., Hsieh, Y.C., Kuo, S.Y., Lu, C.L., Hwang, W.S., Lin, I.H.,

iris-AperTO

University of Turin's Institutional Research Information System and Open Access Institutional Repository

Tsao, C.J. & Huang, W.T. (2010) Hepatitis C virus infection is significantly associated with malignant lymphoma in Taiwan, particularly with nodal and splenic marginal zone lymphomas. J Clin Pathol, 63, 595-598.

44. de Sanjose, S., Benavente, Y., Vajdic, C.M., Engels, E.A., Morton, L.M., Bracci, P.M., Spinelli, J.J., Zheng, T., Zhang, Y., Franceschi, S., Talamini, R., Holly, E.A., Grulich, A.E., Cerhan, J.R., Hartge, P., Cozen, W., Boffetta, P., Brennan, P., Maynadie, M., Cocco, P., Bosch, R., Foretova, L., Staines, A., Becker, N. & Nieters, A. (2008) Hepatitis C and non-Hodgkin lymphoma among 4784 cases and 6269 controls from the International Lymphoma Epidemiology Consortium. Clin Gastroenterol Hepatol, 6, 451-458.
45. Arcaini, L., Burcheri, S., Rossi, A., Paulli, M., Bruno, R., Passamonti, F., Brusamolino, E., Molteni, A., Pulsoni, A., Cox, M.C., Orsucci, L., Fabbri, A., Frezzato, M., Voso, M.T., Zaja, F., Montanari, F., Merli, M., Pascutto, C., Morra, E., Cortelazzo, S. & Lazzarino, M. (2007) Prevalence of HCV infection in nongastric marginal zone B-cell lymphoma of MALT. Ann Oncol, 18, 346-350.
46. Arcaini, L., Rossi, D., Lucioni, M., Nicola, M., Bruscaggin, A., Fiaccadori, V., Riboni, R., Ramponi, A., Ferretti, V.V., Cresta, S., Casaluci, G.M., Bonfichi, M., Gotti, M., Merli, M., Maffi, A., Arra, M., Varettoni, M., Rattotti, S., Morello, L., Guerrera, M.L., Sciarra, R., Gaidano, G., Cazzola, M. & Paulli, M. (2015) The NOTCH pathway is recurrently mutated in diffuse large B-cell lymphoma associated with hepatitis C virus infection. Haematologica, 100, 246-252.
47. Swerdlow SH, C.E., Harris NL, Jaffe ES, Pileri SA, Stein H, Thiele J, Vardiman JW (2008) WHO Classification of Tumours of Haematopoietic and Lymphoid Tissues. IARC Press, Lyon.
48. Fazi, C., Dagklis, A., Cottini, F., Scarfo, L., Bertilaccio, M.T., Finazzi, R., Memoli, M. & Ghia, P. (2010) Monoclonal B cell lymphocytosis in hepatitis C virus infected individuals. Cytometry B Clin Cytom, 78 Suppl 1, S61-68.
49. Mollejo, M., Menarguez, J., Guisado-Vasco, P., Bento, L., Algara, P., Montes-Moreno, S., Rodriguez-Pinilla, M.S., Cruz, M.A., Casado, F., Montalban, C. & Piris, M.A. (2014) Hepatitis C virus-related lymphoproliferative disorders encompass a broader clinical and morphological spectrum than previously recognized: a clinicopathological study. Mod Pathol, 27, 281-293.
50. Matutes, E., Oscier, D., Montalban, C., Berger, F., Callet-Bauchu, E., Dogan, A., Felman, P., Franco, V., Iannitto, E., Mollejo, M., Papadaki, T., Remstein, E.D., Salar, A., Sole, F., Stamatopoulos, K., Thieblemont, C., Traverse-Glehen, A., Wotherspoon, A., Coiffier, B. & Piris, M.A. (2008) Splenic marginal zone lymphoma proposals for a revision of diagnostic, staging and therapeutic criteria. Leukemia, 22, 487-495.
51. Cheson, B.D., Fisher, R.I., Barrington, S.F., Cavalli, F., Schwartz, L.H., Zucca, E., Lister, T.A., Alliance, A.L., Lymphoma, G., Eastern Cooperative Oncology, G., European Mantle Cell Lymphoma, C., Italian Lymphoma, F., European Organisation for, R., Treatment of Cancer/Dutch Hemato-Oncology, G., Grupo Espanol de Medula, O., German High-Grade Lymphoma Study, G., German Hodgkin's Study, G., Japanese Lymphorra Study, G., Lymphoma Study, A., Group, N.C.T., Nordic Lymphoma Study, G., Southwest Oncology, G. & United Kingdom National Cancer Research, I. (2014) Recommendations for initial evaluation, staging, and response assessment of Hodgkin and non-Hodgkin lymphoma: the Lugano classification. J Clin Oncol, 32, 3059-3068.
52. Dreyling, M., Thieblemont, C., Gallamini, A., Arcaini, L., Campo, E., Hermine, O., Kluin-Nelemans, J.C., Ladetto, M., Le Gouill, S., Iannitto, E., Pileri, S., Rodriguez, J., Schmitz, N., Wotherspoon, A., Zinzani, P. & Zucca, E. (2013) ESMO Consensus conferences:

iris-AperTO

University of Turin's Institutional Research Information System and Open Access Institutional Repository

guidelines on malignant lymphoma. part 2: marginal zone lymphoma, mantle cell lymphoma, peripheral T-cell lymphoma. Ann Oncol, 24, 857-877.

53. Arcaini, L., Lazzarino, M., Colombo, N., Burcheri, S., Boveri, E., Paulli, M., Morra, E., Gambacorta, M., Cortelazzo, S., Tucci, A., Ungari, M., Ambrosetti, A., Menestrina, F., Orsucci, L., Novero, D., Pulsoni, A., Frezzato, M., Gaidano, G., Vallisa, D., Minardi, V., Tripodo, C., Callea, V., Baldini, L., Merli, F., Federico, M., Franco, V. & Iannitto, E. (2006) Splenic marginal zone lymphoma: a prognostic model for clinical use. Blood, 107, 4643-4649.
54. Thieblemont, C., Felman, P., Berger, F., Dumontet, C., Arnaud, P., Hequet, O., Arcache, J., Callet-Bauchu, E., Salles, G. & Coiffier, B. (2002) Treatment of splenic marginal zone B-cell lymphoma: an analysis of 81 patients. Clin Lymphoma, 3, 41-47.
55. Saadoun, D., Suarez, F., Lefrere, F., Valensi, F., Mariette, X., Aouba, A., Besson, C., Varet, B., Troussard, X., Cacoub, P. & Hermine, O. (2005) Splenic lymphoma with villous lymphocytes, associated with type II cryoglobulinemia and HCV infection: a new entity? Blood, 105, 74-76.
56. Ambrosetti, A., Zanotti, R., Pattaro, C., Lenzi, L., Chilosi, M., Caramaschi, P., Arcaini, L., Pasini, F., Biasi, D., Orlandi, E., D'Adda, M., Lucioni, M. & Pizzolo, G. (2004) Most cases of primary salivary mucosa-associated lymphoid tissue lymphoma are associated either with Sjoegren syndrome or hepatitis C virus infection. Br J Haematol, 126, 43-49.
57. Arnaud, P., Escande, M.C., Lecuit, M., Validire, P., Levy, C., Plancher, C., Vincent-Salomon, A., Brousse, N., de Cremoux, P., Hermine, O. & Decaudin, D. (2007) Hepatitis C virus infection and MALT-type ocular adnexal lymphoma. Ann Oncol, 18, 400-401; author reply 401-403.
58. Ferreri, A.J., Viale, E., Guidoboni, M., Resti, A.G., De Conciliis, C., Politi, L., Lettini, A.A., Sacchetti, F., Dolcetti, R., Doglioni, C. & Ponzoni, M. (2006) Clinical implications of hepatitis C virus infection in MALT-type lymphoma of the ocular adnexa. Ann Oncol, 17, 769-772.
59. Paulli, M., Arcaini, L., Lucioni, M., Boveri, E., Capello, D., Passamonti, F., Merli, M., Rattotti, S., Rossi, D., Riboni, R., Berti, E., Magrini, U., Bruno, R., Gaidano, G. & Lazzarino, M. (2009) Subcutaneous 'lipoma-like' B-cell lymphoma associated with HCV infection: a new presentation of primary extranodal marginal zone B-cell lymphoma of MALT. Ann Oncol.
60. Besson, C., Canioni, D., Lepage, E., Pol, S., Morel, P., Lederlin, P., Van Hoof, A., Tilly, H., Gaulard, P., Coiffier, B., Gisselbrecht, C., Brousse, N., Reyes, F. & Hermine, O. (2006) Characteristics and outcome of diffuse large B-cell lymphoma in hepatitis C virus-positive patients in LNH 93 and LNH 98 Groupe d'Etude des Lymphomes de l'Adulte programs. J Clin Oncol, 24, 953-960.
61. Merli, M., Visco, C., Spina, M., Luminari, S., Ferretti, V.V., Gotti, M., Rattotti, S., Fiaccadori, V., Rusconi, C., Targhetta, C., Stelitano, C., Levis, A., Ambrosetti, A., Rossi, D., Rigacci, L., D'Arco, A.M., Musto, P., Chiappella, A., Baldini, L., Bonfichi, M. & Arcaini, L. (2014) Outcome prediction of diffuse large B-cell lymphomas associated with hepatitis C virus infection: a study on behalf of the Fondazione Italiana Linfomi. Haematologica, 99, 489-496.
62. Michot, J.M., Canioni, D., Driss, H., Alric, L., Cacoub, P., Suarez, F., Sibon, D., Thieblemont, C., Dupuis, J., Terrier, B., Feray, C., Tilly, H., Pol, S., Leblond, V., Settegrana, C., Rabiega, P., Barthe, Y., Hendel-Chavez, H., Nguyen-Khac, F., Merle-Beral, H., Berger, F., Molina, T., Charlotte, F., Carrat, F., Davi, F., Hermine, O., Besson, C. & Group, A.H.-L.-C.S. (2015) Antiviral therapy is associated with a better survival in

iris-AperTO

University of Turin's Institutional Research Information System and Open Access Institutional Repository

patients with hepatitis C virus and B-cell non-Hodgkin lymphomas, ANRS HC-13 lympho-C study. Am J Hematol, 90, 197-203.
63. Visco, C., Arcaini, L., Brusamolino, E., Burcheri, S., Ambrosetti, A., Merli, M., Bonoldi, E., Chilosi, M., Viglio, A., Lazzarino, M., Pizzolo, G. & Rodeghiero, F. (2006) Distinctive natural history in hepatitis C virus positive diffuse large B-cell lymphoma: analysis of 156 patients from northern Italy. Ann Oncol, 17, 1434-1440.
64. Roccatello D, Fornasieri A, Giachino O, et al. Multicenter study on HCV-related cryoglobulinemic glomerulonephritis. Am J Kidney Dis. 2007;49:69-82
65. Caussin-Schwemling C, Schmitt C, Stoll-Keller F. Study of the infection of human blood derived monocyte/macrophages with hepatitis C virus in vitro. J Med Virol. 2001;65:14–22.
66. Ito M, Murakami K, Suzuki T, et al. Enhanced expression of lymphomagenesis-related genes in peripheral blood B cells of chronic hepatitis C patients. Clin Immunol. 2010;135:459–65.
67. Muramatsu M, Kinoshita K, Fagarasan S, Yamada S, Shinkai Y, Honjo T. Class switch recombination and hypermutation required activation-induced cytidine deaminase, a potential RNA editing enzyme. Cell. 2000;102:553–63.
68. Roccatello D, Morsica G, Picciotto G, et al. Impaired hepatosplenic elimination of circulating cryoglobulins in patients with essential mixed cryoglobulinemia and hepatitis C virus (HCV) infection. Clin Exp Immunol. 1997;110:9–14.
69. Roccatello D, Isidoro C, Mazzucco G, et al. Role of monocytes in cryoglobulinemia-associated nephritis. Kidney Int. 1993;43:1150–5.
70. Guo S, Wietecha TA, Hudkins KL, Kida Y, Spencer MW,Pichaiwong W, Kojima I, Duffield J, Alpers CE. Macrophages areessential contributors to kidney injury in murine cryoglobulinemic membranoproliferative glomerulonephritis. Kidney Int. 2011; 80: 946–58.
71. Roccatello, A Pani. Cryoglobulinemias in Core Concepts in Parenchimal Kidney Diseases, F Fervenza Ed, SpringerSciences New York, 2014
72. Antonelli A, Ferri C, Pampana A, Fallahi P, Nesti C, Pasquini M, Marchi S, Ferrannini E. Thyroid disorders in chronic hepatitis C. Am J Med. 2004;117(1):10-3.
73. Antonelli A, Ferri C, Fallahi P. Hepatitis C: thyroid dysfunction in patients with hepatitis C on IFN-alpha therapy. Nat Rev Gastroenterol Hepatol. 2009;6(11):633-5.
74. Antonelli A, Ferri C, Fallahi P, Ferrari SM, Frascerra S, Sebastiani M, Franzoni F, Galetta F, Ferrannini E. High values of CXCL10 serum levels in patients with hepatitis C associated mixed cryoglobulinemia in presence or absence of autoimmune thyroiditis. Cytokine. 2008;42(1):137-43.
75. Fallahi P, Ferrari SM, Ruffilli I, Elia G, Giuggioli D, Colaci M, Ferri C, Antonelli A. Incidence of thyroid disorders in mixed cryoglobulinemia: Results from a longitudinal follow-up. Autoimmun Rev. 2016 Mar 9. doi: 10.1016/j.autrev.2016.03.012.
76. Antonelli A, Ferri C, Fallahi P, Nesti C, Zignego AL, Maccheroni M. Thyroid cancer in HCV-related mixed cryoglobulinemia patients. Clin Exp Rheumatol. 2002;20(5):693-6.
77. Fallahi P, Ferrari SM, Politti U, Giuggioli D, Ferri C, Antonelli A. Autoimmune and neoplastic thyroid diseases associated with hepatitis C chronic infection. Int J Endocrinol. 2014;2014:935131.
78. Mason AL, Lau JY, Hoang N, Qian K, Alexander GJ, Xu L, Guo L, Jacob S, Regenstein FG, Zimmerman R, Everhart JE, Wasserfall C, Maclaren NK, Perrillo RP. Association of diabetes mellitus and chronic hepatitis C virus infection. Hepatology. 1999; 29: 328-33

iris-AperTO

University of Turin's Institutional Research Information System and Open Access Institutional Repository

79. Weinman SA, Belalcazar LM. Hepatitis C: a metabolic liver disease. Gastroenterology. 2004 Mar;126(3):917-9.
80. Bugianesi E, McCullough AJ, Marchesini G. Insulin resistance: a metabolic pathway to chronic liver disease. Hepatology. 2005;42(5):987-1000.
81. Allison ME, Wreghitt T, Palmer CR, Alexander GJ. Evidence for a link between hepatitis C virus infection and diabetes mellitus in a cirrhotic population. J Hepatol. 1994;21:1135-9.
82. Antonelli A, Ferri C, Fallahi P, Sebastiani M, Nesti C, Barani L, Barale R, Ferrannini E. Type 2 diabetes in hepatitis C-related mixed cryoglobulinaemia patients. Rheumatology (Oxford). 2004;43(2):238-40.
83. Antonelli A, Ferri C, Fallahi P, Pampana A, Ferrari SM, Goglia F, Ferrannini E. Hepatitis C virus infection: evidence for an association with type 2 diabetes. Diabetes Care. 2005;28(10):2548-50.
84. Konrad T, Zeuzem S, Vicini P, Toffolo G, Briem D, Lormann J, Herrmann G, Berger A, Kusterer K, Teuber G, Cobelli C, Usadel KH. Evaluation of factors controlling glucose tolerance in patients with HCV infection before and after 4 months therapy with interferon-alpha. Eur J Clin Invest. 2000;30(2):111-21.
85. Chen CL, Yang HI, Yang WS, Liu CJ, Chen PJ, You SL, Wang LY, Sun CA, Lu SN, Chen DS, Chen CJ. Metabolic factors and risk of hepatocellular carcinoma by chronic hepatitis B/C infection: a follow-up study in Taiwan. Gastroenterology. 2008;135:111-21.
86. Ferri C, Cutolo M, Zignego AL, Longombardo G, Sulli A, Cavallaro D, Giusti M, Accardo S, Mazzocca A, Pasero G. Role of androgens in HCV-related mixed cryoglobulinemia. Arthritis Rheum 1998; 41: 539A
87. Malaguarnera M, Vicari E, Calogero A, Cammalleri L, Di Fazio I, Gargante MP, Pennisi G, Risino C, Ranno S, Rampello L. Sexual dysfunction in chronic hepatitis C virus patients treated with interferon alpha and ribavirin. J Interferon Cytokine Res. 2008; 28: 603-9
88. Fusco F, D'Anzeo G, Rossi A, Sciorio C, Buonomo AR, d'Emmanuele di Villa Bianca R, Borgia G, Mirone V, Gentile I. Erectile dysfunction in patients with chronic viral hepatitis: a systematic review of the literature. Expert Opin Pharmacother. 2013; 14: 2533-44
89. Ferri C, Bertozzi MA, Zignego AL. Erectile dysfunction and hepatitis C virus infection. JAMA. 2002;288(6):698-9.
90. Crook ED, Penumalee S, Gavini B, Filippova K. Hepatitis C Is a Predictor of Poorer Renal Survival in Diabetic Patients. Diabetes Care. 2005;28(9):2187-91.
91. Ferri C, La Civita L, Cirafisi C, Siciliano G, Longombardo G, Bombardieri S, Rossi B. Peripheral neuropathy in mixed cryoglobulinemia: clinical and electrophysiologic investigations. J Rheumatol. 1992 Jun;19(6):889-95
92. Cacoub P, Saadoun D, Limal N, Léger JM, Maisonobe T. Hepatitis C virus infection and mixed cryoglobulinaemia vasculitis: a review of neurological complications. AIDS. 2005; 19: S128-34.
93. Mathew S, Faheem M, Ibrahim SM, Iqbal W, Rauff B et al. Hepatitis C virus and neurological damage. World J Hepatol, 2016
94. Adinolfi LE, Nevola R, Lus G, Restivo L, Guerrera B, Romano C, Zampino R, Rinaldi L, Sellitto A, Giordano M, Marrone A. Chronic hepatitis C virus infection and neurological and psychiatric disorders: an overview. World J Gastroenterol. 2015 Feb 28;21(8):2269-80

iris-AperTO

University of Turin's Institutional Research Information System and Open Access Institutional Repository

95. Monaco S, Mariotto S, Ferrari S, Calabrese M, Zanusso G, Gajofatto A, Sansonno D, Dammacco F. Hepatitis C virus-associated neurocognitive and neuropsychiatric disorders: Advances in 2015. World J Gastroenterol. 2015 Nov 14;21(42):11974-83.
96. Lidove O, Cacoub P, Maisonobe T, Servan J, Thibault V, Piette JC, Léger JM. Hepatitis C virus infection with peripheral neuropathy is not always associated with cryoglobulinaemia. Ann Rheum Dis. 2001 Mar;60(3):290-2.
97. Casato M, Saadoun D, Marchetti A, Limal N, Picq C, Pantano P, Galanaud D, Cianci R, Duhaut P, Piette JC, Fiorilli M, Cacoub P. Central nervous system involvement in hepatitis C virus cryoglobulinemia vasculitis: a multicenter case-control study using magnetic resonance imaging and neuropsychological tests. J Rheumatol. 2005 Mar;32(3):484-8.
98. Ito H, Ito H, Nagano M, Nakano S, Shigeyoshi Y, Kusaka H. In situ identification of hepatitis C virus RNA in muscle. Neurology 2005; 64: 1073-5.
99. Saadoun D, Bieche I, Authier FJ, Laurendeau I, Jambou F, Piette JC, Vidaud M, Maisonobe T, Cacoub P. Role of matrix metalloproteinases, proinflammatory cytokines, and oxidative stress-derived molecules in hepatitis C virus-associated mixed cryoglobulinemia vasculitis neuropathy. Arthritis Rheum. 2007 Apr;56(4):1315-24.
100. Alpa M, Ferrero B, Cavallo R, Naretto C, Menegatti E, Di Simone D, Napoli F, La Grotta R, Rossi D, Baldovino S, Sena LM, Roccatello D. Anti-neuronal antibodies in patients with HCV-related mixed cryoglobulinemia. Autoimmun Rev.2008 Oct;8(1):56-8.
101. Lucaciu LA, Dumitrascu DL. Depression and suicide ideation in chronic hepatitis C patients untreated and treated with interferon: prevalence, prevention, and treatment. Ann Gastroenterol. 2015 Oct-Dec;28(4):440-7.
102. Boonyapisit K, Katirji B. Severe exacerbation of hepatitis C-associated vasculitic neuropathy following treatment with interferon alpha: a case report and literature review. Muscle Nerve. 2002; 25: 909-13.
103. Fattovich G, Giustina G, Favarato S, Ruol A. A survey of adverse events in 11,241 patients with chronic viral hepatitis treated with alfa interferon. J Hepatol 1996; 24: 38-47.
104. Herrmann DN, McDermott MP, Henderson D, Chen L, Akowuah K, Schifitto G; North East AIDS Dementia (NEAD) Consortium. Epidermal nerve fiber density, axonal swellings and QST as predictors of HIV distal sensory neuropathy. Muscle Nerve. 2004;29:420-7
105. Gemignani F, Brindani F, Alfieri S, Giuberti T, Allegri I, Ferrari C, Marbini A. Clinical spectrum of cryoglobulinaemic neuropathy. J Neurol Neurosurg Psychiatry. 2005; 76: 1410-4
106. Abdel Razek AA, Alvarez H, Bagg S, Refaat S, Castillo M. Imaging spectrum of CNS vasculitis. Radiographics. 2014 Jul-Aug;34(4):873-94
107. Küker W. Cerebral vasculitis: imaging signs revisited. Neuroradiology. 2007; 49: 471-9
108. Heeren M, Sojref F, Schuppner R, Worthmann H, Pflugrad H, Tryc AB, Pasedag T, Weissenborn K. Active at night, sleepy all day--sleep disturbances in patients with hepatitis C virus infection. J Hepatol. 2014 Apr;60(4):732-40
109. Chaudhary M, Sharma M. Management of Psychological Effects through Counselling During HCV (Hepatitis) Treatment. Int J Indian Psychol 2016; 3: 106-12
110. Ishizaka N, Ishizaka Y, Takahashi E, Tooda E, Hashimoto H, Nagai R, Yamakado M. Association between hepatitis C virus seropositivity, carotid-artery plaque, and intima-media thickening. Lancet; 2002; 359: 133-5.

iris-AperTO

University of Turin's Institutional Research Information System and Open Access Institutional Repository

111. Adinolfi LE, Zampino R, Restivo L, Lonardo A, Guerrera B, Marrone A, Nascimbeni F, Florio A, Loria P. Chronic hepatitis C virus infection and atherosclerosis: clinical impact and mechanisms. World J Gastroenterol. 2014 Apr 7;20(13):3410-7
112. Terrier B, Karras A, Cluzel P, Collet JP, Sène D, Saadoun D, Cacoub P. Presentation and prognosis of cardiac involvement in hepatitis C virus-related vasculitis. Am J Cardiol. 2013 Jan 15;111(2):265-72
113. Guiltinan AM, Kaidarova Z, Custer B, Orland J, Strollo A, Cyrus S, Busch MP, Murphy EL. Increased all-cause, liver, and cardiac mortality among hepatitis C virus-seropositive blood donors. Am J Epidemiol. 2008 Mar 15;167(6):743-50.
114. El-Kamary SS, Jhaveri R, Shardell MD. All-cause, liver-related, and non-liver-related mortality among HCV-infected individuals in the general US population. Clin Infect Dis. 2011 Jul 15;53(2):150-7
115. Bartoloni E, Shoenfeld Y, Gerli R. Inflammatory and autoimmune mechanisms in the induction of atherosclerotic damage in systemic rheumatic diseases: two faces of the same coin. Arthritis Care Res. 2011 Feb;63(2):178-83. doi: 10.1002/acr.20322.
116. Campbell LA, Rosenfeld ME. Infection and Atherosclerosis Development. Arch Med Res. 2015 Jul;46(5):339-50
117. Zampino R, Marrone A, Restivo L, Guerrera B, Sellitto A, Rinaldi L, Romano C, Adinolfi LE. Chronic HCV infection and inflammation: Clinical impact on hepatic and extra-hepatic manifestations. World J Hepatol. 2013 Oct 27;5(10):528-40
118. Boddi M, Abbate R, Chellini B, Giusti B, Giannini C, Pratesi G, Rossi L, Pratesi C, Gensini GF, Paperetti L, Zignego AL. Hepatitis C virus RNA localization in human carotid plaques. J Clin Virol. 2010 Jan;47(1):72-5
119. Garcovich S, Garcovich M, Capizzi R, Gasbarrini A, Zocco MA. Cutaneous manifestations of hepatitis C in the era of new antiviral agents. World J Hepatol. 2015 Nov 28;7(27):2740-8
120. Imafuku S, Naito R, Nakayama J. Possible association of hepatitis C virus infection with late-onset psoriasis: a hospital-based observational study. J Dermatol. 2013 Oct;40(10):813-8.
121. Kanada KN, Schupp CW, Armstrong AW. Association between psoriasis and viral infections in the United States: focusing on hepatitis B, hepatitis C and human immunodeficiency virus. J Eur Acad Dermatol Venereol. 2013 Oct;27(10):1312-6.
122. Wilson SE, Lee WM, Murakami C, Weng J, Moninger GA. Mooren-type hepatitis C virus-associated corneal ulceration. Ophthalmology. 1994 Apr;101(4):736-45.
123. Aliannejad R, Ghanei M. Hepatitis C and pulmonary fibrosis: Hepatitis C and pulmonary fibrosis. Hepat Mon. 2011 Feb;11(2):71-3
124. Saadoun D, Terrier B, Semoun O, Sene D, Maisonobe T, Musset L, Amoura Z, Rigon MR, Cacoub P. Hepatitis C virus-associated polyarteritis nodosa. Arthritis Care Res (Hoboken). 2011 Mar;63(3):427-35
125. Ferri C, Longombardo G, La Civita L, Greco F, Lombardini F, Cecchetti R, Cagianelli MA, Marchi S, Monti M, Zignego AL, Manns MP. Hepatitis C virus chronic infection as a common cause of mixed cryoglobulinaemia and autoimmune liver disease. J Intern Med. 1994; 236: 31-6
126. Kozanoglu E, Canataroglu A, Abayli B, Colakoglu S, Goncu K. Fibromyalgia syndrome in patients with hepatitis C infection. Rheumatol Int 2003; 23: 248-51.
127. Narvaez J, Nolla JM, Valverde-Garciala J. Lack of association of fibromyalgia with hepatitis C virus infection. J Rheumatol 2005; 32: 1118-21.

128. Fiore G, Giacovazzo F, Giacovazzo M. HCV and dermatomyositis: report of 5 cases of dermatomyositis in patients with HCV infection. Riv Eur Sci Med Farmacol. 1996; 18: 197-201.
129. Ferri C, Manfredi A, Sebastiani M, Colaci M, Giuggioli D, Vacchi C, Della Casa G, Cerri S, Torricelli P, Luppi F. Interstitial pneumonia with autoimmune features and undifferentiated connective tissue disease: Our interdisciplinary rheumatology-pneumology experience, and review of the literature. Autoimmun Rev. 2016; 15: 61-70
130. Zignego AL, Macchia D, Monti M, Thiers V, Mazzetti M, Foschi M, Maggi E, Romagnani S, Gentilini P, Bréchot C. Infection of peripheral mononuclear blood cells by hepatitis C virus. J Hepatol. 1992 Jul;15(3):382-6
131. Ferri C, Monti M, La Civita L, Longombardo G, Greco F, Pasero G, Gentilini P, Bombardieri S, Zignego AL. Infection of peripheral blood mononuclear cells by hepatitis C virus in mixed cryoglobulinemia. Blood. 1993; 82: 3701-4.
132. González-Grande R, Jiménez-Pérez M, González Arjona C, Mostazo Torres J. New approaches in the treatment of hepatitis C. World J Gastroenterol. 2016 Jan 28;22(4):1421-32
133. Zopf S, Kremer AE, Neurath MF, Siebler J. Advances in hepatitis C therapy: What is the current state - what come's next? World J Hepatol. 2016 Jan 28;8(3):139-47

Legend to the Figures

Fig. 1. Various HCV-EHDs can be classified according to the strength of the association evaluated on the basis of epidemiological, clinico-pathological, virological, and laboratory investigations. This subsetting is quite definite with regards the first 2 groups, while other associations are waiting for a right qualification.

1: HCV represents the main etiological agent as concordantly demonstrated by all the above investigations;

2: the association between HCV and disease is demonstrated in a significant proportion of patients compared to general population (often with heterogeneous geographical distribution), its potential role is supported by in depth clinico-pathogenetic studies;

iris-AperTO

University of Turin's Institutional Research Information System and Open Access Institutional Repository

3: a role of HCV infection has been suggested by cohort studies; a possible causative role may be limited to a small number of patients and/or possibly more relevant in specific geographical areas;

4: a number of anecdotal observations suggested a possible role of HCV; further investigations are required.

B-cell NHL: B-cell non-Hodgkin's lymphomas; PCT: porphyria cutanea tarda; SS: typical features of Sjögren's syndrome; PM/DM: polymyositis / dermatomyositis: PAN: panarteritis nodosa

Fig. 2. The Network of HCV-related Disorders

The figure is a schematic representation of the network of HCV-related disorders, which encompasses both hepatic and extrahepatic diseases (HCV-EHDs).
Liver involvement represents the most common clinical manifestation of chronic HCV infection, while HCV-EHDs may develop in a minority of patients.
HCV-EHDs may appear either as organ-specific disorders, i.e. arthritis, neuropathy, glomerulonephritis, etc.) or as systemic autoimmune disorder such as mixed cryoglobulinemia syndrome (MCs). Isolated and totally asymptomatic serum cryoglobulins are generally detectable in over 50% of HCV infected individuals, while classical MCs can be diagnosed in a small percentage of patients on the basis of both serological (circulating mixed cryoglobulins) and typical clinic-pathological features (see text).
In the clinical practice we can observe a variable combination of hepatic and HCV-EHDs among HCV-infected patients, as well as in the same patient during the long-term follow-up. The most harmful complications of chronic HCV infection may appear abruptly (sensory-motor peripheral neuropathy, glomerulonephritis, widespread vasculitis, etc.) or more often as late manifestations (malignancies), alone or in the setting of MCs.

B-NHL: B-cell non-Hodgkin's lymphomas; HCC: hepatocellular carcinoma

Fig. 3. Clinical assessment of HCV-infected individuals

The figure shows the diagnostic steps for a correct diagnostic assessment of HCV-related extrahepatic disorders (HCV-EHDs). At the first assessment all patients with chronic HCV infection should be investigated for possible hepatic and/or HCV-EHDs through a first-line investigations in order to detect signs and symptoms, anamnestic/present, by means of standardized questionnaire, physical examination, and a core set of laboratory/instrumental procedures (see also Tab. 1). Individuals with symptoms suggestive of possible HCV-EHDs will be deeply evaluated by means of targeted investigations that may define different HCV-EHDs (see text). In all cases, the presence of underlying disorders potentially responsible for HCV-EHDs should be excluded, mainly

iris-AperTO

University of Turin's Institutional Research Information System and Open Access Institutional Repository

other infectious agents (HBV, HIV, etc.) or neoplastic diseases.

HCC: hepatocellular carcinoma; MCs: mixed cryoglobulienmia syndrome; SS: sicca syndrome (in few cases typical features of Sjögren's syndrome); PCT: porphyria cutanea tarda; B-NHL: B-cell non-Hodgkin's lymphomas; °Others: see Fig. 1.

Fig. 4. General clinical assessment of HCV-EHDs

The figure shows in detail the diagnostic guidelines with first- and second-line investigations to detect single HCV-related extrahepatic disorders (HCV-EHDs) (see also text, Tab. 1, and Fig. 3).

FNA: fine-needle aspiration of thyroid nodules
Doppler-US: transcranial color-Doppler ultrasonography; MRI: magnetic resonance imaging CT: computed tomography angiography; PET: positron emission tomography; RF: rheumatoid factor; anti-CCP: anti-cyclic citrullinated peptide antibodies; ANA: anti-nuclear antibodies; ENA: anti-nuclear extractable antigen antibodies; URO-D: uroporphyrinogen decarboxylase; GN: glomerulonephritis (diffuse membranoproliferative glomerulonephritis in about 80 % of case).

Appendix to revise and complete

ISG-EHCV coauthors:

Prof. Milvia Casato, ……..
Prof. Peter Lamprecht, …….

iris-AperTO

University of Turin's Institutional Research Information System and Open Access Institutional Repository

Prof. Alessandra Mangia, …….
Prof. Athanasios Tzioufas, ……
Dr. Anne Claire Desbois, Research fellow, Université Pierre et Marie Curie, Paris
Dr. Cloe Commarmond, Research fellow, Université Pierre et Marie Curie, Paris
Prof Oliver Hermine, Hematologist, Université Paris Descartes, Paris
Dr. Pilar Brito-Zeón, Research Fellow, Hospital Clinic, Barcelona
Prof. Xavier Forns, Hepatologist, Hospital Clinic, Barcelona
Prof. Armando Lopez-Guillermo, Hematologist, Hospital Clinic, Barcelona
Dr. Laura Gragnani, Research fellow, Interdepartmental Center for Systemic Manifestations of Hepatitis Viruses (MaSVE), Department of Experimental and Clinical Medicine, University of Florence, Florence, Italy
Prof Alberto Bosi, Hematologist, University of Florence
Dr. Teresa Urraro, Rheumatologist, University of Florence
Dr. Marcella Visentini, Research fellow, Sapienza University of Rome
Dr. Alessandro Pulsoni, Hematologist, Sapienza University of Rome
Dr. Adriano De Santis, Hepatologist, Sapienza University of Rome
Dr. Theodoros Androutsakos, Research fellow, University of Athens
Prof. Gregory Hatzis, Hepatologist, University of Athens
Dr. Anja Kerstein, Research fellow, Klinik für Rheumatologie, Oberarzt, Lübeck
Dr. Susanne Schinke, Rheumatologist, Klinik für Rheumatologie, Oberarzt, Lübeck
Dr. Sandra Muñoz, Rheumatologist, Centro Médico Nacional 20 de Noviembre, ISSSTE, México DF
Dr. Francisco Medina, Rheumatologist, Hospital de Especialidades, Centro Médico Nacional Siglo XXI, Mexico DF
Dr. Luis-Javier Jara, Rheumatologist, Centro Médico Nacional La Raza, Mexico DF
Dr. Mario García-Carrasco, Rheumatologist, Systemic Autoimmune Diseases Research Unit, IMSS, Puebla, México Department of Rheumatology and Immunology, Benemérita Universidad Autónoma de Puebla, Puebla, México
Prof. Munther Khamashta, Internist & Rheumatologist, Dubai Hospital, Dubai, United Arab Emirates
Prof. Yehuda Shoenfeld, Head Zabludowicz Center for Autoimmune Diseases, Sheba Medical Center, Tel-Hashomer, Israel
Prof. John H. Stone, Harvard Medical School, Boston, MA, US
Dr. Soledad Retamozo, Hospital Privado, Centro Médico de Córdoba, Córdoba, Argentina
Prof. Chien-Jen Chen, National Taiwan University, Nankang, Taipei 11529, Taiwan
Prof. Margit Zeher, University of Debrecen, Debrecen, Hungary
Prof. Elke Theander and Thomas Mandl, Skåne University Hospital, Malmö, Sweden
Pr. Gaafar Ragab, MD • Internal Medicine • Faculty of Medicine, Cairo University Department of Internal Medicine Clinical Immunology and Rheumatology Unit Internal Medicine Hospital Kasr Al-Ainy, 8 Kasr Al-Ainy st., Cairo, P.O. 11562 • Tel: +201005190006 • Fax: +20 233380345 • Mailing address: P.O. Box: 152 Orman, Giza, Egypt, 12612 • E-mail:
Dr. Alexandre Da Sousa, rheumatologist, Rua Loefgren, 1587. Apt 82. Vila Clementino. Sao Paulo 04040-032, Brazil
Dr. Dilia Giuggioli, MD Chair and Rheumatology Unit, Medical School, University of Modena and Reggio Emilia, Azienda Ospedaliero- Universitaria, Policlinico di Modena, 41124 Modena, Italy Dr: Michele Colaci, MD Chair and Rheumatology Unit, Medical School, University of Modena and Reggio Emilia, Azienda Ospedaliero- Universitaria, Policlinico di Modena, 41124 Modena, Italy
Dr. Poupak Fallahi: Department of Clinical and Experimental Medicine, University of Pisa, Via Savi 10, Pisa 56126, Italy.
Dr. Silvia Martina Ferrari: Department of Clinical and Experimental Medicine, University of Pisa, Via Savi 10, Pisa 56126, Italy.

iris-AperTO

University of Turin's Institutional Research Information System and Open Access Institutional Repository

Tab. 1. HCV-infected individuals: detection of extra-hepatic manifestations

Signs and symptoms (anamnestic/present)		First line laboratory investigations
Constitutional	Weakness Fever Weight loss Myalgias, fibromyalgia	Liver function tests Routine blood chemistry Virological tests ESR, CRP RF Cryoglobulinemia Complement C3/C4 Serum immunofixation ANA, anti-ENA TSH Urinalysis Abdominal/thyroid ultrasonography EKG Chest x-ray
Skin inv.	Orthostatic purpura Necrotizing vasculitis Skin ulcers bullae/hyperpigmentation/ erosions at sun-exposed areas	
Articular inv.	Arthralgias Arthritis	
Salivary gland inv.	sicca syndrome	
Renal inv.	Edema	
Vascular inv.	Hypertentension Raynaud's phenomenon Hyperviscosity syndrome	
Heart/lung inv.	Dyspnea, edema, hemoptoe pleural/pericardial effusion claudication, heart failure	
Neurological inv.	Peripheral neuropathy Cranial nerve involvement CNS involvement*	
Hematolocical inv.	Adenopathy Splenomegaly Cytopenias Lymphocytosis Monoclonal component Systemic symptoms	
Endocrine inv.	hypothyroidism Diabetes type 2 Erectile dysfunction	

iris-AperTO

University of Turin's Institutional Research Information System and Open Access Institutional Repository

ESR: erythrocyte sedimentation rate; CRP: C reactive protein; RF: rheumatoid factor; ANA: anti-nuclear antibodies; anti-ENA: antibodies anti-extractable nuclear antigens; TSH: thyroid-stimulating hormone; EKG: electrocardiogram

Tab. 2. Differential diagnosis between some HCV-EHDs and idiopathic rheumatic diseases

	Mixed cryogl. HCV+	Sicca syndrome HCV+	pSjögren's syndrome	Arthritis HCV+	Rheumatoid arthritis
Symptoms					
Purpura	+++	+/-	+/-	+/-	+/-
Weakness	+++	+	+	+	+/-
Arthralgias	+++	+/-	+/-	+++	+++
Oligoarthritis	+	+	+	+	+
Polyarthritis	+/-	+/-	+	+	+++
Erosive arthritis	-	-	+/-	+/-	+++
sicca syndrome	+	+++	+++	+/-	+/-
Renal inv.	++	+/-	+	+/-	+/-
Peripheral neuropathy	++	+/-	+	+/-	+/-
B-NHL	+	+/-	+	+/-	+/-
Laboratory alterations					
Mixed cryoglobulins	+++	+/-	+	+/-	+/-
Low complement C4	+++	+/-	-	+/-	-
RF	+++	+/-	+++	+/-	++
anti-CCP Ab	-	-	-	-	++
ANA	+/-	+/-	+++	+/-	+/-
anti-SSA/SSB Ab	+/-	+/-	+++	-	-
Salivary gland biopsy	+/-	+/-	+++	+/-	+/-

Colored areas highlight the parameters useful for differential diagnosis.
B-NHL: B-cell non-Hodgkin's lymphomas; RF: rheumatoid factor; anti-CCP: anti-cyclic citrullinated peptide antibodies; ANA: anti-nuclear antibodies

iris-AperTO

University of Turin's Institutional Research Information System and Open Access Institutional Repository

Ferri et al. Fig. 1

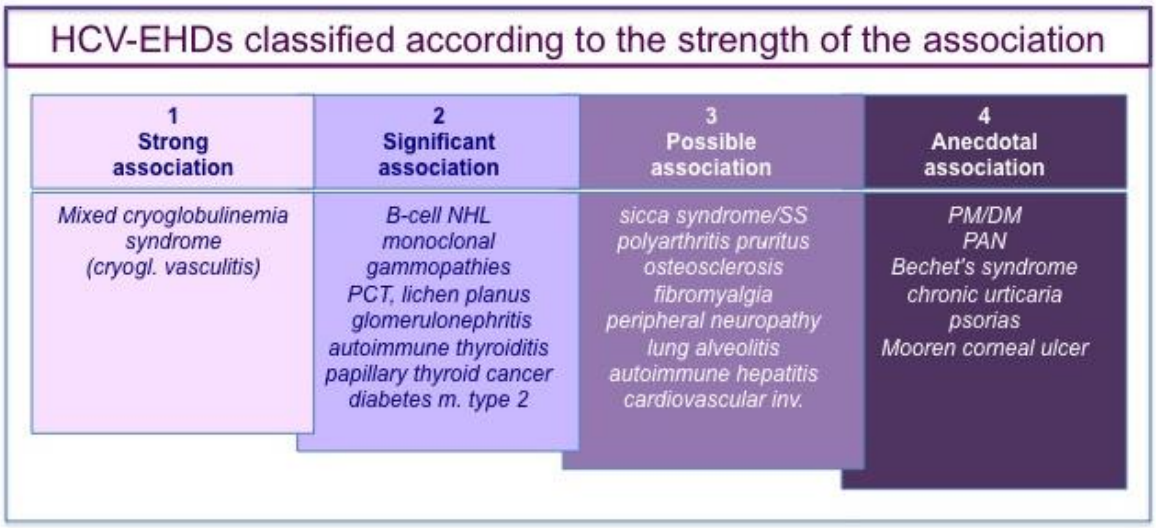

Ferri et al. Fig. 2

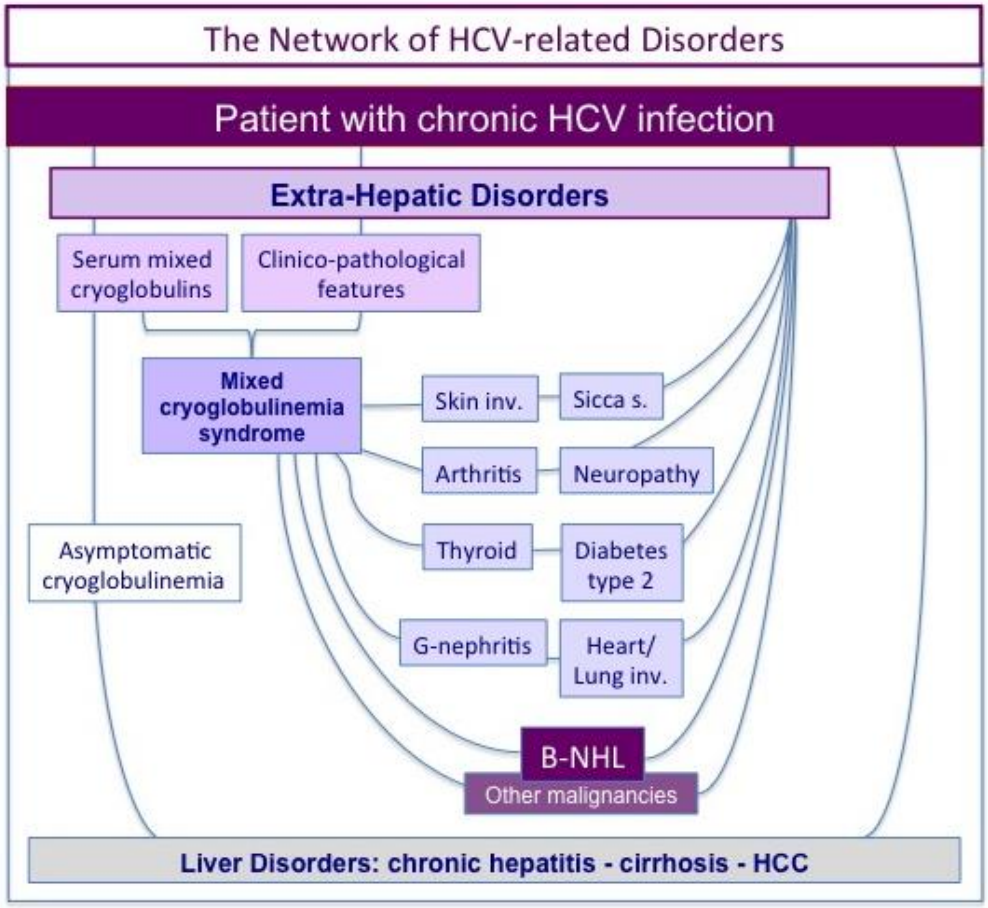

iris-AperTO

University of Turin's Institutional Research Information System and Open Access Institutional Repository

Ferri et al. Fig. 3

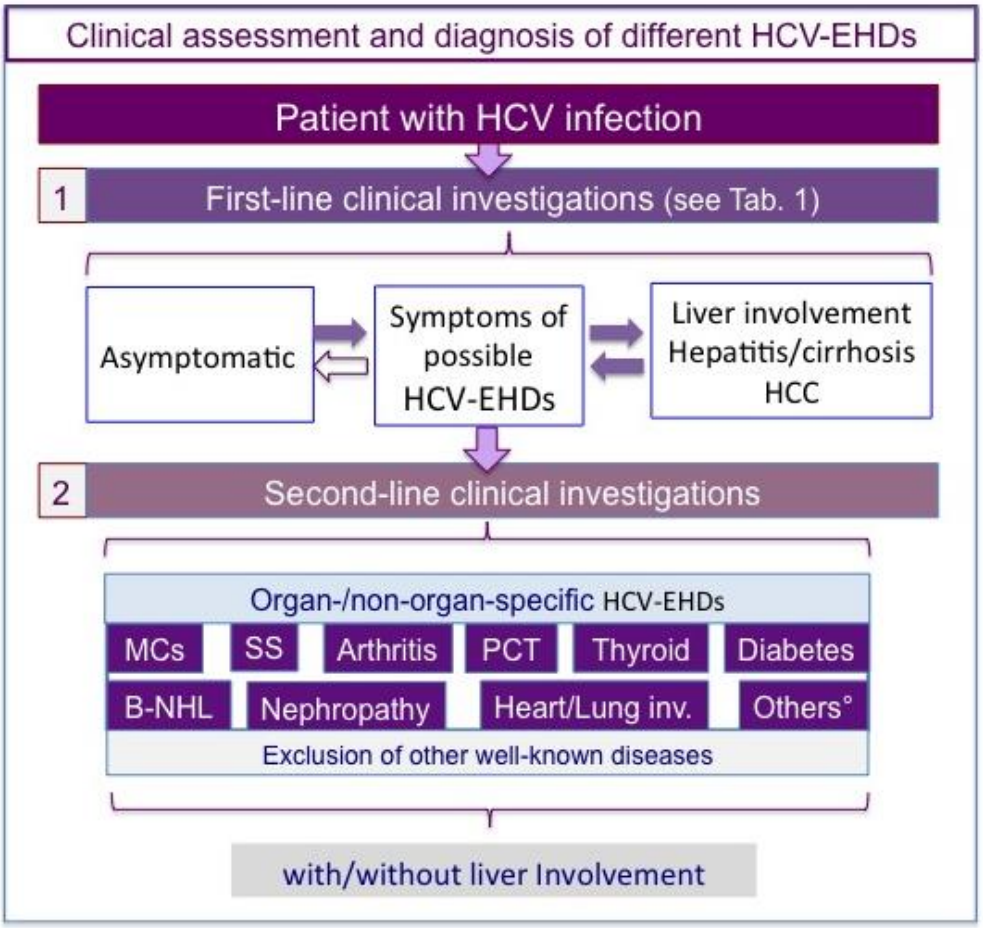

iris-AperTO

University of Turin's Institutional Research Information System and Open Access Institutional Repository

Ferri et al. Fig. 4

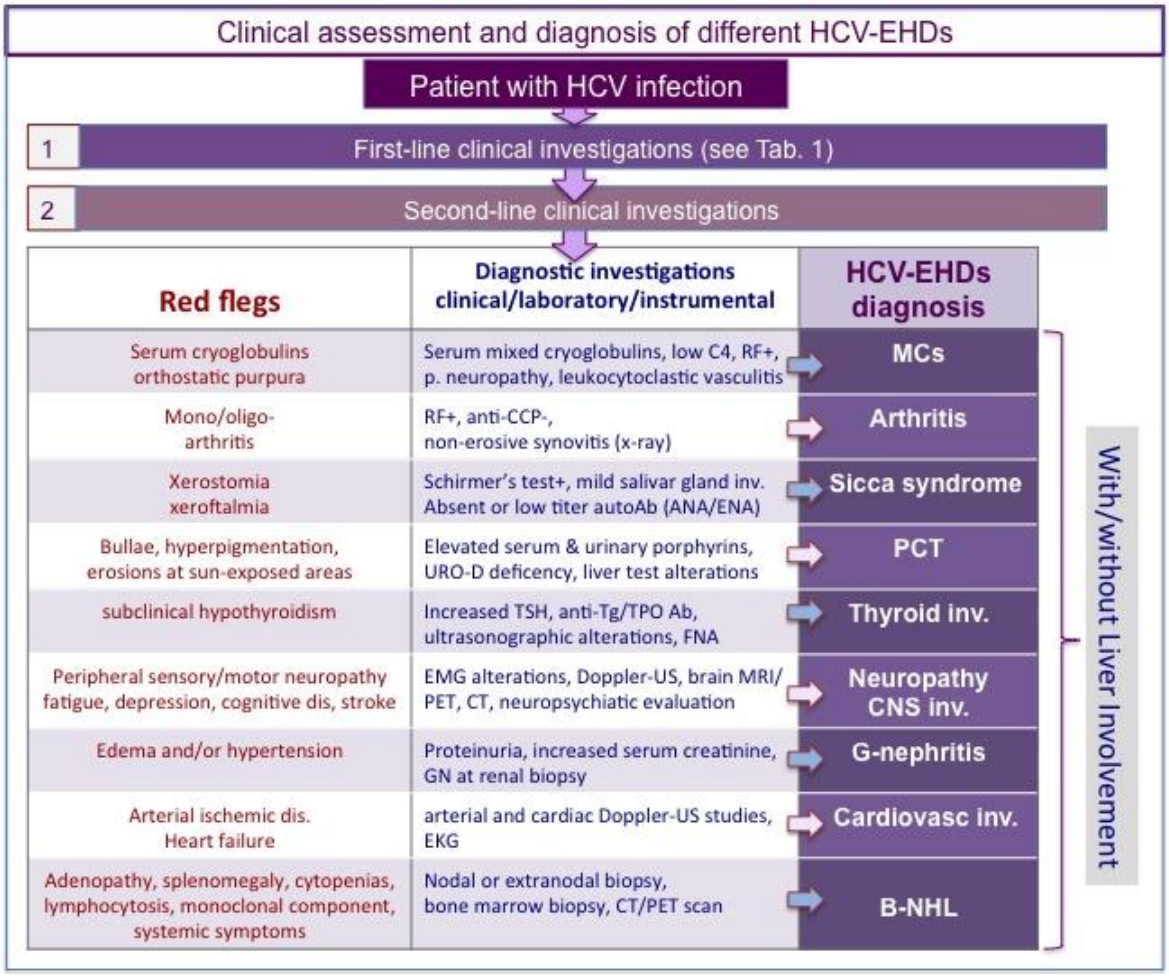

iris-AperTO

University of Turin's Institutional Research Information System and Open Access Institutional Repository