

Bilateral choroidal caverns in a child with pachychoroid and anxious personality

Matteo Pederzoli^{a,b}, Riccardo Sacconi^{a,b}, Marco Battista^{a,b}, Francesco Bandello^{a,b}, Giuseppe Querques^{a,b,*}

^a School of Medicine, Vita-Salute San Raffaele University, Milan, Italy

^b Division of Head and Neck, Ophthalmology Unit, IRCCS San Raffaele Scientific Institute, Milan, Italy

ARTICLE INFO

Keywords:

Choroidal caverns
Pachychoroid
Optical coherence tomography
COVID-19

ABSTRACT

Purpose: To report a case of a 7-year-old male patient with bilateral choroidal caverns (CC) and pachychoroid. **Observations:** During the Italian COVID-19 lockdown, a 7-year old boy presented with bilateral vision decline that had started two weeks before. Structural optical coherence tomography revealed pachychoroid and CC bilaterally. Other ocular examinations were negative. The patient had an apprehensive personality and symptoms quickly resolved when he was provided with non-prescription glasses; his visual disturbances were thus considered to be functional and factitious.

Conclusions and Importance: Our patient's symptoms remind us that the distress imposed upon psychologically frail subjects by the COVID-19 pandemic may have multifaceted manifestations. The discovery of CC in a pediatric patient with healthy eyes presents us with new questions about the processes of degeneration thought to be the cause for CC. Further studies are needed to estimate the prevalence of CC in the general adult and pediatric populations, as well as in patients with chorioretinal diseases.

1. Introduction

Choroidal caverns (CC) are small, well-demarcated, optically void choroidal spaces using structural optical coherence tomography (OCT) initially discovered in patients with geographic atrophy (GA), and later observed in eyes with various chorioretinal diseases and in healthy adults.^{1–9} Even though their content and clinical significance is debated, they are generally believed to be the result of choroidal stroma involution.^{1,2,4,10} Therefore, CC have never been described in healthy children. We hereby report on a case of bilateral CC occurring in a 7-year old boy with pachychoroid.

2. Case report

Towards the end of the 2020 Italian COVID-19 lockdown, a 7-year-old boy came to our clinic for evaluation complaining of a visual acuity decline in both eyes. Symptoms had started two weeks before. He had no previous ocular history, nor history of COVID-19 exposure. His eyes were emmetropic. Since his symptoms appeared concerning, he was admitted to an urgent evaluation following our center's COVID-19

safety protocol.¹²

At presentation, cycloplegic refractive error was +0.25 in the right eye and +0.50 in the left eye. Best-corrected visual acuity (BCVA) was 20/60 in both eyes. Anterior segment examination was unremarkable. Intraocular pressure was 15 mmHg in both eyes. Dilated fundus examination unveiled no pathological feature.

We performed multimodal imaging and functional examinations in order to identify potential causes for vision loss in our patient (Fig. 1). Short-wavelength autofluorescence showed a normal autofluorescence pattern. Structural OCT showed normal retinal profile and thickness in the macular region of both eyes. The choroid of both eyes exceeded normal thickness for our patient's age.¹³ The choroid of both eyes also featured large hyporeflective areas with irregular, shaded hyper-reflective borders, that were consistent with choroidal pachyvessels. Interestingly, other numerous small, well-defined, optically void areas were present, mostly in the Sattler layer; we identified them as CC. OCT angiography (OCTA) unveiled lack of flow signal in such areas, confirming the avascular nature of the lesions.

Computerized perimetry showed scattered absolute and relative visual field defects in both eyes, but these findings were highly unreliable

* Corresponding author. Department of Ophthalmology, University Vita-Salute, IRCCS Ospedale San Raffaele, Via Olgettina 60, Milan, 20132, Italy.

E-mail addresses: giuseppe.querques@hsr.it, querques.giuseppe@hsr.it (G. Querques).

<https://doi.org/10.1016/j.ajoc.2022.101505>

Received 19 October 2021; Received in revised form 15 March 2022; Accepted 20 March 2022

Available online 25 March 2022

2451-9936/© 2022 The Authors. Published by Elsevier Inc. This is an open access article under the CC BY-NC-ND license (<http://creativecommons.org/licenses/by-nc-nd/4.0/>).

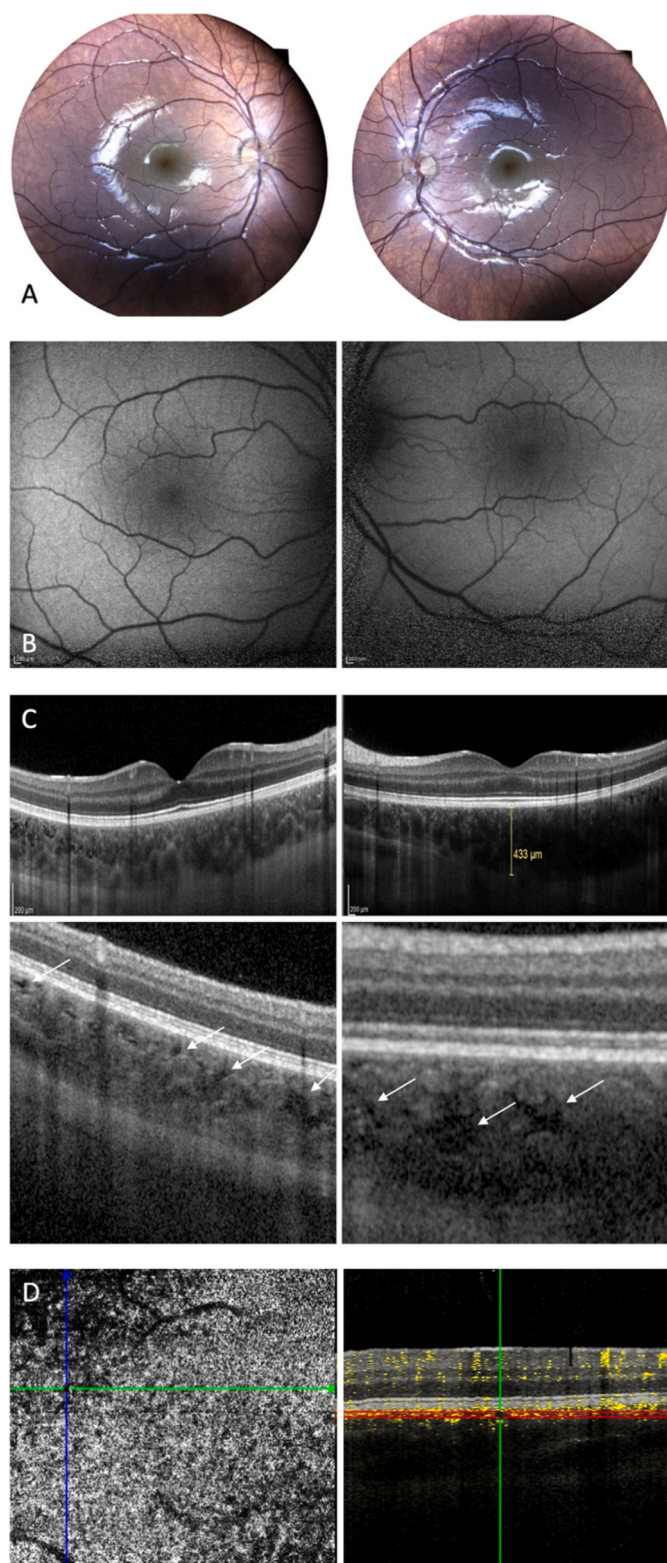


Fig. 1. Multimodal Imaging of both eyes. Eidon TrueColor posterior pole retinography and Heidelberg blue light autofluorescence imaging showed no abnormalities (A, B). Optical coherence tomography unveiled increased choroidal thickness, pachyvessels and numerous choroidal caverns (white arrows) (C). Optical coherence tomography angiography showed lack of flow signal in correspondence of choroidal caverns (D). (For interpretation of the references to colour in this figure legend, the reader is referred to the Web version of this article.)

due to a high number of false negatives and positives. The patient underwent electroretinography, which showed normal scotopic and photopic responses.

The boy's mother reported that he had become quite anxious during lockdown. Since he seemed to express a strong desire for eyeglasses, we advised her to provide him non-prescription glasses. After few days, BCVA was 20/20 in both eyes, leading us to interpret the previous ocular complaints as a functional and factitious defect.

3. Discussion

Choroidal caverns are void polygonal cavities displayed by structural OCT first described in the choroid of patients with geographic atrophy.¹ They have a prevalence of 12.5% among GA patients; they most commonly occur unilaterally in such patients and have mean greatest linear dimensions of $148 \times 84 \mu\text{m}$. Indocyanine green angiography and OCTA confirm absence of blood flow. Since CC were initially observed inside GA areas, it was proposed that they represent areas of involution of nonperfused ghost vessels, with persistence of stromal pillars.¹

Different authors reported the presence of CC in various diseases, and have advanced further hypotheses on the nature of CC. Dolz-Marco et al.² observed that CC tend to present posterior hyperreflective tails, and are also present in eyes with other causes for atrophy, such as neovascular age-related macular degeneration, as well as in healthy eyes. Friedman lipid globules were suggested as a histologic correlate for CC. Although a direct link between CC and Friedman globules was not obtainable, it has been proposed that CC may be storage sites for fatty acids, which may be mobilized to support the metabolic requests of photoreceptors.²

CC were also observed in patients with diseases of the pachychoroid spectrum (such as central serous chorioretinitis, pachychoroid-related neovascularopathies, and pachychoroid pigment epitheliopathy).^{3,5} CC were mostly found in areas of vascular hyperpermeability, where pachyvessels were evident; it was also observed that CC were more numerous in eyes with thicker choroids.³ This has led to the conclusion that CC may be the result of the loss of choroidal stroma in areas of increased choroidal thickness.³

Interestingly, Corvi et al. reported on a unique case of CC occurring in the context of a choroidal nevus in an eye with pachychoroid.⁶

Furthermore, CC have been found in myopic eyes.⁴ These eyes showed increased choroidal thickness compared to length-matched eyes that had no evidence of CC. The choroidal stretching phenomena occurring in myopic eyes, together with a reduction in choroidal vascular density, have been thought to originate CC in these patients.⁴

Eyes affected by retinal dystrophies may occasionally feature CC.² In a case of Best vitelliform dystrophy with CC, Carnevali et al. interpreted the optically void choroidal lesions as the result of Best-related choroidal degeneration.⁷ In addition, CC may occur in specific choroidal patterns of Stargardt disease and Retinitis Pigmentosa, in association with reduction in Sattler and Haller layers thickness.^{8,9}

The main differential diagnoses for CC are other optically void choroidal spaces, such as choroidal clefts, choroidal rifts, choroidal loculations and peripapillary intrachoroidal cavitations.^{14–18}

This is the first case report to our knowledge describing choroidal caverns in an otherwise healthy child, whose eyes presented increased choroidal thickness and pachyvessels. We believe that our patient's visual defect was purely functional in nature. It is interesting to note that our young patient exhibited an anxious personality, which along with pachychoroid may pose him at a higher risk for the development of central serous chorioretinopathy in the future.¹⁹ His case testifies to the psychological implications that the COVID-19 pandemic and lockdown may have had on subjects still in their formative years, and especially on those prone to anxiety.²⁰

The finding of CC in such a young subject leaves us with new interrogatives. Even though the nature of the content of CC is debated, it is generally acknowledged that CC constitute a sign of choroidal

involution. Given the absence of other causes for choroidal stroma damage, we lean towards attributing CC in our patient to the presence of pachychoroid. If that was the case, it would be quite noteworthy that pachychoroid-related CC may occur so precociously.

Because of the observation of CC in this unsuspected patient, we believe that CC may occur more frequently than currently thought, particularly in eyes with undiagnosed predisposing phenomena of distortion, compression and stretching (such as in eyes with myopia, pachychoroid, and atrophic chorioretinal lesions). Our report highlights that CC may even occur in patients whose young age did not allow for longstanding choroidal degeneration.

In conclusion, we believe that further studies are needed to establish the nature of CC, to assess CC distribution among healthy and diseased adult eyes, and to acquire additional data on CC prevalence in children.

Patient consent

The patient provided written informed consent for publication of this case report and any accompanying images.

Funding

No funding or grant support.

Authorship

All authors attest that they meet the current ICMJE criteria for Authorship.

Declaration of competing interest

Riccardo Sacconi: consultant for Bayer Shering-Pharma (Berlin, Germany), Novartis (Basel, Switzerland), Zeiss (Dublin, USA).

Francesco Bandello consultant for: Alcon (Fort Worth, Texas, USA), Alimera Sciences (Alpharetta, Georgia, USA), Allergan Inc (Irvine, California, USA), Farmila-Thea (Clermont-Ferrand, France), Bayer Shering-Pharma (Berlin, Germany), Bausch And Lomb (Rochester, New York, USA), Genentech (San Francisco, California, USA), Hoffmann-La-Roche (Basel, Switzerland), NovagaliPharma (Évry, France), Novartis (Basel, Switzerland), Sanofi-Aventis (Paris, France), Thrombogenics (Heverlee, Belgium), Zeiss (Dublin, USA)

Giuseppe Querques consultant for: Alimera Sciences (Alpharetta, Georgia, USA), Allergan Inc (Irvine, California, USA), Bayer Shering-

Pharma (Berlin, Germany), Heidelberg (Germany), Novartis (Basel, Switzerland), Sandoz (Berlin, Germany), Zeiss (Dublin, USA).

References

1. Querques G, Costanzo E, Miere A, Capuano V, Souied EH. Choroidal caverns: a novel optical coherence tomography finding in geographic atrophy. *Invest Ophthalmol Vis Sci.* 2016;57(6):2578–2582.
2. Dolz-Marco R, Glover JP, Gal-Or O, et al. Choroidal and sub-retinal pigment epithelium caverns: multimodal imaging and correspondence with friedman lipid globules. *Ophthalmology.* 2018;125(8):1287–1301.
3. Sakurada Y, Leong BCS, Parikh R, Fragiotta S, Freund KB. Association between choroidal caverns and choroidal vascular hyperpermeability IN eyes with pachychoroid diseases. *Retina.* 2018;38(10):1977–1983.
4. Sacconi R, Borrelli E, Marchese A, et al. Re: dolz-Marco et al.: choroidal and sub-retinal pigment epithelium caverns: multimodal imaging and correspondence with Friedman lipid globules (Ophthalmology. 2018;125:1287-1301. *Ophthalmology.* 2019;126(7):e53–e54.
5. Ayachit A, Joshi S, Kathyayini SV, Ayachit G. Choroidal caverns in pachychoroid neovascularopathy. *Indian J Ophthalmol.* 2020;68(1).
6. Corvi F, Corradetti G, Wong A, et al. Multimodal imaging of a choroidal nevus with caverns in the setting of pachychoroid disease. *Retin Cases Brief Rep.* February 2021. published online ahead of print.
7. Carnevali A, Sacconi R, Corbelli E, Querques L, Bandello F, Querques G. Choroidal caverns: a previously unreported optical coherence tomography finding in best vitelliform dystrophy. *Ophthalmic Surg Lasers Imaging Retina.* 2018;49(4):284–287.
8. Arrigo A, Grazioli A, Romano F, et al. Choroidal patterns in Stargardt disease: correlations with visual acuity and disease progression. *J Clin Med.* 2019;8(9):1388.
9. Arrigo A, Bordato A, Romano F, et al. Choroidal patterns in retinitis Pigmentosa: correlation with visual acuity and disease progression. *Transl Vis Sci Technol.* 2020;9(4):17.
10. Xia Y, Feng N, Hua R. Choroidal caverns" spectrum lesions. *Eye.* 2021;35(5):1508–1512.
11. Borrelli E, Sacconi R, Querques L, et al. Taking the right measures to control COVID-19 in ophthalmology: the experience of a tertiary eye care referral center in Italy. *Eye.* 2020;34(7):1175–1176.
12. Fontaine M, Gaucher D, Sauer A, Speeg-Schatz C. Choroidal thickness and ametropia in children: a longitudinal study. *Eur J Ophthalmol.* 2017;27(6):730–734.
13. Mukai R, Sato T, Kishi S. A hyporeflective space between hyperreflective materials in pigment epithelial detachment and Bruch's membrane in neovascular age-related macular degeneration. *BMC Ophthalmol.* 2014;14:159.
14. Pece A, Borrelli E, Sacconi R, Maione G, Bandello F, Querques G. Choroidal cleft simulating choroidal caverns in neovascular age-related macular degeneration. *Eur J Ophthalmol.* 2019;29(5):471–473.
15. Battista M, Borrelli E, Veronese C, et al. choroidal rift: a new OCT finding in eyes with central serous chorioretinopathy. *J Clin Med.* 2020;9(7).
16. Spaide RF, Ryan EHJ. Loculation of fluid in the posterior choroid in eyes with central serous chorioretinopathy. *Am J Ophthalmol.* 2015;160(6):1211–1216.
17. Freund KB, Ciardella AP, Yannuzzi LA, et al. Peripapillary detachment in pathologic myopia. *Arch Ophthalmol.* 2003;121(2):197–204.
18. Yannuzzi LA. Type-A behavior and central serous chorioretinopathy. *Retina.* 1987;7(2):111–131.
19. Caffo E, Scandroglio F, Asta L. Debate: COVID-19 and psychological well-being of children and adolescents in Italy. *Child Adolesc Ment Health.* 2020;25(3):167–168.