

Macular Perfusion Parameters in Different Angiocube Sizes: Does The Size Matter in Quantitative Optical Coherence Tomography Angiography?

Alessandro Rabiolo,¹ Francesco Gelormini,¹ Alessandro Marchese,¹ Maria Vittoria Cicinelli,¹ Giacinto Triolo,¹ Riccardo Sacconi,^{1,2} Lea Querques,¹ Francesco Bandello,¹ and Giuseppe Querques¹

¹Department of Ophthalmology, University Vita-Salute, IRCCS San Raffaele, Milan, Italy

²Eye Clinic, Department of Neurological and Movement Sciences, University of Verona, Verona, Italy

Correspondence: Giuseppe Querques, Department of Ophthalmology, IRCCS Ospedale San Raffaele, University Vita-Salute San Raffaele, Via Olgettina 60, Milan, 20132, Italy; giuseppe.querques@hotmail.it.

Submitted: June 5, 2017

Accepted: December 7, 2017

Citation: Rabiolo A, Gelormini F, Marchese A, et al. Macular perfusion parameters in different angiocube sizes: does the size matter in quantitative optical coherence tomography angiography? *Invest Ophthalmol Vis Sci*. 2018;59:231–237. <https://doi.org/10.1167/iops.17-22359>

PURPOSE. To investigate the macular quantitative parameters interchangeability of three different optical coherence tomography (OCTA) angiocubes (i.e., 3×3 , 6×6 , and 12×12 mm) on healthy subjects and patients affected by diabetic retinopathy (DR) and to assess the interrater reliability of such indices across the different scan protocols.

METHODS. Retrospective study involving 20 eyes of healthy subjects and 20 eyes with DR. All eyes underwent swept-source OCTA with 3×3 -, 6×6 -, and 12×12 -mm angiocubes centered on the fovea. Foveal avascular zone (FAZ) area and vessel density on 3×3 -, 6×6 -, and 12×12 -mm macular scans were calculated by three independent operators at all retina, superficial, deep, and choriocapillary vascular layers. Interchangeability and interrater reliabilities were estimated using intraclass correlation coefficient (ICC).

RESULTS. Interscan reproducibility of FAZ area was very strong (ICC > 0.85) at every plexus. On the contrary, vessel density values significantly varied across different scan sizes (ICC < 0.51). Intrascan interrater reliability was high for all retina and superficial FAZ areas, while it was satisfactory at deep capillary plexus only for 3×3 -mm scan.

CONCLUSIONS. FAZ area at all plexuses is a robust parameter even if calculated on angiocubes with different size. However, interrater reliability is higher when measured in smaller scans. Conversely, vessel density results depend on the size of angiocube, although their interrater reliability is extremely high. Studies involving OCTA should take into consideration that scan size may influence macular perfusion parameters and interrater reliability.

Keywords: optical coherence tomography angiography, quantitative optical coherence tomography angiography, foveal avascular zone, vessel density, ImageJ

Optical coherence tomography angiography (OCTA) is a relatively new technology, which allows the visualization of retinal and choroidal vascular layers with no need of dye injection.¹ Differently from fluorescein angiography, OCTA permits the evaluation of retinal and choroidal vascular networks in a separate, noninvasive and three-dimensional fashion.¹ OCTA relies on the principle that erythrocytes flowing in blood vessels are the only moving structure across co-registered sequential B-scans and, therefore, they can be used as a motion contrast to differentiate vessels from static tissues.¹ Based on this assumption, several algorithms have been developed by many instruments including complex optical microangiography (OMAG) for Zeiss devices (Angioplex and PLEX Elite 9000; Carl Zeiss Meditec, Inc., Dublin, CA, USA),^{2,3} split spectrum amplitude decorrelation angiography algorithm (SSADA) for RTVue XR Avanti (Optovue Inc., Fremont, CA, USA),⁴ OCT angiography ratio analyses (OCTARA) for DRI OCT Triton (Topcon, Tokyo, Japan),⁵ and full-spectrum amplitude decorrelation algorithm (FSADA) for Heidelberg (Spectralis; HRA Heidelberg, Heidelberg, Germany).⁶ All these machines provide en face angiogram images, which can be postprocessed in order to obtain quantitative parameters, such

as foveal avascular zone (FAZ) area and vessel density. Many studies have reported that these parameters have high intra- and interoperator reproducibility both in eyes with and without retinal diseases, for the same scan type and for the same machine.^{7–13} In a study by Dong and coworkers,¹⁴ a good agreement between 3×3 - and 6×6 -mm angiocubes was found for choriocapillary vessel density and for FAZ area at all retina vasculatures; conversely, reliability for retinal vessel density was weak. However, scan interchangeability has been only tested for small angiocubes and it remains uncertain for wider size scans (e.g., 12×12 mm). One of the advantages of OCTA compared with fluorescein angiography is the possibility to distinguish between superficial and deep plexuses; however, the effect of different scan sizes on interchangeability and interoperator reliability for each plexus is still unknown. In addition, interchangeability of 3×3 - and 6×6 -mm angiocubes has been demonstrated only for one spectral-domain (SD)-OCT-A device (Optovue) using an automatic method and only in healthy Chinese subjects.¹⁴ Therefore, it remains unclear whether other instruments or manual measurements may yield different results, particularly when applied to individuals with retinal disorders.



To address these points, we conducted a study, which aimed (1) to investigate the impact of three different angiocubes (i.e., 3×3 , 6×6 , and 12×12 mm) on quantitative measures in healthy subjects or with diabetic retinopathy (DR), and (2) to assess the interrater reliability of such indices across the different scan protocols.

METHODS

Study Design and Population

The present study was a retrospective analysis of clinical data acquired from healthy subjects and patients with DR presented at the Medical Retina & Imaging Unit of the Department of Ophthalmology, University Vita-Salute, San Raffaele Hospital, Milan, Italy. In our clinic, all patients referred for OCT examination undergo a standard imaging protocol, which includes SD-OCT (Spectralis; HRA Heidelberg) and OCT-A (PLEX Elite 9000; Carl Zeiss Meditec, Inc.).

Electronic clinical records, SD-OCT and swept source (SS)-OCT-A images from both healthy subjects and patients diagnosed with DR were reviewed. For each group, we included the first 20 consecutive eligible eyes starting from April 4, 2017 and going backward. Inclusion criteria were: age greater than or equal to 18-years old; refractive error between -6 and $+3$ diopters; availability of all 3×3 -, 6×6 -, and 12×12 -mm OCT-A scans with a signal strength greater than or equal to 7 and centered on the fovea. Exclusion criteria were: presence of any retinal disease other than DR; presence of any optic nerve disease; previous ocular surgery other than uncomplicated cataract extraction and IOL implantation performed less than or equal to 6 months before enrollment; artifacts on OCT-A images.

Structural SD-OCT Measurements

The structural SD-OCT acquisition protocol included 19 horizontal raster linear B-scans, each composed by nine averaged OCT B-scans (1024 A-scans per line) at 240- μ m intervals, covering an area of $20^\circ \times 15^\circ$. The central macular thickness (CMT) in the central 1-mm diameter circle of the Early Treatment Diabetic Retinopathy Study (ETDRS) thickness map was recorded with the Spectralis Software.

SS-OCTA Device and Scanning Protocol

The SS-OCTA instrument (PLEX Elite 9000) uses a swept laser source with a central wavelength of 1040 to 1060 nm (980–1120 nm full bandwidth) and operates at 100,000 A-scans per second. The tissutal axial and tranverse resolutions are approximately 6 μ m and 20 μ m, respectively. In order to generate an OCT-A image, datasets are processed by means of the OMAG algorithm, which uses variations in both the intensity and phase information between sequential B-scans acquired at the same position.^{5,15} The 3×3 -mm acquisition is made of 300×300 A-Scans, while the others (i.e., 6×6 , 12×12 mm) are acquired with 500×500 A-Scans.

All 3×3 , 6×6 , and 12×12 mm employ a 1024×1024 -pixel array with 2.9, 5.9, and 11.7 μ m-spacing between pixels, respectively.

All scans were centered on the fovea and automated segmentations of full-thickness (internal limiting membrane to Bruch's membrane) retinal vasculatures, superficial, deep, and choriocapillary vascular layers were reviewed and manual corrections were carried out as necessary to ensure an accurate segmentation. Instrument projections removal algorithm was applied to images at deep capillary plexus and choriocapillaris.

Quantitative Analysis of OCT-A Images

All images were exported to Joint Photographic Expert Group (jpeg) format and analyzed using ImageJ software (<http://imagej.nih.gov/ij/>; provided in the public domain by the National Institutes of Health, Bethesda, MD, USA) by three independent operators (AR, FG, AM), as illustrated in Figure 1. The FAZ area was manually measured at all retina, superficial, and deep vascular layers using a previously published method.^{16,17} Briefly, the FAZ area was encircled using the polygon selection tool and its area was recorded in squared millimeters.

The vessel density was calculated on binarized images using a threshold algorithm, similarly to other studies.^{18,19} The ImageJ 'mean threshold' algorithm, which automatically computes the threshold value as the mean of the local grayscale distribution, was applied to all images. Binarized 8-bit images were converted to red-green-blue (RGB) color model. A region of interest of 512×512 and 256×256 pixels centered on the fovea was applied, respectively, to the 6×6 - and 12×12 -mm images and pixels outside that perimeter were cleared to pure blue color, in order to select the area corresponding to the 3×3 -mm scan. FAZ area was restored to each corresponding image and it was colored to pure blue. White pixels were considered as vessel, black pixels as background, and blue pixels were automatically excluded from the analysis in order to prevent the inclusion of FAZ area and areas outside the 3×3 -mm perimeter during the vessel density calculation. Vessel density was calculated as the ratio between the number of white pixels and the total number of pixels after excluding blue pixels.

Statistical Analysis

The variables included in the analysis were as follows: demographic data; best corrected visual acuity (BCVA); DR severity, CMT; FAZ area at full-thickness, superficial and deep layers; and vessel density at full thickness, superficial, deep, and choriocapillary vascular layers. Interobserver reliability among the three operators was assessed using intraclass correlation coefficient (ICC) for all patients, healthy subjects and patients with DR. Macular perfusion parameters values calculated by the three raters for each plexus were averaged and their consistency across the 3 different scans (i.e., 3×3 , 6×6 , and 12×12 mm) was assessed by means of ICC for all patients, healthy subjects and patients with DR. All results are reported as mean \pm SD values. All statistics were performed using GraphPad Prism software 6.0 (GraphPad Software, Inc., San Diego, CA, USA) and SPSS software 21 (SPSS, Inc., Chicago, IL, USA).

RESULTS

In this study, there were 20 eyes of 12 healthy subjects and twenty eyes of 13 patients with DR. Demographic data and main clinical data of the study population are illustrated in Table 1. In one eye in the DR group, quantitative indices of deep capillary plexus at 12×12 -mm scan were not calculated because FAZ was not recognizable by any of the raters.

The ICCs for FAZ area and vessel density across the three different scan size are shown in Table 2 and Figure 2. With regards to the FAZ area measurement, an excellent (ICC > 0.90) reliability was found at all retina, superficial, and deep capillary plexuses, except for the DR subgroup at the deep capillary plexus, where it was good anyway (ICC 0.852, 95% confidence interval [CI] 0.714–0.935). Not surprisingly, the CIs for the FAZ area were lower in DR patients than in healthy subjects at every plexus.

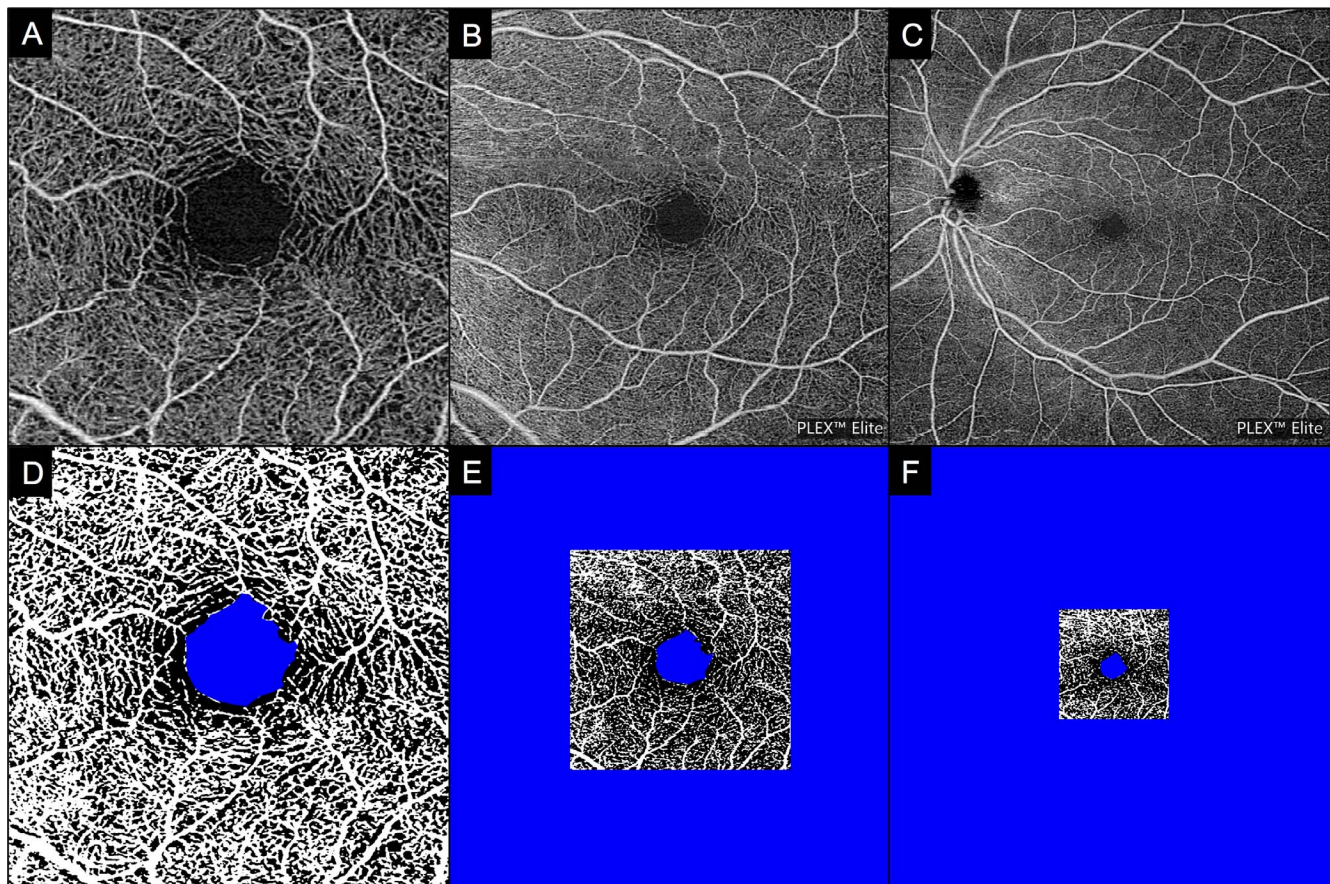


FIGURE 1. Quantification of macular perfusion parameters. The grayscale 3×3 (A), 6×6 (B) and 12×12 (C) en face optical angiograms were converted to binary images (D–F) using a threshold algorithm. A 3×3 -mm area centered on the FAZ was selected on 6×6 and 12×12 mm and used for the image analysis. The FAZ area, depicted in blue, was manually outlined.

Conversely, the interscan reliability of vessel density measurements was poor ($ICC < 0.50$) in every vascular layer, apart from DR patients at the superficial capillary plexus that disclosed by any means a weak reliability ($ICC\ 0.506$, 95% CI 0.185–0.753). Noteworthy, the reliability of vessel density assessment was higher in DR subgroup compared with healthy patients at all plexuses. In 2 eyes, the FAZ area at the deep capillary plexus was not entirely contained in the 3×3 -mm scan.

The interrater reliability for every macular quantitative index at each scan size is shown in Table 3. Regarding the

vessel density, the interobserver reliability was excellent ($ICC > 0.90$) in every vascular plexus at all scan sizes. The FAZ area at all retina and superficial vascular layers disclosed an excellent reliability for all groups at 3×3 - and 6×6 -mm scans. For the same plexuses, interrater reliability for FAZ area of the 12×12 -mm scan was strong (all retina $ICC = 0.820$, superficial $ICC = 0.898$) in the whole cohort of patients, although lower than that of smaller scan protocols. Interestingly, reproducibility was higher in healthy subjects than in DR patients.

At the deep capillary plexus, the interrater reliabilities for FAZ area 3×3 , 6×6 , and 12×12 mm were globally strong ($ICC = 0.816$), moderate ($ICC = 0.545$), and poor ($ICC = 0.290$), respectively. In healthy subjects, a good correlation ($ICC > 0.70$) was appreciated in all three scan protocols. Conversely, interrater reliability in the DR group was strong only for the 3×3 mm ($ICC = 0.799$), while it was poor and very poor for 6×6 - ($ICC = 0.383$) and 12×12 -mm ($ICC = 0.113$) scans, respectively.

DISCUSSION

In the present study, we tested whether macular quantitative parameters (i.e., FAZ area, vessel density) are interchangeable when calculated on different angiocubes (i.e., 3×3 , 6×6 , and 12×12 mm) in subjects with and without retinopathy. In our cohort of patients, the FAZ area, but not vessel density, was a highly reproducible parameter across different angiocubes. Moreover, we investigated if the scan size could affect the

TABLE 1. Demographic and Main Clinical Data of Study Population

Parameters	Overall	Controls	DR
N, patients/eyes	25/40	12/20	13/0
Age y, mean \pm SD	57.0 \pm 16.1	51.8 \pm 17.9	60.8 \pm 13.9
Race, Caucasian	25	12	13
Sex, male/female	14/11	7/5	7/6
Eye, right/left	23/17	13/7	10/10
BCVA, logmar, mean \pm SD	0.14 \pm 0.3	0.0 \pm 0.0	0.29 \pm 0.4
CMT, μ m, mean \pm SD	299.1 \pm 73.8	280.2 \pm 25.7	307.6 \pm 86.6
DME, yes/no	9/11	n/a	9/11
DR severity			
Mild	7	n/a	7
Moderate	9	n/a	9
Severe	2	n/a	2
Proliferative	2	n/a	2

TABLE 2. Reliability of Quantitative Parameters Among 3 × 3-, 6 × 6-, and 12 × 12-mm Macular Scans

	ICC (95% CI)		
	Overall	Controls	DR
All Retina			
FAZ	0.939 (0.901–0.965)	0.983 (0.964–0.993)	0.903 (0.810–0.957)
Vessel density	0.133 (–0.14 to 0.319)	0.055 (–0.046 to 0.240)	0.257 (0.022–0.539)
SCP			
FAZ	0.957 (0.929–0.975)	0.985 (0.966–0.994)	0.932 (0.864–0.970)
Vessel density	0.384 (0.187–0.578)	0.102 (–0.046 to 0.340)	0.506 (0.185–0.753)
DCP			
FAZ	0.911 (0.855–0.949)	0.960 (0.908–0.983)	0.852 (0.714–0.935)
Vessel density	0.097 (–0.23 to 0.271)	0.028 (–0.032 to 0.153)	0.063 (–0.018 to 0.232)
Choriocapillaris			
Vessel density	0.305 (0.113–0.508)	0.066 (–0.138 to 0.361)	0.328 (0.045–0.617)

SCP, superficial capillary plexus; DCP, deep capillary plexus.

interrater reliability. We found a solid reproducibility for both vessel density and FAZ area assessment at the full-thickness retina and superficial vascular layers; conversely, the interrater reliability of FAZ area at the deep capillary plexus was good only for the 3 × 3-mm angiocube.

OCT-A is an extremely attractive tool, which can provide interesting information, such as identification of choroidal neovascularization (CNV) in asymptomatic patients with AMD²⁰ or CNV complicating central serous chorioretinopathy.²¹ Beyond qualitative assessment, OCT-A angiograms may be post-processed in order to obtain quantitative data. Two popular indices are represented by FAZ area and vessel density. The FAZ is a capillary-free area encircled by interconnecting vessels at its margins, corresponding to the foveola, where capillaries of both superficial and deep plexuses break off.²² Although some devices (i.e., Optovue RTVue XR Avanti, Zeiss Angioplex) allow the automatic quantification of macular perfusion parameters using the built-in software, other instruments require the manual selection of innermost retinal vascular arcades in order to outline the FAZ area and image binarization or skeletonization algorithms to obtain vessel

density. Macular quantitative parameters vary across different instruments and techniques (i.e., manual versus automatic assessment); however, several studies demonstrated that they have a good inter- and intraoperator reliability in case of same machine, acquisition and postprocessing protocols.^{7–9,11,12,23} Measurement at the superficial plexus is highly reliable, while manual demarcation at the deep plexus may be not easy due to less definite contours.¹² La Spina and colleagues¹⁰ demonstrated that FAZ is a stable parameter, which is not affected by acute changes in retinal and metabolic states. Despite being highly variable even in healthy subjects,²⁴ several conditions (e.g., DR,²⁵ retinal vein occlusion,²⁶ and sickle cell disease)²⁷ may affect the FAZ size due to the occlusion of capillaries surrounding the FAZ. As a result, the FAZ area in these patients is enlarged and more irregular and, thus, its manual quantification may not be straightforward, especially at the deep plexus.

In our cohort of patients, we found a strong reliability for FAZ area measurements in all three scan sizes in both eyes with and without retinopathy; therefore, the FAZ area should be considered as a robust and interchangeable measure even if

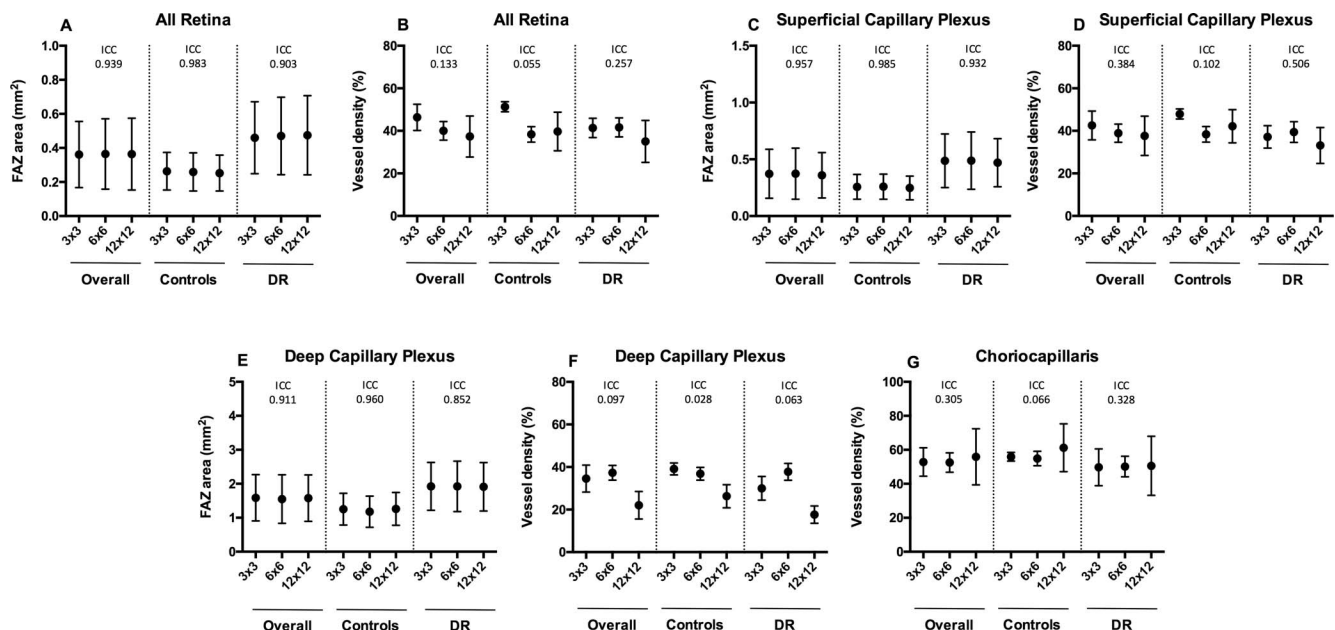


FIGURE 2. Interscan interrater reliability for macular quantitative parameters at all retina (A, B), superficial (C, D), deep (E, F), and choriocapillary (G) vascular layers.

TABLE 3. Reliability of Quantitative Macular Parameters Among Three Operators

	ICC (95% CI)											
	3 × 3 mm			6 × 6 mm			12 × 12 mm					
	Overall	Controls	DR	Overall	Controls	DR	Overall	Controls	DR	Overall	Controls	DR
All retina												
FAZ	0.982 (0.957-0.992)	0.974 (0.813-0.993)	0.977 (0.945-0.991)	0.954 (0.873-0.980)	0.965 (0.704-0.990)	0.933 (0.802-0.975)	0.820 (0.662-0.905)	0.894 (0.457-0.969)	0.749 (0.360-0.903)	0.820 (0.662-0.905)	0.894 (0.457-0.969)	0.749 (0.360-0.903)
Vessel density	1 (0.999-1)	0.999 (0.998-1)	0.999 (0.998-1)	0.999 (0.998-0.999)	1 (0.998-1)	0.998 (0.995-0.999)	0.997 (0.986-0.999)	0.994 (0.909-0.999)	0.999 (0.998-1)	0.997 (0.986-0.999)	0.994 (0.909-0.999)	0.999 (0.998-1)
SCP												
FAZ	0.972 (0.894-0.989)	0.971 (0.763-0.992)	0.960 (0.824-0.987)	0.956 (0.873-0.981)	0.963 (0.700-0.990)	0.938 (0.797-0.978)	0.898 (0.783-0.950)	0.931 (0.577-0.980)	0.845 (0.551-0.943)	0.898 (0.783-0.950)	0.931 (0.577-0.980)	0.845 (0.551-0.943)
Vessel density	1 (1-1)	0.999 (0.997-1)	1 (0.999-1)	0.999 (0.998-)	1 (0.99-1)	0.999 (0.997-0.999)	1 (1-1)	1 (0.999-1)	1 (0.999-1)	1 (1-1)	1 (0.999-1)	1 (0.999-1)
DCP												
FAZ	0.816 (0.270-0.936)	0.720 (0.116-0.910)	0.799 (0.228-0.937)	0.545 (0.313-0.722)	0.695 (0.190-0.889)	0.383 (0.119-0.649)	0.290 (0.096-0.496)	0.807 (0.236-0.941)	0.113 (-0.074 to 0.392)	0.290 (0.096-0.496)	0.807 (0.236-0.941)	0.113 (-0.074 to 0.392)
Vessel density	0.981 (0.916-0.993)	0.919 (0.416-0.978)	0.972 (0.917-0.990)	0.971 (0.876-0.989)	0.951 (0.688-0.968)	0.982 (0.946-0.994)	0.998 (0.990-0.999)	0.997 (0.968-0.999)	0.994 (0.983-0.998)	0.998 (0.990-0.999)	0.997 (0.968-0.999)	0.994 (0.983-0.998)
Choriocapillaris												
Vessel density	1 (1-1)	1 (1-1)	1 (1-1)	1 (1-1)	1 (1-1)	1 (1-1)	1 (1-1)	1 (1-1)	1 (1-1)	1 (1-1)	1 (1-1)	1 (1-1)

calculated in wide angiocubes, such as the 12 × 12-mm scan. Looking at the subgroups, it is noteworthy that the reliability across different scan size was high not only in healthy eyes, but also in the DR group. When considering the FAZ area interrater reliability for each single plexus in the same excellent results were found only for all retina and superficial vascular layers in smaller angiocubes (i.e., 3 × 3 and 6 × 6 mm). Less but still satisfactory reliability was disclosed also for 12 × 12-mm angiocube at the same plexuses besides diabetic subgroup at all retina. As reported by other studies,¹² the interrater reliability was not as good for deep vascular plexus. Interestingly, good results were seen in the 3 × 3-mm scan, but not in the others. In addition, diabetic patients had poorer interrater reliability than healthy subjects; however, several factors should be taken into account in order to explain this finding. The deep plexus is considerably disrupted in DR patients, especially in cases of severe retinopathy.²⁸ In addition, diabetic macular edema is associated with the involvement of the deeper retinal layers and, thus, it can also affect FAZ measure.^{29,30} Because the 12 × 12-mm angiocube has a poor resolution, it can be more difficult to unequivocally outline FAZ area compared with smaller scans. In this regard, in one eye of DR subgroup, all readers were not able to draw FAZ perimeter in 12 × 12-mm angiocube because it was not clearly distinguishable. On the other hand, vascular disruption in eyes suffering from DR can be so pronounced that in two eyes deep FAZ was not completely contained in the 3 × 3-mm scan. This could be explained considering that FAZ is usually larger at deep capillary plexus, and, as already mentioned, deep vascular layer disruption is more pronounced in DR.^{17,28}

With regard to vessel density, our study showed a poor interchangeability across different angiocubes for every plexus and every subgroup. Several aspects should be considered to interpret this finding. The number of A-scan for the three angiocubes is different, namely the angiocube 3 × 3 is made of 300 × 300 A-Scans, the others (6 × 6, 9 × 9, and 12 × 12) are acquired with 500 × 500 A-Scans. Furthermore, the spacing between the pixels is 2.9, 5.9, and 11.7 μm, respectively, for 3 × 3, 6 × 6, and 12 × 12 mm, and thus, wider scans are characterized by less resolution than smaller but denser scans. Finally, the overlap between original 3 × 3 mm and cropped wider images (6 × 6 and 12 × 12 mm) could be slightly inaccurate. Compared with the previous study by Dong and colleagues,¹⁴ we did not observe interchangeability for choriocapillary vessel density. This could be due to differences in instruments, type of OCT-A (SD versus SS), quantitative measures calculation, and study population. Because vessel density calculation was semiautomatic, and thus, less operator-dependent than FAZ area, the interrater reliability was almost perfect across all plexuses at every angiocube. Although counterintuitive, interscan vessel density reliability was higher in DR group than in control one. Explanation of this finding is as hard as speculative. DR is characterized by capillary dropouts with relative sparing of larger vessels. The drop of image resolution from smaller to larger angiocubes could have affected more the visualization of small capillaries than larger vessels, especially when a threshold is applied.

The first limitation of our study is the small sample size. Moreover, we did not apply any correction of image magnification related to difference into axial length (as proposed by Sampson et al.³¹) because this study was retrospective in its nature and such measurements were not available. In the present study, however, we did not compare the absolute values of macular quantitative parameters between patients with DR and controls, but rather the interscan and intrascan reliabilities. Another potential limitation of our study could be related to artifacts on OCT-A; however, artifacts were considered as an exclusion criterion,

and they should not have been affecting our analysis. Finally, quantitative parameters were manually calculated and only one OCT-A device was used; therefore, our findings may be not applicable to other postprocessing algorithms or OCT-A devices.

In conclusion, we demonstrated that FAZ area at all plexuses is a robust parameter even if calculated in different angiocubes. However, its interrater reliability is higher when measured in smaller scans. On the other hand, vessel density results depend on the angiocube size, although their interrater reliability is extremely high. Studies involving OCT-A should take into account that the scan size may affect macular perfusion parameters and interrater reliability.

Acknowledgments

Disclosure: **A. Rabiolo**, None; **F. Gelormini**, None; **A. Marchese**, None; **M.V. Cicinelli**, None; **G. Triolo**, None; **R. Sacconi**, None; **L. Querques**, None; **F. Bandello**, Allergan (S), Alimera (S), Bayer (S), Farmila-Thea (S), Schering Pharma (S), Sanofi-Aventis (S), Novagali (S), Pharma (S), Hoffmann-La Roche (S), Genentech (S), Novartis (S); **G. Querques**, Alimera Sciences (C), Allergan, Inc. (C), Bayer Schering-Pharma (C), Heidelberg (C), Novartis (C), Sandoz (C), Zeiss (C)

References

- Rabiolo A, Carnevali A, Bandello F, Querques G. Optical coherence tomography angiography: evolution or revolution? *Expert Rev Ophthalmol*. 2016;11:243-245.
- Rosenfeld PJ, Durbini MK, Roisman L, et al. ZEISS angioplex spectral domain optical coherence tomography angiography: technical aspects. *Dev Ophthalmol*. 2016;56:18-29.
- Miller AR, Roisman L, Zhang Q, et al. Comparison between spectral-domain and swept-source optical coherence tomography angiographic imaging of choroidal neovascularization. *Invest Ophthalmol Vis Sci*. 2017;58:1499-1505.
- Huang D, Jia Y, Gao SS, Lumbroso B, Rispoli M. Optical coherence tomography angiography using the optovue device. *Dev Ophthalmol*. 2016;56:6-12.
- Huang Y, Zhang Q, Thorell MR, et al. Swept-source OCT angiography of the retinal vasculature using intensity differentiation-based optical microangiography algorithms. *Ophthalmic Surg Lasers Imaging Retina*. 2014;45:382-389.
- Coscas G, Lupidi M, Coscas F Heidelberg spectralis optical coherence tomography angiography: technical aspects. *Dev Ophthalmol*. 2016;56:1-5.
- Al-Sheikh M, Tepelus TC, Nazikyan T, Sadda SR. Repeatability of automated vessel density measurements using optical coherence tomography angiography. *Br J Ophthalmol*. 2017;101:449-452.
- Carpineto P, Mastropasqua R, Marchini G, Toto L, Di Nicola M, Di Antonio L. Reproducibility and repeatability of foveal avascular zone measurements in healthy subjects by optical coherence tomography angiography. *Br J Ophthalmol*. 2016; 100:671-676.
- Guo J, She X, Liu X, Sun X. Repeatability and reproducibility of foveal avascular zone area measurements using angioplex spectral domain optical coherence tomography angiography in healthy subjects. *Ophthalmologica*. 2017;237:21-28.
- La Spina C, Carnevali A, Marchese A, Querques G, Bandello F. Reproducibility and reliability of optical coherence tomography angiography for foveal avascular zone evaluation and measurement in different settings. *Retina*. 2017;37:1636-1641.
- Mastropasqua R, Toto L, Mattei PA, et al. Reproducibility and repeatability of foveal avascular zone area measurements using swept-source optical coherence tomography angiography in healthy subjects. *Eur J Ophthalmol*. 2017;27:336-341.
- Shahlaee A, Pefkianaki M, Hsu J, Ho AC. Measurement of foveal avascular zone dimensions and its reliability in healthy eyes using optical coherence tomography angiography. *Am J Ophthalmol*. 2016;161:50-55.e1.
- You Q, Freeman WR, Weinreb RN, et al. Reproducibility of vessel density measurement with optical coherence tomography angiography in eyes with and without retinopathy. *Retina*. 2017;37:1475-1482.
- Dong J, Jia YD, Wu Q, et al. Interchangeability and reliability of macular perfusion parameter measurements using optical coherence tomography angiography. *Br J Ophthalmol* 2017.
- Roisman L, Zhang Q, Wang RK, et al. Optical coherence tomography angiography of asymptomatic neovascularization in intermediate age-related macular degeneration. *Ophthalmology*. 2016;123:1309-1319.
- Battaglia Parodi M, Rabiolo A, Cicinelli MV, Iacono P, Romano F, Bandello F. Quantitative analysis of optical coherence tomography angiography in adult-onset foveomacular vitelliform dystrophy [published online ahead of print January 31, 2017]. *Retina*. doi:10.1097/IAE.0000000000001539.
- Samara WA, Say EA, Khoo CT, et al. Correlation of foveal avascular zone size with foveal morphology in normal eyes using optical coherence tomography angiography. *Retina*. 2015;35:2188-2195.
- Carnevali A, Sacconi R, Corbelli E, et al. Optical coherence tomography angiography analysis of retinal vascular plexuses and choriocapillaris in patients with type 1 diabetes without diabetic retinopathy. *Acta Diabetol*. 2017;54:695-702.
- Cicinelli MV, Rabiolo A, Marchese A, et al. Choroid morphometric analysis in non-neovascular age-related macular degeneration by means of optical coherence tomography angiography. *Br J Ophthalmol*. 2017;101:1193-1200.
- Carnevali A, Cicinelli MV, Capuano V, et al. Optical coherence tomography angiography: a useful tool for diagnosis of treatment-naïve quiescent choroidal neovascularization. *Am J Ophthalmol*. 2016;169:189-198.
- Bousquet E, Bonnin S, Mrejen S, Krivosic V, Tadayoni R, Gaudric A. Optical coherence tomography angiography of flat irregular pigment epithelium detachment in chronic central serous chorioretinopathy [published online ahead of print March 3, 2017]. *Retina*. doi:10.1097/IAE.0000000000001580.
- Cicinelli MV, Carnevali A, Rabiolo A, et al. Clinical spectrum of macular-foveal capillaries evaluated with optical coherence tomography angiography. *Retina*. 2017;37:436-443.
- Magrath GN, Say EA, Sioufi K, Ferenczy S, Samara WA, Shields CL. Variability in foveal avascular zone and capillary density using optical coherence tomography angiography machines in healthy eyes. *Retina*. 2017;37:2102-2111.
- Shahlaee A, Samara WA, Hsu J, et al. In vivo assessment of macular vascular density in healthy human eyes using optical coherence tomography angiography. *Am J Ophthalmol*. 2016; 165:39-46.
- Al-Sheikh M, Akil H, Pfau M, Sadda SR. Swept-source oct angiography imaging of the foveal avascular zone and macular capillary network density in diabetic retinopathy. *Invest Ophthalmol Vis Sci*. 2016;57:3907-3913.
- Adhi M, Filho MA, Louzada RN, et al. Retinal capillary network and foveal avascular zone in eyes with vein occlusion and fellow eyes analyzed with optical coherence tomography angiography. *Invest Ophthalmol Vis Sci*. 2016;57:OCT486-OCT494.
- Minvielle W, Caillaux V, Cohen SY, et al. Macular microangiopathy in sickle cell disease using optical coherence tomography angiography. *Am J Ophthalmol*. 2016;164:137-144.e1.

28. Sambhav K, Abu-Amero KK, Chalam KV. Deep capillary macular perfusion indices obtained with OCT angiography correlate with degree of nonproliferative diabetic retinopathy [published online ahead of print May 27, 2017]. *Eur J Ophthalmol*. doi:10.5301/ejo.5000948.
29. Coscas G, Lupidi M, Coscas F. Optical coherence tomographic angiography in diabetic macular ischemia: a new step forward. *JAMA Ophthalmol*. 2016;134:373-374.
30. Munk MR, Jampol LM, Simader C, et al. Differentiation of diabetic macular edema from pseudophakic cystoid macular edema by spectral-domain optical coherence tomography. *Invest Ophthalmol Vis Sci*. 2015;56:6724-6733.
31. Sampson DM, Gong P, An D, et al. Axial length variation impacts on superficial retinal vessel density and foveal avascular zone area measurements using optical coherence tomography angiography. *Invest Ophthalmol Vis Sci*. 2017; 58:3065-3072.