


Contents lists available at [ScienceDirect](https://www.sciencedirect.com)

# American Journal of Ophthalmology Case Reports

journal homepage: [www.ajocasereports.com/](http://www.ajocasereports.com/)

## Bilateral asymptomatic macular hypopigmentation in a young woman: multimodal imaging and pathogenetic hypothesis

Federico Fantaguzzi<sup>a</sup>, Ilaria Zucchiatti<sup>a</sup>, Riccardo Sacconi<sup>a</sup>, Anna Valeria Bux<sup>b</sup>,  
 Francesco Prascina<sup>a</sup>, Francesco Bandello<sup>a</sup>, Giuseppe Querques<sup>a,\*</sup>

<sup>a</sup> Department of Ophthalmology, University Vita-Salute, IRCCS San Raffaele, Milan, Italy

<sup>b</sup> Department of Ophthalmology, University of Foggia, Foggia, Italy

### ARTICLE INFO

#### Keywords:

Retinal pigment epithelium  
 Macular retinal hypopigmentation  
 Optical coherence tomography  
 Near-infrared autofluorescence  
 Short-wavelength autofluorescence

### ABSTRACT

**Purpose:** Macular retinal pigment epithelium (RPE) hypopigmentation is a recently described very rare condition and its pathogenesis is not completely understood. We report the case of a 23-year-old female who presented with bilateral whitish, oval-shaped foveal lesions and we speculated about the possible etiopathogenetic origin. **Observations:** A 23-year-old female presented to our consideration for a routine ophthalmology visit. Visual acuity was 20/20 in both eyes. The fundus examination revealed a perifoveal choroidal nevus in the right eye and a bilateral yellowish, oval-shaped lesion centered on the fovea. Imaging tests (Spectral Domain-Optical Coherence Tomography, short wavelength and near-infrared autofluorescence) and functional tests (microperimetry and multifocal electroretinogram) were within normal limits, supporting the diagnosis of macular hypopigmentation without functional loss. **Conclusions:** A complex dysregulation of both choroidal and RPE with melanin loss may be responsible for this condition.

### 1. Introduction

Macular retinal pigment epithelium (RPE) hypopigmentation occurring without functional loss is a very rare disorder, described in 2017 by Boulanger-Scemama et al.<sup>1</sup> in three otherwise asymptomatic female patients. The most common ocular manifestation of macular RPE hypopigmentation is normal visual acuity associated to an unusual macular hypopigmentation that presents as a pale, white-yellow, oval-circular shaped lesion centered on the fovea. This lesion is variable in size and is usually discovered incidentally on ocular fundus examination. To the best of our knowledge, no other cases of this stationary and asymptomatic condition have been described. Therefore, the etiopathogenesis of macular RPE hypopigmentation is still not completely understood. The authors hypothesized that these lesions were likely the result of a decreased amount of melanin within RPE cells. This pathogenic hypothesis is primarily based on fundus autofluorescence (FAF) and optical coherence tomography (OCT) findings.

FAF is a non-invasive imaging technique that relies on the ability of some substances normally present in the retina and in the choroid to act as fluorophores, (i.e. emitting light energy when hit by a beam of light of

a specific wavelength). The two main fluorophores in the retina are lipofuscin and melanin. Lipofuscin is produced by degradation of the outer photoreceptor segments in the RPE. It is characterized by an emission peak at 570–605nm when hit by a wavelength of 488nm. Therefore, lipofuscin can be studied in vivo with a short wavelength FAF (SW-FAF) (Fig. 3A). Melanin is contained in the melanosomes, arranged in the apical portion of RPE cells, just below the photoreceptor layer. It is characterized by an emission peak >800nm when stimulated by a wavelength of 787nm. Therefore, melanin can be studied in vivo with a near-infrared FAF (NIR-FAF). In healthy eyes, NIR-FAF is characterized by an area of hyperautofluorescence that is centered on the fovea and corresponds to the higher concentration of RPE melanin at this location, compared with the surrounding retina. This area of increased autofluorescence at NIR-FAF corresponds to reduced autofluorescence at central SW-FAF, as melanin contained in the apical portions of RPE cells masks the lipofuscin signal (Fig. 3B). This pattern is reversed in macular RPE hypopigmentation in which NIR-FAF shows macular hypoautofluorescence, whereas SW-FAF shows foveal-centered ring of hyperautofluorescence as a result of the unmasking of the lipofuscin signal.

As described by Boulanger-Scemama et al.,<sup>1</sup> OCT shows additional

\* Corresponding author.

E-mail address: [giuseppe.querques@hotmail.it](mailto:giuseppe.querques@hotmail.it) (G. Querques).

<https://doi.org/10.1016/j.ajoc.2022.101725>

Received 2 June 2022; Received in revised form 6 October 2022; Accepted 9 October 2022

Available online 13 October 2022

2451-9936/© 2022 The Authors. Published by Elsevier Inc. This is an open access article under the CC BY-NC-ND license (<http://creativecommons.org/licenses/by-nc-nd/4.0/>).

distinctive features of this condition. The retina has a normal morphology and structure, and no alterations are visible at the RPE level. However, the underlying choroid and sclera show a greater reflectivity in comparison to the surrounding area. This retrofoveal choroidal hyperreflectivity is similar to what is observed in RPE atrophy. In fact, an increase in signal backscattering by the choroid suggests loss of the normal RPE barrier. However, in macular RPE hypopigmentation the outer OCT bands are normally conformed.

Aim of this report is to describe a further bilateral case of this very rare condition, investigated by means of multimodal imaging, such as autofluorescence, OCT, microperimetry and multifocal electroretinogram and to present some pathogenetic hypothesis.

## 2. Case report

A healthy 23-year-old woman presented to our attention for the first time in December 2020 for a routine ophthalmologic examination. Ocular history was negative except for a choroidal nevus in the right eye that she was keeping controlled with annual fundus examinations. Past medical was unremarkable and she was using neither topical nor systemic medication related to retinotoxicity. Family history was negative for both inherited and acquired retinal diseases. She presented to our clinic with no visual disturbances.

On exam, visual acuity was 20/20 in both eyes with no refractive correction. She did not complain any metamorphopsia on the Amsler grid. Anterior segment and intraocular pressure were within normal limits in both eyes. Dilated fundus examination and fundus photograph (Fig. 1A and B) revealed a flat choroidal nevus located superiorly and nasally to the macula, in the right eye. An abnormal macular reflex was evident in both eyes associated with discrete alterations in the macular pigmentation. These changes presented as a sharply demarcated oval-shaped lesion with a major horizontal axis and yellowish in color.

The patient was then investigated by means of multimodal imaging to clarify the nature of these lesions. Infrared reflectance (Fig. 1C and D) showed only mild changes with a hyperreflective foveal and parafoveal appearance; an hyperreflective signal was evident at the choroidal nevus of the right eye (Fig. 1C and D). SW-FAF (Fig. 1E and F) showed a target

pattern characterized by foveal hypoautofluorescence surrounded by a hyperautofluorescent annulus in the parafovea. NIR-FAF (Fig. 1G) showed a foveal and parafoveal hypoautofluorescence associated with hyperautofluorescence at the choroidal nevus of the right eye; a faint parafoveal hypoautofluorescence is also visible in left eye (Fig. 1H). Spectral Domain-OCT B-scan centered on the fovea (Fig. 2C) revealed a normal-structured retina with a normal outer retinal representation. However, a retrofoveal hyperreflectivity of the choroid and sclera was present. In addition, in the site of the RPE hypopigmentation, on enhanced depth imaging (EDI)-OCT an irregular profile of the chorioc-scleral junction is visible, showing a focal reduction of the choroidal thickness compared to the nearby unaffected retina. En-face OCT showed a normal reflectivity of the RPE, without any area of altered reflectivity at the site of the lesion (Fig. 2A).

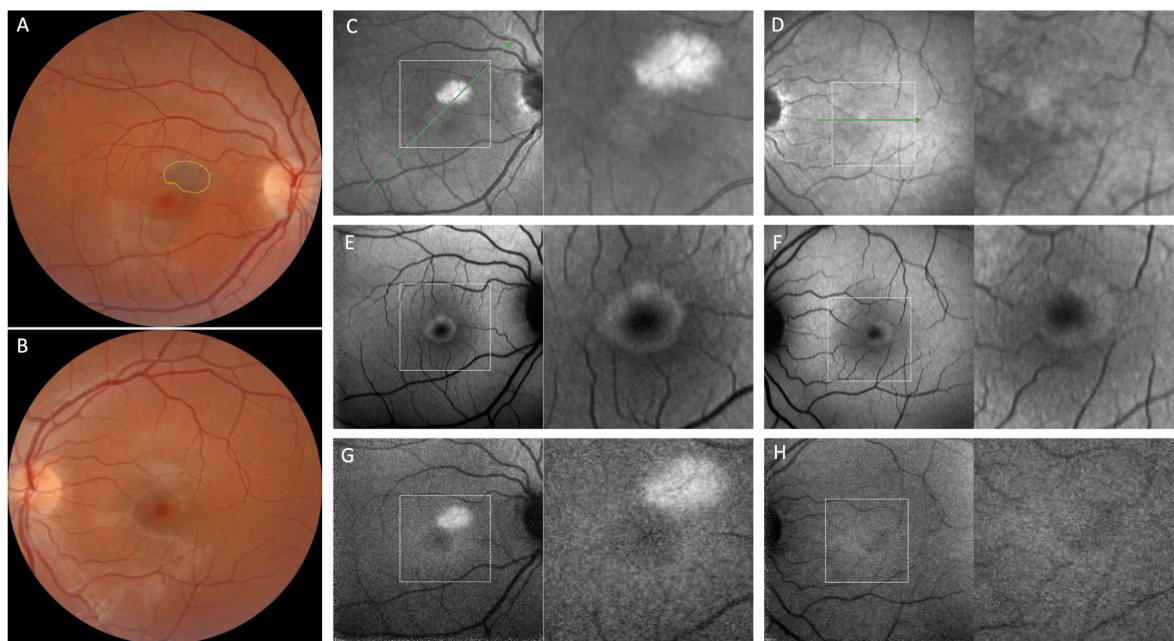
After the initial evaluation, the patient was also investigated with microperimetry and multifocal electroretinogram in order to exclude a pre-clinical stage of macular dystrophy; both examinations were found to be within normal limits.

## 3. Discussion

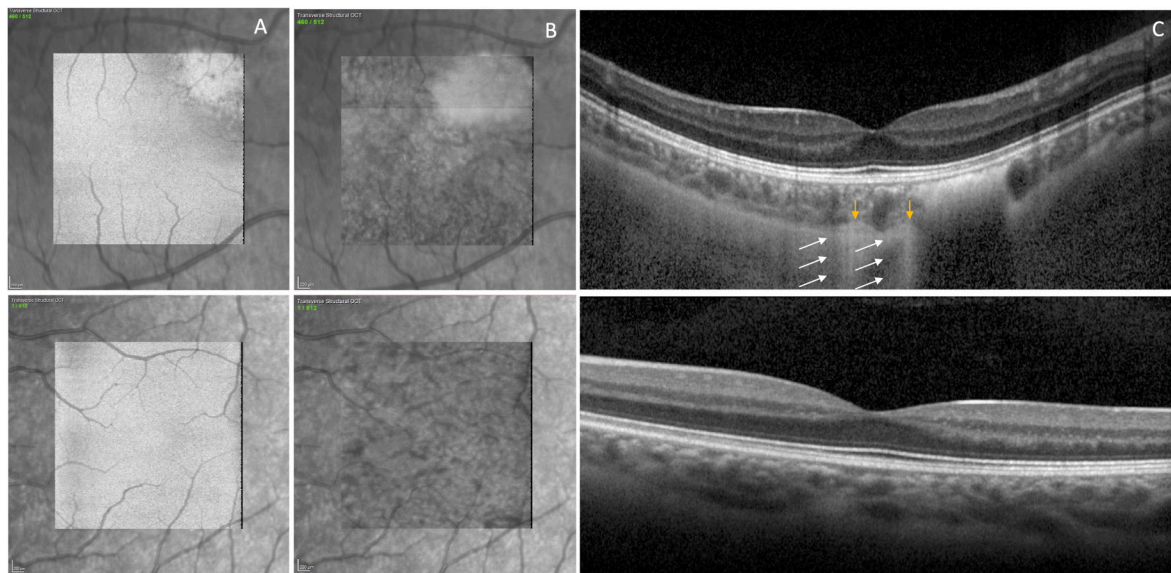
We presented a case of bilateral macular RPE hypopigmentation without functional loss. To the best of our knowledge only three cases have been previously reported by Boulanger-Scemama et al.<sup>1</sup> In their case series all patients were female and the age of detection was between 29 and 65 years old. Only in one case the condition was monolateral. Because of the multimodal imaging features, especially those of SW-FAF and NIR-FAF, the authors proposed that these lesions represent focal hypopigmentation of the RPE.

The RPE is a monolayer of highly pigmented cells distributed along the inner aspect of Bruch's membrane. There are three main types of pigment granules in human RPE: 1) melanosomes that are formed during embryogenesis; 2) lipofuscin granules that accumulate with increasing age; 3) melanolipofuscin granules that are a feature of aged RPE. Eumelanin within the RPE has a protective role against radiation and oxidative stress.<sup>2,3</sup>

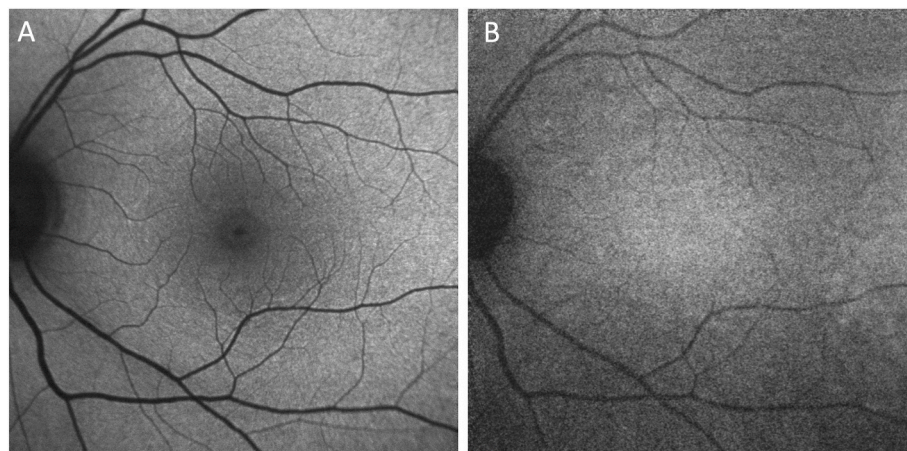
On the other hand, the choroid is a dense network of blood vessels



**Fig. 1.** Fundus photographs (A, B) show discrete alterations in the macular pigmentation and a choroidal nevus in the right eye (yellow dotted line). The latter is more evident in infrared reflectance (C, D) due to its hyper-reflective signal. Short wavelength autofluorescence (E, F) shows an unusual parafoveal hyperautofluorescence. Near-infrared autofluorescence of the right eye (G) displays a foveal hypoautofluorescence; a faint hypoautofluorescence is also present in left eye (H). (For interpretation of the references to color in this figure legend, the reader is referred to the Web version of this article.)



**Fig. 2.** En-face face optical coherence tomography (OCT) with both retinal pigment epithelium (RPE) (A) and choroid (B) segmentations do not show noticeable differences in the tissue reflectivity between the area involved by depigmentation and the surrounding areas. B-scan OCT (C) shows a normal-structured retina with booth a normal outer retinal and retinal pigment epithelium representation. Both a retrofoveal hyperreflectivity (white arrows) of the choroid and sclera and a focal reduction of the choroidal thickness at the lesion site are present (yellow arrows). (For interpretation of the references to color in this figure legend, the reader is referred to the Web version of this article.)



**Fig. 3.** Short wavelength autofluorescence (A) and near-infrared autofluorescence (B) of a healthy control.

embedded in a collagenous and elastic stroma containing melanocytes, fibroblasts, and resident immune cells that supplies the outer retina.<sup>4</sup>

The overall autofluorescence intensity in NIR-FAF depends on the distribution of melanin in both the RPE and the choroid. Therefore, the presence of macular hypoautofluorescence in NIR-FAF itself does not allow a conclusive determination of whether the melanin loss is within RPE, or within choroid, or within both.

A useful complement to the NIR-FAF is provided by OCT images. Four outer hyper-reflective retinal bands are currently identified: external limiting membrane (ELM), the ellipsoid zone (EZ), the interdigitation zone (IZ), and the RPE-Bruch’s Membrane (RPE-BrM) bands.<sup>5</sup> The described four hyperreflective bands are also clearly visible in subjects with albinism, suggesting that melanosomes are not completely responsible for the reflectivity of the RPE-BrM band. However, in albino subjects a splitting of the RPE-BrM band is commonly observed, resulting in the appearance of a separated BrM band. Since melanosomes serve to absorb photons and increase light scattering, when their concentration within RPE is reduced, as in albinism, a fifth hyper-reflective band appears. In other words, the presence of melanin causes an

increase in the reflectance of the RPE and a consequent broadening of its band preventing the observation of BrM.<sup>6</sup> The presence of a fifth band is more prevalent in subjects with albinism than in the normal population.<sup>7</sup> Since the lesions described in our case and in all three cases by Boulanger-Scemama et al. are focal, one may expect to observe some differences in the reflectivity or thickness of the RPE band between the area involved by depigmentation and the surrounding areas. However, OCT images do not show a clear separation of the RPE band from the BrM band, nor a reduction in the reflectivity of the RPE-BrM band at the lesion site. One possibility is that the reduction in melanin concentration within the RPE cells is not enough to produce observable changes in the OCT bands but is sufficient to result in increased choroidal backscattering. A second possibility is that the RPE is relatively normal, and the loss of melanin affects mainly the choroid. This is supported by the finding of normal reflectivity of the RPE on both B-scan and en-face OCT. This second scenario does not explain the SW-FAF findings. Although SW-FAF does not directly show melanin fluorescence, it allows to indirectly estimate its reduction. An increase in macular SW-FAF autofluorescence may occur due to a pathological increase in

lipofuscin or due to a reduction in macular melanin pigment, which normally masks the lipofuscin signal. Since no deposits of lipofuscin are present at b-scan OCT, it is more likely that the increase in autofluorescence is due to a loss of the masking effect of the RPE melanin. This hypothesis agrees with what has already been postulated by Boulanger-Scemama et al. namely that lesions are in part related to a loss of melanin within the RPE. However, one can argue that macular SW-FAF did not appear increased because of masking effects by xanthophylls and thus we cannot exclude that a loss of choroidal melanin may co-occur in this condition. Previous study reported that visualization of the choroid on OCT imaging might be affected by pigmented uveal melanocytes in the choroid<sup>8–10</sup> and that the melanin pigment in the uvea might be a major contributor to choroidal morphology than RPE pigment.<sup>10</sup>

In our case, the hypopigmentation in the right eye is contiguous with a choroidal nevus. Pigmented choroidal nevi frequently exhibit a circular band of depigmentation (also known as a “halo sign”). The genesis of the halo is not completely known. It is known to be a predictor of choroidal nevus stability with a statistically lower risk of transformation into choroidal melanoma. It has also been associated with the presence of cutaneous melanoma in some studies. This association could be related to the presence of a cytotoxic immune response against melanoma antigens which cross-reacts against the melanocyte antigens.<sup>11</sup> Regardless of the mechanism of halo sign formation in the choroidal nevus, it appears, at least fundoscopically, similar to the hypopigmentation in our case.

In previous studies regarding unilateral choroidal melanocytosis, EDI-OCT has been employed to assess choroidal changes compared the unaffected eye<sup>8,9</sup> demonstrating that choroidal melanin might have some optical interesting properties influencing choroidal visualization and measurements. In the paper of Pellegrini et al. OCT passing through choroidal melanocytosis showed increased choroidal thickness, with a greater visualization of the choroidal stromal tissue and minimal effect on the overlying retina.<sup>8</sup> In our report, an irregular profile of the chorio-scleral junction is clearly visible in the site of the RPE depigmentation, without any significant retinal alterations. Our findings are in line with the previous cited, showing that changes in the choroidal melanin may be able to influence choroidal visualization on OCT.

This finding suggests that RPE and choroidal melanin dysregulation may coexist in RPE depigmentation.

#### 4. Conclusion

We described the multimodal imaging features of a case of macular hypopigmentation, the 4th reported so far to our knowledge, associated with a choroidal nevus. Our findings support what has already been described in the literature about melanin loss at the RPE level. However, a more complex dysregulation also involving the choroid may be responsible for this finding. Long follow-up of patients will be necessary to further enrich our knowledge about the pathogenesis and the clinical course of this rare condition.

#### Patient consent

Consent to publish this case report has been obtained from the patient in writing form. This report does not contain any personal identifying information.

#### Authorship

None. All authors attest that they meet the current ICMJE criteria for Authorship.

#### Financial disclosures

FF have nothing to disclose. IZ have nothing to disclose. RS have nothing to disclose. AVB have nothing to disclose. FP have nothing to disclose. FB has the following disclosures: Abbvie, Alimera, Bayer, Boehringer-Ingelheim, Fidia sooft, Hofmann la roche, Novartis, Ntc pharma, Oxurion NV, SIFI. GQ has the following disclosures: Alimera Sciences, Allergan Inc, Amgen, Bayer Shering-Pharma, Heidelberg, KBH, LEH Pharma, Lumithera, Novartis, Sandoz, Sifi, Sooft-Fidea, Zeiss.

#### Acknowledgements

None.

#### References

- Boulanger-Scemama E, Akesbi J, Tick S, Mohand-Said S, Sahel JA, Audo I. Multimodal imaging and functional correlations identify unusual cases of macular retinal pigment epithelium hypopigmentation occurring without functional loss. *Doc Ophthalmol*. 2017;135:77–83.
- Wang Z, Dillon J, Gaillard ER. Antioxidant properties of melanin in retinal pigment epithelial cells. *Photochem Photobiol*. 2006;82:474–479.
- Sarna T. Properties and function of the ocular melanin—a photobiophysical view. *J Photochem Photobiol, B*. 1992;12:215–258.
- Nickla DL, Wallman J. The multifunctional choroid. *Prog Retin Eye Res*. 2010;29:144–168.
- Spaide RF, Curcio CA. Anatomical correlates to the bands seen in the outer retina by optical coherence tomography: literature review and model. *Retina*. 2011;31:1609–1619.
- Wilk MA, Huckenpähler AL, Collery RF, Link BA, Carroll J. The effect of retinal melanin on optical coherence tomography images. *Transl Vis Sci Technol*. 2017;6:8.
- Wilk MA, McAllister JT, Cooper RF, et al. Relationship between foveal cone specialization and pit morphology in albinism. *Invest Ophthalmol Vis Sci*. 2014;55:4186–4198.
- Pellegrini M, Shields CL, Arepalli S, Shields JA. Choroidal melanocytosis evaluation with enhanced depth imaging optical coherence tomography. *Ophthalmology*. 2014;121:257–261.
- Venkatesh R, Reddy NG, Chhablani J. Impact of melanin on choroidal measurements. *Med Hypotheses*. 2021;146, 110408.
- Yiu G, Vuong VS, Oltjen S, et al. Effect of uveal melanocytes on choroidal morphology in rhesus macaques and humans on enhanced-depth imaging optical coherence tomography. *Invest Ophthalmol Vis Sci*. 2016;57:5764–5771.
- Shields CL, Maktabi AM, Jahnle E, Mashayekhi A, Lally SE, Shields JA. Halo nevus of the choroid in 150 patients: the 2010 Henry van Dyke Lecture. *Arch Ophthalmol*. 2010;128:859–864.