

## Progressive resolution of exudation from perifoveal vascular anomalous complex: A possible role of diclofenac therapy?

Beatrice Tombolini<sup>a,b</sup>, Michele Cavalleri<sup>a,b</sup>, Riccardo Sacconi<sup>a,b</sup>, Lea Querques<sup>a,b</sup>,  
Iliaria Zucchiatti<sup>a,b</sup>, Francesco Bandello<sup>a,b</sup>, Giuseppe Querques<sup>a,b,\*</sup>

<sup>a</sup> School of Medicine, Vita-Salute San Raffaele University, Milan, Italy

<sup>b</sup> Division of Head and Neck, Ophthalmology Unit, IRCCS San Raffaele Scientific Institute, Milan, Italy

### ARTICLE INFO

#### Keywords:

Diclofenac  
Exudative  
Optical coherence tomography angiography  
PEVAC  
Perifoveal exudative vascular anomalous complex  
Perifoveal vascular anomalous complex  
PVAC

### ABSTRACT

**Purpose:** To report a case of progressive resolution of exudation in a patient affected by perifoveal vascular anomalous complex (PVAC) undergoing topical diclofenac therapy.

**Observations:** A 74-year-old man presented to our department with visual decrease in his right eye lasting six months. Lack of clinical history of arterial hypertension, diabetes, or any other systemic or local vasculopathy, together with retinal multimodal imaging, led to the diagnosis of exudative (e)PVAC. Serial spectral-domain optical coherence tomography (SD-OCT) examinations documented a resolution of intraretinal exudation after one-month topical diclofenac therapy.

**Conclusion and Importance:** Initiation of topical diclofenac was associated with resolution of exudation, therefore we hypothesize its potential role in the treatment of ePVAC.

### 1. Introduction

Perifoveal vascular anomalous complex (PVAC) is a perifoveal, unilateral, usually unifocal, less frequently multiple, large aneurysmal lesion associated with surrounding microvascular changes in an otherwise healthy patient.<sup>1</sup>

This condition was first described by Querques and associates as PEVAC.<sup>2</sup>

Lesions occurring in PVAC disease are usually not progressive and cause a moderate impact on vision, with visual decline and metamorphopsia caused by intraretinal exudation associated with the large aneurysmal lesions.<sup>1</sup>

Recently, it has been suggested to differentiate two forms of this condition: a non-exudative (nePVAC) and an exudative one (ePVAC), being the first the preclinical stage of the latter.<sup>3</sup>

Exudative PVAC is usually unresponsive to intravitreal anti-vascular endothelial growth factor (VEGF) injections, but spontaneous resolution of intraretinal cystic spaces without any treatment has been reported.<sup>1,4</sup> Focal laser photocoagulation was also described as an effective treatment.<sup>5</sup>

In this report, we present the case of a patient with who was treated with one-month topical diclofenac therapy at another medical center

and demonstrated a resolution of exudation. The possible role of diclofenac topical therapy in this case is discussed.

### 2. Case report

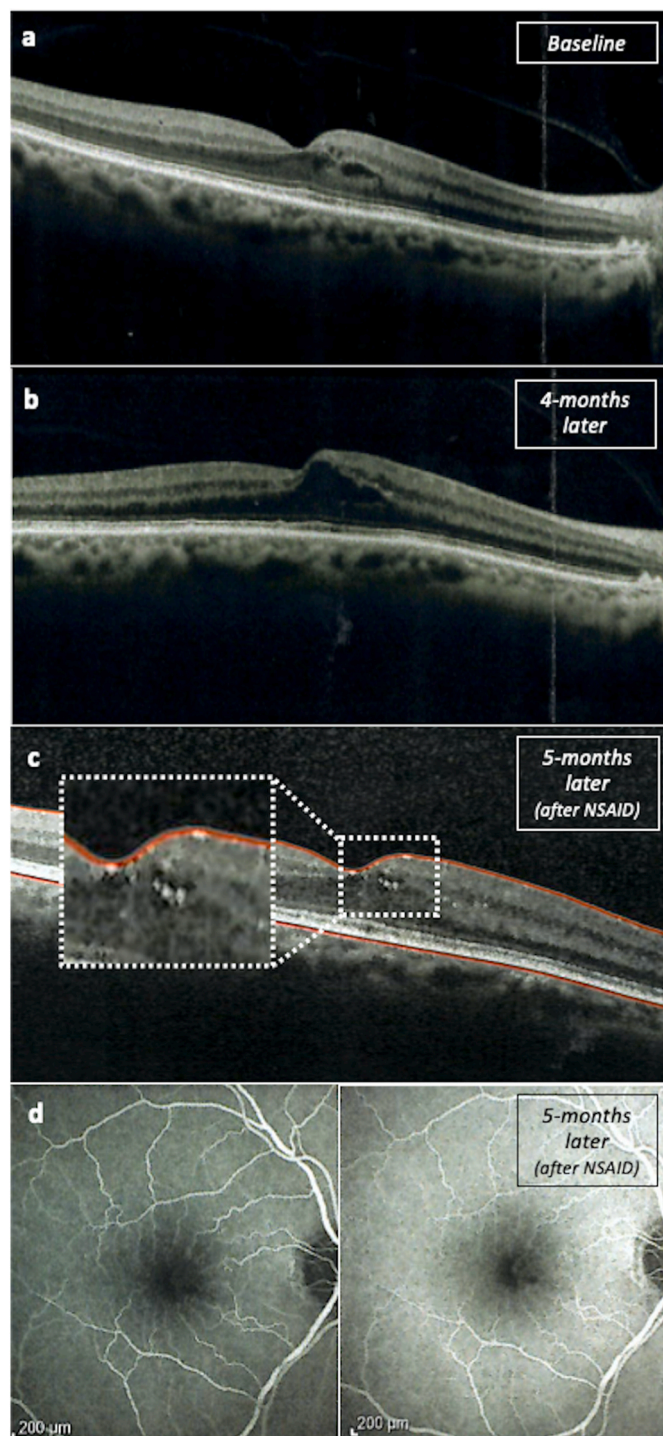
A 74-year-old man presented to the Medical Retina and Imaging Unit of San Raffaele Hospital (Milan, Italy) complaining of a visual decrease in his right eye (RE) lasting six months.

He was initially referred to another center, where he was evaluated with spectral domain-optical coherence tomography (SD-OCT) which showed the presence of perifoveal intraretinal cysts in the nasal macula in his RE. (Fig. 1a). No angiographic tests (fluorescein angiography, FA, or OCT angiography, OCTA) were performed by ophthalmologists of this center at first consultation. Four months later from baseline, repeated SD-OCT showed an increase in intraretinal cysts. (Fig. 1b).

Given the increase of intraretinal fluid, the patient was advised to start on topical diclofenac 0.1% drops twice a day for one month. Five months later from baseline, FA was performed (Fig. 1d), which, together with SD-OCT findings (Fig. 1c) led to the diagnosis of ePVAC. Interestingly, FA revealed a lack of perfusion of the large aneurysmal lesion associated with surrounding microvascular changes. However, due to the persistence of rare perifoveal intraretinal cysts and rare hard

\* Corresponding author. Department of Ophthalmology, San Raffaele Scientific Institute, Via Olgettina 60, Milan, 20132, Italy.

E-mail addresses: [querques.giuseppe@hsr.it](mailto:querques.giuseppe@hsr.it), [giuseppe.querques@hotmail.it](mailto:giuseppe.querques@hotmail.it) (G. Querques).



**Fig. 1.** Multimodal imaging of ePVAC in right eye at baseline and at follow-up examinations (from another center).

1a) Baseline structural OCT showing perifoveal intraretinal cysts in the nasal macula of right eye. 1b) Structural OCT performed four-months later showing an increase in intraretinal cysts. 1c) Structural OCT performed five months later from baseline, after one-month topical non steroidal anti-inflammatory drug. (White rectangle) Corresponding magnification of rare intraretinal cysts and hard exudates. 1d) Fluorescein angiography (FA) performed five months later from baseline, after one-month topical non steroidal anti-inflammatory drug. Early (left) and late phases (right) reveal a lack of perfusion of the large aneurysmal lesion associated with surrounding microvascular changes. ePVAC: exudative perifoveal vascular complex. NSAID: non steroidal anti-inflammatory drug.

exudates (Fig. 1c), he was suggested to start with a loading phase of 3 anti-VEGF injections.

The patient then decided to seek a second opinion and was referred to our center. At the time of presentation at our Medical Retina and Imaging Unit, BCVA was 20/25 in RE and 20/20 in LE. Anterior segment examination was unremarkable. Intraocular pressure measured with Goldmann applanation tonometry was 15 mmHg in both eyes. Fundus examination in RE revealed a perifoveal isolated large aneurysm, without signs of hemorrhages or hard exudates, while LE was normal. SD-OCT (performed with Spectralis, Heidelberg Engineering, Heidelberg, Germany) demonstrated a perifoveal round hyperreflective lesion surrounding a lumen containing variably reflective material in absence of hyporeflective exudation. (Fig. 2) Swept-source optical coherence tomography angiography (SS-OCTA) (performed with Plex Elite 9000, Zeiss Meditec, Inc, Dublin, California, USA) displayed an isolated large dilated aneurysmal lesion, without detectable flow signal in any capillary plexus. (Fig. 3)

Given the lack of clinical history of arterial hypertension, diabetes, or any other systemic or local vasculopathy, a diagnosis of resolved ePVAC in RE was made. The patient was then advised against undergoing the intravitreal antiangiogenic treatment and is being kept under close monitoring with multimodal retinal imaging.

### 3. Discussion

Although multimodal imaging has provided a better understanding of many retinal diseases, nowadays PVAC pathogenesis remains still unclear. Different hypotheses have been proposed.

PVAC may be consequence of focal endothelial cell injury, in patients not affected by other vascular or inflammatory disease.<sup>1,2</sup> Therefore, an increased endothelial damage may lead to exudation and progression from nePVAC to ePVAC.<sup>3</sup> Both perifoveal aneurysm and perilesional capillaries rarefaction seem to result from pericytes loss, in particular from breakdown of pericytes' basement membrane by matrix metalloproteinase-9.<sup>6</sup> Thus, PVAC genesis would be not regulated by VEGF, but by the imbalance between a reduced wall strength and an increased wall tension, in accordance with Laplace's law.<sup>7</sup> Notably, perilesional microvascular rarefaction has been associated to an impaired angiogenesis<sup>8</sup> and local ageing.<sup>9,10</sup>

A glial cell-driven genesis, secondary to Müller cells necrosis, has been postulated to explain a case of concomitant PVAC and lamellar hole-associated epiretinal proliferation.<sup>11</sup>

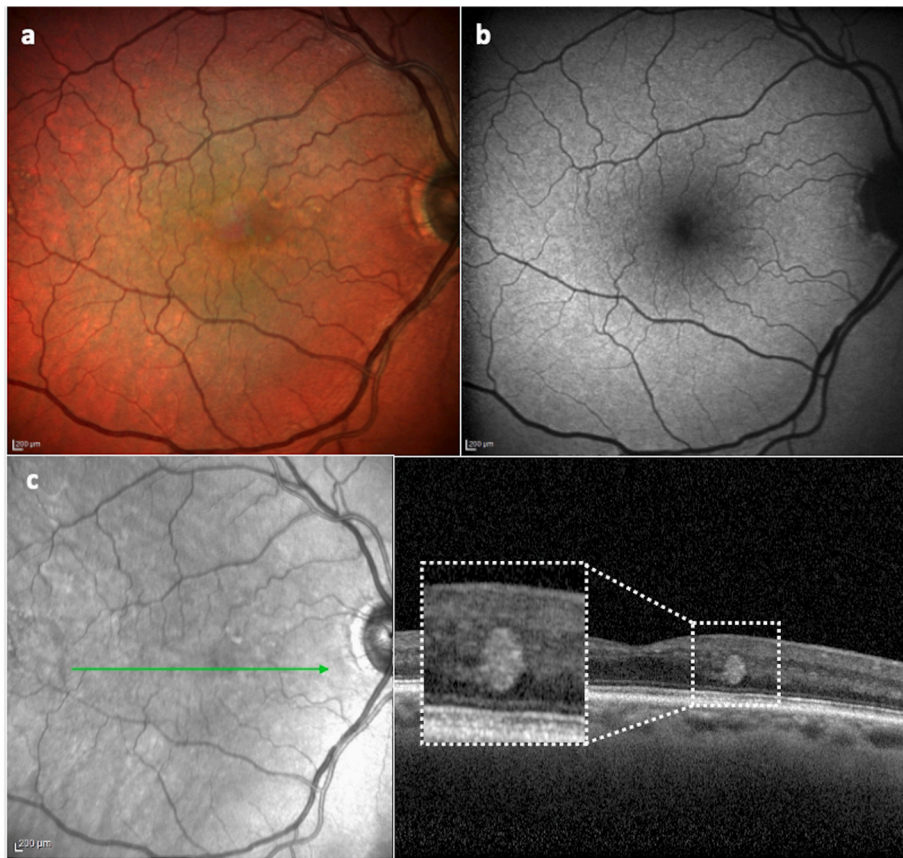
In addition, PVAC could be a response to anatomical variation, in particular to prepapillary arterio-arterial loop, in chronic slow flow retinopathy.<sup>12</sup>

In this report, we present the case of a patient with PVAC who was treated with topical non-steroidal anti-inflammatory (NSAID) therapy and demonstrated a progressive resolution of exudation.

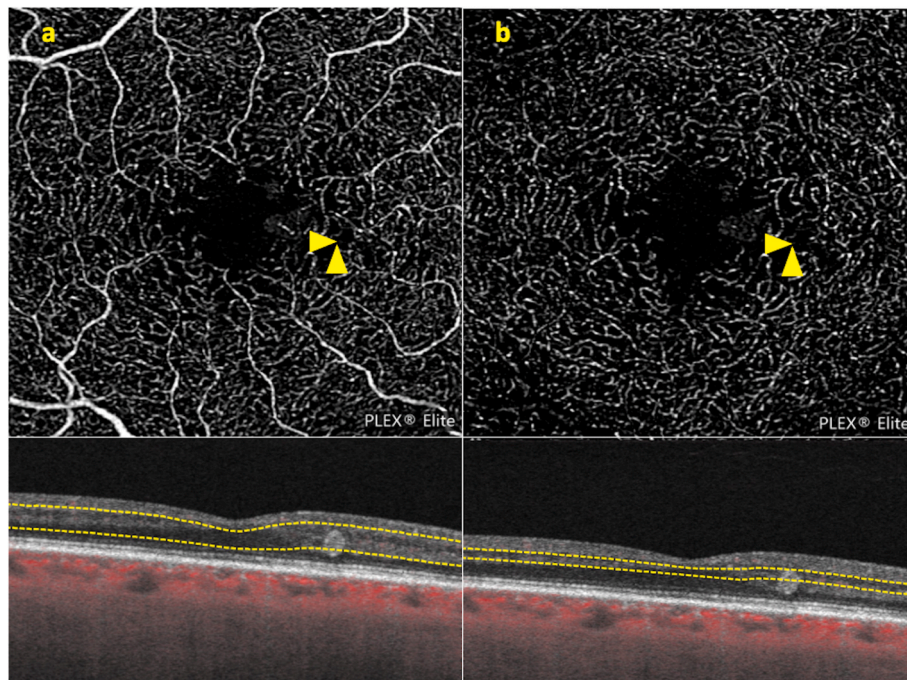
NSAIDs are one of the most common prescribed class of medications.

Management of pseudophakic cystoid macular edema, post-operative pain after refractive surgery, allergic conjunctivitis, and prevention of miosis during intraocular surgery are some of on-label ophthalmological clinical uses of topical NSAIDs. As off-label medications, NSAID have been shown to be beneficial in the treatment of diabetic retinopathy, ocular tumors, post-retinal vein occlusion, and neovascular age-related macular degeneration.<sup>13</sup>

NSAIDs inhibit expression of cyclooxygenase (COX) enzymes isoforms (COX-1, COX-2) and their products, namely prostaglandins (PGs) and thromboxanes (TXs). Normally, PGs acts as vasodilating agents, so that their inhibition causes blood-retina barrier disruption, leukocyte migration, and therefore inflammation and edema.<sup>14</sup> Increasing evidence suggests that NSAIDs might also prove efficient as anti-angiogenic drugs. Recent clinical and experimental studies have demonstrated that COX-2 promotes angiogenesis.<sup>15</sup> Interestingly, Chang et al demonstrated a positive correlation between known angiogenic regulatory genes (VEGF, Ang2, Flt-1, Tie2) and COX-2 over-expression.<sup>16</sup> Thus,



**Fig. 2.** Multimodal imaging of nePVAC at follow-up examination. (2a) Multicolor. (2b) Blue-autofluorescence. (2c) Combined infrared reflectance imaging (IR) and structural OCT showing a perifoveal round hyperreflective lesion surrounding a lumen containing variably reflective material, in absence of hyporeflective exudation. (White rectangle) Corresponding magnification of perifoveal round hyperreflective lesion. NePVAC: non exudative exudative perifoveal vascular complex. (For interpretation of the references to color in this figure legend, the reader is referred to the Web version of this article.)



**Fig. 3.** OCT-angiography of nePVAC at follow-up examination, displaying an isolated large dilated aneurysmal lesion, without detectable flow signal in superficial (3a) and deep (3b) retinal capillary plexus. nePVAC: non exudative perifoveal vascular complex.

COX-2 pathway might induce anti-angiogenic genes' expression, such as Ang2 and Tie2. NSAIDs impact on angiogenic cascade could explain the supposed beneficial effect of topical diclofenac in reducing our case of

exudative perifoveal vascular aneurysm complex.

Interestingly, topical NSAIDs together with topical steroids may lead to long-term resolution of cystoid macular edema secondary to

idiopathic macular telangiectasia type 1.<sup>17</sup>

However, given the fact that there is no definitive evidence proving beyond doubt the role of diclofenac in reducing macular edema, including exudation from PVAC, there is clearly a possibility that the reduction in intraretinal exudation in our case was not related to any therapeutic effect of diclofenac, but rather occurred as a coincident event.

#### Patient consent

The patient provided written informed consent for publication of this case report and any accompanying images.

#### Funding

No funding or grant support.

#### Authorship

All authors attest that they meet the current ICMJE criteria for Authorship.

#### Declaration of competing interest

Beatrice Tombolini, Michele Cavalleri, Ilaria Zucchiatti, Lea Querques: none.

Riccardo Sacconi: consultant for Bayer Shering-Pharma (Berlin, Germany), Novartis (Basel, Switzerland), Zeiss (Dublin, USA).

Francesco Bandello consultant for: Alcon (Fort Worth, Texas, USA), Alimera Sciences (Alpharetta, Georgia, USA), Allergan Inc (Irvine, California, USA), Farmila-Thea (Clermont-Ferrand, France), Bayer Shering-Pharma (Berlin, Germany), Bausch And Lomb (Rochester, New York, USA), Genentech (San Francisco, California, USA), Hoffmann-La-Roche (Basel, Switzerland), NovagaliPharma (Évry, France), Novartis (Basel, Switzerland), Sanofi-Aventis (Paris, France), Thrombogenics (Heverlee, Belgium), Zeiss (Dublin, USA).

Giuseppe Querques consultant for: Alimera Sciences (Alpharetta, Georgia, USA), Allergan Inc (Irvine, California, USA), Bayer Shering-Pharma (Berlin, Germany), Heidelberg (Germany), Novartis (Basel, Switzerland), Sandoz (Berlin, Germany), Zeiss (Dublin, USA).

#### References

1. Sacconi R, Freund KB, Yannuzzi LA, et al. The expanded spectrum of perifoveal exudative vascular anomalous complex. *Am J Ophthalmol.* 2017;184:137–146. <https://doi.org/10.1016/j.ajo.2017.10.009>.
2. Querques G, Kuhn D, Massamba N, Leveziel N, Querques L, Souied EH. Perifoveal exudative vascular anomalous complex. *J Fr Ophthalmol.* 2011;34(8):559.e1–559.e4. <https://doi.org/10.1016/j.jfo.2011.03.002>.
3. Sacconi R, Borrelli E, Satta SV, et al. Nonexudative perifoveal vascular anomalous complex: the subclinical stage of perifoveal exudative vascular anomalous complex? *Am J Ophthalmol.* 2020;218:59–67. <https://doi.org/10.1016/j.ajo.2020.04.025>.
4. Sacconi R, Borrelli E, Bandello F, Querques G. Perifoveal exudative vascular anomalous complex in a highly myopic eye. *Ther Adv Ophthalmol.* 2020;12, 251584142094793. <https://doi.org/10.1177/2515841420947930>.
5. Mrejen S, Le HM, Nghiem-Buffer S, Tabary S, Quentel G, Cohen SY. Insights into perifoveal exudative vascular anomalous complex. *Retina.* 2020;40(1):80–86. <https://doi.org/10.1097/IAE.0000000000002435>.
6. Smid LM, Verhoekx JSN, Martinez Ciriano JP, Vermeer KA, Yzer S. Multimodal imaging comparison of perifoveal exudative vascular anomalous complex and resembling lesions. *Acta Ophthalmol.* 2021;99(5):553–558. <https://doi.org/10.1111/aos.14650>.
7. Spaide RF, Barquet LA. Retinal capillary macroaneurysms. *Retina.* 2019;39(10):1889–1895. <https://doi.org/10.1097/IAE.0000000000002406>.
8. Goligorsky MS. Microvascular rarefaction: the decline and fall of blood vessels. *Organogenesis.* 2010;6(1):1–10. <https://doi.org/10.4161/org.6.1.10427>.
9. Verhoekx JSN, Smid LM, Vermeer KA, Martinez Ciriano JP, Yzer S. Anatomical changes on sequential multimodal imaging in perifoveal exudative vascular anomalous complex. *Retina.* 2021;41(1):162–169. <https://doi.org/10.1097/IAE.0000000000002809>.
10. Azemin MZC, Kumar DK, Wong TY, et al. Age-related rarefaction in the fractal dimension of retinal vessel. *Neurobiol Aging.* 2012;33(1):194.e1–194.e4. <https://doi.org/10.1016/j.neurobiolaging.2010.04.010>.
11. Siedlecki J, Vounotrypdis E, Vogt D, Wolf A, Priglinger SG, Schumann RG. Lamellar hole-associated epiretinal proliferation presenting with perifoveal exudative vascular anomalous complex. *Am J Ophthalmol Case Reports.* 2019;14(July 2018):112–116. <https://doi.org/10.1016/j.ajoc.2019.03.008>.
12. Ayachit AG, Sacconi R, Ayachit GS, Joshi S, Querques G. Perifoveal exudative vascular anomalous complexlike lesion as a complication of prepapillary arterial loops. *Ophthalmic Surg Lasers Imaging Retin.* 2018;49(12):974–978. <https://doi.org/10.3928/23258160-20181203-11>.
13. Russo A, Costagliola C, Delcassi L, et al. Topical nonsteroidal anti-inflammatory drugs for macular edema. *Mediat Inflamm.* 2013;2013. <https://doi.org/10.1155/2013/476525>.
14. Semeraro F, Russo A, Gambicorti E, et al. Efficacy and vitreous levels of topical NSAIDs. *Exp Opin Drug Deliv.* 2015;12(11):1767–1782. <https://doi.org/10.1517/17425247.2015.1068756>.
15. Monnier Y, Zaric J, Rüegg C. Inhibition of angiogenesis by non-steroidal anti-inflammatory drugs: from the bench to the bedside and back. *Curr Drug Targets - Inflamm Allergy.* 2005;4(1):31–38. <https://doi.org/10.2174/1568010053622975>.
16. Chang SH, Liu CH, Conway R, et al. Role of prostaglandin E2-dependent angiogenic switch in cyclooxygenase 2-induced breast cancer progression. *Proc Natl Acad Sci U S A.* 2004;101(2):591–596. <https://doi.org/10.1073/pnas.2535911100>.
17. Dunn EN, Gregori NZ, Goldhardt R. Phakic cystoid macular edema secondary to idiopathic macular telangiectasia type 1 responsive to topical anti-inflammatory agents. *Semin Ophthalmol.* 2013;28(2):84–87. <https://doi.org/10.3109/08820538.2012.760615>.