

# Lurbinectedin improves macular edema in a case of central retinal vein occlusion<sup>☆</sup>

Filippo Simona<sup>a</sup>, Feliciano Menna<sup>a</sup>, Luciano Wannesson<sup>b</sup>, Alessandro Meduri<sup>c</sup>,  
Gabriella De Salvo<sup>d</sup>, Giuseppe Querques<sup>e,\*</sup>

<sup>a</sup> PAX Eye Center, Locarno, Switzerland

<sup>b</sup> Istituto Oncologico della Svizzera Italiana (IOSI), Bellinzona, Switzerland

<sup>c</sup> Biomedical, Dental and Morphological and Functional Images Sciences, Department, University of Messina, Messina, Italy

<sup>d</sup> Ophthalmology Department, University Hospital Southampton Foundation Trust, Southampton, United Kingdom

<sup>e</sup> IRCCS San Raffaele Scientific Institute, University Vita-Salute, Milan, Italy

## ARTICLE INFO

### Keywords

1-central retinal vein occlusion

Keyword 2-lurbinectedin

Keyword 3- macular edema

Keyword 4

Natural anticancer drugs

Keyword 5

Optical coherence tomography

## ABSTRACT

**Purpose:** To evaluate the response to lurbinectedin in a case of macular edema, secondary to central retinal vein occlusion (CRVO). Serial spectral domain optical coherence tomography (SD-OCT) scans were taken in a 70-year-old man with a 24-month history of macular edema secondary to CRVO in the right eye. The patient underwent 5 cycles of chemotherapy with lurbinectedin between October 2018 and May 2019. Central macular thickness (CMT) before and after each chemotherapy cycle was measured together with progression analysis using the CIRRUS Zeiss software.

**Observations:** SD-OCT showed alternating recurrence and resolution of macular edema closely related to the chemotherapy administrations. CMT oscillated between 496 and 284  $\mu\text{m}$  during the follow-up. The macular edema was showed to decrease as soon as 4 days following chemotherapy.

**Conclusions and importance:** Resolution of macular edema associated with CRVO was seen in our patient whilst undergoing chemotherapy with lurbinectedin. Lurbinectedin may play a role in the treatment of macular edema secondary to CRVO and may open new therapeutic indication for this natural marine molecule.

## 1. Introduction

Retinal vein occlusions (RVOs) are one of the most common causes of acquired retinal vascular abnormality in adults and a frequent cause of visual loss.<sup>1</sup>

Treatments for macular edema (ME) associated with RVO includes intravitreal injections of anti-vascular endothelial growth factor (VEGF) and implants of corticosteroids, hyperbaric oxygenation, pars plana vitrectomy, arteriovenous sheathotomy, chorioretinal anastomosis, thrombolysis, intravitreal injections of plasmin, and grid laser photocoagulation. All the above treatments have a different mechanism of action.<sup>2-9</sup>

Despite many available treatments, a few patients with ME are considered non-responders with resistant or recalcitrant ME. Hence, different approaches such as intravitreal tissue plasminogen activator

injections have been tried.<sup>10</sup>

In this report we describe a case of ME secondary to central retinal vein occlusion (CRVO), responding to intravenous treatment with lurbinectedin, a selective inhibitor of oncogenic transcription used to treat patients with small-cell lung cancer (SCLC).

### 1.1. Case report

We present a case of a 70-year-old man with a 24-month history of ME secondary to central retinal vein occlusion (CRVO) in the right eye, referred to the PAX Eye Center while participating to a phase II clinical study (PM1183-B-005-14, PharmaMar, Spain).

The patient's past medical history included untreated essential hypertension, chronic obstructive pulmonary disease, monoclonal gammopathy of undetermined significance, hepatitis C, tuberculosis,

<sup>☆</sup> Doctor De Salvo received consultancy fees from Allergan Abbvie, Apellis, Bayer, Boehringer Ingelheim, Heidelberg Engineering, Novartis, Roche and Teva outside this work. Dr Querques received fees are listed above.

\* Corresponding author. Department of Ophthalmology Università Vita-Salute IRCCS Ospedale San Raffaele, Via Olgettina 60, 20132, Milan, Italy.

E-mail address: [giuseppe.querques@hotmail.it](mailto:giuseppe.querques@hotmail.it) (G. Querques).

<https://doi.org/10.1016/j.ajoc.2022.101743>

Received 18 June 2022; Received in revised form 23 October 2022; Accepted 1 November 2022

Available online 6 November 2022

2451-9936/© 2022 The Authors. Published by Elsevier Inc. This is an open access article under the CC BY-NC-ND license (<http://creativecommons.org/licenses/by-nc-nd/4.0/>).

aneurysm of the left anterior cerebral artery. He was a smoker (61 packages of cigarettes in the last year). His past ocular history included blepharitis.

The multicenter study was designed to assess the efficacy and safety of lurbinectedin as second-line treatment of advanced, metastatic SCLC and was conducted at the Oncology Institute of Southern Switzerland (IOSI) in Bellinzona, Switzerland.

The diagnosis of limited-disease SCLC was made in February 2017. The patient underwent bi-modal treatment with chemoradiation until May 2017 with a curative intent; however, the disease relapsed one year after the completion of the treatment plan.

In November 2017, before the disease relapse, the patient developed CRVO with ME in the right eye (OD) (Fig. 1) for which he underwent 3 monthly injections of ranibizumab (Lucentis®, Novartis, Basel, Switzerland) in another practice in Switzerland.

The patient was then referred to our PAX Eye Center (July 2018) (Fig. 2) due to recurrent ME for which he underwent a further ranibizumab injection. On referral, visual acuity (VA) was 20/32 OD and 20/20 left eye (OS). Intraocular pressure (IOP) was 12 mmHg OD and 13 mmHg OS. Anterior segment was unremarkable in both eyes.

On the follow-up scheduled date in August 2018, a spectral domain optical coherence tomography (SD-OCT) performed revealed resolution of the ME following the injection (Fig. 2). Whereas further follow-up (October 2018) showed recurrence of intraretinal fluid at SD-OCT; no further intravitreal injections with ranibizumab were allowed by the treating oncologists to avoid potential confusion in case of development of ocular adverse reactions. Meanwhile, intravenous therapy with lurbinectedin 5.76 mg was started by the oncology department; unexpected, complete resolution of ME was noted at DS-OCT eleven days following the start of the systemic treatment. At that point, patient underwent monthly follow-ups including VA measurements and SD-OCT macular scans. Remarkably, an alternating pattern of recurrence-and-resolution of the ME was noted during 1-year follow-up. This behavior was clearly related to the lurbinectedin administrations (Fig. 3a – e and 4).

## 2. Discussion

In this report we describe the response to lurbinectedin in an eye affected by ME secondary to CRVO.

The patient presented with a few cardiovascular risks which could have been the cause of the CRVO. Nevertheless, a paraneoplastic cause linked to the metastatic SCLC could not be excluded.

Following the diagnosis of CRVO, ophthalmic reviews were arranged monthly. During the follow ups visits we noticed alternating recurrence and resolution of the edema, strictly related to his chemotherapy sessions.

Lurbinectedin is a natural marine molecule isolated from the Caribbean algae “*Ecteinascidia turbinata*”, approved for the treatment of

advanced soft tissue sarcoma. This agent exhibits a potent anti-proliferative activity by covalently binding to small DNA grooves that induce rupture in double-stranded DNA, thus leading to cellular apoptosis. Lurbinectedin is currently investigated in phase II clinical trials for the treatment of SCLC, breast, ovarian and uterine cancers.<sup>11–13</sup>

All patients in the clinical trial were treated with 3.2 mg/m<sup>2</sup> lurbinectedin administered as a 1-h intravenous infusion once every 3 weeks. Treatment was given until disease progression as defined by the RECIST (response criteria in solid tumors), or unacceptable toxicity to 2.0 mg/m<sup>2</sup> (as per investigator decision). Patients were seen at the Oncology Clinic at every lurbinectedin cycle and radiological assessments (CT scan or MRI) were done every 6 weeks until cycle 6, and every 9 weeks thereafter.

Lurbinectedin belongs to the category of alkaloids of marine origin. It is structurally related to trabectedin, from which however differs in the C ring due to the presence of a tetrahydro-β-carboline instead of a tetrahydroisokinoline. The alkaloids of marine origin are part of the large class of chemotherapeutic drugs with antimetabolic action of natural origin, including vincristine, already known for its effective action in the treatment of retinoblastoma.<sup>14</sup>

Alkaloids and taxanes interrupt cell-division by alteration of the microtubule dynamics, causing the inhibition of tubulin polymerization with a consequent arrest of the cell cycle in the G2/M phases, with a consequent cell death.

The alkaloids are produced by algae from amino acids and are thought to be synthesized with defensive purposes or may derive from the metabolism of toxic substances or to stimulate growth as sources of nitrogen. In fact, regarding their function in the plant physiology, different opinions are found in the literature.<sup>15</sup> Some authors attribute to these molecules a detoxifying action, hypothesizing that harmful substances are eliminated through their synthesis; other authors attribute them a nitrogen repository function and finally, the purpose of protecting the algae from external agents.<sup>16,17</sup> These compounds contain basic nitrogen and have been used by humans since ancient times, having effects like codeine and morphine.<sup>18,19</sup>

The anti-inflammatory action has already been scientifically proved for the equivalent compound, trabectedin<sup>20</sup> but reports on the positive effect of lurbinectedin on ME have not yet been described. Therefore, we speculate that the concomitant resolution of ME in our patient may be linked to the lurbinectedin anti-inflammatory action.

Despite its beneficial chemo-therapeutic and anti-inflammatory effects, patients receiving lurbinectedin may develop side effects. The most common reported on the Basket trial<sup>21</sup> were leukopenia (29%), neutropenia (46%), thrombocytopenia (7%), increased level of γ-glutamyl transferase (GTT, 15%), fatigue (7%) and febrile neutropenia (5%).

In the context of natural anticancer agents that could be useful to treat ocular pathologies, only the action of fucoidan, a sulfated polysaccharide with a high content of L-fucose, which can be extracted from brown algae and marine invertebrates, has been previously described. The study, conducted on retinas of diabetic mice, showed that the fucoidan downregulates the HIF-1α/VEGF signaling pathway and showed a reduction in VEGF expression even after combined use of fucoidan and bevacizumab.<sup>22,23</sup> An anti-VEGF mechanism of action has yet to be proven for lurbinectedin.

In conclusion, our case study suggests a new possible beneficial anti-edematous effect of lurbinectedin on ME associated with CRVO. Further studies need to be conducted to identify the most promising candidates and to investigate the effect of lurbinectedin in this cohort of patients.

## Funding

No funding or grant support.

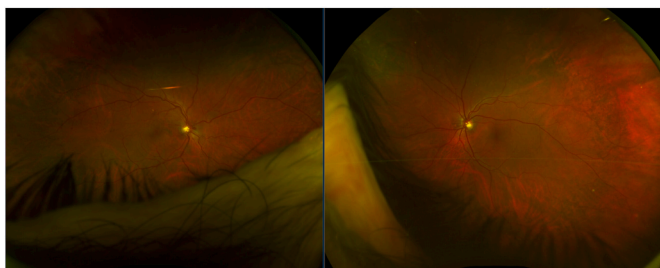
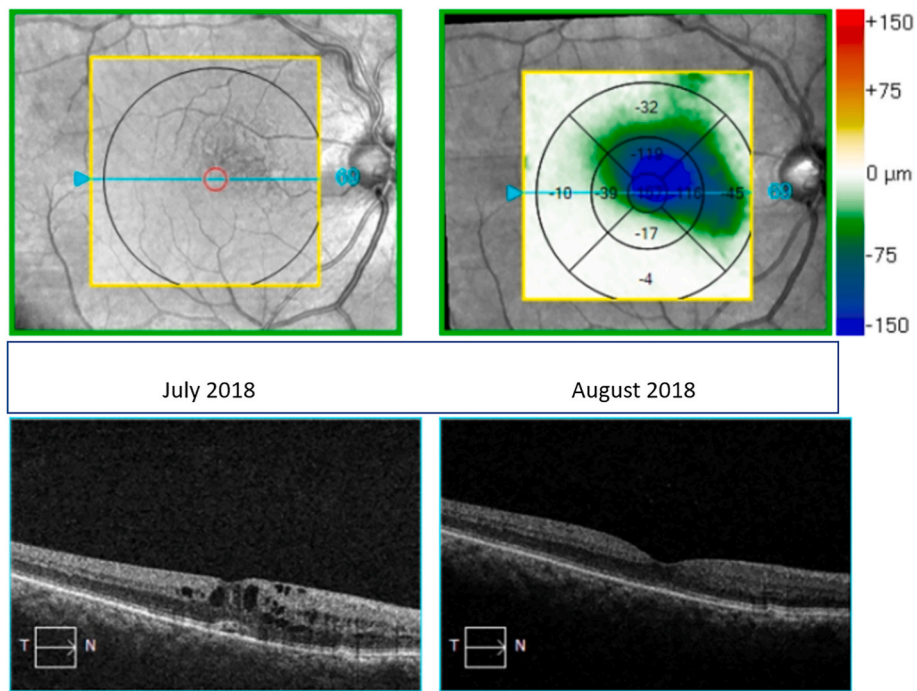
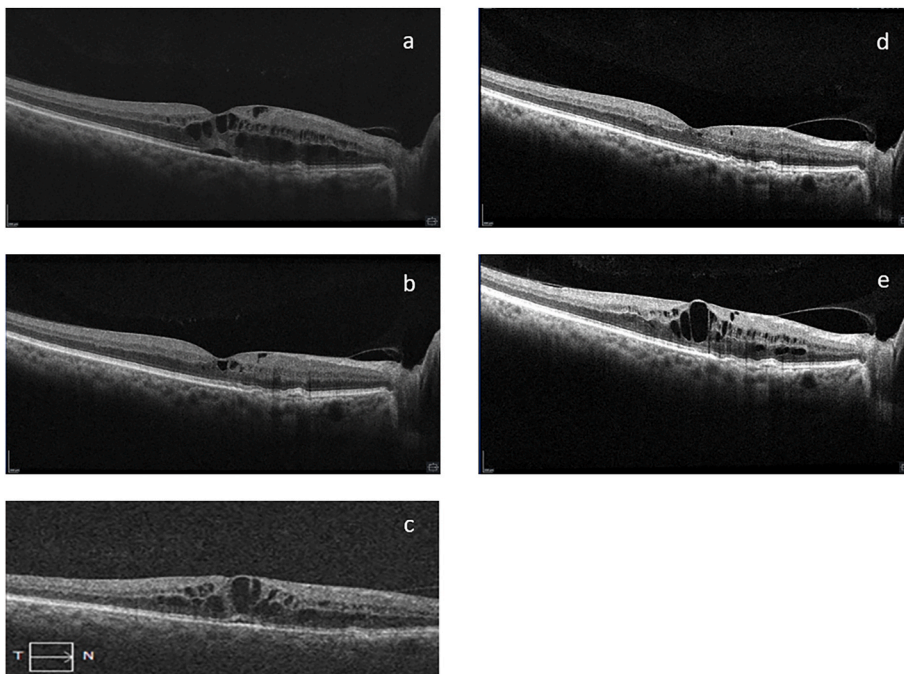


Fig. 1. Fundus color photo at presentation (July 2018) showing vascular tortuosity without intraretinal hemorrhages in the right eye (RE), and absence of retinal changes in the left eye. Note the hemorrhage on the nasal aspect of the optic nerve. (For interpretation of the references to color in this figure legend, the reader is referred to the Web version of this article.)



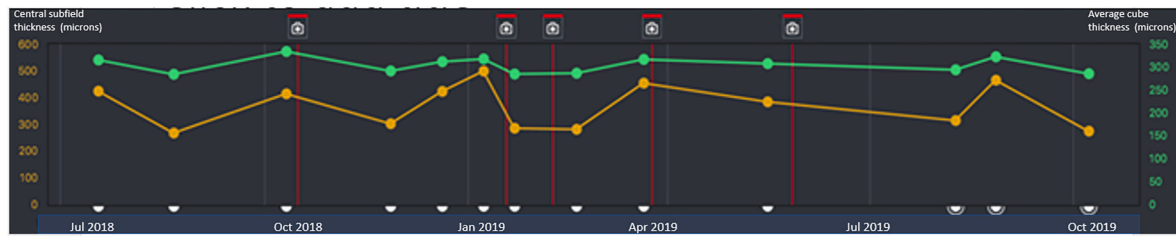
**Fig. 2.** On the left, spectral domain optical coherence tomography (SD-OCT) right eye showing increased intraretinal thickness caused by slight edema secondary to central retinal vein occlusion (July 2018). On the right, SD-OCT showing resolution of the edema in the right eye (August 2018).



**Fig. 3.** Spectral domain optical coherence tomography showing alternating recurrence and resolution of macular edema (ME) strictly related to the chemotherapy sessions. Note also the presence of drusen.  
**3a** – ME before treatment with lurbinectedin (October 2018), with central macular thickness (CMT) of 413  $\mu\text{m}$   
**3b** – resolution of ME 11 days post treatment with lurbinectedin, CMT of 300  $\mu\text{m}$   
**3c** – recurrence of ME before treatment with lurbinectedin (January 2019), CMT of 496  $\mu\text{m}$   
**3d** – resolution of ME 4 days following treatment with lurbinectedin, CMT reduced to 284  $\mu\text{m}$   
**3e** – recurrence of ME before further treatment with lurbinectedin, CMT increased to 449  $\mu\text{m}$ .

**Doctor querques received fees from**

- Alimera Sciences, Inc: Consultant/Advisor
- Allegro: Advisor
- Allergan: Consultant/Advisor
- Apellis: Consultant/Advisor
- Baush & Lomb: Consultant
- Bayer Healthcare Pharmaceuticals: Consultant/Advisor
- Boehringer Ingelheim: Advisor
- CenterVue: Consultant/Advisor
- Heidelberg Engineering: Consultant/Advisor
- Lumithera: Advisor
- Nevacar: Advisor
- Novartis Pharmaceuticals Corporation: Consultant/Advisor
- Roche: Consultant/Advisor
- SIFI: Advisor/Consultant
- Sooft/Fidia: Consultant
- Topcon: Consultant
- Thea: Consultant
- Zeiss: Consultant/Advisor



**Fig. 4.** Spectral domain optical coherence tomography progression analysis. Red lines: Chemotherapy sessions with lurbinectedin (16.10.2018, 18.1.2019, 8.2.2019, 25.3.2019, 27.5.2019); Green line: the central subfield thickness (average retinal thickness in a disc-shaped region of 1 mm diameter centered on the fovea); Yellow line: the average cube thickness (macular thickness map using a macular cube 512 × 128). Note the decrease of the ME following the chemotherapy sessions. (For interpretation of the references to color in this figure legend, the reader is referred to the Web version of this article.)

### Patient consent

Consent given by patient to use anonymized clinical details within the settings of the Lurbinectedin clinical trial.

### Authorship

All authors attest that they meet the current ICMJE criteria for Authorship.

### Declaration of competing interest

The authors have no proprietary or commercial interest in any materials

Discussed in this article.

No conflicting relationship exists for any author.

No competing interests among authors.

### Acknowledgements

None.

### References

- Rogers S, McIntosh RL, Cheung N, et al. The prevalence of retinal vein occlusion: pooled data from population studies from the United States, Europe, Asia, and Australia. *Ophthalmology*. 2010;117:313–319.
- Spaide RF, Lee JK, Klancnik JM, Gross NE. Optical coherence tomography of branch retinal vein occlusion. *Retina*. 2003;23:343–347.
- Stefansson E. Treatment of branch retinal vein occlusion. *Acta Ophthalmol*. 2008;86:122–123.
- The Central Vein Occlusion Study Group N Report. A randomized clinical trial of early panretinal photocoagulation for ischemic central vein occlusion. *Ophthalmology*. 1995;102:1434–1444.
- Thompson JT. What is the role of vitrectomy for macular edema from branch retinal vein occlusion? *Am J Ophthalmol*. 2004;138:1037–1038.
- Mandelcorn MS, Nrusimhadevara RK. Internal limiting membrane peeling for decompression of macular edema in retinal vein occlusion: a report of 14 cases. *Retina*. 2004;24:348–355.
- Penfold PL, Wen L, Madigan MC, Gillies MC, King NJC, Provis JM. Triamcinolone acetonide modulates permeability and intercellular adhesion molecule-1 (ICAM-1) expression of the ECV304 cell line: implications for macular degeneration. *Clin Exp Immunol*. 2000;121:458–465.
- Jonas JB. Intravitreal triamcinolone acetonide for treatment of intraocular oedematous and neovascular diseases. *Acta Ophthalmol Scand*. 2005;83:645–663.
- Sakuma T, Mizota A, Inoue J, Tanaka M. Intravitreal injection of autologous plasmin enzyme for macular edema associated with branch retinal vein occlusion. *Am J Ophthalmol*. 2010;150:876–882.
- Glacet-Bernard A, Kuhn D, Vine AK, Oubraham H, Coscas G, Soubrane G. Treatment of recent onset central retinal vein occlusion with intravitreal tissue plasminogen activator: a pilot study. *Br J Ophthalmol*. 2000;84:609–613.
- Cruz, Llop-Guevara, Garber Arun, Serra. Multicenter phase II study of lurbinectedin in BRCA-Mutated and unselected metastatic advanced breast cancer and biomarker assessment substudy. *J Clin Oncol*. 2018;36(31):3134–3143.
- Vidal Muñoz C, Guillén MJ, Moretó J, Puertas S, Martínez-Iniesta M, Figueras A. Lurbinectedin (PM01183), a new DNA minor groove binder, inhibits growth of orthotopic primary graft of cisplatin-resistant epithelial ovarian cancer. *Clin Cancer Res*. 2012 Oct;18(19):5399–5411.
- Yokoi Mabuchi, Shimura. Lurbinectedin (PM01183), a selective inhibitor of active transcription, effectively eliminates both cancer cells and cancer stem cells in preclinical models of uterine cervical cancer. *Invest N Drugs*. 2019 Oct;37(5):818–827.
- Malik RK, Friedman HS, Djang WT, et al. Treatment of trilateral retinoblastoma with vincristine and cyclophosphamide. *Am J Ophthalmol*. 1986;102(5):650–656.
- Allavena P, Signorelli M, Chieppa M, et al. Anti-inflammatory properties of the novel antitumor agent yondelis (trabectedin): inhibition of macrophage differentiation and cytokine production. *Cancer Res*. 2005;65(7):2964–2971.
- Eguchi R, Ono N, Hirai Morita A, et al. Classification of alkaloids according to the starting substances of their biosynthetic pathways using graph convolutional neural networks. *BMC Bioinf*. 2019;20:380.
- Megharaj M, Madhavi DR, Sreenivasulu C, Umamaheswari A, Venkateswarlu. Biodegradation of methyl parathion by soil isolates of microalgae and cyanobacteria. *Bull Environ Contam Toxicol*. 1994;53:292–297.
- Harwood L, Guschina IA. The versatility of algae and their lipid metabolism. *Biochimie*. 2009;91(6):679–684.
- Güven KC, Bora A, Sunam G. Alkaloid content of marine algae. I. Hordenine from *Phyllophora nervosa*. *Eczacılik Bul*. 1969;11:177–184.
- Güven KS, Percot A, Sezik E. Alkaloids in marine algae. *Mar Drugs*. 2010;8(2):269–284.
- Trigo J, Subbiah V, Besse B, et al. Lurbinectedin as second-line treatment for patients with small-cell lung cancer: a single-arm, open-label, phase 2 basket trial. *Lancet Oncol*. 2020;21:645–654.
- Cugati S, Chen CS, Lee AW. Fingolimod and macular edema. Pathophysiology, diagnosis, and management. *Neurol Clin Pract*. 2014 Oct;4(5):402–409.
- Klettner A. Fucoidan as a potential therapeutic for major blinding diseases: a hypothesis. *Mar Drugs*. 2016;14(2):31.