
Melanoma clinicopathological groups characterized and compared with dermoscopy and reflectance confocal microscopy



Cristina Faldetta, MD,^a Shaniko Kaleci, PhD,^a Johanna Chester, BA, BBS,^a Cristel Ruini, MD,^{b,c} Silvana Ciardo, BS,^a Marco Manfredini, MD,^a Stefania Guida, MD, PhD,^{d,c} Camilla Chello, MD,^c Carmen Cantisani, MD, PhD,^c Jade N. Young, BS,^f Patricia Cabral, MD,^f Nicholas Gulati, MD, PhD,^f Emma Guttman-Yassky, MD, PhD,^f Giovanni Pellacani, MD,^c and Francesca Farnetani, MD^a

Background: Dermoscopic and reflectance confocal microscopy (RCM) correlations between morphologic groups of melanoma have not yet been described.

Objective: Describe and compare dermoscopic and RCM features of cutaneous melanomas with histopathological confirmation.

Methods: Single center, retrospective analysis of consecutive melanomas evaluated with RCM (2015-2019). Lesions were clinically classified as typical, nevus-like, amelanotic/nonmelanoma skin cancer (NMSC)-like, seborrheic keratosis (SK)-like and lentigo/lentigo maligna (LM)-like. Presence or absence of common facial and nonfacial melanoma dermoscopic and RCM patterns were recorded. Clusters were compared with typical lesions by multivariate logistic regression.

Results: Among 583 melanoma lesions, significant differences between clusters were evident (compared to typical lesions). Observation of dermoscopic features (>50% of lesions) in amelanotic/NMSC-like lesions consistently displayed 3 patterns (atypical network, atypical vascular pattern + regression structures), and nevus-like and SK-like lesions and lentigo/LM-like lesions consistently displayed 2 patterns (atypical network + regression structures, and nonevident follicles + heavy pigmentation intensity). Differences were less evident with RCM, as almost all lesions were consistent with melanoma diagnosis.

Limitations: Small SK-like lesions sample, single RCM analyses (no reproduction of outcome).

Conclusion: RCM has the potential to augment our ability to consistently and accurately diagnose melanoma independently of clinical and dermoscopic features. (J Am Acad Dermatol 2024;90:309-18.)

From the Dermatology Clinic, University of Modena and Reggio Emilia, Modena, Italy^a; Department of Dermatology and Allergy, University Hospital, LMU Munich, Munich, Germany^b; Dermatology Clinic, Department of Clinical Internal, Anesthesiological and Cardiovascular Sciences, Sapienza University of Rome, Rome, Italy^c; School of Medicine Vita Salute San Raffaele University, Milan, Italy^d; Dermatologic Clinic, IRCCS San Raffaele Scientific Institute, Milan, Italy^e; and Department of Dermatology, Mount Sinai, New York, New York.^f

Funding sources: The research leading to these results has received funding from the European Union - NextGenerationEU through the Italian Ministry of University and Research under PNRR - M4C2-11.3 Project PE_00000019 HEAL ITALIA to Francesca Farnetani CUP E93C22001860006.

Disclaimer: The views and opinions expressed are those of the authors only and do not necessarily reflect those of the European Union or the European Commission. Neither the

European Union nor the European Commission can be held responsible for them.

Patient consent: Not applicable.

IRB approval status: IRB of University of Modena and Reggio Emilia approved the study. Protocol number 0008852/20.

Accepted for publication September 25, 2023.

Correspondence to: Francesca Farnetani, MD, Professor, Dermatology Clinic, University of Modena and Reggio Emilia, Via Del Pozzo 71, 41124 Modena, Italy. E-mail: farnetani.francesca@gmail.com.

Published online November 19, 2023.

0190-9622

© 2023 by the American Academy of Dermatology, Inc. Published by Elsevier Inc. This is an open access article under the CC BY license (<http://creativecommons.org/licenses/by/4.0/>).

<https://doi.org/10.1016/j.jaad.2023.09.084>

Key words: dermoscopy; histology; histopathology; melanoma; melanoma features; RCM; reflectance confocal microscopy.

INTRODUCTION

Cutaneous melanoma presents various clinical, histopathologic, and biologic features,¹⁻⁵ mimicking other skin lesions, such as pigmented basal cell carcinoma (BCC), seborrheic keratosis (SK), and others.⁶⁻¹¹ Increased time to diagnosis is associated with poor prognosis¹² and delay can be due to both patients¹²⁻¹⁶ and physicians¹⁷⁻²² inability to determine high-risk lesions.

The wide range of clinical presentations of nonacral cutaneous melanomas were recently classified into 5 clinicopathological clusters, derived from demographic, morphologic, and pathologic factors. Cluster types are “typical,” “nevus-like,” “amelanotic/nonmelanoma skin cancer (NMSC)-like,” “SK-like,” and “lentigo/lentigo maligna (LM)-like”.²³

Dermoscopy improves sensitivity and specificity of melanoma identification compared to naked-eye examination alone (90% vs 71% and 90% vs 81%, respectively),²⁴ reducing the number of unnecessary lesion biopsies for gold standard, histopathology diagnosis.²⁵ Reflectance confocal microscopy (RCM) is a noninvasive, *in vivo* tool that provides an optical biopsy through horizontal skin scanning at nearly histologic resolution. RCM has been estimated to further reduce the number of unnecessary biopsies by 43.4% compared to dermoscopy alone.^{26,27}

Typical melanoma type lesions are commonly represented in literature, whereas other clinicopathological types are less represented.²³ Although common dermoscopy and RCM features have been correlated with histopathologic subtypes and criteria have been specified,^{1,28-32} correlations between morphologic groups as defined by Klebanov et al with dermoscopic and RCM features have not yet been described. Characterizing clinicopathological categories of melanoma could offer insights into the spectrum of melanoma presentation and enhance diagnostic accuracy.

This study aims to describe and compare the presence or absence of dermoscopic and RCM features observed among a large cohort of histopathologically confirmed cutaneous melanomas,

according to previously defined clinicopathologically-based cluster groups.²³

MATERIALS AND METHODS

We retrospectively evaluated a dedicated database of consecutive lesions assessed with RCM at the Department of Dermatology, University of Modena and Reggio Emilia, registered between January 2015 and December 2019. Melanocytic lesions in adult patients with histopathologically confirmed melanoma were initially identified. Lesions with a complete set of morphologic, dermoscopic, and RCM images were included. Given the technical limitations of RCM's ability to visualize deep skin layers,^{8,9} acral lesions are not included in the database, and are therefore not represented in this study.

Dermoscopic images were acquired using a dermatoscope on polarized mode with contact (Dermlite Photo 3Gen_ LLC). RCM imaging was performed with reflectance mode confocal laser microscope⁹ (Vivascope1500; MAVIG GmbH).

The study was approved by the Institutional Review Board (IRB) of Modena (Prot# 0008852/20), and the investigation conducted in accordance with the Declaration of Helsinki.

Clinicopathologic and dermoscopic features

Two independent dermatologists (CF, CC) were provided with a complete set of clinical images and were asked to classify each lesion according to cluster groups. For any discrepancy among lesion group assignments, a third (CR) and, when necessary, a fourth (FF) dermatologist were consulted to achieve group consensus. Clinical images were of lesions only (whole body images were not provided).

Evaluators were asked to record the presence or absence of the dermoscopic patterns listed in the revisited 7-point checklist of melanoma features³³ and the 4 features indicated by Lallas et al³⁴ for facial lesions. Cluster groups were compared to the typical cluster group. Amelanotic/NMSC-like cluster lesions

CAPSULE SUMMARY

- Clinicopathologic and dermoscopic assessments highlighted heterogeneous feature frequencies among melanoma that mimic other lesion types. Differential diagnosis was difficult to achieve, as many features are not specific to melanoma.
- RCM assessments highlighted a homogenous frequency of melanoma-specific features, increasing consistent and accurate melanoma diagnoses independently of clinical and dermoscopic features.

Abbreviations used:

BCC:	basal cell carcinoma
DEJ:	dermo-epidermal junction
LM:	lentigo maligna
LMM:	lentigo maligna type
NMSC:	nonmelanoma skin cancer
RCM:	reflectance confocal microscopy
SK:	seborrheic keratosis

included both hypomelanotic (pigmentation <30%) and true nonpigmented amelanotic melanomas.

Reflectance confocal microscopy analysis

Instrument and acquisition methods have been previously described.³⁵ At this center, all lesions candidate for excision were referred for an immediate RCM evaluation. Briefly, for each lesion, a complete set of at least 3 VivaBlock mosaics (epidermal layers, dermo-epidermal junction [DEJ], and upper dermis) were available. Lesion images were divided among 3 expert dermatologists (CR, SG, MM) for evaluation according to 8 established RCM melanoma criteria.

Histopathology

Tumors were classified as melanoma (including superficial spreading melanoma and invasive), lentigo maligna type (LM/LMM), or unclassified. Tumors were staged according to the American Joint Committee on Cancer classifications: Tis, melanoma in situ; T1, ≤ 1.0 mm; T2, ≥ 1.0 -2.0 mm; T3, ≥ 2.0 -4.0 mm; T4, > 4.0 mm.³⁶

Statistical analysis

Statistical analysis was performed using STATA v.17 (StataCorp. 2021. Stata Statistical Software: Release 17: StataCorp LLC.). Continuous variables in subgroups were compared using unpaired Student's t tests and categorical variables were compared using Pearson's chi-squared tests. Multivariate logistic regression using stepwise selection (intercept-only model fitted individual score statistics and variables $P < .05$) identified prognostic factors between cluster groups and typical lesions. Insignificant variables were removed. "Goodness of fit" was evaluated with the Hosmer and Lemeshow test. Univariate and multivariate logistic regression data (odds ratio (OR) and 95% confidence interval (CI)). A $P < .05$ was considered significant.

RESULTS

Demographic and histopathologic features

A total of 598 melanoma cases were identified for study enrollment. Fifteen lesions were excluded due

to an incomplete imaging set. In total, 583 melanomas were included in the study and analyzed, see Flow chart Fig 1.

Table I outlines demographic and histological characteristics of included lesions. In the total cohort, most patients were male (56.1%) and mean age was 57.9 years (20-89). The most common lesion location was the trunk (61.9%). In terms of lesion thickness, 45.8% were Tis (including LM). Only 8.4% of cases were $>T1$.

Most lesions were classified by clinicopathological images as typical (40.1%), followed by nevus-like (35.7%), lentigo/LM-like (11.5%), amelanotic/NMSC-like (9.4%), and very few were classified as SK-like (3.3%).

Among the clinicopathological groups, there were significant differences in patient age at diagnosis, body location, pathological diagnoses, and melanoma staging. There were no significant differences in sex distribution.

The nevus-like lesion group consisted of the youngest mean age, whereas the lentigo/LM-like group reported the oldest mean age. As expected, most lesions were observed on the trunk across clinicopathologic groups (63%-73%), with the exception of the lentigo/LM-like lesions, which were frequently observed on the head and neck (73.1%). Of the 41 lesions confirmed with histology as LM/LMM, 29 were classified clinicopathologically as lentigo-LM like (70.7%). Tis was the most common classification overall (45.8%). Among typical, amelanotic/NMSC-like and SK-like groups, the most frequent classification was T1 (54.7%, 47.3% and 57.9% respectively). All melanoma above T2 were observed in the typical and amelanotic/NMSC-like (except 1 nevus-like lesion).

Dermoscopic characterization

Typical lesions. Dermoscopic features observed in each cluster are summarized in Table II. In the total cohort of lesions, the most common dermoscopic features were atypical network (83.0%) and regression structures (white scar-like depigmentation and/or blue pepper-like granules) (63.2%). Almost all typical lesions had an atypical network (94.7%), many had regression structures (65.6%) and just over half had blue-white veil (52.8%).

Nevus-like lesions. Two patterns of the 7-point checklist (atypical network and regression structures) were present in $>50\%$ of observations.

Amelanotic/NMSC-like lesions. Only 3 patterns of the 7-point check list (atypical network, regression structures, and atypical vascular pattern) were observed in $>50\%$ of the amelanotic/NMSC-like lesions.

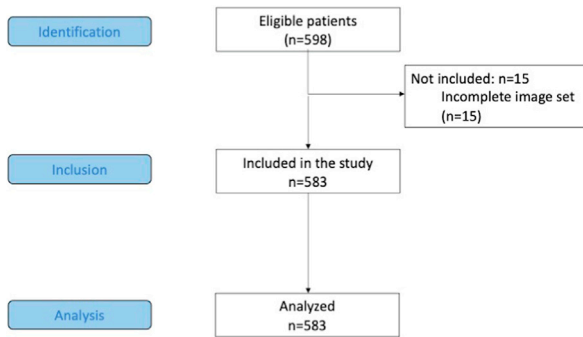


Fig 1. Strobe flow diagram.

SK-like lesions. Only 2 patterns of the 7-point check list (atypical network and regression structures) were observed in >50% of the lesions.

Lentigo/LM-like lesions. Nonevident follicles and heavy pigment intensity were observed in 63% and 59% of lesions, respectively.

A near perfect agreement between dermoscopy evaluators was observed for all dermoscopy features (Kappa. κ 0.91-0.97), highlighting the inter-rater reliability.

As expected, when the lesions were stratified by the 4 features indicated by Lallas et al for the diagnosis of facial lesions, these features were almost exclusively observed among lentigo/LM-like lesions. However, in 18 of the 57 lesions classified as lentigo/LM-like (36/114 observations), none of these specific dermoscopic features were observed (Table III).

Reflectance confocal microscopy characterization

RCM features evaluated are reported in Table IV. In most lesions, typical RCM patterns associated with melanoma diagnosis were observed, including irregular honeycomb/cobblestone pattern (93%), dermal inflammation (83%), irregular DEJ nests (79%), atypical round cells (69%), dendritic cells in sheets/tangled lines (51%) and irregular dermal nests (50%).

Regular honeycomb/cobblestone pattern, ringed, meshwork, clod, combined and non-specific patterns, regular DEJ and dermal and cerebriform nests were similar among all cluster groups compared to the typical cluster group (all $P > .05$). Interestingly, a significantly higher frequency of regular dermal nests and, as expected, dendritic cells in sheets/tangled lines, were observed among lentigo/LM-like lesions (both $P < .05$). Irregular dermal nests were observed in over 50% of SK-like lesions. The presence of cerebriform nests, though rare (6%), was mostly observed among typical and amelanotic/NMSC-like lesions.

DISCUSSION

From our large cohort of 583 histologically-confirmed melanomas, our retrospective assignment of lesions to Klebanov's clinicopathological groups highlighted similar demographic and histopathological data.²³ Clinicopathological differences were evident at the dermoscopic level. Almost all lesions exhibited at least one feature from the 7-point check list or Lallas' 4-features for LM/LMM.^{33,34} Clinicopathologic distinctions were less evident with RCM, as almost all lesions were more clearly consistent with melanoma.

Superficial melanomas were most often classified at clinicopathology as nevus-like or lentigo/LM-like, whereas melanomas ($\geq T1$) were more often classified as typical, amelanotic/NMSC-like or SK-like lesions. The importance of differential diagnosis, especially among lesions that can mimic SK and amelanotic/NMSC lesions, is crucial as a misdiagnosis of invasive melanoma lesions can be fatal.^{8,37,38}

Overall, there was a high degree of dermoscopic variability among clinicopathologic categories. Dermoscopic features observed in >50% of lesions per cluster included only 3 (atypical network, atypical vascular pattern, and regression structures) in amelanotic/NMSC-like lesions, only 2 (atypical network and regression structures) among nevus-like and SK-like lesions, and lentigo/LM-like lesions largely did not contain any of the 7-point check list features. This underlines the difficulty in diagnosing multiple subtypes of melanoma with the naked eye and dermoscopy alone.

Many of the dermoscopic features commonly presented in lesions are not specific to melanoma and cannot alone be used to distinguish melanomas from benign and other malignant lesions. For example, atypical network is a nonspecific feature, as it is observed in both melanoma and nevi.^{32,39} While regression structures are strongly associated with melanoma diagnosis, they are also present on dermoscopy in atypical BCCs.⁸ Carrera et al³⁷ demonstrated that SK-like lesions, subsequently histologically proven melanomas, exhibit blue-white veil, atypical network, and streaks. However, the authors asserted that the 7-point check list was unable to assist in diagnosis, as the most helpful criterion was the blue-black sign (not in the 7-point check list). Furthermore, we observed nonspecific regression structures in over 70% of SK-like lesions. Correct diagnosis of melanoma considered SK-like lesions at clinicopathological observation remains difficult with dermoscopy alone.

In a study of amelanotic and hypomelanotic melanoma lesions, Pizzichetta et al reported that

Table I. Melanoma demographic and histopathological characteristics, classified according to 5 morphological cluster types

	Total <i>n</i> = 583 (100)	Typical <i>n</i> = 234 (40.1)	Nevus-like <i>n</i> = 208 (35.7)	Amelanotic NMSC-like <i>n</i> = 55 (9.4)	SK-like <i>n</i> = 19 (3.3)	Lentigo LM-like <i>n</i> = 57 (11.5)	<i>P</i> -value
Sex, male, <i>n</i> (%)	327 (56.1)	143 (61.1)	109 (52.4)	26 (47.2)	13 (68.4)	36 (53.7)	.181
Age, <i>y</i> , mean ± SD (range)	57.9 ± 15.2 (20-89)	59.9 ± 15.6 (21-89)	52.6 ± 14.0 (20-83)	57.9 ± 13.7 (22-77)	59.7 ± 15.3 (35-85)	67.6 ± 12.4 (42-87)	<.001
Age, <i>y</i> , median (IQR)	59 (46-70)	60 (47-73)	51 (43-64)	61 (46-72)	61 (48-71)	70 (60-78)	<.001
Body site, <i>n</i> (%)							
Head and neck	61 (10.5)	6 (2.6)	5 (2.4)	0 (0.0)	1 (5.3)	49 (73.1)	<.001
Trunk	361 (61.9)	169 (72.2)	136 (65.4)	31 (56.4)	12 (63.2)	13 (19.4)	
Upper limb	63 (10.8)	27 (11.5)	20 (9.6)	9 (16.94)	4 (21.0)	3 (4.5)	
Lower limb	98 (16.8)	32 (13.7)	47 (22.6)	15 (27.3)	2 (10.5)	2 (2.9)	
Histopathological melanoma type diagnosis, <i>n</i> (%)							
Melanoma (superficial spreading and invasive)	536 (92.0)	229 (97.9)	198 (95.2)	63 (96.4)	18 (94.7)	38 (56.7)	<.001
LM/LMM	41 (7.0)	4 (1.7)	7 (3.4)	0 (0.0)	1 (5.3)	29 (43.3)	
Unclassified	6 (1.0)	1 (0.4)	3 (1.4)	2 (3.6)	0 (0.0)	0 (0.0)	
Melanoma thickness, mm, <i>n</i> (%)							
Tis (0.0)	267 (45.8)	73 (31.2)	120 (57.7)	14 (25.4)	8 (42.1)	52 (77.6)	<.001
T1 (≤1.0)	267 (45.8)	128 (54.7)	87 (41.8)	26 (47.3)	11 (57.9)	15 (22.4)	
T2 (>1.0-2.0)	32 (5.5)	20 (8.5)	1 (0.5)	11 (20.0)	0 (0.0)	0 (0.0)	
T3 (≥2.0 4.0)	13 (2.2)	11 (4.7)	0 (0.0)	2 (3.6)	0 (0.0)	0 (0.0)	
T4 (≥4.0)	4 (0.7)	2 (0.8)	0 (0.0)	2 (3.6)	0 (0.0)	0 (0.0)	

LM, Lentigo maligna; LMM, lentigo maligna melan; MIS, melanoma in situ; NMSC, non-melanocytic skin cancer; SK, seborrheic keratoses.

Table II. Melanoma subtype: frequencies of dermoscopic features among morphological groups of melanoma, compared to typical melanoma subtype

<i>n</i> (%)	Total	Typical	Nevus-like	Amelanotic NMSC-like	SK-like	Lentigo LM-like	Kappa. κ
	<i>n</i> = 583 <i>n. observation</i> = 1166 (100.0)	<i>n</i> = 234 <i>n. observations</i> = 468 (40.1)	<i>n</i> = 208 <i>n. observations</i> = 416 (35.7)	<i>n</i> = 55 <i>n. observations</i> = 110 (9.4)	<i>n</i> = 19 <i>n. observations</i> = 38 (3.3)	<i>n</i> = 57 <i>n. observations</i> = 114 (11.5)	
7-point check list							
Atypical network*	968 (83.0)	443 (94.7)	381 (91.6)	72 (65.5) [†]	30 (78.9) [†]	42 (31.3) [†]	0.96
Blue-white veil*	392 (33.6)	247 (52.8)	100 (24.0) [†]	16 (14.5) [†]	16 (42.1)	13 (9.7) [†]	0.92
Atypical vascular pattern*	215 (18.4)	76 (16.2)	47 (11.3)	78 (70.9) [†]	10 (26.3)	4 (3.0) [†]	0.91
Irregular dots/globules*	288 (24.7)	127 (27.1)	122 (29.3)	27 (24.5)	4 (10.5)	8 (6.0) [†]	0.92
Irregular streaks*	195 (16.7)	122 (26.1)	65 (15.6) [†]	2 (1.8) [†]	6 (15.8)	0 (0.0) [†]	0.97
Irregular blotches*	355 (30.4)	229 (48.9)	100 (24.0) [†]	10 (9.1) [†]	7 (18.4) [†]	9 (6.7) [†]	0.95
Regression structures*	737 (63.2)	307 (65.6)	244 (58.7)	95 (86.4) [†]	28 (73.7)	63 (47.0) [†]	0.94
Lallas 4-features for LM identification							
Grey rhomboidal lines*	48 (4.1)	1 (0.2)	2 (0.5)	0 (0.0)	0 (0.0)	45 (33.6) [†]	0.89
Nonevident follicles*	96 (8.2)	2 (0.4)	7 (1.7)	0 (0.0)	2 (5.3)	85 (63.4) [†]	0.94
Grey circles*	62 (5.3)	1 (0.2)	8 (1.9)	0 (0.0)	2 (5.3)	51 (38.1) [†]	0.86
Pigmentation intensity (heavy)*	90 (7.7)	6 (1.3)	4 (1.0)	0 (0.0)	0 (0.0)	80 (59.7) [†]	0.96

Statistical differences are evidenced with an asterisk and reader agreement with kappa statistics, according to the number of observations (2 evaluators).

LM, Lentigo maligna; MIS, melanoma in situ; NMSC, non-melanocytic skin cancer; SK, seborrheic keratoses.

*Significant differences among all morphological groups ($P < .001$).

[†]Statistical significant difference ($P < .05$) compared with the typical melanoma sub-group. Kappa interpretation of agreement: less than chance ($\kappa < 0$), slight ($\kappa = 0.01-0.20$), fair ($\kappa = 0.21-0.4$), moderate ($\kappa = 0.41-0.60$), substantial ($\kappa = 0.61-0.80$), and almost perfect ($\kappa = 0.81-0.99$).

Table III. Melanoma features

	Typical <i>n</i> = 234 <i>n. observations</i> = 468 (40.1)	Nevus-like <i>n</i> = 208 <i>n. observations</i> = 416 (35.7)	Amelanotic NMSC-like <i>n</i> = 55 <i>n. observations</i> = 110 (9.4)	SK-like <i>n</i> = 19 <i>n. observations</i> = 38 (3.3)	Lentigo LM-like <i>n</i> = 57 <i>n. observations</i> = 114 (11.5)
No. of features observed: 7 point check list					
0	0 (0.0)	6 (1.4)*	0 (0.0)	0 (0.0)	60 (44.8) [†]
1	27 (5.8)	45 (10.8)	4 (3.6)	8 (21.1)	32 (23.9)
2	109 (23.3)	177 (42.6)	43 (39.1)	10 (26.3)	25 (18.7)
3	131 (28.0)	112 (26.9)	44 (40.0)	10 (26.3)	12 (9.0)
4	120 (25.6)	59 (14.2)	17 (15.5)	7 (18.4)	4 (3.0)
5	55 (11.8)	14 (3.4)	2 (1.8)	3 (7.9)	1 (0.8)
6	24 (5.1)	3 (0.7)	0 (0.0)	0 (0.0)	0 (0.0)
7	2 (0.4)	0 (0.0)	0 (0.0)	0 (0.0)	0 (0.0)
No. of features observed: Lallas 4-features for LM identification					
0	462 (98.7)	404 (97.1)	110 (100.0)	36 (94.7)	36 (26.9) [‡]
1	3 (0.6)	7 (1.7)	0 (0.0)	0 (0.0)	8 (6.0)
2	2 (0.4)	3 (0.7)	0 (0.0)	2 (5.3)	37 (27.6)
3	1 (0.2)	0 (0.0)	0 (0.0)	0 (0.0)	33 (24.6)
4	0 (0.0)	2 (0.5)	0 (0.0)	0 (0.0)	20 (14.9)

Number of features observed in lesions, according to the melanoma 7-point check-list and the lentigo maligna 4 features identified by Lallas, according to the number of observations (2 evaluators).

MIS, melanoma in situ; *NMSC*, non-melanocytic skin cancer; *SK*, seborrheic keratoses, *LM*, lentigo maligna.

*At histopathology, 3 lesions were confirmed in-situ (*n* = 2) and thin invasive melanoma (*n* = 1).

[†]30 lesions were confirmed LM (*n* = 20), in-situ (*n* = 6) and thin invasive melanoma (*n* = 4).

[‡]Of the 18 lesions, 1 lesion was confirmed LM. A complete agreement of the absence of dermoscopy features was observed by both evaluators.

atypical vascular patterns were common. The authors suggested that other features of the 7-point check list are required to confirm melanoma diagnosis, including atypical network and regression structures,⁴⁰ frequently observed among most melanoma lesions in our study. As demonstrated by Di Matteo et al⁸ in a comparative study of atypical, nonfacial BCCs (≥1 7-point check list criteria) and melanoma (with at least one BCC criteria), atypical vascular patterns should be considered a shared feature. In the study of Lallas et al³⁴, evident follicles were among the 3 patterns representing diagnostic clues for pigmented actinic keratosis, while heavy pigment intensity was found highly suggestive of LM. Among lentigo/LM-like lesions in this study, nonevident follicles were observed in 63%, and heavy pigment intensity in 59%.

With dermoscopy, the clinicopathologic groups differed significantly, especially regarding the number of features of the 7-point check list or Lallas et al 4-features; the typical cluster was the easiest to

diagnose. Three lesions (in the nevus-like group) did not contain any of the 7-point check list features, whereas RCM features (atypical round cells, DEJ nests, dermal nests, and inflammation) provided diagnostic clarity. Eighteen lesions (in the lentigo/LM-like group) did not contain any of the Lallas et al 4-features whereas RCM features (dendritic cell in sheets/tangled lines and regular dermal nests) again provided diagnostic clarity.⁴¹

Very few differences between the clusters were observed at RCM evaluation, with a high representation of irregular honeycomb and cobblestone patterns, dendritic cells in sheets/tangled lines, atypical round cells, irregular DEJ and dermal nests, all highly suggestive of melanoma diagnosis. The significantly higher frequency of dendritic cells in sheets/tangled lines as well as the significant absence of dermal nests characterized lentigo/LM-like lesions, underlining the diagnostic efficacy of RCM for facial lesions. The intraepidermal proliferation of dendritic cells in LM has previously been described.⁴¹

Table IV. RCM and melanoma

	Total <i>n</i> = 583 (100)	Typical <i>n</i> = 234 (40.1)	Nevus-like <i>n</i> = 208 (35.7)	Amelanotic NMSC-like <i>n</i> = 55 (9.4)	SK-like <i>n</i> = 19 (3.3)	Lentigo LM-like <i>n</i> = 67 (11.5)
Honeycomb/cobblestone pattern						
Regular	36 (6.2)	11 (4.7)	20 (9.6)	2 (3.6)	1 (5.3)	2 (3.0)
Irregular	542 (93.0)	222 (94.9)	187 (89.9)	52 (94.5)	18 (94.7)	63 (94)
DEJ Pattern						
Ringed	57 (9.8)	20 (8.5)	29 (13.9)	1 (1.8)	2 (10.5)	5 (7.5)
Meshwork	272 (46.7)	95 (40.6)	108 (51.9)	22 (40)	6 (31.6)	41 (61.2)
Clod	32 (5.5)	15 (6.4)	12 (5.8)	4 (7.3)	1 (5.3)	0 (0.0)
Combined	41 (7.0)	25 (10.7)	7 (3.4)	4 (7.3)	3 (15.8)	2 (3.0)
Non-specific	177 (30.4)	78 (33.3)	51 (24.5)	23 (41.8)	7 (36.8)	18 (26.9)
Dendritic cells in sheets/ tangled lines	299 (51.3)	115 (49.1)	90 (43.3)	27 (49.1)	12 (63.2)	55 (82.1)*
Atypical round cells	404 (69.3)	173 (73.9)	140 (67.3)	31 (56.4)	9 (47.4)	51 (76.1)
Dermal-epidermal junction nests						
Regular	13 (2.2)	3 (1.3)	6 (2.9)	1 (1.8)	0 (0.0)	3 (4.5)
Irregular	460 (78.9)	187 (79.9)	167 (80.3)	41 (74.5)	16 (84.2)	49 (73.1)
Dermal nests						
Regular	87 (14.9)	24 (10.3)	49 (23.6)*	4 (7.3)*	2 (10.5)	8 (11.9)*
Irregular	222 (38.1)	126 (53.8)	56 (26.9)	19 (34.5)	10 (52.6)	11 (16.4)
Inflammation	482 (82.7)	188 (80.3)	174 (83.7)	45 (81.8)	17 (89.5)	58 (86.6)
Cerebriform nests	35 (6.0)	18 (7.7)	6 (2.9)	8 (14.5)	1 (5.3)	2 (3.0)

Reflectance confocal microscopy features frequencies according to cluster groups defined by morphological images, compared to typical lesions (single evaluator).

DEJ, Dermo-epidermal junction; LM, lentigo maligna; MIS, melanoma in situ; NMSC, non-melanocytic skin cancer; SK, seborrheic keratoses.

*Statistical significant difference ($P < .05$) compared with the typical melanoma sub-group.

SK-like melanoma was the smallest group and was largely similar to typical melanoma lesions on RCM. Currently, there are very few RCM studies dedicated to SK-like lesions, perhaps justified by the presence of superficial hyperkeratosis which impedes RCM visualization of the deeper dermis. Oliveira et al described a case of SK-like melanoma observed with RCM. Assessment revealed large, roundish pagetoid cells (isolated or focally aggregated) forming irregular nests, enabling clear diagnostic assumption of melanoma.³⁸ Both RCM features were also observed among our cohort (47.4% and 52.6%), with dendritic cells in sheets/tangled lines also evident in almost two thirds of the SK-like lesions (63.2%).

Amelanotic/NMSC-like lesions were characterized by both meshwork and non-specific patterns, and frequent cerebriform nests, also observed by Pizzichetta et al.⁴²

The only other significant differences were observed with the frequencies of regular dermal nests, most often observed in nevus-like lesions as they were most often Tis.

As suggested by Klebanov et al, computer-aided diagnosis requires a wide spectrum of images to

increase the performance of artificial intelligence in the identification of suspected melanocytic lesions, and all the clinical variability in shape, size, lesion location, surrounding healthy or cancerization field, skin condition, and color.⁴³ Our study's characterization of dermoscopy and RCM features assists clinicians in differential diagnoses of various subtypes of melanoma compared to typical melanoma lesions.

This study is limited by the small sample of SK-like lesions, partially hindering the relevance of significant differences on dermoscopy and RCM. Further, RCM analyses were only performed once, and the reproduction of outcomes cannot be estimated. In addition, the reviewers were aware that all lesions were confirmed cutaneous melanomas, and therefore confirmation bias represents an inherent limitation to presented observations. As this study included the analysis of the presence or absence of features from the 7-point check list and the Lallas 4-features for LM identification only, diagnostic comparison with lesions having predominately benign features, such as lichen planus-like keratosis, could not be performed.

The clinicopathological classification of melanoma highlights the many forms melanoma may

take when observed by the naked eye. Our analysis underlines that this spectrum of melanoma presentation persists with dermoscopy, with differential diagnoses of nevus-like, amelanotic/NMSC-like, and SK-like lesions by dermoscopy alone being especially difficult. Conversely, few differences between clusters were observed with RCM evaluation, and thus RCM has the potential to augment our ability to consistently and accurately diagnose melanoma independently of clinical and dermoscopic features.

Conflicts of interest

None disclosed.

REFERENCES

- Pellacani G, De Pace B, Reggiani C, et al. Distinct melanoma types based on reflectance confocal microscopy. *Exp Dermatol*. 2014;23(6):414-418. <https://doi.org/10.1111/exd.12417>
- Weyers W, Euler M, Diaz-Cascajo C, Schill WB, Bonczkowitz M. Classification of cutaneous malignant melanoma: a reassessment of histopathologic criteria for the distinction of different types. *Cancer*. 1999;86(2):288-299. [https://doi.org/10.1002/\(sici\)1097-0142\(19990715\)86:2<288::aid-cncr13>3.0.co;2-s](https://doi.org/10.1002/(sici)1097-0142(19990715)86:2<288::aid-cncr13>3.0.co;2-s)
- Scoyler RA, Long GV, Thompson JF. Evolving concepts in melanoma classification and their relevance to multidisciplinary melanoma patient care. *Mol Oncol*. 2011;5(2):124-136. <https://doi.org/10.1016/j.molonc.2011.03.002>
- Clark WH Jr, From L, Bernardino EA, Mihm MC. The histogenesis and biologic behavior of primary human malignant melanomas of the skin. *Cancer Res*. 1969;29(3):705-727.
- Zalaudek I, Marghoob AA, Scope A, et al. Three roots of melanoma. *Arch Dermatol*. 2008;144(10):1375-1379. <https://doi.org/10.1001/archderm.144.10.1375>
- Farnetani F, Scope A, Coco V, et al. Paradigmatic cases of pigmented lesions: how to not miss melanoma. *J Dermatol*. 2016;43(12):1433-1437. <https://doi.org/10.1111/1346-8138.13522>
- Izlikson L, Sober AJ, Mihm MC Jr, Zembowicz A. Prevalence of melanoma clinically resembling seborrheic keratosis: analysis of 9204 cases. *Arch Dermatol*. 2002;138(12):1562-1566. <https://doi.org/10.1001/archderm.138.12.1562>
- Di Matteo E, Pampena R, Pizzichetta MA, et al. Unusual dermoscopic patterns of basal cell carcinoma mimicking melanoma. *Exp Dermatol*. 2022;31(6):890-898. <https://doi.org/10.1111/exd.14533>
- Shahriari N, Grant-Kels JM, Rabinovitz H, Oliviero M, Scope A. Reflectance confocal microscopy: diagnostic criteria of common benign and malignant neoplasms, dermoscopic and histopathologic correlates of key confocal criteria, and diagnostic algorithms. *J Am Acad Dermatol*. 2021;84(1):17-31. <https://doi.org/10.1016/j.jaad.2020.05.154>
- Farnetani F, Pedroni G, Lippolis N, et al. Facial seborrheic keratosis with unusual dermoscopic patterns can be differentiated from other skin malignancies by in vivo reflectance confocal microscopy. *J Eur Acad Dermatol Venereol*. 2021;35(11):e784-e787. <https://doi.org/10.1111/jdv.17470>
- Pezzini C, Mandel VD, Persechino F, et al. Seborrheic keratoses mimicking melanoma unveiled by in vivo reflectance confocal microscopy. *Skin Res Technol*. 2018;24(2):285-293. <https://doi.org/10.1111/srt.12427>
- Goodson AG, Grossman D. Strategies for early melanoma detection: approaches to the patient with nevi. *J Am Acad Dermatol*. 2009;60(5):719-735. <https://doi.org/10.1016/j.jaad.2008.10.065>; quiz 736-8.
- Schmid-Wendtner MH, Baumert J, Stange J, Volkenandt M. Delay in the diagnosis of cutaneous melanoma: an analysis of 233 patients. *Melanoma Res*. 2002;12(4):389-394. <https://doi.org/10.1097/00008390-200208000-00012>
- Krige JE, Isaacs S, Hudson DA, King HS, Strover RM, Johnson CA. Delay in the diagnosis of cutaneous malignant melanoma. A prospective study in 250 patients. *Cancer*. 1991;68(9):2064-2068. [https://doi.org/10.1002/1097-0142\(19911101\)68:9<2064::aid-cncr2820680937>3.0.co;2-3](https://doi.org/10.1002/1097-0142(19911101)68:9<2064::aid-cncr2820680937>3.0.co;2-3)
- Doherty VR, MacKie RM. Reasons for poor prognosis in British patients with cutaneous malignant melanoma. *Br Med J*. 1986;292(6526):987-989. <https://doi.org/10.1136/bmj.292.6526.987>
- Richard MA, Grob JJ, Avril MF, et al. Melanoma and tumor thickness: challenges of early diagnosis. *Arch Dermatol*. 1999;135(3):269-274. <https://doi.org/10.1001/archderm.135.3.269>
- Gajda M, Kaminska-Winciorek G. Do not let to be late: overview of reasons for melanoma delayed diagnosis. *Asian Pac J Cancer Prev*. 2014;15(9):3873-3877. <https://doi.org/10.7314/apjcp.2014.15.9.3873>
- Xavier MHSB, Drummond-Lage AP, Baeta C, Rocha L, Almeida AM, Wainstein AJA. Delay in cutaneous melanoma diagnosis: sequence analyses from suspicion to diagnosis in 211 patients. *Medicine (Baltimore)*. 2016;95(31):e4396. <https://doi.org/10.1097/MD.00000000000004396>
- Betti R, Vergani R, Tolomio E, Santambrogio R, Crosti C. Factors of delay in the diagnosis of melanoma. *Eur J Dermatol*. 2003;13(2):183-188.
- Cassileth BR, Temoshok L, Frederick BE, et al. Patient and physician delay in melanoma diagnosis. *J Am Acad Dermatol*. 1988;18(3):591-598. [https://doi.org/10.1016/s0190-9622\(88\)70081-x](https://doi.org/10.1016/s0190-9622(88)70081-x)
- Blum A, Brand CU, Ellwanger U, et al. Awareness and early detection of cutaneous melanoma: an analysis of factors related to delay in treatment. *Br J Dermatol*. 1999;141(5):783-787. <https://doi.org/10.1046/j.1365-2133.1999.03196.x>
- Brochez L, Verhaeghe E, Bleyen L, Naeyaert JM. Time delays and related factors in the diagnosis of cutaneous melanoma. *Eur J Cancer*. 2001;37(7):843-848. [https://doi.org/10.1016/s0959-8049\(00\)00418-4](https://doi.org/10.1016/s0959-8049(00)00418-4)
- Klebanov N, Gunasekera NS, Lin WM, et al. Clinical spectrum of cutaneous melanoma morphology. *J Am Acad Dermatol*. 2019;80(1):178-188.e3. <https://doi.org/10.1016/j.jaad.2018.08.028>
- Vestergaard ME, Macaskill P, Holt PE, Menzies SW. Dermoscopy compared with naked eye examination for the diagnosis of primary melanoma: a meta-analysis of studies performed in a clinical setting. *Br J Dermatol*. 2008;159(3):669-676. <https://doi.org/10.1111/j.1365-2133.2008.08713.x>
- Argenziano G, Albertini G, Castagnetti F, et al. Early diagnosis of melanoma: what is the impact of dermoscopy? *Dermatol Ther*. 2012;25(5):403-409. <https://doi.org/10.1111/j.1529-8019.2012.01482.x>
- Pellacani G, Farnetani F, Ciardo S, et al. Effect of reflectance confocal microscopy for suspect lesions on diagnostic accuracy in melanoma: a randomized clinical trial. *JAMA Dermatol*. 2022;158:754-761. <https://doi.org/10.1001/jamadermatol.2022.1570>
- Pezzini C, Kaleci S, Chester J, Farnetani F, Longo C, Pellacani G. Reflectance confocal microscopy diagnostic accuracy for malignant melanoma in different clinical settings: systematic review and meta-analysis. *J Eur Acad Dermatol Venereol*. 2020;34(10):2268-2279. <https://doi.org/10.1111/jdv.16248>

28. Pellacani G, Scope A, Gonzalez S, et al. Reflectance confocal microscopy made easy: the 4 must-know key features for the diagnosis of melanoma and nonmelanoma skin cancers. *J Am Acad Dermatol*. 2019;81(2):520-526. <https://doi.org/10.1016/j.jaad.2019.03.085>
29. Longo C, Farnetani F, Ciardo S, et al. Is confocal microscopy a valuable tool in diagnosing nodular lesions? A study of 140 cases. *Br J Dermatol*. 2013;169(1):58-67. <https://doi.org/10.1111/bjd.12259>
30. Waddell A, Star P, Guitera P. Advances in the use of reflectance confocal microscopy in melanoma. *Melanoma Manag*. 2018; 5(1):MMT04. <https://doi.org/10.2217/mmt-2018-0001>
31. Gill M, Longo C, Farnetani F, Cesinaro AM, González S, Pellacani G. Non-invasive in vivo dermatopathology: identification of reflectance confocal microscopic correlates to specific histological features seen in melanocytic neoplasms. *J Eur Acad Dermatol Venereol*. 2014;28(8):1069-1078. <https://doi.org/10.1111/jdv.12285>
32. De Pace B, Farnetani F, Losi A, et al. Reinterpreting dermoscopic pigment network with reflectance confocal microscopy for identification of melanoma-specific features. *J Eur Acad Dermatol Venereol*. 2018;32(6):947-955. <https://doi.org/10.1111/jdv.14675>
33. Argenziano G, Catricalà C, Ardigo M, et al. Seven-point checklist of dermoscopy revisited. *Br J Dermatol*. 2011;164(4): 785-790. <https://doi.org/10.1111/j.1365-2133.2010.10194.x>
34. Lallas A, Tschandl P, Kyrgidis A, et al. Dermoscopic clues to differentiate facial lentigo maligna from pigmented actinic keratosis. *Br J Dermatol*. 2016;174(5):1079-1085. <https://doi.org/10.1111/bjd.14355>
35. Navarrete-Dechent C, Liopyris K, Monnier J, et al. Reflectance confocal microscopy terminology glossary for melanocytic skin lesions: a systematic review. *J Am Acad Dermatol*. 2021; 84(1):102-119. <https://doi.org/10.1016/j.jaad.2020.05.097>
36. Keung EZ, Gershenwald JE. The eighth edition American Joint Committee on Cancer (AJCC) melanoma staging system: implications for melanoma treatment and care. *Expert Rev Anticancer Ther*. 2018;18(8):775-784. <https://doi.org/10.1080/14737140.2018.1489246>
37. Carrera C, Segura S, Aguilera P, et al. Dermoscopic clues for diagnosing melanomas that resemble seborrheic keratosis. *JAMA Dermatol*. 2017;153(6):544-551. <https://doi.org/10.1001/jamadermatol.2017.0129>
38. Oliveira A, Arzberger E, Massone C, Carrera C, Zalaudek I. Verrucous melanoma simulating melanoacanthoma: dermoscopic, reflectance confocal microscopic and high-definition optical coherence tomography presentation of a rare melanoma variant. *Australas J Dermatol*. 2016;57(1):72-73. <https://doi.org/10.1111/ajd.12236>
39. Seidenari S, Ferrari C, Borsari S, et al. The dermoscopic variability of pigment network in melanoma in situ. *Melanoma Res*. 2012;22(2):151-157. <https://doi.org/10.1097/cmr.0b013e328350fa28>
40. Pizzichetta MA, Talamini R, Stanganelli I, et al. Amelanotic/hypomelanotic melanoma: clinical and dermoscopic features. *Br J Dermatol*. 2004;150(6):1117-1124. <https://doi.org/10.1111/j.1365-2133.2004.05928.x>
41. de Carvalho N, Farnetani F, Ciardo S, et al. Reflectance confocal microscopy correlates of dermoscopic patterns of facial lesions help to discriminate lentigo maligna from pigmented nonmelanocytic macules. *Br J Dermatol*. 2015;173(1):128-133. <https://doi.org/10.1111/bjd.13546>
42. Pizzichetta MA, Canzonieri V, Rubegni P, et al. Tips for difficult to diagnose hypomelanotic melanomas on reflectance confocal microscopy. *J Dermatol*. 2021;48(7):1067-1072. <https://doi.org/10.1111/1346-8138.15815>
43. Grignaffini F, Barbuto F, Piazza L, et al. Machine learning approaches for skin cancer classification from dermoscopic images: a systematic review. *Algorithms*. 2022;15(11):438. <https://doi.org/10.3390/a15110438>